

Endoscopic Third Ventriculostomy: Role of Image Guidance in Reducing the Complications

Abstract

Introduction: Endoscopic third ventriculostomy (ETV) is performed by neurosurgeons around the world for the management of hydrocephalus. ETV has been associated with multiple complications, the most significant being iatrogenic injury to the fornix. We aim to establish the fact that the use of image guidance while planning a trajectory can reduce the incidence of complications as it significantly alters the usual approach for ETV, i.e., the coronal burr hole can be useful for young neurosurgeons to overcome the learning curve associated with the procedure.

Materials and Methods: This is a prospective, observational study conducted at Liaquat National Hospital. In this study, 43 patients were included who underwent ETV for hydrocephalus. Complications were divided into three major groups: arterial hemorrhage, venous hemorrhage, and injury to neural structures (fornix, hypothalamus, and oculomotor nerve). The data were compared with studies showing the complications of ETV with and without usage of image guidance. **Results:** Among the 43 patients who underwent ETV with image guidance, only two patients (4.65%) had iatrogenic fornix contusions. Neither of them developed memory impairment. None of the patients (0%) encountered other major iatrogenic complications, including injury to the mammillary body, basilar artery, or oculomotor nerve. **Conclusion:** The use of image guidance can reduce trajectory-related complications, including hemorrhage and iatrogenic injuries to the fornix. This study showed that the altered trajectory was beneficial in avoiding major neurological structures while introducing an endoscope through the cortex into the ventricular system.

Keywords: Cerebrospinal fluid diversion, endoscopic third ventriculostomy, endoscopic third ventriculostomy complications, fornix injury, hydrocephalus, image guidance

Muhammad Samir Irfan Wasi,
Salman Sharif¹,
Yousuf Shaikh¹

Department of Neurosurgery, Hull Royal Infirmary, Hull, United Kingdom, ¹Department of Neurosurgery, Liaquat National Hospital, Karachi, Pakistan

Introduction

Cerebrospinal fluid (CSF) diversion through shunts has been used for both communicating and noncommunicating hydrocephalus. The procedure constitutes one of the most complex challenges in the neurosurgical practice. Shunt hardware has seen significant advances in the last decade. Diversion by endoscopic third ventriculostomy (ETV) has been in practice for nearly a century now.^[1] It has recently been rejuvenated with advancements in endoscopic techniques including three-dimensional and high-definition images and other optical enhancement measures.

In 1923, Mixer, a urologist, performed the first ETV using a urethroscope for the procedure.^[2] However, such primitive attempts at the procedure were encountered with failure and were not deemed ideal for

therapeutic intervention. This changed with recent advances in endoscopic equipment and instruments when ETV was brought to focus.

The procedure involves introducing a rigid endoscope typically through a burrhole placed 0.5 cm anterior to the coronal suture and 2.5 cm lateral to the midline.^[3,4,5] This is maneuvered to approach the floor of the third ventricle through the foramen of Monro and is perforated between the infundibular recess anteriorly and mammillary bodies posteriorly. The aim of the surgery is to visualize the contents of interpeduncular cisterns, including the basilar artery, the brainstem, and dura of the clivus.^[6]

The complications of the procedure include hemorrhage secondary to basilar artery rupture and injury to neural structures, including the hypothalamus, pituitary, and

Address for correspondence:

*Dr. Muhammad Samir Irfan Wasi,
Ward 40, Neurosurgery
Department, Hull Royal
Infirmary, HU32JZ, Hull, United
Kingdom.
E-mail: dr.sameerirfan@gmail.
com*

Access this article online

Website: www.asianjns.org

DOI: 10.4103/ajns.AJNS_161_20

Quick Response Code:



How to cite this article: Wasi MS, Sharif S, Shaikh Y. Endoscopic third ventriculostomy: Role of image guidance in reducing the complications. Asian J Neurosurg 2020;15:926-30.

Submitted: 16-Apr-2020

Revised: 04-May-2020

Accepted: 21-Jun-2020

Published: 19-Oct-2020

This is an open access journal, and articles are distributed under the terms of the Creative Commons Attribution-NonCommercial-ShareAlike 4.0 License, which allows others to remix, tweak, and build upon the work non-commercially, as long as appropriate credit is given and the new creations are licensed under the identical terms.

For reprints contact: WKHLRPMedknow_reprints@wolterskluwer.com

fornix. Several studies have reported anterograde amnesia secondary to forniceal injury.^[7] All these complications must be taken into consideration while opting for an endoscopic procedure for the management of hydrocephalus.

The aim of our study was to see whether image guidance would alter the incidence of neural and hemorrhagic iatrogenic injuries when trying to reach the third ventricle through foramen of Monro. Image guidance can thus help young neurosurgeons to overcome the learning curve associated with this procedure.

Materials and Methods

This was a prospective, descriptive, and observational study conducted in the neurosurgery department of Liaquat National Hospital in Karachi, Pakistan. A total of 43 patients were included in the study who underwent ETV between June 2015 and December 2018. The recorded information included age, sex, cause of hydrocephalus, and intraoperative complications. All patients with a previous history of head injury and those who underwent ETV without the image guidance trajectory planning were excluded from the study.

The intraoperative complications were divided into three major groups, and the results were analyzed using the SPSS software version 23 (IBM Corp. Released 2015. IBM SPSS Statistics for Windows, Version 23.0. Armonk, NY: IBM Corp.). The results of this study were compared with the complications reported in historical studies conducted on ETV with and without intraoperative image guidance usage [Tables 1 and 2].

Patients were divided into three groups according to the complications developed. Group A included patients with hemorrhage including rupture of basilar artery or its branches. Group B included patients developing venous hemorrhages, whereas Group C included patients with neural injuries. Group C was further divided into C1

(injury to oculomotor nerve), C2 (injury to hypothalamus), and C3 (injury to fornix). Memory assessment was done with Mini-Mental State Examination (MMSE) score. Pre- and post-operative scores were assessed and compared. The normal range of MMSE score was established in the range of 25–30.^[8] Null hypothesis and alternative hypothesis were put in place. Alternative hypothesis: MMSE scores stay within the normal range postoperatively. Null hypothesis: MMSE scores do not stay within normal range postoperatively. $P < 0.5$ was considered statistically significant.

Surgical technique

A preoperative magnetic resonance imaging (MRI) of the brain with image-guided protocol was done and uploaded on the neuronavigation system. All patients were operated under general anesthesia in the supine position. The ideal trajectory and incision site were identified before incision thus making sure that neural structures along the path were not manipulated. Basilar artery was identified in the sagittal section of MRI. A center point of third ventricular floor was pointed out as site of ventriculostomy. Care was taken to avoid making the stoma close to basilar artery and thus avoid rupture. A line was drawn from this point to the foramen of Monro and then extended up to the scalp. This point marks the optimal entry point for the procedure. Once we had the burr hole site, the rest of the procedure was done based on the description provided by Sainte-Rose and Chumas.^[9] An operating sheath was inserted, and a 0° endoscope was introduced through it after removing the stylet. Anatomical structures including the foramen of Monro, choroid plexus, thalamostriate, and septal veins were identified, and the sheath was advanced through the foramen down to the floor of the third ventricle. It is perforated using a blunt instrument such as bipolar probe, between infundibular recess in front, and mammillary bodies behind. Bipolar diathermy is used with caution when the floor of the third ventricle is opaque. This is to avoid

Table 1: Comparison of our complications with studies conducted on endoscopic third ventriculostomy procedures without image guidance

| Groups | Complications | Wasi et al. | Baykan et al. ^[18] (%) | Bouras and Sgouros ^[23] (%) | Oertel et al. ^[20] (%) | Oertel et al. ^[24] (%) |
|--------|--|-------------|-----------------------------------|--|-----------------------------------|-----------------------------------|
| A | Hemorrhage (including rupture of basilar artery or its branches) | 0 | 0.5 | 3.9 | 0.8 | 0 |
| B | Venous bleed | 0 | 2.4 | - | | 0 |
| C | Neural injuries | | | | | |
| C1 | Oculomotor injury | 0 | - | 1.2 | 2.3 | 0 |
| C2 | Hypothalamus | 0 | - | 0.9 | | 0 |
| C3 | Fornix | 4.65 | - | 0.1 | 16.4 | 5 |

Table 2: Comparison of complication rates of image-guided endoscopic third ventriculostomy

| | Wasi et al. | Martínez-Moreno et al. ^[21] | Ozgural et al. ^[25] | Broggi et al. ^[26] |
|---------------------------|-------------|--|--------------------------------|-------------------------------|
| Number of patients | 43 | 15 | 28 | 17 |
| Fornix injury (%) | 4.65 | 6.6 | 0 | 0 |
| Minor vascular injury (%) | 0 | 0 | 7.14 | 5.88 |

iatrogenic injury to underlying structures. A wide enough opening in the floor of the third ventricle must be made. An endoscope is inserted through the prepontine cistern to see the presence of a secondary membrane. If present, a blunt probe can be used to puncture this membrane. Judicial use of a Fogarty balloon catheter may be done to dilate the stoma. It is important to visualize the basilar artery and cranial nerves. Underlying secondary arachnoid membranes or adhesions are opened up in the same fashion.

Image guidance is used at all stages of surgery, starting from the burr hole entry through the third ventricle to navigating inside the brain. While removing the endoscope, pulsatile movement of the surgical stoma was identified to confirm the free-flowing CSF through fenestration connecting the third ventricle and the prepontine subarachnoid space. Special attention was directed toward looking for contusions or injuries at the time of procedure and any difficulty in moving the scope through the foramen of Monro.

Results

We included 43 patients with ETV performed between June 2015 and December 2018. There were 34 male and 9 female patients. The mean age of the patients was 31.3 years.

The intraoperative complications encountered among these patients are illustrated in Table 1. The study reveals that Group C3 (injury to fornix) included all of the complications encountered during this study. No other complications were noted in any of our patients operated.

None of the patients developed postoperative memory deficit. The average preoperative MMSE score of 43 patients was 27.023. The average postoperative MMSE score was 27.79. Data were analyzed, and a statistically significant $P < 0.5$ was found thus rejecting the null hypothesis. No patients scored below 25 indicating that none developed memory impairment.

Discussion

Mixer reported the use of an endoscope to perform third ventriculostomy back in 1923.^[2] Since then there has been a significant modification in endoscopes and their usage, technological advances in endoscopic surgery and MRI functionality has improved the safety of surgical procedures in neurosurgery. Safe ETV, in children and adults both, is a fine example of such advancements.^[10]

Intraoperative complications are a common occurrence during ETV. These complications occur secondary to intraoperative maneuvers including intra-operative endoscopic manipulations, irrigation, and perforation of the third ventricle. There have been several studies demonstrating early complications of ETV. Short term (<6 months) and intermediate term (<3 years) success have been shown to be quite high, but it depends upon several

risk factors including the age of the patient, previous shunt, and the etiology of the hydrocephalus.^[3,7,10,11,12]

Kulkarni *et al.* have done extensive work on the short-term success of the ETV and calculated their results using ETV success score and has shown good outcome.^[10] Matthew *et al.* has shown a comparable result with a 61% and 47% success rate within 6 months and 3 years of follow-up, respectively.^[13]

In order to reduce the complications and increase the success rate of ETV several innovations were introduced over the time. The use of stereotactic techniques while performing third ventriculostomy was first described by Hoffman *et al.*^[14] and was modified through computed tomography by Kelly^[15,16] in the 80's. However, MRI-guided stereotactic techniques for this procedure have not been described frequently in the literature.

We noticed that the standard entry point was not giving us an ideal trajectory and thus increasing the risk of complications. The introduction of image guidance significantly alters our entry point [Figure 1] and improved outcomes. It provides a safe trajectory for the endoscope to advance through the cortex into the lateral ventricle and then navigate safely through the foramen of Monro.

The technique involves conducting an MRI on image-guided protocol and then performing the standard endoscopic surgery with the addition of image guidance. The system diverts the trajectory of the endoscope from the usual pericoronal approach to avoid the possibility of iatrogenic injury in that path. It defines a new altered trajectory for the endoscope to follow, rendering it safer and more accurate. The conventional entry point usually utilized for this surgery lies at the Kocker's point, 1 cm anterior to the coronal suture on the mid pupillary line.^[17] In our cases the image guidance altered this trajectory to a minimum of 1 cm behind the coronal suture, thus avoiding frequent complications.

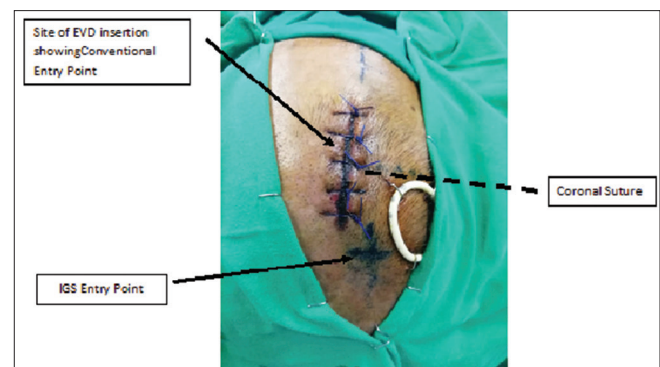


Figure 1: Image guidance significantly alters the entry point from the conventional burr hole site. Shaded line: Indicates the coronal suture. The centre of incision marks the Kocker's point where an EVD was done in this patient previously and is also the site of conventional endoscopic third ventriculostomy incision. Cross mark indicates the entry point for endoscopic third ventriculostomy defined by the image guidance system which is significantly altered in relation to Kocker's point

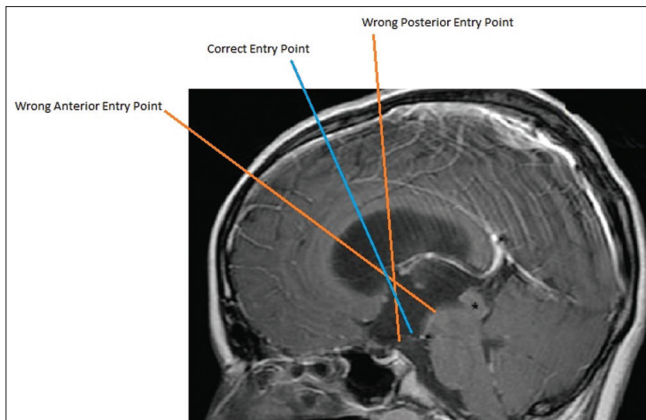


Figure 2: Too anterior entry point can cause injury to fornix and brainstem. Too posterior entry point can cause injury to fornix and motor cortex. Correct entry point is essential to avoid such complications

Wrong trajectories secondary to the conventional blind procedure can cause iatrogenic complications [Figure 2]. An anterior trajectory might cause damage to structures underlying the floor of the third ventricle. A posterior trajectory, on the other hand, might cause iatrogenic injury to the motor cortex and fornix. Similarly, a lateral entry point can cause iatrogenic injury to the fornix. Image guidance can significantly reduce the number of such complications as shown in this study.

Previously, intra-operative complications without using any stereotactic technique have been reported between 5% and 30%, and mortality has been reported up to 1%.^[18] Our study, however, reveals minimal complications occurring in the patients undergoing image-guided ETV with only 2 (4.65%) patients developing fornix contusion [Figure 3]. In one of these patients, the diameter of Foramen of Monro was narrower than the endoscope. In the second case, the burr hole was made more than 1 cm anterior to the proposed site secondary to the iatrogenic error. None of the patients developed any other neural iatrogenic injury or hemorrhagic complications. These injuries occur due to the long-learning curve as the neuroendoscopic procedure involves complicated maneuvers to be carried out.^[19] Regular usage of image guidance can help young neurosurgeons develop skills to avoid such complications and their clinical implications.

Literature reports incidents of multiple other complications intraoperatively. Hemodynamic disturbance secondary to iatrogenic injury to posterior hypothalamus which regulates cardiovascular functions has been reported most commonly.^[18] This was not seen in our patients.

Magnetic resonance image guidance to plan the trajectory of the endoscope proved to be a safe and useful technique in our study compared to other studies conducted on ETV being performed with the blind endoscopic approach [Table 1]. Oertel *et al.*^[20] have reported a 16.4% incidence of fornix contusion in patients undergoing

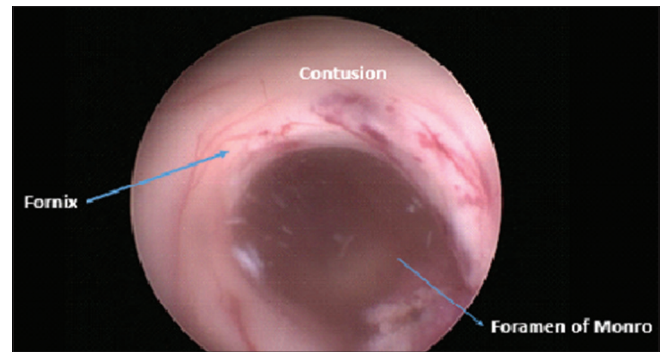


Figure 3: Endoscopic view of endoscopic third ventriculostomy showing forniceal Grade 1 contusion

ETV without image guidance compared to 4.65% in our study. They reported a 2.3% oculomotor nerve injury while no such complications were observed in our study. The navigational technique significantly alters the plan of trajectory thus creating a route with least possibility of iatrogenic injury. Martínez-Moreno *et al.* developed advanced navigational protocol for ETV and applied it on their patients. They had a fornix contusion without clinical correlation in one patient [Table 2].^[21]

The left fornix is functionally involved in the verbal memory, while the right fornix is involved in the visuospatial memory.^[22] The fornix carries fibres from both the caudal and rostral ends of the hippocampus. Both these fibres are separately distributed along the length of the fornix with caudal fibres being carried on the medial aspect and rostral fibres being more lateral. The lateral fibres are concerned with interoceptive signals that are involved with learning, emotional and motivational memory. The medial fibres are mostly involved with exteroceptive processing that relates to scene learning (recognition of objects within a spatial context.^[22] Considering these functional parameters, we assessed the patients postoperatively for neurocognitive dysfunction through MMSE. None of the patients experienced memory impairment.

Our study incites the need for further large-scale studies to be conducted to establish safety and efficacy of image guidance in ETV procedure.

Conclusion

Our study reports no major neurological complications secondary to image-guided ETV. It is thus concluded that the use of image guidance to plan the trajectory for ETV improves safety and accuracy of the procedure compared to conducting ETV without the use of image guidance system (IGS). Young neurosurgeons can benefit from this technique to overcome the learning curve and develop better surgical skills to avoid iatrogenic complications. We recommend the use of IGS for all cases of ETV, when available.

Financial support and sponsorship

Nil.

Conflicts of interest

There are no conflicts of interest.

References

- Rasul FT, Marcus HJ, Toma AK. Is endoscopic third ventriculostomy superior to shunts in patients with non-communicating hydrocephalus? A systematic review and meta-analysis of the evidence. *Acta Neurochir* 2013;155:883-9.
- Mixter W. Ventriculostomy and puncture of the floor of the third ventricle. *Boston Med Surg J* 1923;188:277-8.
- Di Vincenzo J, Keiner D, Gaab MR, Schroeder HW, Oertel JM. Endoscopic third ventriculostomy: Preoperative Considerations and intraoperative Strategy based on 300 procedures. *J Neurol Surg* 2014;75:20-30.
- Feng H, Huang G, Liao X. Endoscopic third ventriculostomy in the management of obstructive hydrocephalus: An outcome analysis. *J Neurosurg* 2004;100:626-33.
- Fritsch MJ, Kienke S, Ankermann T, Padoin M, Mehdorn HM. Endoscopic third ventriculostomy in infants. *J Neurosurg* 2005;103:50-3.
- Spennato P, Tazi S, Bekaert O. Endoscopic third ventriculostomy for idiopathic aqueductal stenosis. *World Neurosurg* 2013;79:13-20.
- Bouras T, Sgouros S. Complications of endoscopic third ventriculostomy. *World Neurosurg* 2013;79:9-12.
- Folstein MF, Folstein SE, McHugh PR. Mini-mental state. A practical method for grading the cognitive state of patients for the clinician. *J Psychiatr Res* 1975;12:189-98.
- Cinalli G. Endoscopic third ventriculostomy. In: Cinalli G, Maixner WJ, Sainte-Rose C, editors. *Pediatric Hydrocephalus*. Italia: Springer-Verlag; 2004. p. 361-88.
- Kulkarni AV, Drake JM, Kestle JR. Predicting who will benefit from endoscopic third ventriculostomy compared with shunt insertion in childhood hydrocephalus using the ETV Success Score. *J Neurosurg Pediatr* 2010;6:310-5.
- Breimer GE, Sival DA, Brusse-Keizer MG. An external validation of the ETVSS for both short-term and long-term predictive adequacy in 104 pediatric patients. *Childs Nerv Syst* 2013;29:1305-11.
- Durnford AJ, Kirkham FJ, Mathad N. Endoscopic third ventriculostomy in the treatment of childhood hydrocephalus: Validation of a success score that predicts long-term outcome. *J Neurosurg Pediatr* 2011;8:489-93.
- Matthew GS, Zakaria R, Ellenbogen JR. Long-term follow-up of endoscopic third ventriculostomy performed in the pediatric population. *J Neurosurg Pediatr* 2016;17:734-8.
- Hoffman HJ, Harwood-Nash D, Gilday DL. Percutaneous third ventriculostomy in the management of non-communicating hydrocephalus. *Neurosurgery* 1980;7:313-21.
- Kelly PJ, Goerss S, Kall BA, Kispert DB. Computer tomography based stereotactic third ventriculostomy: Technical note. *Neurosurgery* 1986;18:791-4.
- Kelly PJ. Stereotactic third ventriculostomy in patients with nontumoral adolescent/adult onset aqueductal stenosis and symptomatic hydrocephalus. *J Neurosurg* 1991;75:865-73.
- Aref M, Martyniuk A, Nath S, Koziarz A, Badhiwala J, Algird A, et al. Endoscopic third ventriculostomy: Outcome analysis of an anterior entry point. *World Neurosurg* 2017;104:554-9.
- Baykan N, Isbir O, Gerçek A, Dağnar A, Ozek M.M (2005) Ten Years of Experience with Pediatric Neuroendoscopic Third Ventriculostomy: Features and Perioperative Complications of 210 Cases. *J Neurosurg Anesthesiol* 17(1):33-7
- Schubert A, Deogaonkar A, Lotto M. Anesthesia for minimally invasive cranial and spinal surgery. *J Neurosurg Anesthesiol* 2006;18:47-56.
- Oertel J, Linsler S, Emmerich C, Keiner D, Gaab M, Schroeder H, et al. Results of combined intraventricular neuroendoscopic procedures in 130 cases with special focus on fornix contusions. *World Neurosurg* 2017;108:817-25.
- Martínez-Moreno M, Widhalm G, Mert A, Kiesel B, Bukaty A, Furtner J, et al. A novel protocol of continuous navigation guidance for endoscopic third ventriculostomy. *Neurosurgery* 2014;10:514-24.
- Raslau FD, Augustinack JC, Klein AP, Ulmer JL, Mathews VP, Mark LP. Memory part 3: The role of the fornix and clinical cases. *AJNR Am J Neuroradiol* 2015;36:1604-8.
- Bouras T, Sgouros S. Complications of endoscopic third ventriculostomy: A systematic review. In: Aygok G, Rekaté H, editors. *Hydrocephalus*. Acta Neurochirurgica Supplementum. Vol. 113. Vienna: Springer; 2012.
- Oertel JM, Mondorf Y, Schroeder HW, Gaab MR. Endoscopic diagnosis and treatment of far distal obstructive hydrocephalus. *Acta Neurochir (Wien)* 2010;152:229-40.
- Ozgural O, Gokmen K, Giuseppe C, Umit E, Ihsan D, Eyyub SM, et al. Marking basilar artery using neuronavigation during endoscopic third ventriculostomy: A clinical study. *Turk Neurosurg* 2020;30:23-9.
- Broggi G, Dones I, Ferroli P, Franzini A, Servello D, Duca S. Image guided neuroendoscopy for third ventriculostomy. *Acta Neurochir* 2000;142:893-9.