

# Can Milking-Like Effect Be the First Clue of a Ventricular Free Wall Rupture?

Ramses Ramirez Damera<sup>1</sup>, Alexander Kong<sup>1</sup>, Muhammad I. Khan<sup>1</sup>, Hiren Patel<sup>2</sup>, Amir Javaid<sup>3</sup>

Review began 02/22/2022

Review ended 03/07/2022

Published 03/10/2022

© Copyright 2022

Ramirez Damera et al. This is an open access article distributed under the terms of the Creative Commons Attribution License CC-BY 4.0., which permits unrestricted use, distribution, and reproduction in any medium, provided the original author and source are credited.

1. Internal Medicine Residency, University of Central Florida College of Medicine, Orlando, USA 2. Cardiovascular Disease, Saint Louis University School of Medicine, St. Louis, USA 3. Cardiology, University of Central Florida College of Medicine, Orlando, USA

**Corresponding author:** Ramses Ramirez Damera, ramsesramirez30@gmail.com

---

## Abstract

Ventricular free wall rupture (VFWR) is a catastrophic complication of myocardial infarction that poses an imminent surgical emergency. Early recognition is essential as it can expedite the process for a life-saving surgical intervention. We present a case of an acute left VFWR resulting from an underlying myocardial infarction which showed a “milking-like effect” during diagnostic angiography. “Milking-like effect” is an angiographic phenomenon typically seen in myocardial bridging, which occurs due to the compression of the intramyocardial coronary segments during systole. The presence of this phenomenon is believed to occur due to the extrinsic compression of the coronary by the evolving hemopericardium.

---

**Categories:** Cardiac/Thoracic/Vascular Surgery, Cardiology, Internal Medicine

**Keywords:** cardiogenic shock, cardiac tamponade, myocardial bridge, myocardial rupture, myocardial infarction complication

## Introduction

Ventricular free wall rupture (VFWR) is a known catastrophic complication of myocardial infarction [1]. It is associated with an extremely high mortality risk and poses an imminent surgical emergency with poor outcomes [2]. Risk factors associated with VFWR include the use of thrombolytic agents, female gender, and large areas of ischemia [3-6]. The underlying pathogenesis is directly related to the weakening or thinning of the architecture as a result of myocardial cell demise, which occurs regardless of whether reperfusion is achieved after the acute ischemic event [7]. Recognizing this complication in the absence of signs of cardiogenic shock remains a very difficult task for most clinicians as there are no risk stratifying tools or clinical clues to help identify those who are at a higher risk and would benefit from further assessment or monitoring. In 2016, Bastante et al. published a report of two patients who presented with ST-segment elevation myocardial infarction (STEMI) and had a “milking-like effect” during emergent angiography. Interestingly, both cases became hemodynamically unstable promptly after catheterization and were then found to have a VFWR; unfortunately, none of the patients survived this tragic complication [8]. We present the case of an acute left VFWR resulting from an underlying myocardial infarction that showed a “milking-like effect” during diagnostic angiography.

## Case Presentation

A 66-year-old gentleman was brought to the emergency department due to ongoing chest pain that had started earlier during the day. The chest pain was described as constant, non-exertional, without any worsening or relieving factors. The patient also reported having a single syncopal episode on the morning of the presentation; however, the family at bedside was unable to provide further details of the incident. His medical history was significant for severe aortic regurgitation and aortic root dilatation for which he had undergone a bovine aortic valve replacement (AVR) five years before presentation. His other chronic conditions included hypertension and benign prostatic enlargement.

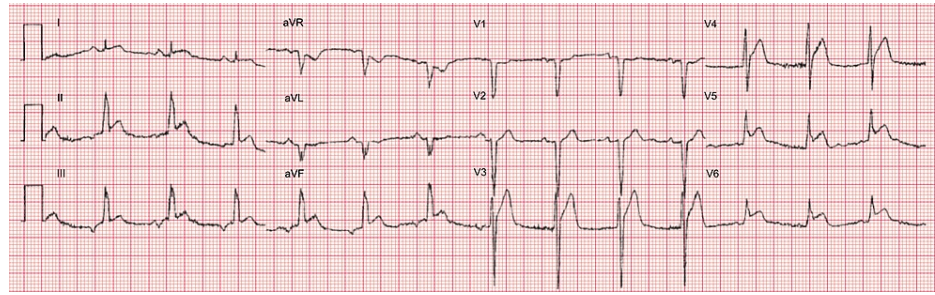
Of significance, the patient had a similar episode of chest pain two days prior and at that time he was taken to another emergency department. An electrocardiogram (ECG) done at that time was normal, according to the patient and family members, so he was sent home but instructed to return for further evaluation if the pain recurred.

Upon presentation to our facility, physical examination revealed an elderly gentleman in mild distress due to chest pain, heart sounds were diminished, but there were no added rales, gallops, or murmurs identified. The remainder of the examination was unremarkable. Initial vital signs showed a blood pressure of 86/55 mmHg, heart rate of 101 beats/minute, respiratory rate of 16 breaths/minute, and normal oxygen saturation. Initial ECG revealed a STEMI in the lateral leads (Figure 1), which led to the activation of the STEMI protocol. He also underwent a chest radiograph that revealed mild cardiomegaly, but no other acute cardiopulmonary findings. Relevant laboratory findings on arrival included a hemoglobin 10.8 g/dL, platelets 155,000/mm<sup>3</sup>, partial thromboplastin time 31.8 seconds, and international normalized ratio 1.3.

### How to cite this article

Ramirez Damera R, Kong A, Khan M I, et al. (March 10, 2022) Can Milking-Like Effect Be the First Clue of a Ventricular Free Wall Rupture?. Cureus 14(3): e23042. DOI 10.7759/cureus.23042

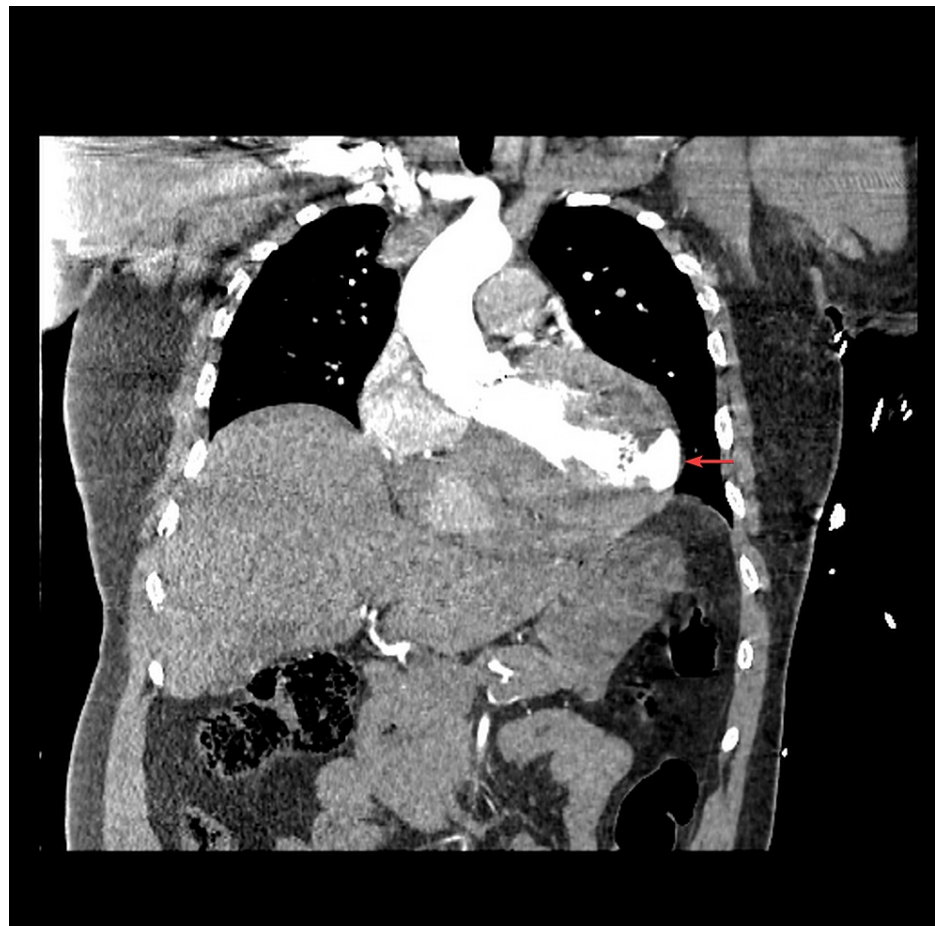Troponin I was 11.51 ng/mL, and brain natriuretic peptide was 1,464 pg/mL.



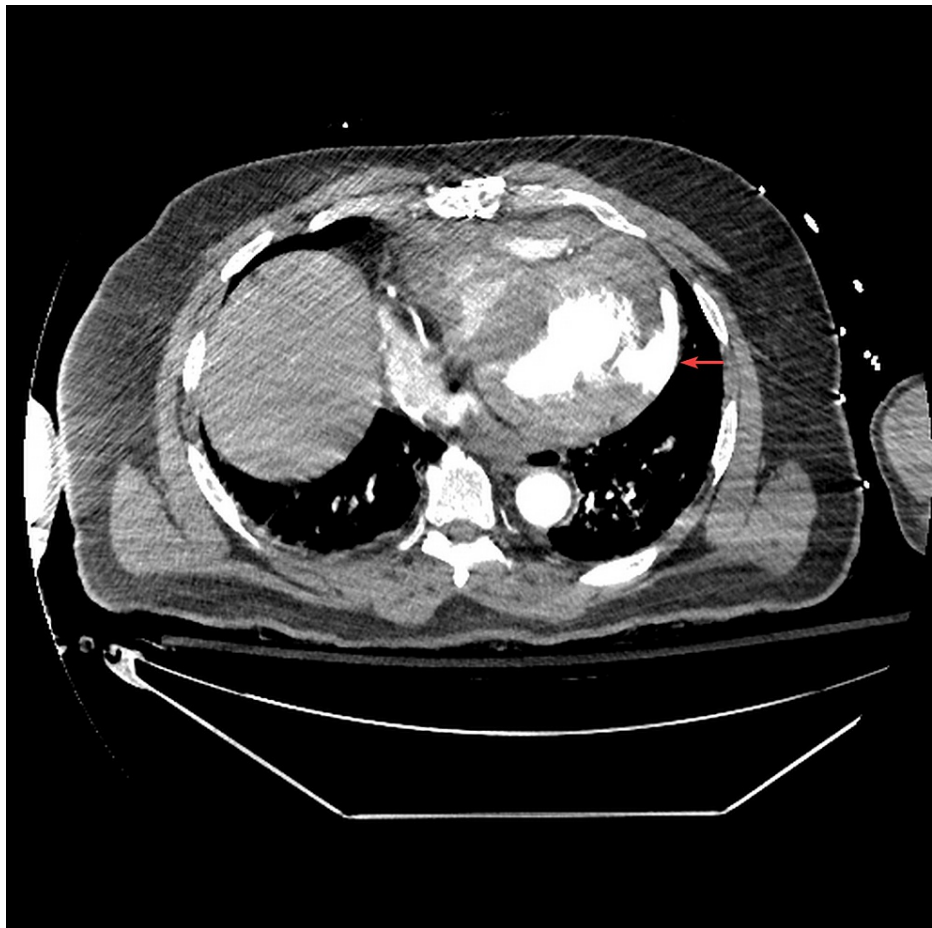**FIGURE 1: Initial electrocardiogram revealing lateral precordial lead ST-segment elevations (V4, V5, and V6) indicating lateral STEMI.**

STEMI: ST-segment elevation myocardial infarction

A computed tomography with angiography (CTA) of the chest was performed as the patient was being taken to the catheterization laboratory. This was done because aortic dissection was on the differential, given his history of AVR, and for that reason intravenous heparin was not initiated. During the cardiac catheterization, the CTA results were called in revealing a lateral free wall rupture with hemopericardium (Figures 2, 3).

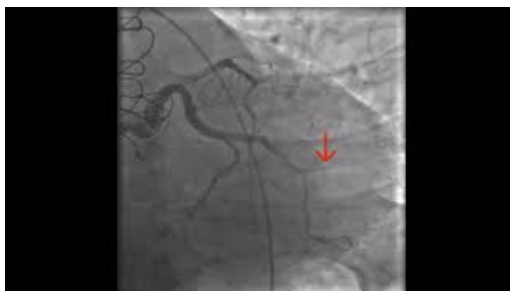

**FIGURE 2: Coronal view of computed tomography with angiography of the chest showing a ventricular free wall rupture with extravasation of contrast from the left ventricle to the pericardial space (red arrow).**



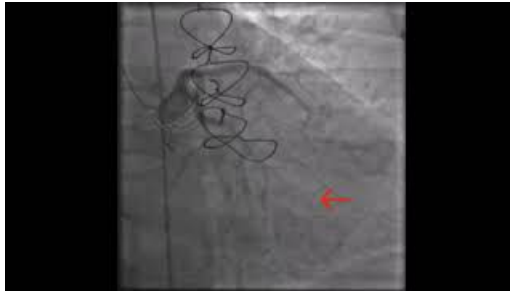**FIGURE 3: Transverse view of computed tomography with angiography of the chest showing a ventricular free wall rupture with extravasation of contrast from the left ventricle to the pericardial space (red arrow).**

It was then decided to limit the angiography to the preliminary coronary anatomy findings so far observed, and the cardiothoracic surgery team was made aware of the critical results. Interestingly, the preliminary evaluation revealed a cut-off of the second marginal, most likely secondary to left ventricular perforation, but the rest of the coronaries were not obstructed (Video 1). To our surprise, a “milking-like effect” was seen at the mid to distal portion of the left anterior descending coronary artery, with almost complete disappearance during systole (Videos 2, 3).



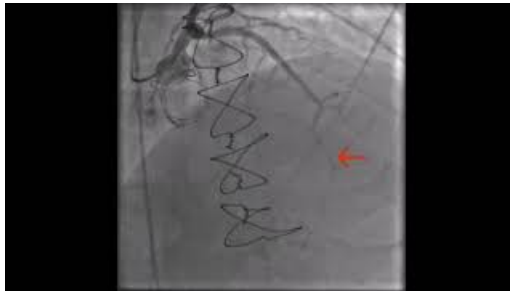**VIDEO 1: Cardiac angiography showing a cut-off of flow at the second marginal branch of the left circumflex coronary artery (red arrow), which was anatomically congruent with the area of free wall rupture.**

View video here: <https://youtu.be/5tIGbHkJiU>



**VIDEO 2: Cardiac angiography of the mid left anterior descending coronary artery revealing an intermittent filling pattern (red arrow), also known as a coronary milking-like effect.**

View video here: <https://youtu.be/anjtr91fmQI>



**VIDEO 3: Cardiac angiography of the mid left anterior descending coronary artery revealing an intermittent filling pattern (red arrow), also known as a coronary milking-like effect.**

View video here: <https://youtu.be/PZ2Zww27fKc>

Shortly after the angiography, the patient became hemodynamically unstable and subsequently went into pulseless electric activity (PEA). Cardiopulmonary resuscitation was started by the critical care team that was able to intubate the patient and achieve return to spontaneous circulation (ROSC) within 10 minutes. After achieving ROSC, the patient was emergently transported to the operating room; however, before being able to arrive there, he became hemodynamically unstable and subsequently went into PEA once again. Despite all attempts made by the critical care and surgical teams, he finally succumbed to his illness.

## Discussion

VFWR remains a difficult entity to diagnose early in its disease course as patients can present with minimal nonspecific symptoms such as chest pain or syncope or they can present in cardiogenic shock [9]. This can delay the recognition of the need for emergent surgical intervention and repair. VFWR is most commonly seen as a post-myocardial infarction complication with either acute or subacute presentation [10,11].

The “milking-like effect” is an angiographic phenomenon that is typically seen in myocardial bridging, which is a congenital disease that results in partial or total intramural coronary distribution. In this subset of patients, the “milking-like effect” occurs from the compression of the intramyocardial coronary segments during systole. This leads to an intermittent filling pattern, depending on the cardiac cycle, which is a hallmark finding of myocardial bridging [12]. “Milking-like effect” has been previously described in association with left ventricular pseudoaneurysms and true aneurysms [13-15]. This angiographic phenomenon is thought to occur because of the acquired dilation of the ventricle, leading to extrinsic compression of the coronary arteries during systole. Bastante et al. were the first to report the presence of a “milking-like effect” in the setting of VFWR and proposed that this angiographic finding could be an early clue of an evolving VFWR.

Our case was unique in that the patient had a CTA before cardiac angiography, which allowed us to recognize the VFWR before hemodynamic compromise. Moreover, despite not being a thorough angiographic evaluation, we were able to grossly assess anatomy and cardiovascular hemodynamics, which is seldom reported in these patients. We also believe that this phenomenon is the result of a temporarily sealed VFWR, with extrinsic compression of the coronary by the evolving hemopericardium.

## Conclusions

The presence of a “milking-like effect” may be an early clue of a developing VFWR. As such, when seen in association with an acute myocardial infarction, it should prompt providers to obtain further imaging as it can be a life-saving decision.

## Additional Information

### Disclosures

**Human subjects:** Consent was obtained or waived by all participants in this study. **Conflicts of interest:** In compliance with the ICMJE uniform disclosure form, all authors declare the following: **Payment/services info:** All authors have declared that no financial support was received from any organization for the submitted work. **Financial relationships:** All authors have declared that they have no financial relationships at present or within the previous three years with any organizations that might have an interest in the submitted work. **Other relationships:** All authors have declared that there are no other relationships or activities that could appear to have influenced the submitted work.

## References

1. Reeder GS: Identification and treatment of complications of myocardial infarction. *Mayo Clin Proc.* 1995, 70:880-4. [10.1016/S0025-6196\(11\)63946-3](https://doi.org/10.1016/S0025-6196(11)63946-3)
2. Pappas PJ, Cernaianu AC, Baldino WA, Cilley JH Jr, DelRossi AJ: Ventricular free-wall rupture after myocardial infarction. Treatment and outcome. *Chest.* 1991, 99:892-5. [10.1378/chest.99.4.892](https://doi.org/10.1378/chest.99.4.892)
3. Becker RC, Gore JM, Lambrew C, et al.: A composite view of cardiac rupture in the United States National Registry of Myocardial Infarction. *J Am Coll Cardiol.* 1996, 27:1321-6. [10.1016/0735-1097\(96\)00008-3](https://doi.org/10.1016/0735-1097(96)00008-3)
4. Honan MB, Harrell FE Jr, Reimer KA, Califf RM, Mark DB, Pryor DB, Hlatky MA: Cardiac rupture, mortality and the timing of thrombolytic therapy: a meta-analysis. *J Am Coll Cardiol.* 1990, 16:359-67. [10.1016/0735-1097\(90\)90586-e](https://doi.org/10.1016/0735-1097(90)90586-e)
5. Shapira I, Isakov A, Burke M, Almog C: Cardiac rupture in patients with acute myocardial infarction. *Chest.* 1987, 92:219-23. [10.1378/chest.92.2.219](https://doi.org/10.1378/chest.92.2.219)
6. Pohjola-Sintonen S, Muller JE, Stone PH, et al.: Ventricular septal and free wall rupture complicating acute myocardial infarction: experience in the Multicenter Investigation of Limitation of Infarct Size. *Am Heart J.* 1989, 117:809-18. [10.1016/0002-8703\(89\)90617-0](https://doi.org/10.1016/0002-8703(89)90617-0)
7. Heymans S, Luttun A, Nuyens D, et al.: Inhibition of plasminogen activators or matrix metalloproteinases prevents cardiac rupture but impairs therapeutic angiogenesis and causes cardiac failure. *Nat Med.* 1999, 5:1135-42. [10.1038/13459](https://doi.org/10.1038/13459)
8. Bastante T, Rivero F, Cuesta J, Aguilera MC, Rodríguez D, Benedicto A, Alfonso F: Milking-like effect as the first clue of left ventricular free wall rupture. *Can J Cardiol.* 2016, 32:1039.e3-5. [10.1016/j.cjca.2015.08.028](https://doi.org/10.1016/j.cjca.2015.08.028)
9. Lateef F, Nimbkar N: Ventricular free wall rupture after myocardial infarction. *Hong Kong J Emerg Med.* 2003, 10:258-46. [10.1177/102490790301000406](https://doi.org/10.1177/102490790301000406)
10. Das A, Biswas S, Bandyopadhyay C, Bhattacharya C, Dalal D: Sudden death due to ventricular free wall rupture following acute myocardial infarction: a rare one. *J Indian Acad Forensic Med.* 2013, 35:291-2.
11. Slater J, Brown RJ, Antonelli TA, et al.: Cardiogenic shock due to cardiac free-wall rupture or tamponade after acute myocardial infarction: a report from the SHOCK Trial Registry. Should we emergently revascularize occluded coronaries for cardiogenic shock?. *J Am Coll Cardiol.* 2000, 36:1117-22. [10.1016/s0735-1097\(00\)00845-7](https://doi.org/10.1016/s0735-1097(00)00845-7)
12. Corban MT, Hung OY, Eshtehardi P, et al.: Myocardial bridging: contemporary understanding of pathophysiology with implications for diagnostic and therapeutic strategies. *J Am Coll Cardiol.* 2014, 63:2346-55. [10.1016/j.jacc.2014.01.049](https://doi.org/10.1016/j.jacc.2014.01.049)
13. Jiménez VA, Sepúlveda J, Ponce J, Baz JA, Iñiguez A: It's just a coronary milking-like effect ... or maybe not: posterolateral artery compression caused by a ventricle pseudoaneurysm. *Eur Heart J Cardiovasc Imaging.* 2014, 15:1193. [10.1093/ehjci/jeu072](https://doi.org/10.1093/ehjci/jeu072)
14. Ferrer-Hita J, Tuesta ID, Lacalzada J, Lara A, Laynez I, Bosa F, Marrero F: Posterior descending artery milking-like effect caused by ventricle pseudoaneurysm compression. *Circulation.* 2005, 111:e453-4. [10.1161/CIRCULATIONAHA.104.495119](https://doi.org/10.1161/CIRCULATIONAHA.104.495119)
15. Moreno R, Perez del Todo J, Macaya C: Milking-like effect secondary to systolic expansion of a post-infarction left ventricular aneurysm. *J Invasive Cardiol.* 2003, 15:608-9.