

Case report

Open Access

Nephropathic cystinosis associated with cardiomyopathy: A 27-year clinical follow-up

Mehul P Dixit*¹ and Ira Greifer²

Address: ¹Division of Nephrology, Department of Pediatrics, University of Arizona, Tucson, USA and ²Division of Nephrology, Department of Pediatrics, Albert Einstein College of Medicine, Bronx, USA

E-mail: Mehul P Dixit* - mdixit@peds.arizona.edu; Ira Greifer - iraipna@aol.com

*Corresponding author

Published: 9 November 2002

Received: 11 July 2002

BMC Nephrology 2002, 3:8

Accepted: 9 November 2002

This article is available from: <http://www.biomedcentral.com/1471-2369/3/8>

© 2002 Dixit and Greifer; licensee BioMed Central Ltd. This is an Open Access article: verbatim copying and redistribution of this article are permitted in all media for any purpose, provided this notice is preserved along with the article's original URL.

Keywords: Nephropathic cystinosis, Renal transplant, Cardiomyopathy, Pseudoaneurysm, Long term survivor

Abstract

Background: Nephropathic cystinosis is an autosomal recessive disease resulting from intracellular accumulation of cystine leading to multiple organ failure.

Case report: We describe the clinical course of a patient managed from the age of six until his death at the age of 33 years. He underwent multiple surgery, including two renal transplants, developed transplant renal artery stenosis that was managed medically, and progressive heart failure at the age of 33 years. His death from a ruptured pseudoaneurysm associated with a restrictive cardiomyopathy is noteworthy. A limited cardiac autopsy revealed the presence of cystine crystals in interstitial cardiac histiocytes and one myocardial cell, along with 1000-fold higher tissue cystine content of the left ventricular myocardium compared to patients without cystinosis, suggesting the possibility of direct cystine mediated metabolic injury.

Background

Nephropathic cystinosis is an autosomal recessive disorder characterized clinically by generalized proximal renal tubular dysfunction, progressive renal damage after intracellular accumulation of cystine [1,2]. The result is the buildup of cystine in various organs and eventual multiple organ failure. In the kidney, it leads to progressive renal damage, resulting in end-stage renal disease (ESRD) by 10 years of age on average [1,2]. The drug cysteamine reduces intracellular concentrations of cystine and can retard progression of renal damage if started early [1,2]. Renal transplantation is a viable option and the graft survival is excellent [3]. The gene for cystinosis which has been cloned and identified as *CTNS*, maps to chromo-

some 17p13 [4]. In the European population, mutations of *CTNS* include a 65-kb deletion-involving marker D17S829 and 11 other small mutations [4]. Other *CTNS* mutations have been confirmed in American-based populations of cystinosis patients [5]. We describe the clinical course of a nephropathic form of cystinosis diagnosed at the age of five years and managed at Albert Einstein College of Medicine from the age of six for the next 27 years. His survival despite multiple complications, and his death at 33 years of age due to a ruptured pseudoaneurysm associated with cardiomyopathy, is noteworthy.

Case report

A one-year old white male child was found to have rickets and was treated with oral vitamin D. He was noted to be growth retarded, and to have albuminuria and aminoaciduria. He received 50,000 units of vitamin D daily, off and on until the age of five. He was then seen at another institution where he underwent renal and bone marrow biopsies. The biopsies revealed cystine deposits; ophthalmological examination confirmed the diagnosis of cystinosis. He was then referred to Albert Einstein College of Medicine for further management. At the age of six years, the patient had growth retardation, renal osteodystrophy, albuminuria, glucosuria and chronic renal insufficiency. A creatinine clearance measured later revealed 20% GFR. He was managed conservatively until he reached ESRD, at the age of 11 years. Four months after initiation of hemodialysis, he developed a persistent fever with fatigue and orthopnea. Physical exam revealed a blood pressure (BP) of 137/101 mm of Hg, an enlarged liver, distended neck veins and pericardial rub. The EKG revealed right atrial and left ventricular enlargement. A clinical diagnosis of uremic pericarditis was made and aggressive dialysis was initiated. The patient responded to aggressive dialysis and hydralazine, guanethidione and methyldopa, for BP control. Subsequently, he developed other complications of cystinosis, namely hypothyroidism, hypersplenism and corneal deposition of cystine with diffuse pigmented mottling of the entire eye and fundus. A splenectomy was performed at the age of 11 years. The spleen weighed 310 grams and was laden with cystine deposits. At that time his medications included antihypertensives, digoxin, bicarbonate, testosterone, L-thyroxine, calcium and vitamin D.

At the age of 12 years, he received a cadaveric renal transplant. He had mild reversible rejection in the first year but maintained normal renal function on azathioprine and prednisone. Four years later, he developed chronic rejection eventually needing dialysis two years later. An arterio-venous (AV) fistula was created on his right arm. His BP remained persistently above 170/110 mm of Hg. Nephrectomies of transplant and native kidneys along with propranolol, minoxidil, hydralazine, and methyldopa were needed to control his BP. At the age of 18 years he received his second cadaveric renal transplant. Four months later, due to persistent uncontrolled hypertension and elevated serum renin (>500 ng/dl/hr), he underwent a transplant arteriogram. It revealed a significant narrowing of the transplant renal artery, one inch distal to the anastomosis, and a slight post-stenotic dilatation. It was decided to medically control hypertension with hydrochlorothiazide, minoxidil, and propranolol. At that time he had a complete slip of both femoral epiphyses and his bones showed signs of chronic renal osteodystrophy.

With rehabilitation using crutches and surgical correction of his genu valgum he was able to ambulate.

For the ensuing 12 years he had a relatively unremarkable course. He had stable renal function with a serum creatinine of 0.8 mg/dl and satisfactory BP control. Annual echocardiograms revealed mild atrial enlargements, mild pulmonic insufficiency and left ventricular hypertrophy with normal systolic function with an ejection fraction (EF) of 68%. His medications included hydrochlorothiazide, propranolol, minoxidil, L-thyroxine, azathioprine and prednisone. His vision refracted to 20/20 in each eye with a correction for mixed astigmatism. He used artificial tears when needed. At the age of 30 he began reporting increasing fatigue, exercise intolerance, and generalized edema. Physical examination confirmed heart failure and furosemide and digitalis were needed for a short period to stabilize his condition. Repair of a large AV fistula did not alter his symptoms. He was readmitted with crampy, persistent abdominal pain. An ultrasound revealed a pseudoaneurysm at the site of the transplant renal artery anastomosis. Gallstones were also noted. After extensive consultations, he was considered a high operative risk and a decision was made to manage him conservatively.

At the age of 33 years he again presented with extreme fatigue and edema. A chest x-ray demonstrated cardiomegaly and bilateral pleural effusions. An echocardiogram showed biventricular hypertrophy with normal left ventricular EF (72%), bilateral atrial enlargement and a dilated aortic root. He was treated with diuretic therapy and digitalis but with limited response. He was subsequently admitted to the hospital in a dehydrated state following a short viral illness. He developed sudden hypotension and worsening of abdominal pain. A CT scan of the abdomen revealed a ruptured abdominal aneurysm. Surgical intervention was attempted, but the patient died on the operating table due to massive blood loss.

Post-mortem examination

A restricted post-mortem examination, limited by the family to cardiac biopsy, was performed within 10 hours of death. At the biopsy site 4 cm above the apex, the anterior left ventricular wall measured 2.5 cm in thickness. The left ventricular myocardium showed prominent myocyte hypertrophy with interstitial and perivascular fibrosis. Electron microscopy revealed rectangular intralysosomal crystals characteristic of cystine within interstitial histiocytes lying adjacent to myocytes (fig. 1). A single myocyte containing crystalline inclusions suggestive of cystine was identified (fig 2). Tissue cystine content was measured using a cystine binding protein assay [6]. The cystine content of the left ventricular myocardium was 18.5 nmol half cystine per mg of wet tissue as compared to myocardium from five control autopsy patients without cystinosis in

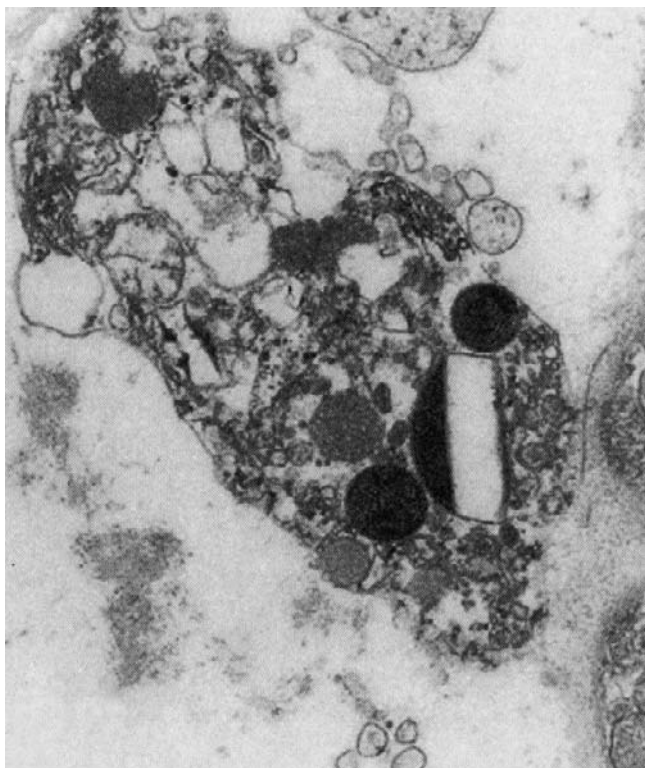


Figure 1
Electron microscopy picture of the myocardium with the interstitium showing cystine rectangular crystal ($\times 15,000$).

whom it was 0.09–0.081 nmol half cystine per mg of wet tissue. Thus, the tissue cystine level was 1000-fold higher than normal.

Discussion

Cystinosis is an autosomal recessive disorder characterized by excessive storage of cystine in several organs, including kidney, spleen, liver, lymph node, cornea and thyroid gland [1,2]. Individuals typically present in the first year of the life with symptoms of severe fluid and electrolyte disturbance, a renal Fanconi syndrome, growth failure, and photophobia. Without specific treatment, they progress to end-stage renal failure (ESRD) by end of the first decade. A rare 'late-onset' form of cystinosis presents in older children with renal impairment but not necessarily a Fanconi syndrome. Adults with 'benign' cystinosis have asymptomatic corneal cystine deposition but do not have progressive renal damage [1,2,7,8]. The diagnosis of nephropathic cystinosis can be confirmed by slit lamp examination of the cornea which reveals needle shaped, tinsel-like refractive opacities. The levels of cystine can be measured in bone-marrow cells, leukocytes, and cells of the rectal mucosa [1,2,7,8]. Renal involvement is characterized by cystine depositions in the interstitium as well as glomerular and tubular epithelium.

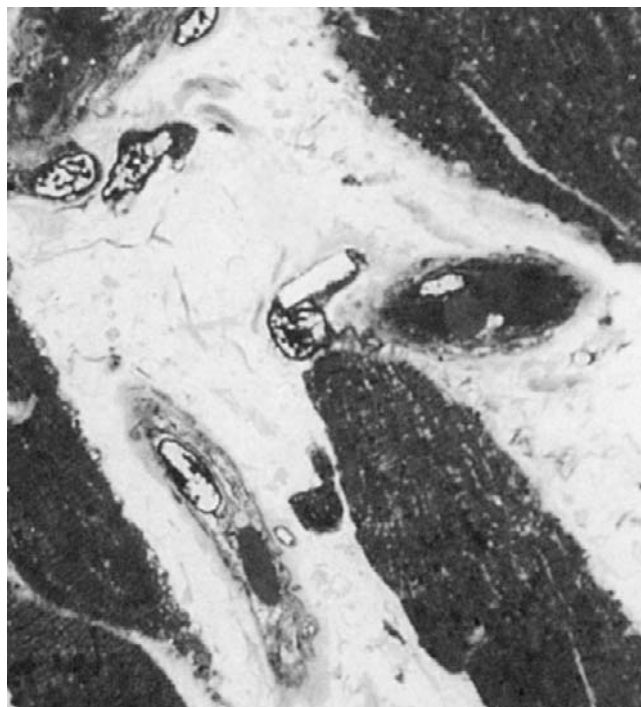

Figure 2
Myocardium with the interstitial histiocytes with rectangular cystine crystal.

With disease progression there is tubular atrophy, interstitial fibrosis, glomerulosclerosis and eventual obsolescence of the glomeruli. Though hypertension is relatively uncommon in these patients. When patients reach ESRD, dialysis or transplantation are reasonable options. Graft survival in these patients is similar to that observed in ESRD of other etiologies [3]. However, cystine continues to accumulate in other organs, leading to multisystem disease. Oral cysteamine can retard progression of renal damage if started early in the course of the disease and if given for prolonged periods [2,9]. Oral cysteamine must be continued even after transplant to prevent ongoing accumulation of cystine [2,9]. By the time oral cysteamine became routinely available the patient had significant progression and therefore was not treated.

Development of aneurysm or pseudoaneurysm of a major vessel in patients with nephropathic cystinosis is quite rare. In fact, there is only one other report of a dissecting aortic aneurysm in a 7-year old boy in whom cystine crystals were absent from the aortic wall [10]. As the histopathological examination of pseudoaneurysm was not carried out the exact etiology remains unknown. Cardiomyopathy associated with cystinosis was also not reported prior to the patient described here. In the literature there are two other reports of myocardial cystine deposition in patients with cystinosis [11,12]. The first report was of a

22-year old male with cystinosis and myopathy [11] who had a myocardial cystine level of 8.7 nmol half cystine per mg of wet tissue (as compared to 18.5 nmol half cystine per mg of wet tissue patient described here). The other patient was a 43 year old woman with a late-onset cystinosis in whom cystine crystals were observed in the myocardium at autopsy [12]. Neither of the two patients had cardiomyopathies. The myocardial cystine load in those two patients may not have been as heavy as in patient described here. It is possible that if the patient described by us had received cysteamine from a very early age, it could have reduced the cystine content in the myocardium. In another series of 13 post-renal-transplant cystinosis patients with distal vacuolar myopathy the cardiac ejection fractions and the wall motions were within normal limits and none of the patients had evidence of cardiac dysfunction [13]. The skeletal muscle cystine levels measured in those patients were similar to myocardial cystine level in the patient described here [13].

The pericarditis at the age of 11 years was attributed to insufficient dialysis and the response to more aggressive dialysis was considered as a satisfactory confirmation of the diagnosis. As the patient was ambulatory and had no further symptoms of heart failure for years after that episode, its role in the development of a restrictive cardiomyopathy twenty years later is unlikely. Annual echocardiograms and periodic cardiac evaluation allowed a fair evaluation of the cardiac status. The severe concentric left ventricular hypertrophy was out of proportion to the degree of hypertension of a long standing duration. Evidence of diastolic dysfunction manifested by pulmonary congestion and bilateral pleural effusions, with a normal left ventricular ejection fraction, point towards a restrictive cardiomyopathy. This could have been the consequence of long standing hypertension, uremia, a large AV fistula, and altered calcium-phosphorous metabolism due to renal osteodystrophy. However, the presence of cystine crystals in interstitial cardiac histiocytes and one myocardial cell, along with 1000-fold higher tissue cystine content of the left ventricular myocardium point towards the possibility of direct cystine mediated metabolic injury. Notably, his symptoms did not resolve after aggressive medical control of BP, surgical closure of the fistula and digitalis/diuretic therapy. The stress of profuse internal bleeding from the rupture of the pseudoaneurysm in conjunction with a weakened cardiac status, resulted in his death. As the patient described here never received cysteamine, the role of this drug in prevention of cardiomyopathy associated with cystinosis remains to be evaluated.

In summary, we describe the clinical course of a nephropathic cystinosis patient managed from the age of six until his death at the age of 33 years. His long-term survival, as-

sociated cardiomyopathy and death due to ruptured pseudoaneurysm are noteworthy.

Acknowledgements

We are grateful to Dr. W. A. Gahl and staff, including Isa Bernardini at the National Institute of Health for performing cystine tissue determinations.

References

- Schneider JA, Clark KF, Greene AA, Reisch JS, Markello TC, Gahl WA, Thoene JG, Noonan PK, Berry KA: **Recent advances in the treatment of cystinosis.** *J Inher Metab Dis* 1995, **18**:387-97
- Gahl WA, Thoene JG, Schneider JA: **Cystinosis.** *N Engl J Med* 2002, **347**:1111-21
- Kashtan CE, McEnery PT, Tejani A, Stablein DM: **Renal allograft survival according to primary diagnosis: a report of the North American Pediatric Renal Transplant Cooperative Study.** *Pediatr Nephrol* 1995, **9**:679-84
- Town M, Jean G, Cherqui S, Attard M, Forestier L, Whitmore SA, Callen DF, Gribouval O, Broyer M, Bates GP, et al: **A novel gene encoding an integral membrane protein is mutated in nephropathic cystinosis.** *Nat Genet* 1998, **18**:319-24
- Kleta R, Anikster Y, Lucero C, Shotelersuk V, Huizing M, Bernardini I, Park M, Thoene J, Schneider J, Gahl WA: **CTNS mutations in African American patients with cystinosis.** *Mol Genet Metab* 2001, **74**:332-7
- Oshima RG, Willis RC, Furlong CE, Schneider JA: **Binding assays for amino acids. The utilization of a cystine binding protein from Escherichia coli for the determination of acid-soluble cystine in small physiological samples.** *J Biol Chem* 1974, **249**:6033-9
- Gahl WA, Schneider JA, Schulman JD, Thoene JG, Reed GF: **Predicted reciprocal serum creatinine at age 10 years as a measure of renal function in children with nephropathic cystinosis treated with oral cysteamine.** *Pediatr Nephrol* 1990, **4**:129-35
- McDowell GA, Town MM, van't Hoff W, Gahl WA: **Clinical and molecular aspects of nephropathic cystinosis.** *J Mol Med* 1998, **76**:295-302
- Schneider JA: **Approval of cysteamine for patients with cystinosis.** *Pediatr Nephrol* 1995, **9**:254
- Strayer DS: **Cystinosis and dissecting aortic aneurysm in a 7-year-old boy.** *Am J Dis Child* 1979, **133**:436-8
- Gahl WA, Dalakas MC, Charnas L, Chen KT, Pezeshkpour GH, Kuwabara T, Davis SL, Chesney RW, Fink J, Hutchison HT: **Myopathy and cystine storage in muscles in a patient with nephropathic cystinosis.** *N Engl J Med* 1988, **319**:1461-4
- Kir'ianov NA, Bazhenov EL, Stetsenko EV: **[Cystinosis in an adult].** *Arkh Patol* 1992, **54**:34-6
- Charnas LR, Luciano CA, Dalakas M, Gilliatt RW, Bernardini I, Ishak K, Cwik VA, Fraker D, Brushart TA, Gahl WA: **Distal vacuolar myopathy in nephropathic cystinosis.** *Ann Neurol* 1994, **35**:181-8

Pre-publication history

The pre-publication history for this paper can be accessed here:

<http://www.biomedcentral.com/1471-2369/3/8/prepub>