

Arthroscopic Latarjet: Technique Description and Preliminary Results. Study of the First 30 Cases*

Latarjet artroscópico: Descrição de técnica cirúrgica e resultados preliminares. Estudo de 30 primeiros casos

Wagner Castropil¹ Breno Schor¹ Alexandre Bitar¹ Giovanna Medina¹ Luiz Henrique Ribas¹ Carlos Mendes¹

¹Department of Orthopedics, Instituto Vita, São Paulo, SP, Brazil

Rev Bras Ortop 2020;55(2):208–214.

Address for correspondence Wagner Castropil, MD, PhD, Instituto Vita, Rua Mato Grosso, 306, 1° andar, Higienópolis, São Paulo, SP, 01239-040, Brasil (e-mail: castropil@institutovita.com.br).

Abstract

Objective Arthroscopic Latarjet has been performed with the aim to be an accurate technique with a low incidence of complications. The aim of the present study was to briefly describe the technique and to evaluate the short-term complications following arthroscopic Latarjet procedure to correct anterior shoulder dislocation with glenoid bone loss.

Methods Retrospective study with 30 subjects with anterior shoulder instability, submitted to arthroscopic Latarjet. Intraoperative and short-term postoperative complications were recorded, as well as the rate of revision surgery.

Results Five cases had complication (16.7%), and in the last 10 cases no complication occurred. In 1 case (3.3%), it was required to reverse for open surgery due to a fracture of the coracoid process during fixation in the glenoid. No other intraoperative complication occurred. No infection was observed. Two cases (6.7%) evolved with temporary neuropraxia of the musculocutaneous nerve, totally reversed with physiotherapy. With a follow-up from 6 to 26 months, 2 patients (6.7%) required a new intervention for graft/screws removal and release of the joint due to excessive limitation in external rotation. There was no case of recurrence.

Conclusion Even in an initial learning curve, arthroscopic Latarjet demonstrated a low rate of short-term complications and was a safe procedure for treating anterior dislocation of the shoulder with glenoid bone loss.

Keywords

- ▶ shoulder
- ▶ shoulder instability
- ▶ arthroscopy
- ▶ minimally invasive surgical procedures

Resumo

Objetivo A realização da cirurgia de Latarjet por via artroscópica tem sido possível pelo desenvolvimento de instrumentais adequados e um protocolo para cirurgia estabelecido e reprodutível, que promete uma técnica mais precisa e com menor incidência de complicações. O objetivo do presente estudo foi fazer uma breve descrição de técnica cirúrgica e avaliar as complicações de curto prazo após a cirurgia

* The present study was conducted at Instituto Vita, São Paulo, SP, Brazil.

de Latarjet por via artroscópica para correção de luxação anterior do ombro com perda óssea glenoidal.

Método Estudo retrospectivo com 30 pacientes com instabilidade anterior do ombro, operados com a técnica de Latarjet por via artroscópica. Foram feitas avaliação das complicações intraoperatórias e pós-operatório de curto prazo e documentação de necessidade de reintervenções.

Resultados Cinco casos tiveram complicação (16,7%), sendo que nos últimos 10 casos nenhuma complicação foi observada. Em 1 caso (3,3%) foi necessária conversão para cirurgia aberta por fratura do processo coracoide no momento de fixação na glenoide. Nenhum outro caso apresentou complicação intraoperatória. Não houve infecção nos casos operados. Dois casos (6,7%) evoluíram com neuropraxia temporária do musculocutâneo, revertida com fisioterapia. Em tempo de seguimento de 6 a 26 meses, 2 pacientes (6,7%) necessitaram de nova intervenção para retirada do material de síntese e liberação articular por excessiva limitação da rotação externa. Não houve caso de recidiva.

Conclusão O procedimento de Latarjet artroscópico se mostrou seguro e com baixa incidência de complicações de curto prazo para correção da luxação anterior no ombro com perda óssea na glenoide mesmo em curva inicial de aprendizagem.

Palavras-chave

- ▶ ombro
- ▶ luxação do ombro
- ▶ artroscopia
- ▶ procedimentos cirúrgicos minimamente invasivos

Introduction

Anterior instability is the most common of shoulder instabilities, being a frequent and potentially disabling injury. The type of treatment in primary (acute) situations and the choice of the surgical technique are controversial, but the understanding that bone defects in the anterior border of the glenoid are the main cause of recurrent instability give rise to procedures for bone reconstruction.¹

The evolution of the treatment of these conditions begins with Bankart,² who described in 1923 the essential lesion in anterior shoulder instability and its repair with sutures of the lip and inferior glenohumeral ligament at the anterior border of the glenoid. In 1954, Latarjet³ described the technique for treating anterior shoulder dislocation by transferring the coracoid process to the anterior edge of the glenoid and fixing it with screws (► **Figure 1**). Later, in 1958, Helfet⁴ describes a similar procedure, but the tip of the coracoid process was sutured to soft tissues close to the anterior edge of the glenoid. He calls this procedure Bristow technique in honor of his teacher. With the popularization of

the method, it came to be called the Bristow-Latarjet technique. Among us, Ferreira Filho⁵ played a key role in the standardization and dissemination of this technique.

The Bristow-Latarjet surgery enables two types of shoulder stabilization effects⁶: static, by the previous graft increasing the glenoid surface, and the dynamic ("sling"), by the action of the conjoint tendon and also by preventing the rising of the inferior 1/3 of the subscapularis tendon.⁷ The technique, although very effective in stabilizing the joint, has a significant potential for complications: neuropraxias of the musculocutaneous and axillary nerves, graft-related and synthesis material problems, and limitation of external rotation leading to arthrosis, are some of the complications patients may face.⁸

With the development of arthroscopic instruments, the same Bankart repair and capsuloplasty could be done through less invasive surgery. Arthroscopic stabilization offered numerous advantages over open stabilization: a 360° view of the joint, fewer complications related to the opening of the subscapularis, less blood loss, reduced use of medications postoperatively, and faster rehabilitation, maintenance of range of motion and aesthetics.⁸ However, the initial medium- and long-term

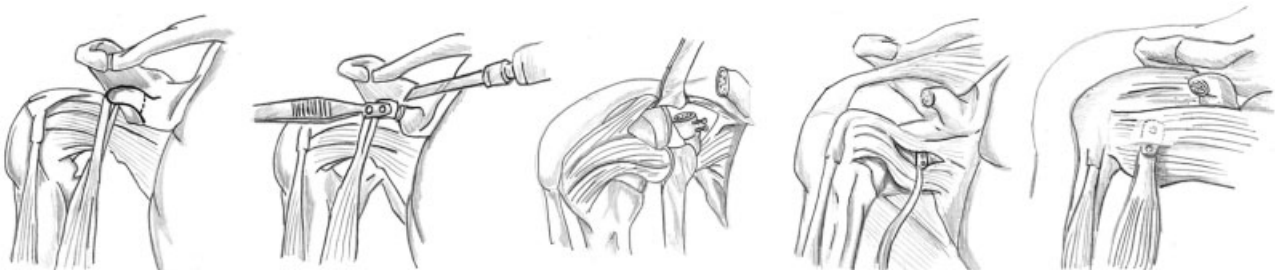

Fig. 1 Latarjet procedure illustration. Path and subsequent osteotomy of the coracoid process, alignment and subsequent passage of the two screws, and final positioning at the anterior edge of the glenoid.

results showed a high relapse rate, ~ between 15 and 20%. With the development of instrumental and anchors, this rate came to resemble the open surgery rate, being a surgeon's choice to perform this procedure by open or arthroscopic approach.⁹

In 2007, the execution of the Latarjet technique by the arthroscopic approach was described¹⁰ for bone failure, ligament insufficiency, humeral avulsion of the glenohumeral nerve (HAGL)-type injury or Bankart repair failure. In 2010, results from 41 cases with no neurological complications or relapses were published, and in 2014 a study showed low recurrence rates in 62 patients with a 5-year follow-up.^{11,12} From then on, reports began to be published with groups around the world, showing the North American,¹³ the Chinese,¹⁴ the Italian¹⁵ and the German experience,¹⁶ reproducing the technique safely, which was the theme of a recent editorial of the Arthroscopy magazine in late 2017.¹⁷

The present study aimed to evaluate the short-term results and early complications of surgery for correction of anterior shoulder dislocation, with glenoid bone loss, by arthroscopic Latarjet technique in an initial single center experience.

Materials and Methods

This is a retrospective case series study, conducted in a single center. The participants analyzed in the present study performed the surgical procedure in question between 2015 and 2017 and were followed-up for at least 6 months after the procedure. This study was approved by the Human Research Ethics Committee, under the CAEE number 88372518.2.0000.5485.

Patients that met the following criteria were included in the present study: with bone defects in the anterior glenoid border > 20% or "engaging" Hill-Sachs lesion (assessed by magnetic resonance imaging (MRI) or computed tomography (CT)) and Instability Severity Index Score (ISIS)¹⁸ greater than six > 6 or Bankart repair failure cases; cases submitted to arthroscopic Latarjet surgery; minimum 6 months of follow-up. Patients with rotator cuff injury or fractures of the humerus proximal third were not included. In total, 30 patients were included.

In the present study, complications related to the procedure were evaluated. In addition, the early complications of the procedure were collected, as well as the need for a new surgical intervention. Data were collected from medical records. There was no sample calculation because it was a single noncomparative group study.

The information that was collected according to the described outcomes was presented through descriptive statistics to describe and summarize the data set.

Surgical technique

The patients were operated in the beach chair position, with a slight inclination of the head to the contralateral side, and positioning of the fields to allow more medial chest exposure. Positioning of the posterior portal, in line with the joint, is fundamental for the proper positioning of the M portal and the correct angle for graft fixation in the glenoid. The portals used were those described by Lafosse and are illustrated in ► **Figure 2**.

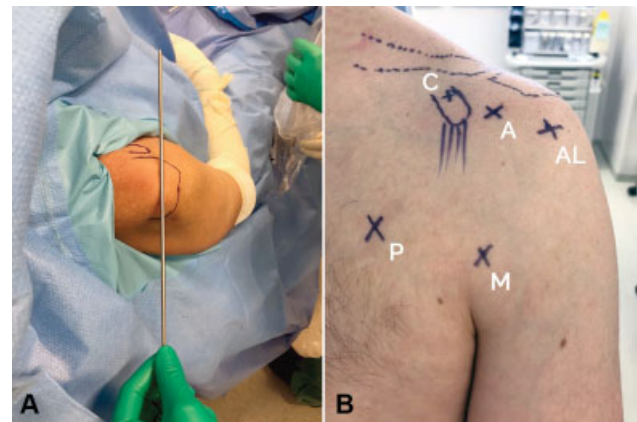


Fig. 2 Arthroscopic portals for arthroscopic Latarjet. Figure A. Positioning of the posterior portal (in line with the joint). Figure B. Portals shown clockwise in image: (M) midsub; (P) pectoral; (C) coracoid; (A) anterior; (AL) anterolateral.

The surgery can be described in the following stages:

1. Bankart lesion identification and opening of the rotator space (visualization: posterior portal; working portal: anterior)

The surgery begins with the posterior portal, and it is important that the portal must be positioned in line with the joint. We performed Bankart lesion identification (► **Figure 3**), the debridement of the anterior glenoid border and the opening of the rotator gap until the lateral edge of the coracoid process is visualized.

2. Preparation of the anterior glenoid border, joint tendon dissection and conduction of midsub and pectoral portals (visualization: anterolateral portal; work portal: anterior)

In this step, we occupy the anterior space of the shoulder. Using the anterolateral portal, we prepared the anterior border of the glenoid (► **Figure 4**), clearing the entire residual lip, and we can see the gap between the conjoint tendon and the deltoid, as well as between the conjoint tendon and the subscapularis. In this step, we identify the axillary and musculocutaneous nerves and release the lateral adhesions of the conjoint tendon.

The next step was to perform the midsub portal, which is made 1.0 cm above the axillary fold and in line with the

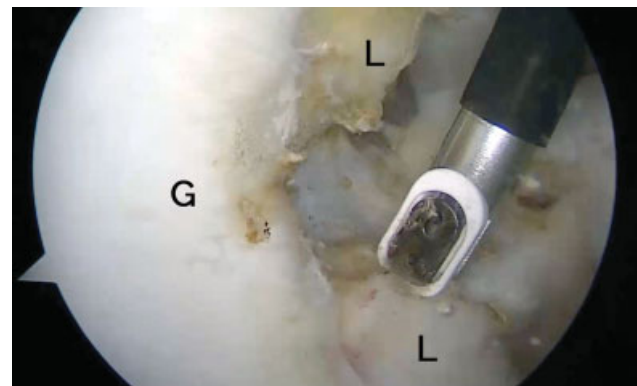


Fig. 3 Labral lesion identification with visualization through the posterior portal (L) using the posterior portal. (G) Glenoid. (L) Labrum.

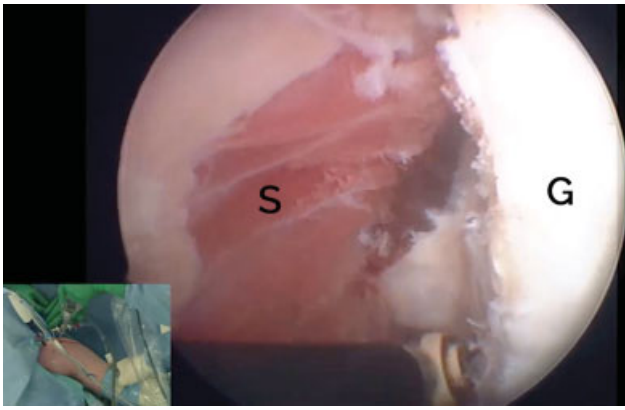


Fig. 4 Visualization of anterior glenoid edge (G) through the anterolateral portal.

coracoid process. Through this portal, we can properly visualize the coracoid process from its lateral portion to its medial portion, as well as the tendon of the subscapularis muscle in all its craniocaudal extension.

In this step, we also perform, from the inside out, the pectoral or “suicidal” portal through which will be made the subscapularis split and the graft passage with fixation on the anterior border of the glenoid.

This step is of fundamental importance for the proper fixation of the graft on the anterior glenoid border, since placement of the same in a too lateral position will result in a lateral position of the graft, and consequent impact on the humeral head.

3. Skeletization and Preparation of the Coracoid Process (visualization: portal midsub; work portals: pectoral and coracoid)

Correct visualization of the coracoid process (→ **Figure 5**) is fundamental to the process of skeletization, releasing it from its ligament and muscle insertions.

Loosening the tendon of the pectoralis minor muscle is a delicate step that must be done carefully, as the musculocutaneous nerve is immediately posterior to it. Complete release of the conjoint tendon from its adhesions and vinculas is important for its proper mobilization and transfer in the next stage.

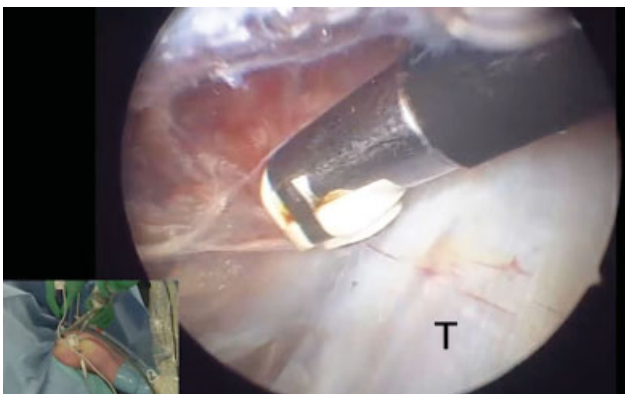


Fig. 5 Visualization of the coracoid process through the midsub portal and medial and lateral skeletization. (T) Conjoint tendon.

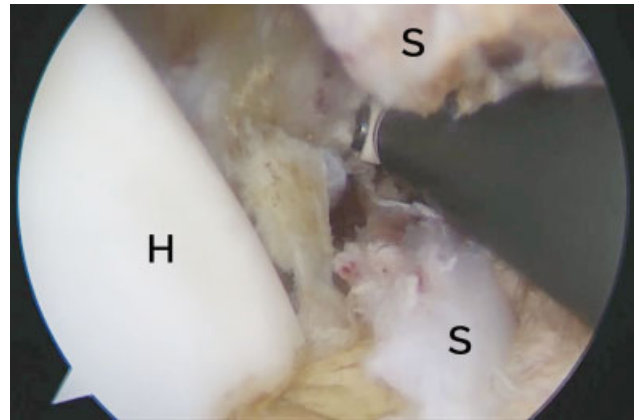


Fig. 6 Subscapular tendon split (S) with midsub portal view. (H) Humeral head.

After the skeletization of the coracoid process, holes were drilled in the coracoid process using alpha and beta guide (DePuy Synthes, Warsaw, IN, USA) and two sliding top hats (DePuy Synthes, Warsaw, IN, USA) were placed. These implants allow the screws to slide with compression of the coracoid process against the anterior glenoid border. After skeletization and preparation, the coracoid process is osteotomized at its base with the use of an osteotome.

4. Subscapular split (view: portal midsub; working portal: pectoral)

The next step was the split of the subscapularis muscle (→ **Figure 6**) to be done between the upper 2/3 and the lower 1/3, with the identification of the axillary nerve and its protection.

5. Coracoid Process Transfer and Fixation (visualization: midsub, anterolateral and posterior portals; working portal: pectoral)

With the use of two cannulated tubular guides (→ **Figure 7**) crossing a double cannula, the coracoid process is fixed and thus can be mobilized as a joystick. With the stabilized coracoid process, we can transfer it through the subscapular split. Since the guides are cannulated, once

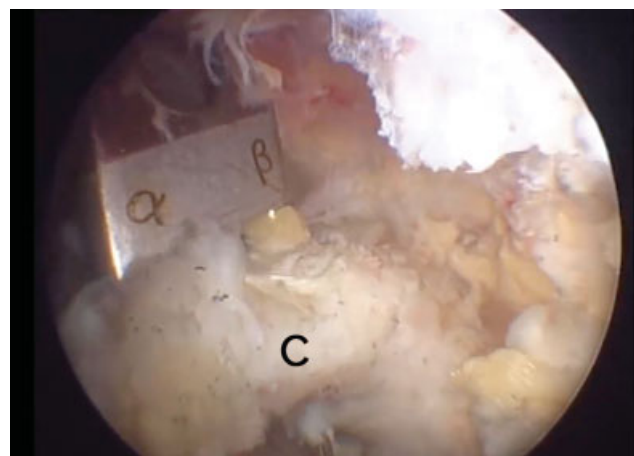


Fig. 7 Coracoid preparation (C) with midsub portal visualization. (α β) Alpha and beta guides.

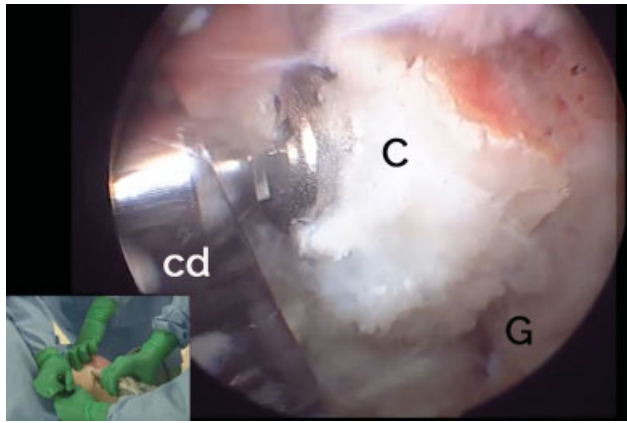


Fig. 8 Coracoid fixation (C) on anterior glenoid edge (G) with screws passed through double cannula (DC) through work through the pectoral portal.

the proper position is found, the graft is fixed to the anterior edge of the glenoid with two Kirschner wires.

This step is still performed without a proper positioning guide on the anterior edge of the glenoid. Some parameters must be obeyed, such as the parallelism between the wires passed through the graft, and the position of the graft in the anterior border of the glenoid, which should be below the equator line, aligned with the articular surface, avoiding too medial or too lateral positioned grafts.

Once found the correct positioning of the graft in the anterior glenoid edge, the cannulated guides are removed, the drilling and passage of screws can be carried out (→ **Figure 8**). As the drill has a length measurement, we can measure the size of the screws to be used as soon as it crosses the posterior cortex of the glenoid. In our experience, the size of these screws varies between 32 and 36 mm, depending on patient size and glenoid placement.

Our postoperative protocol includes sling immobilization and passive mobility as soon as allowed by pain, and maintained for up to 6 weeks, when strengthening begins. Patients are released for physical activity on average after 4 months, and a CT control to identify graft consolidation.

The first 10 procedures were performed arthroscopically, with subsequent open exposure of the surgical site for checking and necessary adjustments. The next 20 cases were done completely arthroscopically.

Results

Follow-up was at least 6 months long, ranging from 6 to 26 months, and there was no exclusion of any patient operated due to the appearance of another unrelated injury. In the study group, 26.7% (8/30) of the patients were female, and the mean age was 34 years old (19–55 years old, minimum and maximum).

The first 10 procedures were performed arthroscopically with subsequent open exposure of the surgical site, previously planned, for checking and necessary adjustments. There was no conversion of cases to perform the procedure

itself, but to check and ensure compliance of repairs. The main technical difficulties observed and corrected in the first cases were: (1) a too superior split of the subscapular; (2) perforation and preparation of the coracoid not aligned with its axis; (3) lateral positioning of the graft.

These difficulties were mainly found by the inadequate positioning of the portals. The midsub portal allows viewing of the subscapularis tendon in all its extension, with the execution of the split at the proper height. The pectoral portal (also called the suicidal portal), performed in line with the joint, is critical for proper graft placement at the anterior border of the glenoid. In the first cases of our learning curve, for fear of performing these two portals, these two steps of surgery may have been hindered. From the 11th case onwards, we proceeded to perform the procedure entirely by arthroscopy, and then, we could observe some complications inherent to the learning curve. Complications occurred in cases of number 6, 11, 12, 14, and 20. It is noteworthy that from the 21st to the 30th cases no complications were observed.

The total number of complications was of 5 events (16.7%), 1 intraoperative (3.3%), 3 transient postoperative events (6.7%) and 3 postoperative events leading to a new elective surgical procedure (6.7%). No patient had > 1 complication, totaling 5 cases (16.7%). No cases had unexpected bleeding during surgery, nor was there any postoperative hematoma. The sutures evolved as expected and no dehiscence occurred. No infections were observed, either deep or surgical wound.

In one case (3.3%) there was a fracture of the coracoid process at the time of fixation of the graft on the anterior glenoid border, and we opted to convert the arthroscopy to open surgery. The residual fragment was enough to maintain a screw fixing the graft. For safety reasons, we opted for conversion to open surgery to check and finalize the procedure. This case was the 20th case in the series. Two cases (6.7%) had musculocutaneous neuropraxia, which was reversed with a physiotherapy period, with no sequelae and no need for medication. Two patients (6.7%) developed limitation of external rotation due to very lateral positioning of the screws. For such cases, a new intervention was necessary to remove the synthesis material and perform the “slimming” of the lateral edge of the graft for joint release. The cases evolved satisfactorily after this procedure.

There was no recurrence in the sample during the follow-up period studied. It is worth remembering that a longer follow-up can bring the definitive results of this procedure.

Discussion

There is a consensus in the literature that Bristow-Latarjet surgery is a useful tool within the arsenal of surgical treatment of glenohumeral instabilities, playing an important role in the treatment of patients with bone lesions, engaging Hill-Sachs lesions, HAGL lesions, in young patients involved in contact sports or in relapses of Bankart lesions.^{19,20} Studies show good results despite the incidence of complications that give rise to concern, either at short, medium or long term.

Major complications are bleeding, axillary and musculocutaneous neuropraxia, graft-related problems (fractures or loosening of synthesis material) and excessive limitation of external rotation that can lead to arthrosis.^{10,11} Based on recent literature, Latarjet surgery, when performed arthroscopically, has a risk of nerve damage between 0 and 1.6%, significantly lower than open surgery. We believe this is due to the direct visualization of the neurovascular structures, to less need for displacement, besides less direct traction on the graft, since it is not pulled out of the joint for its preparation. The study of Zhu et al¹⁴ confirms that an indication for arthroscopic Latarjet is its lower risk of nerve or vascular injury.

Another important point is the positioning of the graft: when placed too lateral it can lead to excessive restriction of external rotation and arthrosis, while too high or medial positioning can lead to high recurrence rates. The literature shows that graft mispositioning varies between 20 and 67% in open surgery and between 4 and 24% when the surgery is performed arthroscopically.²¹⁻²³ We believe that the magnified view provided by the arthroscope, and the ability to look at different angles, makes positioning more accurate in the arthroscopic technique.

In our understanding, the surgeon and staff should be trained to perform the surgery openly, have knowledge and familiarity with arthroscopic instruments, and the surgery can and should be converted to open at any sign of danger to the patient or technical difficulty that endangers the accuracy and the end result. For any procedure, the transition from open surgery to arthroscopy is a process with a learning curve and continuous improvement. The arthroscopic Latarjet learning curve has been demonstrated in the literature, but it also exists for open Latarjet. Many authors^{15,24,25} report that between 18 and 30 cases are necessary for the surgeon and staff to feel safe in the procedure, and it was quite similar to our experience, in which a systematic check for open surgery was performed in the first 10 cases with some necessary adjustments, followed by 20 fully arthroscopic cases with 5 complications in the first 10 cases, and no complications in the final 10 cases of the series. The arthroscopic technique requires some previous experience with arthroscopy, but it was possible to obtain a low number of complications even in an initial experience.

Particularly in this surgery, teamwork is crucial. A knowledge of the technique by the whole team, as well as adequate anesthesiologist control of pressure and flow parameters, is essential not to increase excessively the surgical time and for the success of the procedure. As the technique and instruments evolve, complications tend to be minimized, as recent studies show, and we may have a very effective technique for glenohumeral joint stabilization with low complication rates. Allied to this, the new studies that are being performed evaluating graft positioning, screw fixation angle and graft resorption analysis, bring even more improvements and a better understanding of the technique and what happens to our patients in the long run.

Among the main advantages of the arthroscopic technique, we can mention the more accurate positioning of the graft near the anterior border of the glenoid, proper visualization of neurovascular structures and treatment of associ-

ated injuries, besides the inherent advantages of minimally invasive surgeries (less postoperative pain, lower infection rate and faster rehabilitation, besides being more aesthetically acceptable).^{8,9}

As in other contemporary literature articles,¹³ the present study presented short- to medium-term results of a group of patients treated with arthroscopic Latarjet by a group of surgeons at the beginning of the learning curve. Subsequent studies should show long-term results on arthroscopic application of Latarjet for correction of anterior shoulder dislocation with glenoid bone loss.

Conclusion

The preliminary results found in the present study using the arthroscopic Latarjet technique in the treatment of anterior shoulder instability are encouraging. The incidence of complications was low in relation to injuries of neurovascular structures in graft positioning.

Conflict of Interests

The authors have no conflict of interests to declare.

Acknowledgments

The authors would like to thank Antonio Guilherme Garofo, who contributed to this work with co-author merits, but could not be included in the authorship list due to publication guidelines. Also, the authors thank Bruno Rodrigo Crispim Lima for the brilliant graphic collaboration with the illustration of ► **Figure 1**.

References

- 1 D'Angelo D. Concept of healing of recurrent shoulder dislocation. *Rev Bras Ortop* 2014;49(04):420-425
- 2 Bankart AS. Recurrent or habitual dislocation of the shoulder-joint. *BMJ* 1923;2(3285):1132-1133
- 3 Latarjet M. [Treatment of recurrent dislocation of the shoulder]. *Lyon Chir* 1954;49(08):994-997
- 4 Helfet AJ. Coracoid transplantation for recurring dislocation of the shoulder. *J Bone Joint Surg Br* 1958;40-B(02):198-202
- 5 Ferreira Filho AA. Tratamento da luxacao anterior recidivante do ombro pela tecnica de bristow - latarjet [tese]. São Paulo: Faculdade de Medicina da Universidade de São Paulo; 1984
- 6 Moura DL, Reis ARE, Ferreira J, Capelão M, Cardoso JB. Modified Bristow-Latarjet procedure for treatment of recurrent traumatic anterior glenohumeral dislocation. *Rev Bras Ortop* 2018;53(02):176-183
- 7 Hovelius L, Sandström B, Sundgren K, Saebö M. One hundred eighteen Bristow-Latarjet repairs for recurrent anterior dislocation of the shoulder prospectively followed for fifteen years: study I-clinical results. *J Shoulder Elbow Surg* 2004;13(05):509-516
- 8 Karlsson J, Magnusson L, Ejerhed L, Hulthenheim I, Lundin O, Kartus J. Comparison of open and arthroscopic stabilization for recurrent shoulder dislocation in patients with a Bankart lesion. *Am J Sports Med* 2001;29(05):538-542
- 9 Freedman KB, Smith AP, Romeo AA, Cole BJ, Bach BR Jr. Open Bankart repair versus arthroscopic repair with transglenoid sutures or bioabsorbable tacks for Recurrent Anterior instability of the shoulder: a meta-analysis. *Am J Sports Med* 2004;32(06):1520-1527

- 10 Lafosse L, Lejeune E, Bouchard A, Kakuda C, Gobezie R, Kochhar T. The arthroscopic Latarjet procedure for the treatment of anterior shoulder instability. *Arthroscopy* 2007;23(11):1242.e1–1242.e5
- 11 Lafosse L, Boyle S, Gutierrez-Aramberri M, Shah A, Meller R. Arthroscopic Latarjet procedure. *Orthop Clin North Am* 2010;41(03):393–405
- 12 Dumont GD, Fogerty S, Rosso C, Lafosse L. The arthroscopic Latarjet procedure for anterior shoulder instability: 5-year minimum follow-up. *Am J Sports Med* 2014;42(11):2560–2566
- 13 Athwal GS, Meislin R, Getz C, Weinstein D, Favorito P. Short-term Complications of the Arthroscopic Latarjet Procedure: A North American Experience. *Arthroscopy* 2016;32(10):1965–1970
- 14 Zhu YM, Jiang C, Song G, Lu Y, Li F. Arthroscopic Latarjet Procedure With Anterior Capsular Reconstruction: Clinical Outcome and Radiologic Evaluation With a Minimum 2-Year Follow-Up. *Arthroscopy* 2017;33(12):2128–2135
- 15 Castricini R, De Benedetto M, Orlando N, Rocchi M, Zini R, Pirani P. Arthroscopic Latarjet procedure: analysis of the learning curve. *Musculoskelet Surg* 2013;97(Suppl 1):93–98
- 16 Schulze-Borges J, Agneskirchner JD, Bobrowitsch E, et al. Biomechanical comparison of open and arthroscopic Latarjet procedures. *Arthroscopy* 2013;29(04):630–637
- 17 Boileau P, Saliken D. Editorial Commentary: The Wake of the Dragon: Will the Orthopaedic Community Adopt the Shoulder Arthroscopic Latarjet Procedure as We Adopted the Arthroscopic Rotator Cuff Repair? *Arthroscopy* 2017;33(12):2139–2143
- 18 Balg F, Boileau P. The instability severity index score. A simple pre-operative score to select patients for arthroscopic or open shoulder stabilisation. *J Bone Joint Surg Br* 2007;89(11):1470–1477
- 19 da Silva LA, da Costa Lima ÁG, Kautsky RM, Santos PD, do Val Sella G, Checchia SL. Evaluation of the results and complications of the Latarjet procedure for recurrent anterior dislocation of the shoulder. *Rev Bras Ortop* 2015;50(06):652–659
- 20 Ikemoto RY, Murachovisky J, Nascimento LG, et al. Results from Latarjet surgery for treating traumatic anterior shoulder instability associated with bone erosion in the glenoid cavity, after minimum follow-up of one year. *Rev Bras Ortop* 2015;46(05):553–560
- 21 Kraus TM, Martetschläger F, Graveleau N, et al. CT-based quantitative assessment of the surface size and en-face position of the coracoid block post-Latarjet procedure. *Arch Orthop Trauma Surg* 2013;133(11):1543–1548
- 22 Casabianca L, Gerometta A, Masseurin A, et al. Graft position and fusion rate following arthroscopic Latarjet. *Knee Surg Sports Traumatol Arthrosc* 2016;24(02):507–512
- 23 Boileau P, Thélu CÉ, Mercier N, et al. Arthroscopic Bristow-Latarjet combined with Bankart repair restores shoulder stability in patients with glenoid bone loss. *Clin Orthop Relat Res* 2014;472(08):2413–2424
- 24 Kany J, Flamand O, Grimberg J, et al. Arthroscopic Latarjet procedure: is optimal positioning of the bone block and screws possible? A prospective computed tomography scan analysis. *J Shoulder Elbow Surg* 2016;25(01):69–77
- 25 Cunningham G, Benchouk S, Kherad O, Lädermann A. Comparison of arthroscopic and open Latarjet with a learning curve analysis. *Knee Surg Sports Traumatol Arthrosc* 2016;24(02):540–545