



5-Aminolevulinic Acid—A Biomarker for Worse Prognosis in IDH-Wildtype II Tumors? Evolution of a Fluorescence-Positive Diffuse Astrocytoma: A Case Report

Jose E. Valerio^{1,2,3} Sebastian Ochoa^{1,2} Sandra Alvarez^{1,2} Matteo Borro¹
Andres M. Alvarez-Pinzon^{1,2,4,5}

¹Neurosurgery Oncology Department, Miami Neurosciences Center at Larkin, South Miami, Florida, United States

²Latino America Valerio Foundation, Weston, Florida, United States

³Palmetto General Hospital, A Steward Family Hospital, Florida, United States

⁴The Institute of Neuroscience of Castilla y León (INCYL), University of Salamanca (USAL), Salamanca, Spain

⁵Biotechnology Program, Johns Hopkins University, Baltimore, Maryland, United States

Address for correspondence Andres M. Alvarez-Pinzon, MD, PhD, MHA, Neurosurgery Oncology Department, Miami Neurosciences Center at Larkin, Miami, FL 33143, United States (e-mail: andresmauricioalvarez07@gmail.com).

J Neurol Surg Rep 2022;83:e95–e99.

Abstract

Introduction In 2017, the U.S. Food and Drug Administration (FDA) approved 5-aminolevulinic acid (5-ALA) as an intraoperative optical imaging agent in patients with suspected high-grade gliomas (HGGs). However, the application of 5-ALA for low-grade gliomas is still less accepted. Astrocytoma, isocitrate dehydrogenase (IDH) mutant tumors are diffuse infiltrating astrocytic tumors where there is no identifiable border between the tumor and normal brain tissue, even though the borders may appear relatively well-margined on imaging. Generally, it is considered that 5-ALA cannot pass through a normal blood–brain barrier (BBB). Thus, 5-ALA fluorescence may mean disruption of BBB in grade II glioma.

Case Report A 74-year-old male patient was diagnosed with a right parietal lesion suggestive of a low-grade brain tumor in a surgical resection using 5-ALA, which led to the detection of tiny fluorescence spots during the surgery. The frozen section was consistent with diffuse astrocytoma, IDH-wildtype (World Health Organization [WHO] grade II). The patient's postoperative magnetic resonance imaging (MRI) showed complete resection. Eight months after surgery, he began experiencing symptoms again and was admitted with a brain MRI finding consistent with recurrent infiltrating astrocytomas. This required reoperation of the brain tumor resection with 5-ALA. Unlike the first surgery, they observed a high fluorescence intensity; the pathological finding was glioblastoma, IDH-wildtype (WHO grade IV). Postsurgical brain MRI showed total resection of the tumor. The patient was discharged 4 weeks after surgery and continued with specialized clinical follow-up.

Keywords

- ▶ brain tumor
- ▶ 5-ALA
- ▶ diffuse astrocytoma

received
March 31, 2022
accepted
May 11, 2022
accepted manuscript online
May 22, 2022

DOI <https://doi.org/10.1055/a-1858-7628>.
ISSN 2193-6358.

© 2022. The Author(s).

This is an open access article published by Thieme under the terms of the Creative Commons Attribution-NonDerivative-NonCommercial-License, permitting copying and reproduction so long as the original work is given appropriate credit. Contents may not be used for commercial purposes, or adapted, remixed, transformed or built upon. (<https://creativecommons.org/licenses/by-nc-nd/4.0/>)

Georg Thieme Verlag KG, Rüdigerstraße 14, 70469 Stuttgart, Germany

Conclusion The use of 5-ALA continues to be a great contributor to the improvement in complete resection of primary brain tumors, especially HGG. Besides, fluorescence is increasingly approaching its use as a prognostic tool for aggressive clinical course, regardless of the initial grade of the tumor. This case report is an effort to expand knowledge for potentially using 5-ALA to help prognosticate brain tumors. Nevertheless, more clinical prospective studies must be conducted.

Introduction

Diffuse astrocytoma isocitrate dehydrogenase (IDH)-wildtype is an uncommon diagnosis, and the pathology of the disease is controversial.^{1–3} The grading of astrocytoma, IDH mutant is based on histological features, as well incorporating molecular markers (introduced in the 5th edition (2021) World Health Organization [WHO] classification of central nervous system [CNS] tumors).¹ IDH-mutant adult-type astrocytomas are typically diagnosed in young adults median age of 36 years for grades II and III (combined), and 38 years for grade IV. This is substantially younger than glioblastoma (GBM) IDH-wildtype tumors (median: 50–60 years of age). There is a substantially higher incidence in men of all ages and of all grades tumor. Tumors with normal IDH genes referred to as “IDH-wildtype” tend to behave far more aggressively. It is well documented that pathological classification has an elevated interobserver discrepancy and consequently incorrectly predicts clinical outcomes. Additional clinical research studies have presented that the genetic status of these tumors is further reflective of their subtypes than the histologic grading. 5-Aminolevulinic acid (5-ALA) is an orally administered prodrug that improves GBM visualization during surgery, allowing safer and more extensive tumor resection. Prognosis is similar to that of primary GBM.^{1–3} Although it is a low-grade glioma, it exhibits molecular and clinical features of high-grade glioma and may represent an early stage of primary GBM.^{3,4} For that reason, even the mere existence of this type of tumor is in doubt.^{4,5} 5-ALA improves the delimitation of malignant tissue during surgery, obtaining a positive predictive value of 95.7% (when used for the diagnosis of GBM by biopsy).^{5–7} 5-ALA achieves a better extent of resection (EOR), simultaneously decreasing residual fluorescence tissue (gadolinium T1 magnetic resonance imaging [MRI]), which led to an increase in overall survival (27.0 months confidence interval [CI] 95%: 22.4–31.6) compared with patients with residual fluorescence tissue (17.5 months CI 95%: 12.5–22.5).^{6,8}

The FDA approval of 5-ALA as an intraoperative optical imaging agent in patients with suspected high-grade gliomas (HGGs) occurred in 2017.^{1,7} However, the application of 5-ALA for low-grade gliomas is still less accepted.^{8–11} In this case report, we discuss the case of a histologically low-grade glioma with positive fluorescence that develops a poor outcome.

Case Presentation

This is a 74-year-old male patient, right-handed, history of hypertension, various cardiovascular interventions, and polypharmacy. Referred symptoms were left-hand numbness

and tingling sensation, associated with the left side of the face and tongue numbness, as well as slurred speech. MRI of the brain revealed a right parietal lesion, with mass-effect and solid consistency, suggestive of a low-grade brain tumor, which led to the decision to biopsy the lesion. The result of the biopsy suggested low-grade glioma but awaits permanent sections to a definitive diagnosis. Surgery for complete resection was scheduled 1 month later. The patient underwent Awake Stereotactic Frameless Craniotomy using 5-ALA (1500 mg oral route, 2 hours before surgery) fluorescence guidance and neuronavigation. Patient was not on any drugs that may affect 5-ALA fluorescence. Tiny spots of fluorescence were observed during surgery (weak fluorescence). The frozen section was consistent with diffuse astrocytoma, IDH-wildtype (WHO grade II). Mitoses, necrosis, CDKN2A/B homozygous deletion, and microvascular proliferation were absent. Postsurgical brain MRI showed complete resection (►Fig. 1). The patient was discharged with clinical and imaging follow-up every 3 months to monitor the lesion.

Eight months postsurgery, the patient became symptomatic again and was admitted to the emergency room. MRI findings indicated recurrent infiltrating astrocytoma, extensive adjacent vasogenic edema, mass effect, and resolving hemorrhage. The patient underwent reoperation with 5-ALA fluorescence guidance resection and neuronavigation. In contrast to the first surgery, high-intensity fluorescence was observed, well related to HGG. A new sample was sent to pathology, resulting in GBM, IDH-wildtype (WHO grade IV).

Postsurgical brain MRI showed complete resection of the tumor (►Fig. 2). The patient was discharged 4 weeks after surgery and continued with specialized clinical follow-up. One month after discharge, he showed improvement in symptoms, mild left muscular weakness, no aphasia, normal coordination, and mild gait difficulty—the last MRI reported an overall improvement in the operative cavity and no mass effect. To gain a deeper understanding of the patient's case, a timeline of their evolution was drawn (►Fig. 3).

Discussion

From the authors' knowledge, this is the first report of a 5-ALA fluorescent diffuse astrocytoma IDH-wildtype and its tracing until malignant transformation. The IDH-mutant astrocytomas are now graded II, III, or IV established on histological and molecular features, but remarkably a grade IV tumor is no longer a GBM, but reasonably just an astrocytoma, IDH mutant WHO CNS grade IV. GBM is currently measured as separate entity and different and must be IDH-

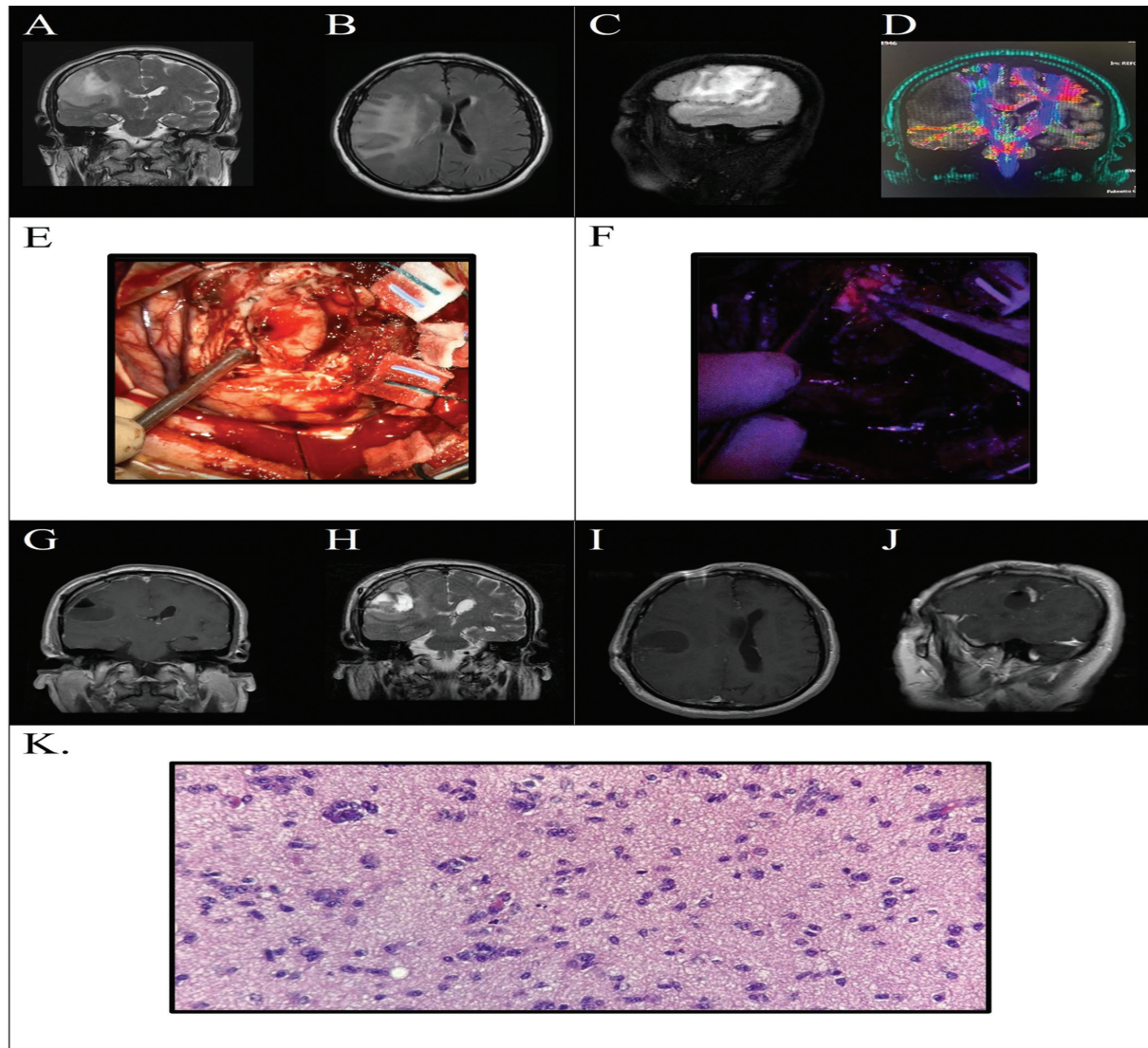


Fig. 1 Evolution of first surgical intervention. Preoperative magnetic resonance imaging (MRI): Right mid-parietal gray matter lesion related to a low-grade glioma. (A) Coronal T2; (B) axial fluid-attenuated inversion recovery; (C) sagittal T2; (D) diffusion tensor imaging); intraoperative images. Correlation between the different moments of the surgery (E), white light; (F) 5-aminolevulinic acid fluorescence in blue light. Postoperative MRI: complete resection of the tumor, (G) coronal T1; (H) coronal T2; (I) axial T1; and (J), sagittal T1). Brain tumor pathology: increased cellularity and increased cytologic atypia, histiocytic reaction and chronic inflammation, ki-67 positive, 3 + , nuclear on 5% of cells; (K) diffuse astrocytoma, isocitrate dehydrogenase-wildtype, World Health Organization grade II.

wildtype, and is therefore discussed separately. Essentially, the identification of astrocytoma, IDH mutant is an adult-type diagnosis, different from a variety of other pediatric-type diffuse astrocytomas. In a previous retrospective clinical study, So Youn Ji et al¹¹ evaluate the performance of 5-ALA in 827 cases of gliomas. Their survey agreed with most of the literature by finding fluorescence in 95% of GBM. While in a lower percentage, the grade I to III gliomas also showed a certain degree of fluorescence during surgery (55, 24.1, 26.3% of cases, respectively). There were 20 cases of diffuse astrocytomas or oligoastrocytomas. Only two of the cases reported focal fluorescence and a total of 15 cases that underwent resection, including those that had focal fluorescence. Paradoxically, there was no improvement in EOR for positive fluorescence low-grade gliomas.^{10,11} Generally, it is

considered that 5-ALA cannot pass through a normal blood-brain barrier (BBB). Thus, 5-ALA fluorescence may mean disruption of BBB in grade II glioma. According to the literature, the rates of 5-ALA induced fluorescence in WHO grade II tumors vary^{8,10-13} (– Table 1).

As shown in our case, the clinical relevance of positive fluorescence in low-grade gliomas is poorly understood; however, due to the recurrence of the tumor and its aggressiveness, we agree that it is directly related to an increased proliferation rate and anaplasia as referred to in studies.¹⁴⁻¹⁶ We consider that fluorescence during surgery could have been a red flag for poor prognosis in this patient. Jaber et al¹³ reported a shorter overall survival (51.6 months [34.8–68.3] vs. 68.2 months [62.7–73.8], $p = 0.002$) and shorter periods of malignant transformation (43.0 months [27.5–58.5] vs.

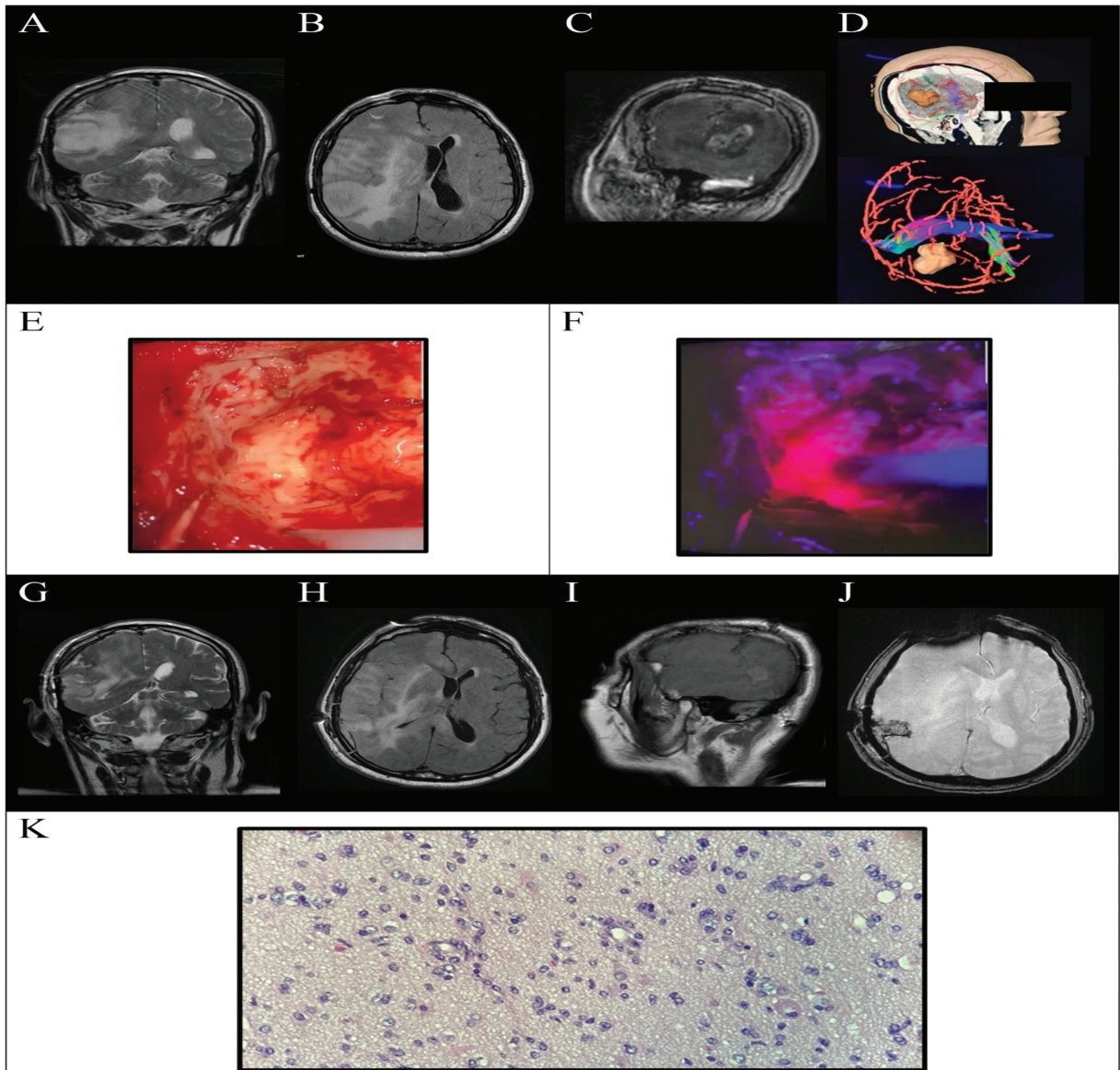


Fig. 2 Evolution of second surgical intervention. Preoperative magnetic resonance imaging (MRI): Finding consistent with recurrent infiltrating astrocytoma (A) coronal T2; (B) axial fluid-attenuated inversion recovery; (C) sagittal T1 gadolinium; (D) diffusion tensor imaging, three-dimensional axial and sagittal. Intraoperative images. Correlation between the different moments of the surgery (E) white light; (F), 5-aminolevulinic acid fluorescence with blue light. Postoperative MRI: complete resection of the tumor (G) coronal T2; (H) axial T2; (I) sagittal T1; (J) axial; Brain tumor pathology: areas of necrosis, diffuse infiltrative pattern, ki-67 positive, 3 +, in 3% of tumor cells. (K) Glioblastoma, isocitrate dehydrogenase-wildtype, World Health Organization grade IV).

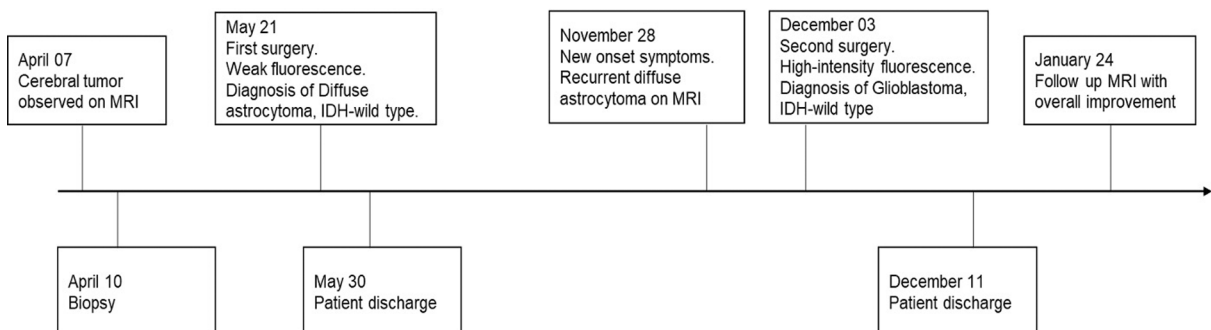


Fig. 3 Timeline of the clinical case. IDH, isocitrate dehydrogenase; MRI, magnetic resonance imaging.

Table 1 Fluorescence in World Health Organization grade II gliomas

Authors and year	Cases with positive fluorescence	Total cases
So Young Ji et al (2019) ¹¹	21 (25%)	87
Ewelt et al (2011) ¹²	1 (8%)	13
Widhalm et al (2013) ⁹	4 (9%)	33
Jaber et al (2016) ¹⁴	13 (16%)	82
Marbacher et al (2014) ¹³	8 (40%)	20

64.6 months [57.7–71.5], $p=0.015$) in patients with low-grade glioma with positive fluorescence against those without.^{13–16} In contrast, the patient in the case had faster malignant transformation (8 months). However, these types of tumors could have a clinical course and survival more akin or only slightly longer than GBM IDH-wild type.^{1–4} We also consider that 5-ALA helped improve the EOR in this patient.

Conclusion

The use of 5-ALA continues to be a great contributor to the improvement in complete resection of primary brain tumors, especially HGG. Besides, fluorescence is increasingly approaching its use as a prognostic tool for aggressive clinical behavior, regardless of the initial grade of the tumor. This case is reported in an effort to extend knowledge for future research for the use of 5-ALA in brain tumors as a prognostic tool. Nevertheless, more studies with greater power should be designed to achieve a definitive conclusion.

Conflict of Interest

None.

Authors' Contributions

All authors contributed to manuscript conceptualization, investigation, manuscript edition, review and writing.

References

- 1 Brat D, Reuss D, Deimling A, Huse JR. Astrocytoma, IDH-mutant. In: WHO Classification of Tumours Editorial Board. Central Nervous System Tumours. Lyon (France): International Agency for Research on Cancer; 2021. (WHO Classification of Tumours Series, 5th ed.; vol. 6). <https://publications.iarc.fr/601>
- 2 Brat DJ, Verhaak RG, Aldape KD, et al; Cancer Genome Atlas Research Network. Comprehensive, integrative genomic analysis of diffuse lower-grade gliomas. *N Engl J Med* 2015;372(26):2481–2498
- 3 Louis DN, Perry A, Reifenberger G, et al. The 2016 World Health Organization Classification of Tumors of the Central Nervous System: a summary. *Acta Neuropathol* 2016;131(06):803–820
- 4 Hasselblatt M, Jaber M, Reuss D, et al. Diffuse astrocytoma, IDH-wildtype: a dissolving diagnosis. *J Neuropathol Exp Neurol* 2018;77(06):422–425
- 5 Reuss DE, Kratz A, Sahm F, et al. Adult IDH wild type astrocytomas biologically and clinically resolve into other tumor entities. *Acta Neuropathol* 2015;130(03):407–417
- 6 Stummer W, Tonn JC, Goetz C, et al. 5-Aminolevulinic acid-derived tumor fluorescence: the diagnostic accuracy of visible fluorescence qualities as corroborated by spectrometry and histology and postoperative imaging. *Neurosurgery* 2014;74(03):310–319, discussion 319–320
- 7 Aldave G, Tejada S, Pay E, et al. Prognostic value of residual fluorescent tissue in glioblastoma patients after gross total resection in 5-aminolevulinic Acid-guided surgery. *Neurosurgery* 2013;72(06):915–920, discussion 920–921
- 8 Hadjipanayis CG, Stummer W. 5-ALA and FDA approval for glioma surgery. *J Neurooncol* 2019;141(03):479–486
- 9 Widhalm G, Kiesel B, Woehrer A, et al. 5-Aminolevulinic acid induced fluorescence is a powerful intraoperative marker for precise histopathological grading of gliomas with non-significant contrast-enhancement. *PLoS One* 2013;8(10):e76988
- 10 Nishikawa R. Fluorescence illuminates the way. *Neuro-oncol* 2011;13(08):805
- 11 Ji SY, Kim JW, Park C-K. Experience profiling of fluorescence-guided surgery II: non-glioma pathologies. *Brain Tumor Res Treat* 2019;7(02):105–111
- 12 Ewelt C, Floeth FW, Felsberg J, et al. Finding the anaplastic focus in diffuse gliomas: the value of Gd-DTPA enhanced MRI, FET-PET, and intraoperative, ALA-derived tissue fluorescence. *Clin Neurol Neurosurg* 2011;113(07):541–547
- 13 Marbacher S, Klinger E, Schwyzer L, et al. Use of fluorescence to guide resection or biopsy of primary brain tumors and brain metastases. *Neurosurg Focus* 2014;36(02):E10
- 14 Jaber M, Wölfer J, Ewelt C, et al. The value of 5-aminolevulinic acid in low-grade gliomas and high-grade gliomas lacking glioblastoma imaging features: an analysis based on fluorescence, magnetic resonance imaging, 18F-fluoroethyl tyrosine positron emission tomography, and tumor molecular factors. *Neurosurgery* 2016;78(03):401–411, discussion 411
- 15 Widhalm G, Wolfsberger S, Minchev G, et al. 5-Aminolevulinic acid is a promising marker for detection of anaplastic foci in diffusely infiltrating gliomas with nonsignificant contrast enhancement. *Cancer* 2010;116(06):1545–1552
- 16 Jaber M, Ewelt C, Wölfer J, et al. Is visible aminolevulinic acid-induced fluorescence an independent biomarker for prognosis in histologically confirmed (World Health Organization 2016) low-grade gliomas? *Neurosurgery* 2019;84(06):1214–1224