

[ CASE REPORT ]

## Cerebral Venous Thrombosis: An Unexpected Complication with Cerebrospinal Fluid Leaks after a Fall in a Patient with Spinocerebellar Ataxia Type 6

Yuki Yamamoto<sup>1</sup>, Nobuaki Yamamoto<sup>1</sup>, Koji Fujita<sup>1</sup>, Tatsuya Fukumoto<sup>1</sup>,  
Nagahisa Murakami<sup>1</sup>, Hideo Mure<sup>2</sup>, Yasuhisa Kanematsu<sup>2</sup>,  
Yasushi Takagi<sup>2</sup> and Yuishin Izumi<sup>1</sup>

### Abstract:

A 65-year-old woman with spinocerebellar ataxia presented with generalized seizures due to subcortical hemorrhaging. Magnetic resonance imaging (MRI) revealed obstruction of the superior sagittal sinus. Despite treatment, she became comatose. MRI newly revealed subdural fluid collection and descent of the brainstem. Her history indicated a recent fall, prompting additional studies, which revealed lumbar fracture and cerebrospinal fluid (CSF) leaks. We performed an epidural blood patch, and her consciousness was fully restored in one month. This is the first report of cerebral venous thrombosis with CSF leaks in the lumbar region due to a fall injury.

**Key words:** cerebral venous thrombosis, cerebrospinal fluid, spinal trauma, spinocerebellar ataxias

(Intern Med 59: 1749-1753, 2020)

(DOI: 10.2169/internalmedicine.4388-20)

### Introduction

Spinal cerebrospinal fluid (CSF) leaks caused by traumatic, iatrogenic, or idiopathic induce intracranial hypotension. Although orthostatic headache is one of the typical symptoms, the diagnosis of CSF leaks remains difficult due to the variety of clinical manifestations (1, 2). Cerebral venous thrombosis (CVT) is a rare but life-threatening complication of intracranial hypotension (3). We encountered an elderly patient with spinocerebellar ataxia type 6 (SCA6) who, after falling, developed CVT with a CSF leaks. The diagnosis was challenging, but she was successfully treated.

We herein report the treatment course for this case and discuss the complicated factors leading to its resolution.

### Case Report

A 65-year-old woman suddenly developed a generalized

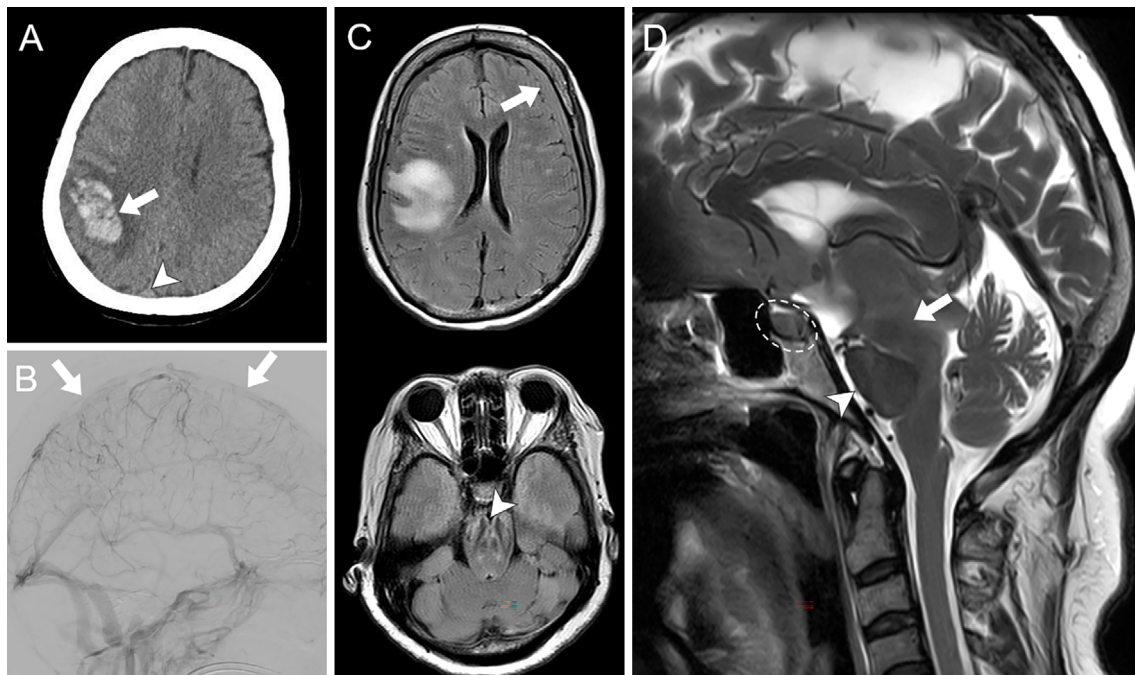
seizure and was taken to our hospital. She had slowly progressive limb ataxia and dysarthria and had been diagnosed with SCA6 20 years ago by genetic testing. Taltirelin hydrate had been used to relieve cerebellar ataxia. She required a cane for walking; however, her gait had been unstable, with a history of falling several times a year. There was no history of head trauma or headache before admission.

Her seizures disappeared with the administration of antiepileptic drugs, such as levetiracetam (2,000 mg daily) and phenytoin (300 mg daily), after using intravenous diazepam (10 mg); however, she then experienced left hemiparesis. Head computed tomography (CT) showed subcortical hemorrhaging in the right parietal lobe. Although a hyperdense area in the superior sagittal sinus (SSS), indicating CVT, was present on CT, the attending physicians did not recognize it at the time of admission (Fig. 1A). Conservative treatment using antiepileptic drugs was continued, but her consciousness level gradually declined. On the eighth day after the onset, magnetic resonance venography revealed de-

<sup>1</sup>Department of Neurology, University of Tokushima Graduate School of Biomedical Sciences, Japan and <sup>2</sup>Department of Neurosurgery, University of Tokushima Graduate School of Biomedical Sciences, Japan

Received: January 5, 2020; Accepted: February 9, 2020; Advance Publication by J-STAGE: April 2, 2020

Correspondence to Dr. Yuki Yamamoto, yuki.yamamoto412@gmail.com



**Figure 1.** (A) An axial view of a head computed tomography scan reveals subcortical hemorrhaging in the right parietal lobe (arrow) and a hyperdense area in the superior sagittal sinus (arrowheads). (B) Digital subtraction angiography of the left common carotid artery (lateral view). Poor reflux of the superior sagittal sinus (arrows) is observed in the venous phase. (C) Axial fluid-attenuated inversion recovery magnetic resonance imaging (MRI) reveals subdural fluid collection along the left-side frontal convexity (arrow), deformation of the midbrain, and narrowing of the interpeduncular fossa (arrowhead). (D) Sagittal T2-weighted MRI reveals sagging and deformation of the midbrain (arrow), flattening of the anterior pons (arrowhead), and enlargement of the pituitary gland (dotted circle).

fects of the anterior part of the SSS. The serum D-dimer level at admission was 6.9  $\mu\text{g}/\text{mL}$  (cut-off, <1.0). Protein S, protein C, antithrombin, and homocysteine levels were all normal. Digital subtraction angiography revealed cerebral venous congestion and obstruction of the SSS (Fig. 1B), and she was diagnosed with CVT.

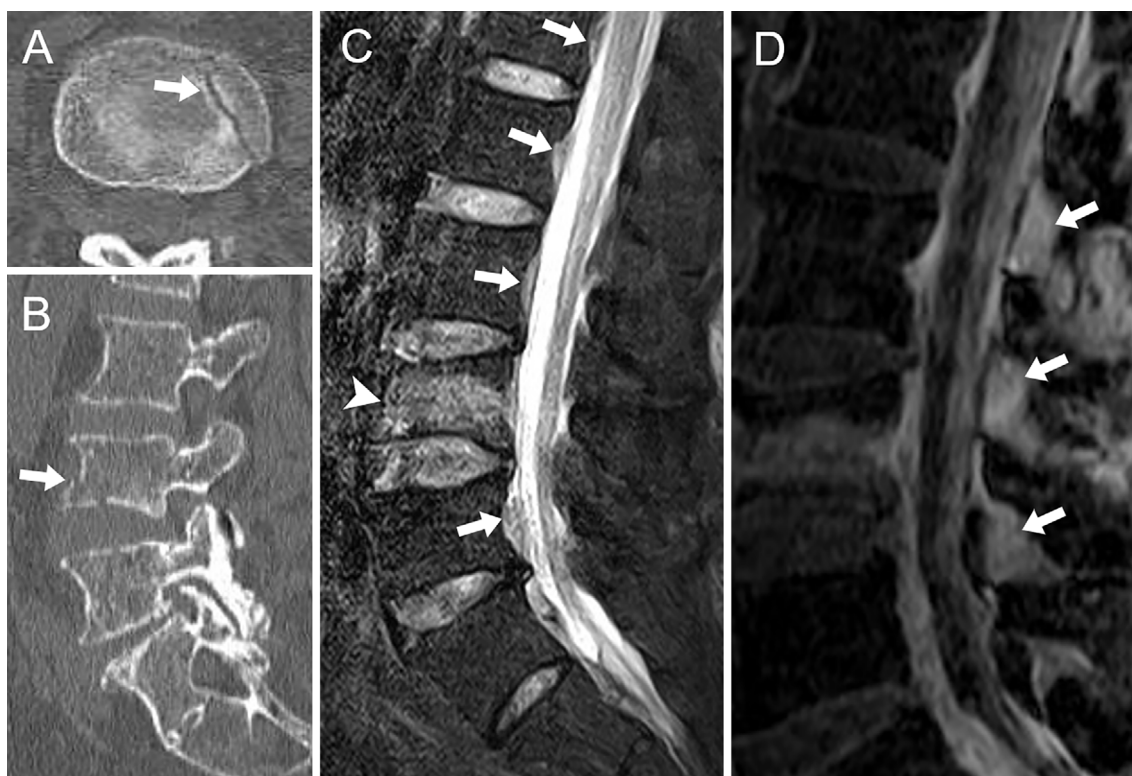She received unfractionated heparin infusion and additionally underwent endovascular treatment because alteration in her mental status was progressing. Multiple thrombi were removed by transvenous thrombectomy using a stent retriever device (Solitaire FR<sup>®</sup>; Medtronic, Irvine, USA). On the following day, however, she became comatose with bilateral pupil dilation. Brain magnetic resonance imaging (MRI) showed subdural fluid collection along the left frontal convexity and sagging and deformation of the brainstem (Fig. 1C, D).

A history of a fall and contusion of the back two weeks before admission was then discovered. We suspected CSF leaks at the lumbar region of the spinal cord. Lumbar MRI and CT revealed a fresh fracture of the fourth lumbar vertebral body and extravasation of CSF to the dorsal extradural fat tissues (Fig. 2A-C). Neither radionuclide cisternography nor CT myelography was performed due to the severity of her status. We corrected the diagnoses to CVT with CSF leaks and fracture of the fourth lumbar vertebral body asso-

ciated with the falling injury. An epidural blood patch (EBP) was planned; 15 mL of blood was injected through a catheter inserted between the fourth and fifth lumbar space. After the EBP, her mental status gradually improved and fully recovered over the course of the following month. Follow-up imaging studies showed resolution of the subdural fluid collection and improvement of the sagging and deformity of the brainstem (Fig. 3). Anticoagulation therapy had been switched from heparin to apixaban (10 mg daily) and continued, with the patient experienced no increase in cerebral hemorrhaging or bleeding complications over the following year. Partial left-side hemiparesis remained, and she went home after several months of rehabilitation in another hospital.

## Discussion

CVT is a rare but life-threatening complication of intracranial hypotension. Schievink et al. reported that 3 of 141 patients (2.1%) with spontaneous intracranial hypotension were also diagnosed with CVT (3). Several hypotheses exist concerning the mechanism by which intracranial hypotension causes CVT, including increased and stagnated cerebral venous blood compensating for CSF loss, mechanical distortion of the vessel wall caused by brain sagging and increase



**Figure 2.** (A) Axial and (B) sagittal views of computed tomography scans reveal a fracture line in the fourth lumbar vertebral body (arrows). (C) Sagittal short T1 inversion recovery magnetic resonance imaging (MRI) reveals anterior epidural fluid collection at the level of the lumbar region (arrows) and a fresh compression fracture of the fourth lumbar vertebral body (arrowhead). (D) Sagittal gadolinium-enhanced fat-suppressed T2-weighted MRI reveals extravasation of fluid into the dorsal extradural fat tissues (arrows).

of blood viscosity in the venous compartment caused by reduced CSF absorption (3). Currently, more than 30 similar cases have been reported in the literature, and most of these were due to idiopathic CSF leaks at the location of cervical or thoracic levels (4). To our knowledge, this is the first report of a case of CVT with CSF leaks in the lumbar region due to a fall injury.

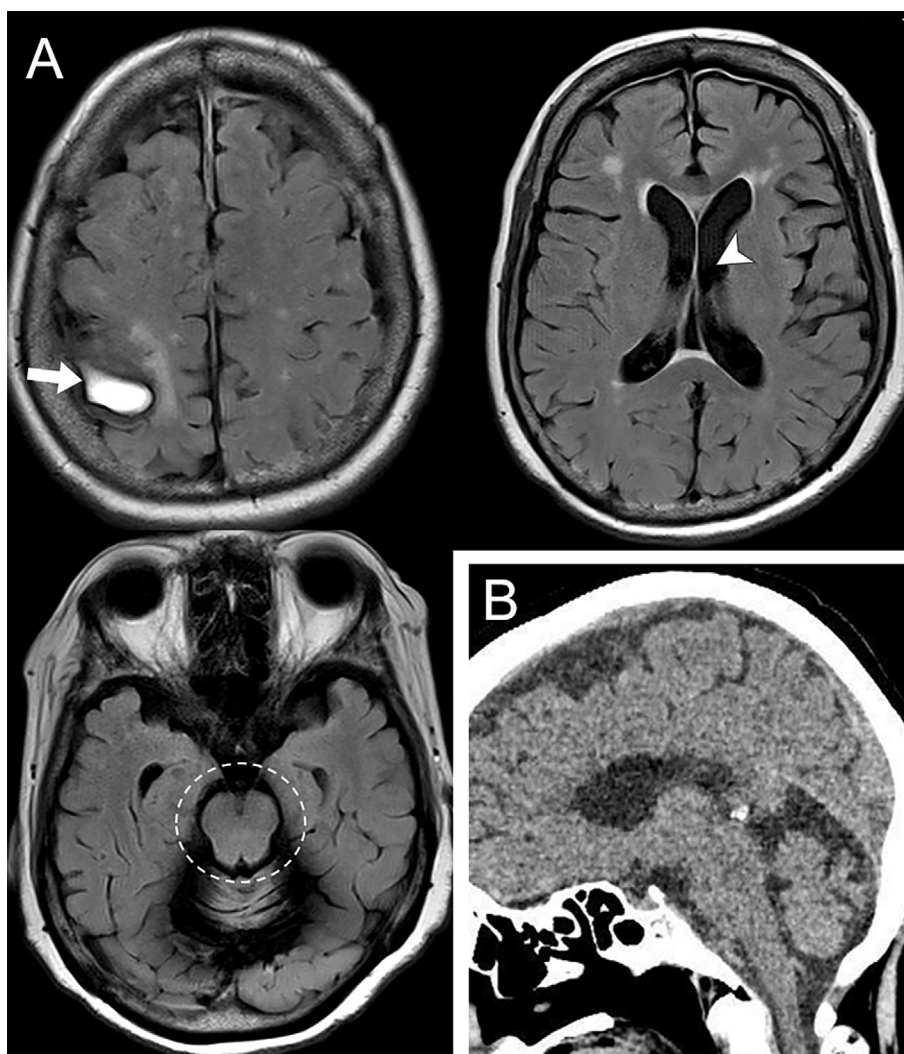
If the symptoms and imaging findings of CVT dominate, it can be difficult to recognize the underlying intracranial hypotension and CSF leaks. As our patient did not experience any type of headache from the time of the fall to the admission, the diagnosis was even more difficult. In fact, clinical features of intracranial hypotension may vary, and headache may even be absent, as has been reported in some asymptomatic cases (5). The interactions between the CSF pressure, clinical manifestations, and imaging changes appear to be complex and variable. In our case, the expansion of the intracranial CSF space by cerebellar atrophy might have affected her symptoms.

SCA is characterized by slowly progressive limb and truncal ataxia (6). There is still no curative treatment, and management of SCA is aimed at providing supportive care and preventing complications. One of the major complications is falling. According to Fonteyn et al., 84% of SCA patients (including SCA1, 2, 3 and 6) reported at least 1 fall

during a period of 12 months (7). Fall-related injuries were common, and a longer disease duration was associated with a higher fall frequency. In our case, a fall injury due to gait instability triggered the CSF leaks in the lumbar region and accompanying CVT. Similar situations may occur not only in patients with SCA but also in those with gait instability in general.

Recommended diagnostics to locate CSF leaks in the spinal region include cisternography or myelography with radioisotope or contrast medium. However, in cases with severe neurological symptoms, as in our patient, these examinations may be contraindicated. Brain MRI findings that suggest intracranial hypotension include subdural fluid collection, diffuse pachymeningeal contrast enhancement, and descent of the cerebellar tonsils and brainstem (8). MRI is also useful for identifying CSF leaks in the spinal region, including engorgement of the spinal epidural venous plexus, and spinal dural enhancement. This can sometimes identify the actual site of leaks when extradural extravasation of fluid is observed (1). Sakurai et al. recently revealed that interspinous arched hyperintensity on lumbosacral sagittal fat-suppressed T2-weighted MRI indicates the focus of CSF leaks (9). In our case, corresponding findings were found around the dorsal side of the vertebral body fracture, and we regarded them as indirect evidence of CSF leaks.





**Figure 3.** Images one month after epidural blood patch treatment. (A) Axial views of fluid-attenuated inversion recovery magnetic resonance imaging reveal hematoma in the subacute phase in the right parietal lobe (arrow). The subdural fluid collection had regressed, the size of the lateral ventricle was normal (arrowhead), and no midbrain deformation was noted (dotted circle). (B) Sagittal view of a computed tomography scan reveals no sagging and deformation of brainstem.

We initially attempted anticoagulation and endovascular treatments for CVT, but no clear improvement was obtained. Although the efficacy of endovascular treatment for CVT has not been established, certain recanalization rates and beneficial effects have been suggested, especially for severe cases involving coma and cerebral hemorrhaging (10). In our case, since the development of CVT was closely associated with CSF leaks, the primary treatment should have been directed towards the leaks. EBP is one of the curative treatments for CSF leaks through tamponade of the dural leak, fibrin deposition, and scar formation. Early and long-term anticoagulation with heparin and vitamin K antagonists is recommended for treatment of CVT, regardless of the presence of intracranial hemorrhaging (11). The indication of anticoagulation for secondary CVT with CSF leaks is controversial (4). We administered intravenous injections of unfractionated heparin for the first two weeks and thereafter continued treatment with apixaban. Only a few case series

have reported the efficacy of direct oral anticoagulants including apixaban on CVT (12). However, apixaban has the advantage of reducing bleeding risk over vitamin K antagonists in the area of stroke prevention for patients with atrial fibrillation (13). In this case, we considered intracranial bleeding due to falls and selected anti-coagulation therapy with apixaban.

Appropriate written consent was obtained from patients described in this article.

**The authors state that they have no Conflict of Interest (COI).**

#### References

1. Mokri B. Spontaneous low pressure, low CSF volume headaches: spontaneous CSF leaks. *Headache* **53**: 1034-1053, 2013.
2. Schievink WI. Spontaneous spinal cerebrospinal fluid leaks and in-

- tracranial hypotension. *JAMA* **295**: 2286-2296, 2006.
3. Schievink WI, Maya MM. Cerebral venous thrombosis in spontaneous intracranial hypotension. *Headache* **48**: 1511-1519, 2008.
  4. Zhang D, Wang J, Zhang Q, et al. Cerebral venous thrombosis in spontaneous intracranial hypotension: a report on 4 cases and a review of the literature. *Headache* **58**: 1244-1255, 2018.
  5. Mokri B, Atkinson JL, Piepgras DG. Absent headache despite CSF volume depletion (intracranial hypotension). *Neurology* **55**: 1722-1724, 2000.
  6. Matsumura R, Futamura N, Fujimoto Y, et al. Spinocerebellar ataxia type 6. Molecular and clinical features of 35 Japanese patients including one homozygous for the CAG repeat expansion. *Neurology* **49**: 1238-1243, 1997.
  7. Fonteyn EM, Schmitz-Hubsch T, Verstappen CC, et al. Prospective analysis of falls in dominant ataxias. *Eur Neurol* **69**: 53-57, 2013.
  8. Schievink WI, Maya MM, Louy C, et al. Diagnostic criteria for spontaneous spinal CSF leaks and intracranial hypotension. *AJNR Am J Neuroradiol* **29**: 853-856, 2008.
  9. Sakurai K, Kanoto M, Nakagawa M, et al. Dinosaur tail sign: a useful spinal MRI finding indicative of cerebrospinal fluid leakage. *Headache* **57**: 917-925, 2017.
  10. Ilyas A, Chen CJ, Raper DM, et al. Endovascular mechanical thrombectomy for cerebral venous sinus thrombosis: a systematic review. *J Neurointerv Surg* **9**: 1086-1092, 2017.
  11. Ferro JM, Bousser MG, Canhao P, et al. European Stroke Organization guideline for the diagnosis and treatment of cerebral venous thrombosis-endorsed by the European Academy of Neurology. *Eur Stroke J* **2**: 195-221, 2017.
  12. Rao SK, Ibrahim M, Hanni CM, et al. Apixaban for the treatment of cerebral venous thrombosis: a case series. *J Neurol Sci* **381**: 312-320, 2017.
  13. Granger CB, Alexander JH, McMurray JJ, et al. Apixaban versus warfarin in patients with atrial fibrillation. *N Engl J Med* **365**: 981-992, 2011.

The Internal Medicine is an Open Access journal distributed under the Creative Commons Attribution-NonCommercial-NoDerivatives 4.0 International License. To view the details of this license, please visit (<https://creativecommons.org/licenses/by-nc-nd/4.0/>).