

HOSTED BY



ELSEVIER

Contents lists available at ScienceDirect

# Chinese Journal of Traumatology

journal homepage: <http://www.elsevier.com/locate/CJTEE>

## Case report

# Extended anterolateral thigh pedicled flap for reconstruction of trochanteric and gluteal defects: A new & innovative approach for reconstruction

G.I. Nambi <sup>a</sup>, Abhijeet Ashok Salunke <sup>b,\*</sup>, Szeryn Chung <sup>c</sup>, K.S. Raj Kumar <sup>d</sup>, Vikram Anil Chaudhari <sup>e</sup>, Anant Dattaray Dhanwate <sup>f</sup>

<sup>a</sup> Plastic & Reconstructive Microvascular Services, Kovai Medical Center & Hospital, Tamilnadu 641014, India

<sup>b</sup> Department of Orthopedics, Pramukswami Medical College, Gujrat, India

<sup>c</sup> Department of Hand Surgery, Singapore General Hospital, Singapore

<sup>d</sup> General & Laparoscopic Surgical Services, Kovai Medical Center & Hospital, Tamilnadu 641014, India

<sup>e</sup> Division of G.I. Surgical Oncology, Tata Memorial Hospital, Mumbai, India

<sup>f</sup> Department of Anatomy, Government Medical College, Aurangabad, India

## ARTICLE INFO

### Article history:

Received 17 January 2015

Received in revised form

13 April 2015

Accepted 13 April 2015

Available online 17 December 2015

### Keywords:

Anterolateral thigh flap

Lateral circumflex femoral artery

Gluteal defect

Trochanteric defect

## ABSTRACT

Descending branch of the lateral circumflex femoral artery (LCFA) is commonly used pedicle for anterolateral thigh (ALT) flap. Oblique branch of LCFA is an alternative pedicle that can be used in microvascular surgery. According to review of literature and to the best of our knowledge we could not find the use of oblique branch of LCFA as a pedicle of the ALT flap in regional soft tissue reconstruction. Here we presented a case of a 55-year-old man sustaining soft tissue injury and wound over the left trochanteric and gluteal region following a road traffic accident, who was treated by the use of extended ALT pedicle flap with oblique branch of LCFA as the pedicle for reconstruction of soft tissue defect in trochanteric and gluteal regions with successful outcome.

© 2015 Daping Hospital and the Research Institute of Surgery of the Third Military Medical University.

Production and hosting by Elsevier B.V. This is an open access article under the CC BY-NC-ND license

(<http://creativecommons.org/licenses/by-nc-nd/4.0/>).

## Introduction

The pedicled anterolateral thigh (ALT) flap is a common flap used for soft tissue cover and reconstruction of defects in the lower abdomen, pelvic and thigh region.<sup>1–5</sup> The free ALT flap is a useful flap for soft tissue reconstruction in various regions of body. Descending branch of the lateral circumflex femoral artery (LCFA) is commonly used pedicle for anterolateral thigh flap.<sup>2–4</sup> Oblique branch of LCFA is an alternative pedicle that can be used in microvascular surgery. According to review of literature and best of our knowledge we could not find use of oblique branch of LCFA as a

pedicle of the ALT flap in regional soft tissue reconstruction. This method is a new and innovative approach for reconstruction of gluteal and trochanteric defects following trauma, injury and infection. We present the use of extended ALT pedicle flap with oblique branch of LCFA as the pedicle for reconstruction of soft tissue defect in trochanteric and gluteal regions with successful outcome.

## Case report

A 55-year-old man presented to our center with extensive raw areas over the left trochanteric and gluteal regions. Patient was treated for psoriasis skin lesions for a long duration. He had sustained soft tissue injury and wound over the left trochanteric and gluteal region following a road traffic accident, and was treated with repeated debridement surgery to excise non-viable soft tissues areas.

\* Corresponding author.

E-mail address: [drabhijeetsalunke@gmail.com](mailto:drabhijeetsalunke@gmail.com) (A.A. Salunke).

Peer review under responsibility of Daping Hospital and the Research Institute of Surgery of the Third Military Medical University.

On examination, there was an extensive soft tissue defect involving the left trochanteric and gluteal region and a part of the hip and proximal femur were exposed (Fig. 1). Surgical cover of the entire defect with an extended ALT flap from the ipsilateral thigh was planned. Preoperative color Doppler of the ALT perforators revealed good signals. A flap measuring 30 cm × 10 cm was marked and raised. While raising the flap it was noticed that the LCFA had an oblique branch which had a fasciocutaneous course while the descending branch had an intra-muscular course through the vastus lateralis (Fig. 2). Therefore a decision was made to raise the flap based on the oblique branch of LCFA pedicle as a fasciocutaneous flap. The defect was covered completely with the flap and the flap donor site was covered with split skin graft. Postoperatively there was a minimal flap tip necrosis and focal areas of skin graft loss healed completely (Fig. 3). Patient was on regular follow-up and was able to perform activities of daily living and had a full range of movement of hip and knee joint.

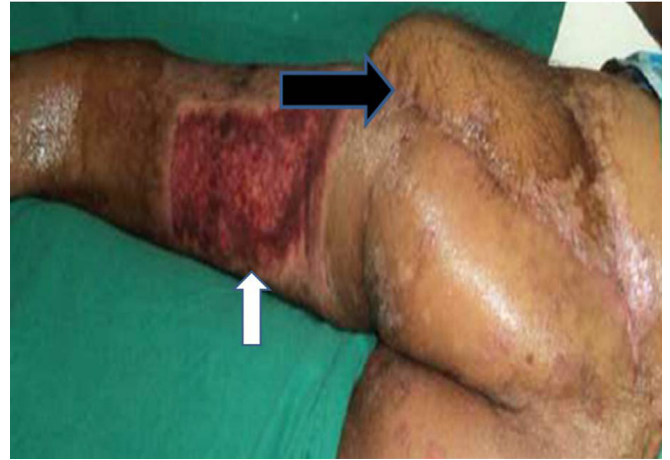

Fig. 3. Postoperative image of the flap settled well into the trochanteric and gluteal defect (black arrow) & skin graft site healed well (white arrow).

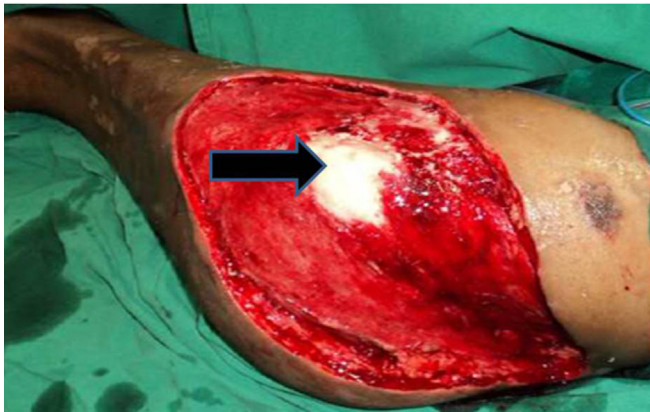

Fig. 1. Extensive soft tissue defect over the left trochanteric & gluteal region (black arrow over exposed greater trochanteric bone).

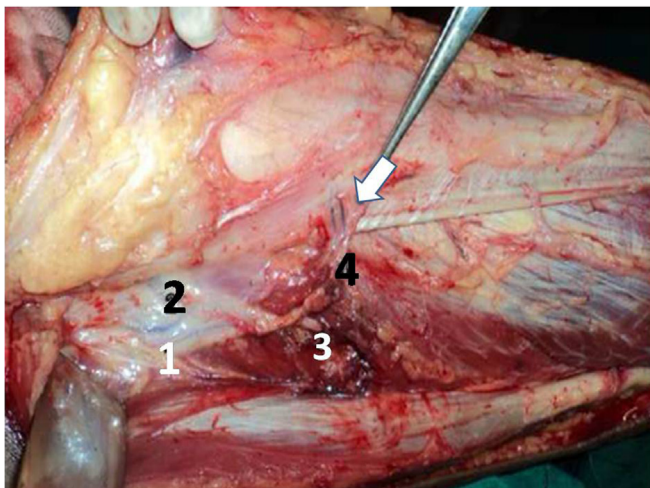


Fig. 2. Arterial pattern of the LCFA: (1) the LCFA, (2) the transverse branch of the LCFA, (3) the descending branch traversing in to the vastus lateralis muscle, (4) the oblique branch supplying the skin (white arrow).

## Discussion

Several modifications of conventional ALT flap are used for covering soft tissue defects. The extended ALT flaps are the flap with size measuring more than 240 cm<sup>2</sup> and are used as free flaps in reconstruction of complex oncological and posttraumatic defects.<sup>3</sup> These pedicle flaps are used in the reconstruction of complex regional soft tissue defects around pelvic girdle.<sup>1–5</sup> According to review of literature, the descending branch of the LCFA is used as the source vessel for the pedicled ALT flap. Oblique branch of the LCFA is described as the alternative vascular pedicle of the ALT flap.<sup>2</sup> The oblique branch arises as a separate branch of the LCFA or from the descending or transverse branches of the LCFA. It can have a septocutaneous or musculocutaneous course and can be used to design a second free flap (twin free flap) from the ipsilateral thigh.<sup>2,4</sup> In current study there was wound over left hip and greater trochanter of the femur and surrounding wound had healthy granulation tissue.

The treatment options were:

1. To cover the raw area with split skin grafts and use a small ALT pedicle flap to cover the exposed bone prominence areas or
2. To cover the entire defect with a single extended ALT pedicle flap and cover the flap donor site with split skin grafts.

Use of only split skin grafts in the weight bearing regions are prone for repeated breakdown leading to ulcerations. The common problem in both the treatment options was requirement of large split skin graft to cover the primary or the secondary defect. The second option was selected because majority of the raw area was over two distinctive weight bearing regions i.e. the greater trochanter in the lateral recumbent position and gluteal in the sitting position. An extended ALT pedicle flap provides a good tissue with proper contour match without the morbidities associated with micro surgery.<sup>1–7</sup> The flap donor site can be covered well with split skin graft.

The presence of an oblique branch of LCFA was recognized and was used as a pedicle for fasciocutaneous flap and the vastus lateralis muscle and the descending branch of the LCFA were preserved. In current case we had used an ALT flap of larger flap size and the pedicle was formed by the oblique branch of the LCFA and the conventional descending branch was not used. This avoided the unnecessary sacrifice of the vastus lateralis muscle and also excess

bulk of the flap enabling a good reconstruction of two (trochanteric & gluteal) anatomical regions.

The use of single fasciocutaneous flap helped for preserving the component muscle (vastus lateralis) with intact pedicle (descending branch of LCFA) for future requirement as free muscle flap.

So we suggest the use of this new and innovative approach for reconstruction of gluteal and trochanteric defects following trauma, injury and infection.

## References

1. Friji MT, Suri MP, Shankhdhar VK, et al. Pedicled anterolateral thigh flap: a versatile flap for difficult regional soft tissue reconstruction. *Ann Plast Surg.* 2010;64:458–461.
2. Wong CH, Wei FC, Fu B, et al. Alternative vascular pedicle of the anterolateral thigh flap: the oblique branch of the lateral circumflex femoral artery. *Plast Reconstr Surg.* 2009;123:571–577.
3. Yadav PS, Ahmad QG, Shankhdhar VK, et al. Reconstruction of complex thoraco-abdominal defects with extended anterolateral thigh flap. *Indian J Plast Surg.* 2010;43:158–165.
4. Ahmad QG, Yadav PS, Shankhdhar VK, et al. Anterolateral thigh twin free flaps from a single donor site – a modification based on the oblique branch of the lateral circumflex femoral artery. *Indian J Surg.* 2014;76:165–168.
5. Salunke AA, Nambi GI, Manoharan A. Osteomyelitis of the pubic bone with vesicocutaneous – vesicovaginal fistula: a delayed complication of post-cervical cancer radiotherapy. *Niger Med J.* 2014;55:83–85.
6. Dumanian GA. Abdominal wall reconstruction. In: Thorne CH, Beasley RW, Aston SJ, et al., eds. *Grabb and Smith Plastic Surgery*. Philadelphia: WB Saunders; 2007:665–669.
7. Rohrich RJ, Lowe JB, Hackney FL, et al. An algorithm for abdominal wall reconstruction. *Plast Reconstr Surg.* 2000;105:202.