



Review Article

Postoperative complications with cryotherapy in bone tumors

Clark Chen^{a,*}, John Garlich^b, Katie Vincent^c, Earl Brien^b^a School of Medicine, University of Miami, Miami, FL 33136, United States^b Department of Orthopaedic Surgery, Cedars Sinai Medical Center, Los Angeles, CA 90048, United States^c Brigham Young University, Provo, UT 84602, United States

ARTICLE INFO

Keywords:

Cryotherapy
 Cryoablation
 Benign aggressive bone tumor
 Liquid nitrogen
 Complication
 Curettage

ABSTRACT

The technique of cryosurgery has been used to control local recurrence in a variety of benign and malignant bone tumors. Early studies revealed significant complication rates (25%) that included fracture, infection, and soft tissue injury. Our method of cryosurgery has yielded excellent tumor control with improved complication rates. The objective of this study is to determine the characteristics of postoperative complications after pouring liquid nitrogen into curettaged bone defects, and to review our current indications and surgical technique in bone tumor management.

We reviewed charts in over 200 patients who received cryoablation for bone tumors from 1994 to 2015. Imaging studies were evaluated in all patients diagnosed with a complication. All patients receiving cryotherapy had soft tissue management intraoperatively that included warm saline directed to the structures. Liquid nitrogen was poured into the bone defect and in some cases, additional spraying with a cryogun into the defect was performed.

The majority of cryotherapy was used in cases of active or aggressive benign tumors. Our low complication rate of 2.34% included 1 post-operative fracture, 3 infection, and 1 paraesthesia. Bone graft or cementation was used in the majority of patients, all of which fully incorporated.

Cryoablation is an excellent form of adjuvant therapy for active and aggressive benign tumors and may be used in malignant tumors as well. Soft tissue protection is critical to avoid skin necrosis and wound breakdown. We recommend the use of cryotherapy in active and aggressive bone tumors as an adjuvant treatment prior to bone grafting or cementation.

1. Introduction

The technique of cryosurgery has been used to control local recurrence in a variety of benign and malignant bone tumors. Cryotherapy was initially instituted in seventeenth century originally by the Greeks, and adapted for dermatological use in 1850 for its anesthetic and vasoconstriction effects [1]. Since then, cryotherapy was put toward other uses in neurosurgery, gynecology, and eventually orthopaedics. The first reported use of cryosurgery for metastatic bone tumors was by Marcove who described an open system “direct pour” method using liquid nitrogen to aggressively fill the tumor cavity several times [2]. Repeated exposure of the curettaged area to extreme temperatures below 20 °C created ice crystal formations that were later shown to produce osmotic disturbances and bone necrosis [3].

The initial study with cryotherapy by Marcove revealed a high complication rate (51%) that included fracture, skin necrosis, infection, and neuropraxia [4]. The use of curettage alone was shown to be associated with a high recurrence rate but minimized complications

[5]. The high complication rate with cryotherapy led to other adjuvant modalities such as phenol, peroxide, and aggressive burring in the treatment of bone tumors. However, refinement and experience with the technique helped reduce complication rates over time [6]. Recent studies have revealed that cryosurgery could be a recommended treatment for benign-aggressive and malignant bone tumors with little bone loss or long standing functional complications [3,7].

The purpose of this study was to describe our surgical technique used in cryoablation and to evaluate the complication rate using cryosurgery as an adjuvant in treating bone tumors.

2. Materials and methods

We retrospectively reviewed charts in patients who had been treated with cryoablation between 1994 and 2015. Follow up varied with the tumor type or until complete healing was seen radiographically. 5 patients had three freeze/thaws 207 patients had two freeze thaws and 2 patients had cryoprobe treatment. Surgical technique using

* Corresponding author.

E-mail address: cjc217@med.miami.edu (C. Chen).

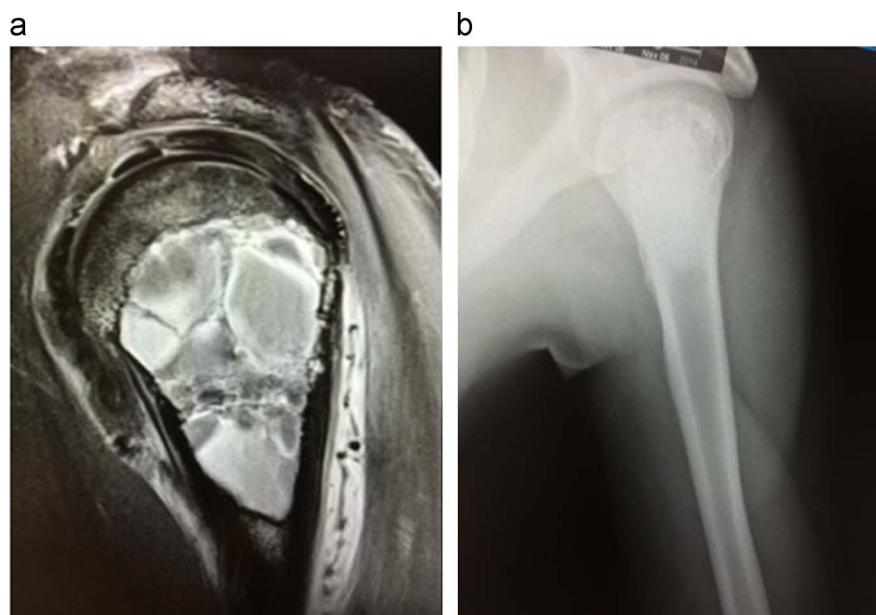


Fig. 1. Aggressive chondroblastoma with an aneurysmal bone cyst of the proximal humerus seen on MRI treated with curettage, cryotherapy and bone graft substitute. a) Initial evaluation; b) Post-operative outcome.

the freeze/thaw technique included initial extensive curettage of the lesion through a 1.5–3.5 cm defect in the bone made with an 8 mm drill and followed by increasing the size of the cortical defect with curettes. The tumor was excised using a combination of angled curettes and large bore Frazier tip suction under fluoroscopic guidance. A high speed burr was not used. Once the lesion was removed, warming the overlying tissue prior to pouring in the liquid nitrogen was performed. The liquid nitrogen was poured into the defect through a metal funnel under direct vision. If the liquid nitrogen began freezing the overlying tissue, warm saline would be judiciously applied to prevent freezing damage to the skin, subcutaneous tissue and in some cases the muscle. After the liquid nitrogen was poured into the defect, the limb would be manipulated to achieve maximum freeze throughout the defect. Once the intralesional ice ball thawed, a second and or third freeze thaw cycle would be repeated. If a portion of the defect could not be adequately frozen, additional freezing using a cryogun spray would be administered. The defect was then filled with either bone grafting, bone graft substitute, or polymethyl methacrylate (PMMA) cement to return mechanical support (Fig. 1). Tourniquet was used if the tumor surgery was distal to the proximal humerus and femur.

A second technique implemented included the use of cryoprobe. The tumor size was evaluated, the size and number of cryoprobes were determined to achieve a complete freeze, and the probes were inserted percutaneously under fluoroscopic guidance. Two freeze thaws were performed and the probes were removed.

3. Results

There were 232 cases where cryotherapy was used in 214 patients between 1994 and 2015. There were 96 male and 118 female. The age of patients ranged from 4 to 95. All patients had undergone imaging studies for evaluation. A majority of cases consisted of active or aggressive benign tumors. The most common tumor types included enchondroma (75), giant cell tumor (42), aneurysmal bone cyst (20 primary); (15 secondary), metastatic disease (19) and chondroblastoma (16). Complications included superficial infections (2), deep infection (1), fracture (1) and paraesthesia (1) (Table 1). 12 cases of local recurrence requiring additional surgery was noted primarily in aggressive giant cell tumors and chondroblastoma with secondary ABC. A majority of patients received bone graft or PMMA cementation, with all

Table 1

Patients presented with the following subtypes of bone tumor. Secondary Aneurysmal bone cyst present in 6 chondroblastoma, 3 fibrous dysplasia, 6 giant cell tumor and were not counted as separate cases,.

Types of Tumor included in current study	
Chondroblastoma	16
Chondromyxoid Fibroma	7
Osteoblastoma	1
Nonossifying Fibroma	8
Enchondroma	75
Chondrosarcoma (Low Grade)	1
Aneurysmal Bone Cyst, Primary	20
Giant Cell Tumor	42
Unicameral Bone Cyst	7
Lipoma	2
Fibrous Dysplasia	3
Eosinophilic Granuloma	1
Other Metastatic	19
Malignant Tumor	9
Other	3
Total Patients	214
Repeat Surgeries	18
Aneurysmal Bone Cyst, Secondary	15
Total Cases	232

bone fillers incorporating. There were no restrictions postoperatively in our cases involving benign tumors.

4. Discussion

The common local adjuvants with curettage include phenol, cryotherapy, laser, and cement. Cryotherapy agents include carbon dioxide and liquid nitrogen. However, liquid nitrogen is favored for its rapid freezing capabilities (-196°C) for a potentially large area necrosis.

Previous studies show that cryosurgery may be as effective as wide resection for therapeutic treatment of benign-aggressive, low grade, and malignant bone tumors [2,6,8]. A slow freeze and quick thaw can preserve cells, but a quick freeze and slow thaw is repeated to induce cell death [9,10]. Exposing the curettaged area to a quick freeze below -20°C creates ice crystals that disrupt cell osmolality which leads to apoptosis [11,12]. A minimum of 2 freeze thaw cycles is needed to

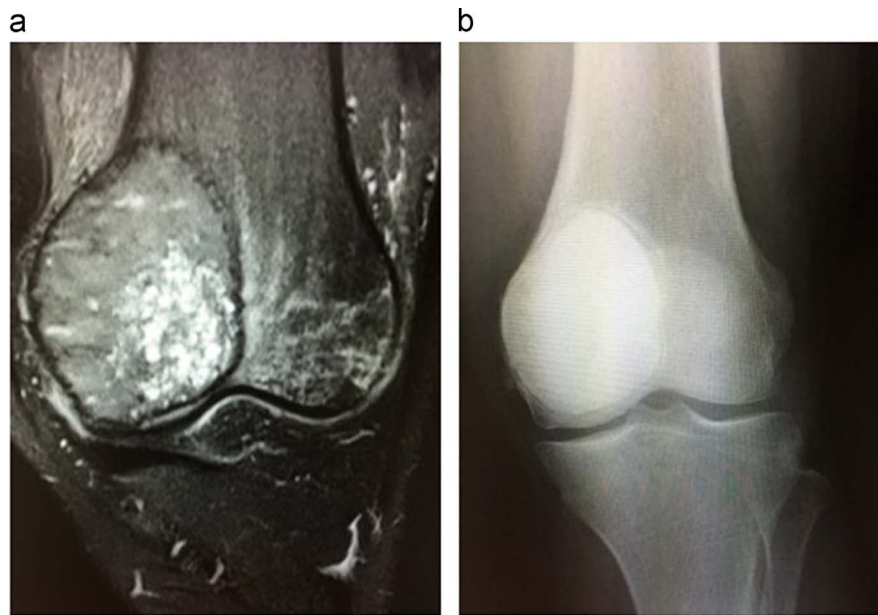


Fig. 2. Giant cell tumor of the distal femur seen on MRI characterized by a heterogeneous, epiphyseal metaphyseal mass expanding the medial femoral metaphysis; Plain x-ray reveals cementation after curettage and cryoablation using two freeze thaws. a) Initial evaluation; b) Post-operative outcome.

achieve a level of necrosis comparable to other adjuvant therapies, with 3 cycles having no significant difference in apoptosis [13,14]. However, choosing to use excessive amounts of freeze thaw cycles has been associated with higher fracture rates and non-unions [15]. Therefore, two freeze cycles appears to balance necrosis while limiting complications. Articular cartilage adjacent to the freezing zone commonly seen in epiphyseal tumors such as giant cell tumor and chondroblastoma have been theoretical concerns during the freezing process [16,17], however we have not seen this complication (Fig. 2).

Cryotherapy has several limitations with large, high-grade malignant bone tumors that involve soft tissue structures. Application of liquid nitrogen directly into the soft tissues can cause cellular damage to adjacent muscles and neurovasculature structures. A cryoprobe has been utilized to deliver several freeze thaw cycles intralesionally before soft tissue tumor resection as a therapeutic alternative, however contamination and inability to kill tumor cells at the periphery remain a significant concern [18,19]. Such closed techniques was first used by Gage et al. to treat malignant soft-tissue lesions by circulating liquid nitrogen through tubes [20]. The advancements in this technology created the minimally invasive argon gas probe to create apoptosis by developing an ice ball structure intralesionally [21]. Other recent described techniques involve filling the tumor cavity with a gel medium that can evenly cool an irregularly shaped cavity [22].

Many authors have used cryotherapy in tumors that have the potential to recur (Table 2). However, there has not been widespread acceptance of this form of adjuvant treatment because of the known complications. Studies revealed significant early complications including fracture, infection, skin necrosis, neuropraxia, embolism, and wound healing [4]. Postoperative cryosurgery fracture is common because curettage creates a large deformity in the bone [23,24]. Extensive curettage and cryosurgery improves the therapeutic effect but increases the chance of postoperative fracture. To exacerbate the situation, bone necrosis from cryotherapy delays reossification, which was shown in a dog model [25]. We had one fracture complication, however, it occurred in a rock climber 3 weeks postoperatively despite being instructed to avoid any weight bearing on the extremity for 12–16 weeks after we used bone graft substitute to fill the defect. Some have addressed fracture complications by using PMMA and internal fixation after cryosurgery [25,26]. Regardless, larger lesions particularly near weight bearing joints associated with soft tissue extension,

are at high risk of fracture [16].

Cryotherapy related soft tissue injury usually occurs within a few weeks postoperatively. Skin necrosis is a significant complication if freezing of the superficial surface occurs. Constant irrigation of the adjacent tissues with warm saline reduces the chance of skin necrosis. Our rate of infection was (1.40%) which was comparable to previously reported rates ranging of 0–8% [4,11,27]. One controversial topic is tourniquet use. There have been studies that argue for tourniquet use to decrease circulation and increase bone necrosis [4]. Opponents believe that tourniquets decrease skin and nerve vascularization which can lead to skin necrosis or neuropraxia [28]. However, we did not find an increased risk of soft tissue complications when using the tourniquet.

Prophylactic antibiotics were given in all cases in a similar manner to other tumor surgeries and we did not find an increase in infections using cryoablation. Transient neuropraxias secondary to cryosurgery is well documented in adjacent nerves near the cryosurgery treatment site [10,29]. One patient had paraesthesia that may have been a result of the cryoablation. This is a more common complication when cryotherapy is used in the sacrum, and this was well described previously [30]. We had no nitrogen gas embolus, a complication that has been described previously [31,32]. Our technique always allowed nitrogen gas to displace into the air and was never sealed manually or by the soft tissues during the freezing process.

Our indications for cryotherapy include benign bone tumors and metastatic disease. We preferred curettage prior to cryotherapy using fluoroscopic image as described in the methodology. Neither high speed burr nor pulse irrigation was ever used because of the theoretical concern of pushing tumor cells into the microcirculation and potentially spreading the tumor systemically. Interestingly, no cases of metastasizing giant cell tumor or chondroblastoma occurred in our patients.

Controversy on whether to use cryotherapy in low grade chondrosarcoma persists because of the complex, inconsistent pathologic diagnoses given to the intramedullary hyaline cartilaginous tumors. One institution commonly diagnosed the “grade ½ chondrosarcoma” and successfully treated the tumors with curettage and adjuvant therapy. However, upon review, pathologists diagnosed them as enchondroma. Similarly, we have seen inconsistent pathologic diagnoses on a case by case basis from enchondroma, grade ½ chondrosarcoma, and grade I chondrosarcoma from different institutions. The literature has clearly made a distinction that intralesional surgery with

Table 2

Complications summary comparison with breakdown of fractures, infections, joint degeneration, neuropraxia, and skin necrosis. Patients with paraesthesia were grouped under neuropraxia. Other complications seen in previous studies that did not fit into a previous category included.

Review on complications rate in postoperative cryotherapy patients								
Author	Cases	Fractures	Infection	Jt. Degen.	Neuropraxia	Skin Necrosis	Other	Rates
Abouafia et al. 1994 [19]	9	0	0	0	0	0	0	0.0%
Ahlmann et al. 2006 [7]	10	0	0	0	0	0	^a 1	10.0%
El-Moatasem et al. 2015 [35]	6	0	0	0	0	0	0	0.0%
Jacobs & Clemency 1985 [12]	12	6	0	0	0	0	0	50.0%
Kollender et al. 2003 [3]	14	0	0	0	1	0	^b 1	14.3%
Lim et al. 2005 [36]	16	0	0	0	0	0	0	0.0%
Malawer & Dunham 1991 [26]	25	2	0	0	0	1	^c 1	16.0%
Malawer et al. 1999 [11]	102	6	0	2	0	3	0	10.8%
Marcove et al. 1977 [23]	18	7	0	3	4	0	0	77.8%
Marcove et al. 1978 + 1973 [4]	52	13	8	2	4	4	0	59.6%
Marcove et al. 1994 [30]	7	0	2	0	0	2	^d 1	71.4%
Marcove et al. 1995 [37]	51	5	0	1	1	1	0	15.7%
Mashhour & Rahman 2014 [38]	14	0	0	2	0	1	0	21.4%
Mohler et al. 2010 [39]	46	3	0	0	0	0	0	6.5%
Oeseburg et al. 1978 [40]	5	1	0	0	0	0	0	20.0%
Peeters et al. 2009 [41]	80	1	1	0	3	0	0	6.3%
Pritsch et al. 2007 [14]	60	10	0	0	0	0	0	16.7%
Schreuder et al. 1997 [15]	26	0	2	0	1	0	0	0.0%
Schreuder et al. 1997 [28]	42	2	2	0	1	0	0	11.9%
Sheth et al. 1995 [42]	26	0	1	3	3	1	0	30.8%
Souna et al. 2010 [27]	15	0	0	0	0	0	0	0.0%
van der Geest et al. 2008 [6]	123	18	3	0	3	0	^e 1	20.3%
Current Study	232	1	3	0	1	0	0	2.2%

^a 1 synovial fistula.
^b 1 rectal fistula.
^c 1 cerebral spinal fluid leak.
^d 1 hardware malfunction.
^e 1 nitrogen gas emboli.

or without cryotherapy for pelvic low grade chondrosarcoma should not be used because of the unacceptable high local recurrence rate and the potential of the tumor to step up in grade and metastasize to the lungs [33,34]. The authors strongly believe that wide en bloc resection of grade I chondrosarcomas of flat bones should be the treatment of choice, not intralesional surgery with adjuvant cryoablation.

In summary, there have been several techniques describing the use of cryotherapy in bone tumors. The authors have used both the pouring technique and cryoprobes in the management of bone tumors. With this technique, our results reveal an acceptable complication rate (2.34%) with the use of cryotherapy (Table 2). We believe that the technical process in which cryotherapy is used impacts the complication rate and possibly the local recurrence rate as well. Nevertheless, our method of cryosurgery has yielded excellent tumor control with relatively low postoperative complication rates despite the limitations of this retrospective study and variability of tumor type.

Funding

This research did not receive any specific grant from funding agencies in the public, commercial, or not-for-profit sectors.

Acknowledgements

None.

References

[1] J.M. Arnott, Practical illustrations of the remedial efficiency of a very low or anesthetic temperature in cancer, *Lancet* 2 (1850) 257–316.
 [2] R.C. Marcove, T.R. Miller, Treatment of primary and metastatic bone tumors by cryosurgery, *J. Am. Med. Assoc.* 207 (1969) 1890–1894.
 [3] Y. Kollender, I. Meller, J. Bickels, G. Flusser, J. Issakov, O. Merimsky, et al., Role of adjuvant cryosurgery in intralesional treatment of sacral tumors, *Cancer* 97 (2003) 2830–2838.
 [4] R.C. Marcove, L.D. Weis, M.R. Vaghaiwalla, R. Pearson, A.G. Huvos, Cryosurgery in

the treatment of giant cell tumors of bone. A report of 52 consecutive cases, *Cancer* 41 (1978) 957–969.
 [5] M.R. Bapat, R.S. Narlawar, M.K. Pimple, P.B. Bhosale, Giant cell tumour of talar body, *J. Postgrad. Med.* 46 (2000) 110–111.
 [6] I.C. van der Geest, M.H. de Valk, J.W. de Rooy, M. Pruszczynski, R.P. Veth, H.W. Schreuder, Oncological and functional results of cryosurgical therapy of enchondromas and chondrosarcomas grade 1, *J. Surg. Oncol.* 98 (2008) 421–426.
 [7] E.R. Ahlmann, L.R. Menendez, A.N. Fedenko, T. Learch, Influence of cryosurgery on treatment outcome of low-grade chondrosarcoma, *Clin. Orthop. Relat. Res.* 451 (2006) 201–207.
 [8] H.W. Schreuder, R.P. Veth, M. Pruszczynski, J.A. Lemmens, H.S. Koops, W.M. Molenaar, Aneurysmal bone cysts treated by curettage, cryotherapy and bone grafting, *J. Bone Jt. Surg. Br. Vol.* 79 (1997) 20–25.
 [9] R.C. Marcove, R.C. Searfoss, W.F. Whitmore, H. Grabstald, Cryosurgery in the treatment of bone metastases from renal cell carcinoma, *Clin. Orthop. Relat. Res.* (1977) 220–227.
 [10] H.W. Schreuder, J. van Egmond, H.B. van Beem, R.P. Veth, Monitoring during cryosurgery of bone tumors, *J. Surg. Oncol.* 65 (1997) 40–45.
 [11] A.A. Gage, J. Baust, Mechanisms of tissue injury in cryosurgery, *Cryobiology* 37 (1998) 171–186.
 [12] M.M. Malawer, J. Bickels, I. Meller, R.G. Buch, R.M. Henshaw, Y. Kollender, Cryosurgery in the treatment of giant cell tumor. A long-term followup study, *Clin. Orthop. Relat. Res.* (1999) 176–188.
 [13] P.A. Jacobs, R.E. Clemency Jr., The closed cryosurgical treatment of giant cell tumor, *Clin. Orthop. Relat. Res.* (1985) 149–158.
 [14] D. Robinson, M. Yassin, Z. Nevo, Cryotherapy of musculoskeletal tumors—from basic science to clinical results, *Technol. Cancer Res. Treat.* 3 (2004) 371–375.
 [15] T. Pritsch, J. Bickels, C.C. Wu, H.M. Squires, M.M. Malawer, The risk for fractures after curettage and cryosurgery around the knee, *Clin. Orthop. Relat. Res.* 458 (2007) 159–167.
 [16] H. Nishida, T. Shirai, K. Hayashi, A. Takeuchi, Y. Tanzawa, A. Mizokami, et al., Cryotreatment against metastatic renal cell bone tumour reduced multiple lung metastases, *Anticancer Res.* 31 (2011) 2927–2930.
 [17] A.J. Abouafia, D.H. Rosenbaum, L. Sicard-Rosenbaum, J.S. Jelinek, M.M. Malawer, Treatment of large subchondral tumors of the knee with cryosurgery and composite reconstruction, *Clin. Orthop. Relat. Res.* (1994) 189–199.
 [18] J. Bickels, I. Meller, B.M. Shmookler, M.M. Malawer, The role and biology of cryosurgery in the treatment of bone tumors. A review, *Acta Orthop. Scand.* 70 (1999) 308–315.
 [19] J. Baust, A.A. Gage, H. Ma, C.M. Zhang, Minimally invasive cryosurgery—technological advances, *Cryobiology* 34 (1997) 373–384.
 [20] A.A. Gage, G.W. Greene Jr., M.E. Neiders, F.G. Emmings, Freezing bone without excision. An experimental study of bone-cell destruction and manner of regrowth in dogs, *J. Am. Med. Assoc.* 196 (1966) 770–774.
 [21] J. Bickels, Y. Kollender, O. Merimsky, J. Isaakov, R. Petyan-Brand, I. Meller, Closed

- argon-based cryoablation of bone tumours, *J. Bone Jt. Surg. Br. Vol.* 86 (2004) 714–718.
- [22] J. Bickels, M. Malawer, J. Wittig, *Operative Techniques in Orthopaedic Surgical Oncology*, Wolters Kluwer Health/Lippincott Williams & Wilkins, Philadelphia, 2012.
- [23] R.C. Marcove, P.B. Stovell, A.G. Huvos, P.G. Bullough, The use of cryosurgery in the treatment of low and medium grade chondrosarcoma. A Prelim. Report. *Clin. Orthop. Relat. Res.* (1977) 147–156.
- [24] J.J. Eckardt, T.J. Grogan, Giant cell tumor of bone, *Clin. Orthop. Relat. Res.* (1986) 45–58.
- [25] M.M. Malawer, M.R. Marks, D. McChesney, M. Piasio, S.F. Gunther, B.M. Schmookler, The effect of cryosurgery and polymethylmethacrylate in dogs with experimental bone defects comparable to tumor defects, *Clin. Orthop. Relat. Res.* (1988) 299–310.
- [26] M.M. Malawer, W. Dunham, Cryosurgery and acrylic cementation as surgical adjuncts in the treatment of aggressive (benign) bone tumors. Analysis of 25 patients below the age of 21, *Clin. Orthop. Relat. Res.* (1991) 42–57.
- [27] B.S. Souna, N. Belot, H. Duval, F. Langlais, H. Thomazeau, No recurrences in selected patients after curettage with cryotherapy for grade I chondrosarcomas, *Clin. Orthop. Relat. Res.* 468 (2010) 1956–1962.
- [28] H.W. Schreuder, E.U. Conrad 3rd, J.D. Bruckner, A.T. Howlett, L.S. Sorensen, Treatment of simple bone cysts in children with curettage and cryosurgery, *J. Pediatr. Orthop.* 17 (1997) 814–820.
- [29] L.R. Menendez, M.S. Tan, M.T. Kiyabu, S.P. Chawla, Cryosurgical ablation of soft tissue sarcomas: a phase I trial of feasibility and safety, *Cancer* 86 (1999) 50–57.
- [30] R.C. Marcove, D.S. Sheth, E.W. Brien, A.G. Huvos, J.H. Healey, Conservative surgery for giant cell tumors of the sacrum. The role of cryosurgery as a supplement to curettage and partial excision, *Cancer* 74 (1994) 1253–1260.
- [31] R.C. Marcove, A 17-year review of cryosurgery in the treatment of bone tumors, *Clin. Orthop. Relat. Res.* (1982) 231–234.
- [32] H.W. Schreuder, H.B. van Beem, R.P. Veth, Venous gas embolism during cryosurgery for bone tumors, *J. Surg. Oncol.* 60 (1995) 196–200.
- [33] M. De Paolis, A. Biazzo, C. Romagnoli, N. Ali, S. Giannini, D.M. Donati, The use of iliac stem prosthesis for acetabular defects following resections for periacetabular tumors, *Sci. World J.* (2013), <http://dx.doi.org/10.1155/2013/717031>.
- [34] K. Yokota, A. Sakamoto, Y. Matsumoto, et al., Clinical outcome for patients with dedifferentiated chondrosarcoma: a report of 9 cases at a single institute, *J. Orthop. Surg. Res.* 7 (2012) 38, <http://dx.doi.org/10.1186/1749-799X-7-38>.
- [35] H.B. Oeseburg, C.W. Rogge, H. Schraffordt Koops, J. Oldhoff, Cryosurgical treatment of aneurysmal bone cysts, *J. Surg. Oncol.* 10 (1978) 9–20.
- [36] R.C. Marcove, D.S. Sheth, S. Takemoto, J.H. Healey, The treatment of aneurysmal bone cyst, *Clin. Orthop. Relat. Res.* (1995) 157–163.
- [37] D.S. Sheth, J.H. Healey, M. Sobel, J.M. Lane, R.C. Marcove, Giant cell tumor of the distal radius, *J. Hand Surg.* 20 (1995) 432–440.
- [38] Y.W. Lim, M.H. Tan, Treatment of benign giant cell tumors of bone in Singapore, *Ann. Acad. Med.* 34 (2005) 235–237.
- [39] S.P. Peeters, I.C. Van der Geest, J.W. de Rooy, R.P. Veth, H.W. Schreuder, Aneurysmal bone cyst: the role of cryosurgery as local adjuvant treatment, *J. Surg. Oncol.* 100 (2009) 719–724.
- [40] D.G. Mohler, R. Chiu, D.A. McCall, R.S. Avedian, Curettage and cryosurgery for low-grade cartilage tumors is associated with low recurrence and high function, *Clin. Orthop. Relat. Res.* 468 (2010) 2765–2773.
- [41] M.A. Mashhour, M. Abdel Rahman, Lower recurrence rate in chondroblastoma using extended curettage and cryosurgery, *Int. Orthop.* 38 (2014) 1019–1024.
- [42] H.M. El-Moatasem el, M. Abdel-Rahman, M.A. Eid, Extended curettage and adjuvant therapy for benign tumors of the talus, *Foot* 25 (2015) 79–83.