



Received: 2014.07.21
Accepted: 2014.09.02
Published: 2015.01.16

Authors' Contribution:

- A** Study Design
- B** Data Collection
- C** Statistical Analysis
- D** Data Interpretation
- E** Manuscript Preparation
- F** Literature Search
- G** Funds Collection

Calyceal Diverticulum of the Kidney – Diagnostic Imaging Dilemma in Pediatric Patients – Case Report

Przemysław Bombiński^{1ABCDEF}, Stanisław Warchol^{2ABCDEF}, Michał Brzewski^{1ACDE},
Agnieszka Biejat^{1ACD}, Teresa Dudek-Warchol^{2CDE}, Grażyna Krzemień^{3CDE},
Agnieszka Szmigielska^{3CDE}, Krzysztof Toth^{4CD}

¹ Department of Pediatric Radiology, Medical University of Warsaw, Warsaw, Poland

² Department of Pediatric Surgery and Urology, Medical University of Warsaw, Warsaw, Poland

³ Department of Pediatric Nephrology, Medical University of Warsaw, Warsaw, Poland

⁴ Nuclear Medicine Laboratory, Nukleomed, Warsaw, Poland

Author's address: Przemysław Bombiński, Department of Pediatric Radiology, Medical University of Warsaw, Warsaw, Poland, e-mail: przebom@op.pl

Summary

Background: Calyceal diverticula are rarely diagnosed in children. They can mimic other renal cystic lesions and correct diagnosis can be difficult to establish. Connection between fluid collection and collecting system confirmed by imaging studies is the key diagnostic finding.

Case Report: In this report we present a case of pediatric patient with calyceal diverticulum, with initial ultrasonographic diagnosis of simple renal cyst. Final diagnosis was established after extended diagnostics following infection of a fluid collection.

Conclusions: 1. Differential diagnosis of well-circumscribed solitary renal fluid collections in children should include particularly: simple cyst, calyceal diverticulum and the first demonstration of ADPKD. 2. Diagnosis of calyceal diverticulum should be confirmed by contrast studies. 3. Standard management of calyceal diverticula in children includes ultrasonographic follow-up and conservative treatment and rarely requires surgical intervention.

MeSH Keywords: Child • Nephrology • Pediatrics • Radiology • Urology

PDF file: <http://www.polradiol.com/abstract/index/idArt/892053>

Background

Calyceal diverticula are rarely diagnosed in children [1–5]. They present as fluid-filled spaces communicating with the pelvicalyceal system. They constitute a diagnostic challenge in children due to the ultrasonographic resemblance of solitary renal cysts, which are also rare in this age group [6]. They may take on appearance of solitary or multiple cysts in one or both kidneys. They may cause clinical symptoms related to formation of deposits, infection and hematuria. Demonstrating a connection between this fluid-filled space and pelvicalyceal system in contrast studies, such as computed tomography or urography, as well as scintigraphy and magnetic resonance imaging, is the key diagnostic finding.

The goal of this work is to demonstrate the diagnostic pitfalls associated with calyceal diverticula, particularly in

relation to the diagnostics of cystic renal lesions in children, based on a case study.

Case Study

A 5.5-year-old girl with a solitary simple cyst in a central part of the left kidney diagnosed on ultrasound examination in the 5th month of life was admitted to hospital due to fever. Two days before admission she complained of pain in the lumbar region and fever up to 40 degrees with poor response to antipyretics. Laboratory tests performed on admission revealed elevated inflammatory markers and urinary tract infection. Ultrasound examination (Figure 1) showed a thin-walled cyst filled with non-echogenic fluid, 23 mm in diameter, in the central part of the left kidney. The pelvicalyceal system was not dilated. A follow-up ultrasound performed 3 days later revealed a change in

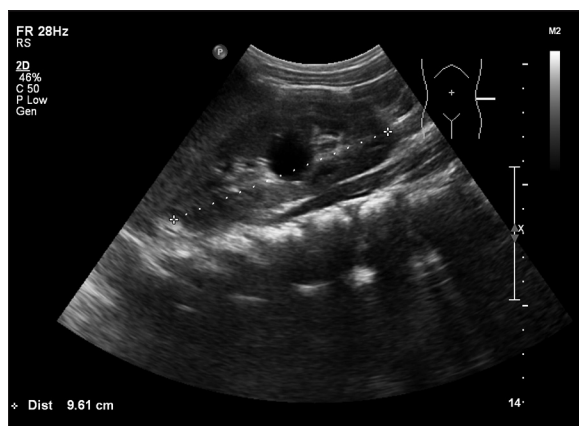

Figure 1. Abdominal US – simple renal cyst in the mid-portion of the left kidney.

cyst’s content – a thick, heterogeneous sediment forming a level with fluid, raising a suspicion of cyst infection with purulence. She was diagnosed with acute pyelonephritis accompanied by left-sided renal cyst infection. Following 2 weeks of antibiotic therapy ultrasound examination revealed regression of inflammatory changes – cyst content became non-echogenic and cystic wall slightly thickened; it also demonstrated scar formation within renal parenchyma around the cyst. Patient was discharged home with a recommendation for future ambulatory care in nephrology and urology outpatient clinics. Scintigraphy (^{99m}Tc-EC) was performed two months after hospitalization in order to precisely assess postinflammatory lesions in renal parenchyma (Figure 2), demonstrating lack of accumulation of the radiomarker in the center of the left kidney in the parenchymal phase, followed by its accumulation in the late phase. Renal accumulation and excretion of a radiomarker was otherwise normal (47% ERPF). Suspicion of centrally located cyst within renal parenchyma projecting on the pelvis and possibly communicating with the pelvicalyceal system was raised. Conventional X-ray urography was performed one month later in order to verify these findings (Figure 3), which demonstrated modeling of central portion of pelvicalyceal system without urinary obstruction. The cyst did not undergo contrast enhancement. Over the course of another two years control US studies showed slight enlargement of the cyst – up to 30 mm. Follow-up scintigraphy was performed at the age of 7.5 years (2 years

after previous study), with similar results as before. Due to some discrepancies between results of previous studies, the girl was referred for multi-phase computed tomography urography (phases: native, parenchymal and late – 15 minutes after administration of contrast medium) (Figure 4A–4C). Examination showed contrast enhancement of cystic content – late phase of the study visualized level of contrast agent in the posterior part of the cyst and increased density of fluid within its lumen. Abdominal X-ray performed 1.5 hours after the CT (Figure 5) showed retention of contrast agent within the cyst. CT image indicated presence of large calyceal diverticulum. The patient was subsequently referred for further observation, with a possibility of surgical intervention in case of the diverticulum enlargement or clinical symptoms appearance.

Discussion

Calyceal diverticula are rarely diagnosed in children [1–5]. They are most often congenital, rarely acquired after urinary tract infection, trauma or urolithiasis. They are incidental findings or may be diagnosed in the course of diagnostics of clinical symptoms associated with formation of deposits, urinary tract infection or hematuria. Literature contains sparse descriptions of diverticuli in children – within last 10 years there were only 6 publications of diverticuli in this age group.

Diagnostic problems are related to similarities between diverticuli and solitary renal cysts, which do not necessitate extended diagnostics in children. They are routinely observed in ultrasound studies and require additional diagnostic procedures in case of complications or diagnostic difficulties. Diverticuli mimic solitary or multiple fluid-filled spaces located within one or both kidneys [1,4,7]. Most diverticuli appear as solitary simple cysts, although there were described cases of diverticuli with a complex cysts appearance [1,2,8]. They are most often located in the upper pole of the kidney [1,3,7,9,10] where they connect with the minor calyx. Less frequently they may be found in the central part of a kidney, where they connect with the major calyx or directly with the renal pelvis – in this location they are usually larger and more frequently cause clinical symptoms.

Diagnosis requires demonstrating a connection between a fluid-filled space and the pelvicalyceal system, which may

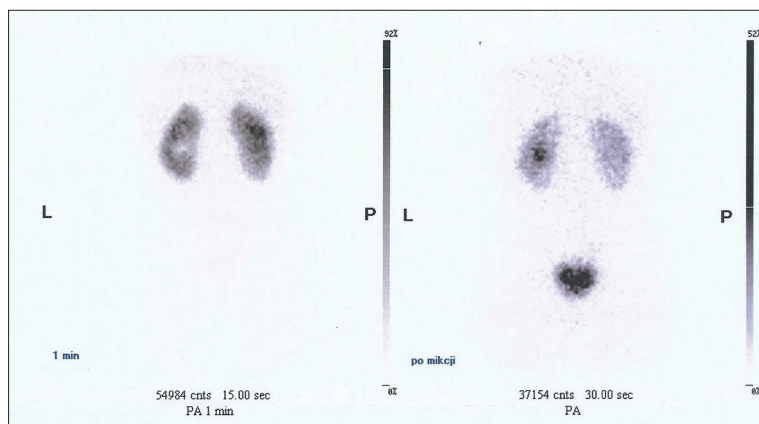


Figure 2. Renal scintigraphy revealed area without radiomarker accumulation in the excretory phase, but with accumulation in the late phase.

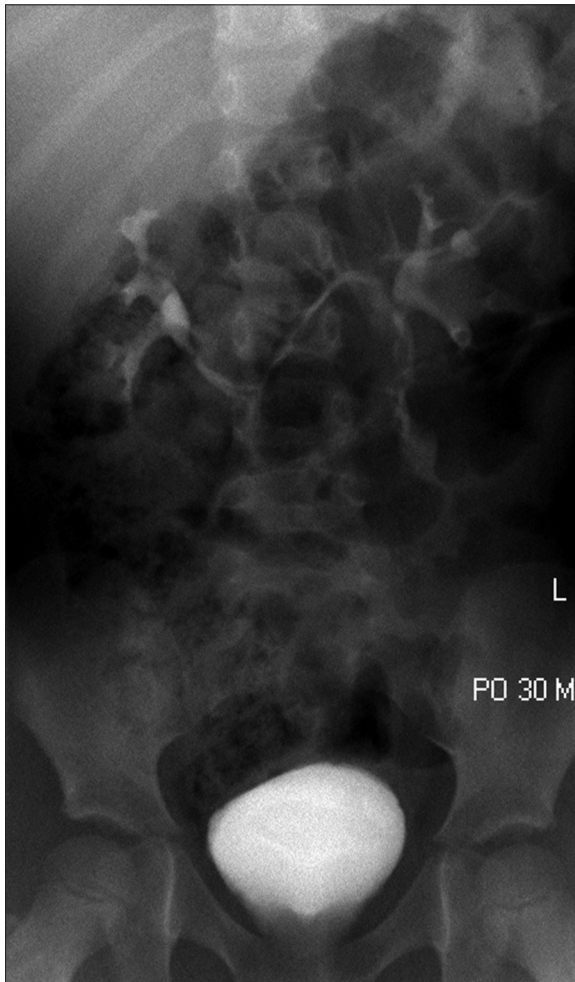

Figure 3. Conventional X-ray urography revealed displacement of the collecting system in the central part, without urinary flow obstruction.

be visualized in contrast studies – conventional X-ray urography and computed tomography urography, as well as scintigraphy or magnetic resonance. CT urography belongs to standard imaging procedures in children [11] due to better urinary tract visualization and similar or even reduced radiation dose in comparison to conventional X-ray urography. Late-phase imaging shows contrast enhancement of fluid-filled space, most often as contrast agent level or increased density of its content. Scintigraphy may demonstrate accumulation of a radiomarker within the cyst and its delayed excretion.

Diverticuli seem to be more common in children than it is currently diagnosed. Diagnostic difficulties are related to their resemblance to other cystic lesions in children, including: simple cysts, hydronephrotic dilatation of pelvicalyceal system in a duplex kidney, cystic renal tumors as well as autosomal dominant polycystic kidney disease (ADPKD), in the course of which cysts may appear as early as in neonatal age. Simple cysts are rare in children [6,12] and may be related to early presentation of ADPKD. Limitations in procedures involving ionizing radiation in this age group constitute an additional problem. Ultrasound examination is the basic examination in children, may

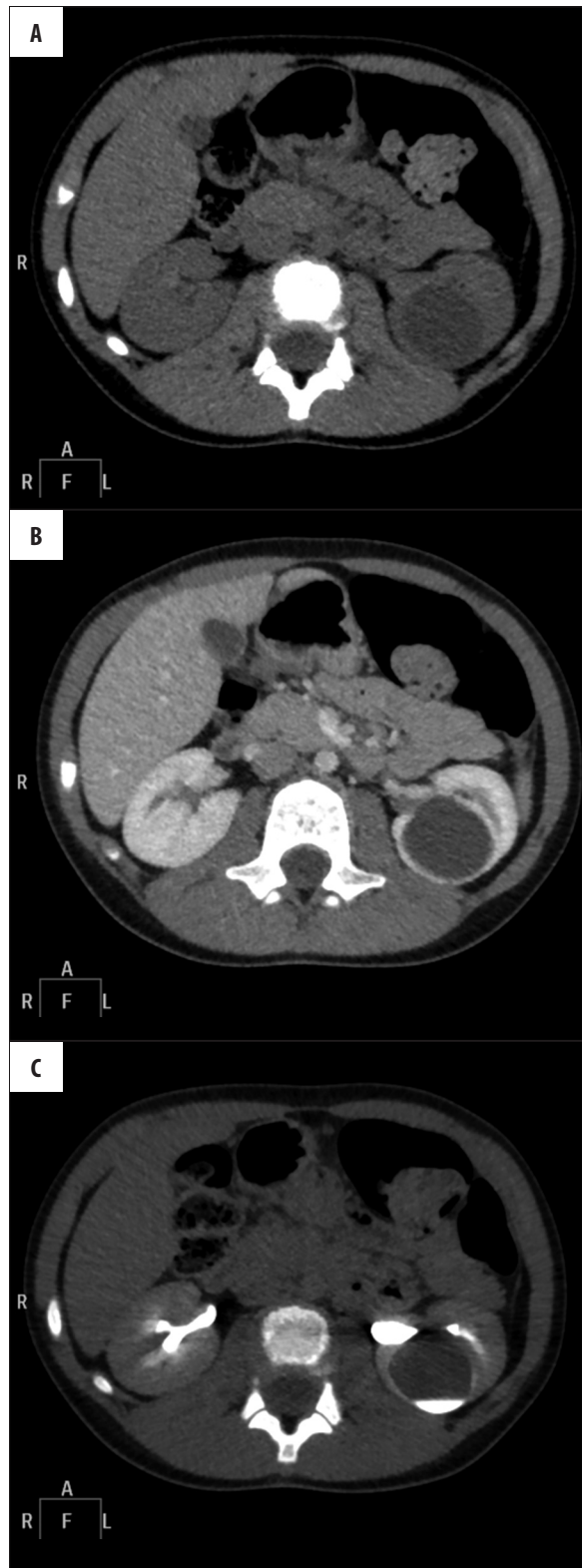


Figure 4. Multiphase CT urography (phases: unenhanced, parenchymal and delayed 15 min. after IV contrast injection) (A–C). Examination revealed contrast filling of the cyst – delayed phase (C) demonstrates level of the contrast and increased enhancement of fluid within the cyst, confirming communication between the renal cyst and the collecting system.

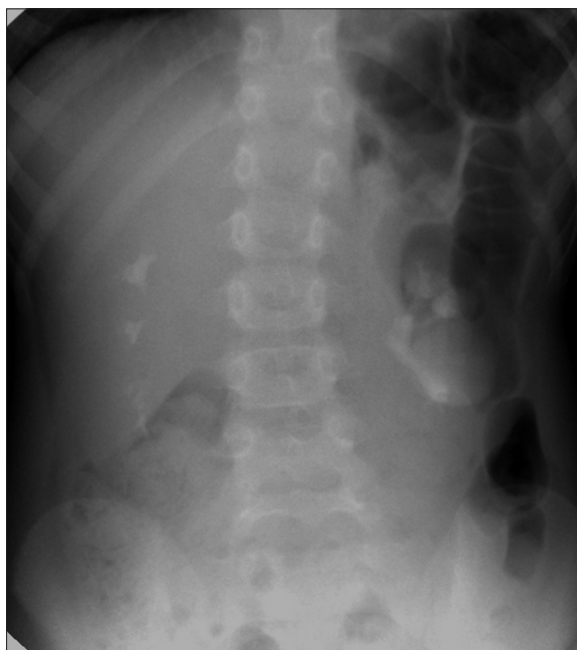


Figure 5. Abdominal x-ray, performed 1.5 hours after CT urography, revealed contrast retention within the cyst.

reveal presence of renal cyst, but will not visualize its connection to the pelvicalyceal system. Demonstration of echogenic sediment, deposits or calcifications at its posterior wall may suggest a diagnosis of diverticulum, particularly when its echogenic content moves with change in body position [7–9]. Contrast imaging should be the next diagnostic step in such case. Computed tomography without late phase does not suffice for proper diagnosis. Moreover, slight increase in density of diverticular content in the parenchymal phase may be misdiagnosed as solid tumor enhancement [9]. For that reason, diagnostics of cystic renal lesions in computed tomography in children should include imaging in the late phase.

Piśmiennictwo:

1. Karmazyn B, Kaefer M, Jennings SG et al: Caliceal diverticulum in pediatric patients: the spectrum of imaging findings. *Pediatr Radiol*, 2011; 41: 1369–73
2. Siegel MJ, McAlister WH: Calyceal diverticula in children: unusual features and complications. *Radiology*, 1979; 131: 79–82
3. Kavukcu S, Cakmakci H, Babayigit A: Diagnosis of caliceal diverticulum in two pediatric patients: a comparison of sonography, CT, and urography. *J Clin Ultrasound*, 2003; 31: 218–21
4. Estrada CR, Datta S, Schneck FX et al: Caliceal diverticula in children: natural history and management. *J Urol*, 2009; 181: 1306–11
5. Casale P, Grady RW, Feng WC et al: The pediatric caliceal diverticulum: diagnosis and laparoscopic management. *J Endourol*, 2004; 18: 668–71
6. Biejat A, Marcinski A, Brzewski M et al: Simple renal cysts in children. *Pol J Radiol*, 2002; 67(1): 64–67
7. Rathaus V, Konen O, Werner M et al: Pyelocalyceal diverticulum: The imaging spectrum with emphasis on the ultrasound features. *Br J Radiol*, 2001; 74: 595–601
8. Surendrababu NR, Govil S: Diagnostic dilemma: calyceal diverticulum vs. complicated cyst. *Indian J Med Sci*, 2005; 59: 403–5
9. Stunell H, McNeill G, Brown RF et al: The imaging appearances of calyceal diverticula complicated by urolithiasis. *Br J Radiol*, 2010; 83: 888–94
10. Wulfsohn MA: Pyelocaliceal diverticula. *J Urol*, 1980; 123: 1–8
11. Bombinski P, Warchol S, Brzewski M et al: Lower-dose CT urography (CTU) with iterative reconstruction technique in children – initial experience and examination protocol. *Pol J Radiol*, 2015; 80: 137–44
12. Marietti S, Woldrich J, Durbin J et al: Urologic findings on computed tomography of the abdomen and pelvis in a pediatric population. *J Pediatr Urol*, 2013; 9: 609–12

In the presented case ultrasound examination demonstrated a fluid-filled space with thick, heterogeneous content forming a fluid-sediment level. However, taking into consideration clinical course and ultrasound images, it was not possible to differentiate infection of a simple cyst and infection of diverticulum. Scintigraphy performed in order to assess renal parenchyma following the infection suggested a communication between fluid-filled space and pelvicalyceal system, although the picture was equivocal. Conventional X-ray urography was performed in order to verify these findings. It yielded negative result and failed to demonstrate contrast enhancement of fluid-filled space. Result of follow-up scintigraphy performed two years later again suggested presence of a diverticulum. At that time, following analysis of previous examinations and discrepancies between their results, we decided to perform CT urography, as MR imaging was not available. Only late phase images in CT urography revealed contrast enhancement of fluid space.

Presence of diverticuli of renal calyces and pelvis may be associated with higher risk of complications [1,2,4,5,9]. The most common include: development of deposits due to urine retention in renal fluid space and recurrent urinary tract infections complicated by abscess formation. Occurrence of the above complications or increase in diverticular size may be an indication for surgical treatment [2].

Conclusions

1. In case of finding of well-circumscribed solitary renal fluid collection in a child's kidney, differential diagnosis should include particularly the following: simple cyst, calyceal diverticulum and the first demonstration of ADPKD.
2. Contrast study is required for diagnosis of calyceal diverticulum.
3. Management of calyceal diverticulum in a child includes ultrasonographic follow-up and conservative treatment and rarely requires surgical intervention.