

# PMMA-collagen Gel in Nonsurgical Rhinoplasty Defects: A Methodological Overview and 15-year Experience

Alexander Rivkin, MD

**Background:** Nonsurgical rhinoplasty (NSR) is an alternative to surgical rhinoplasty for patients who desire correction of mild-to-moderate aesthetic nasal defects but do not wish to undergo surgery due to concern about risks, recovery time, or cost. Although not a surrogate, NSR can be a more accessible and more precise modality for achieving aesthetic goals. Furthermore, for certain types of defects, the precision possible with filler injection versus surgery can make NSR the preferred procedure. In these instances, polymethylmethacrylate (PMMA)-collagen gel is a valuable tool for appropriate candidates due to its permanence and its favorable safety profile when injected appropriately.

**Methods:** Optimal use of PMMA-collagen gel for NSR is predicated on expert-level injector experience and careful patient selection and education. The author draws on over 15 years of experience treating more than 1000 NSR patients with PMMA-collagen gel to provide a discussion of relevant anatomy; methodological overview, including patient selection; and a video describing injection technique of NSR with PMMA-collagen gel.

**Results:** To our knowledge, this is the first published guidance on NSR with permanent filler. In addition to the clinical experience provided, patient images with 10 years of follow-up are included to illustrate the durability of the results and the continued natural appearance of the correction as the treated patients continue to age.

**Conclusion:** In patients with aesthetic nasal deficits treated with filler, where permanent correction is desired, the appropriate use of PMMA-collagen gel is an effective treatment option. (*Plast Reconstr Surg Glob Open* 2022;10:e4477; doi: 10.1097/GOX.0000000000004477; Published online 19 August 2022.)

## INTRODUCTION

Nonsurgical rhinoplasty (NSR) has emerged over the past decade as a valuable technique for correcting mild-to-moderate aesthetic imperfections of the nose.<sup>1</sup> NSR, or non-surgical nose job, is a term that encompasses a range of procedures, including the use of fillers to:

- Camouflage a dorsal hump
- Alter tip definition, projection, or rotation
- Address deformities of the nasal side wall

- Augment dorsal deficiency
- Address a deep radix
- Lengthen the nose
- Alter the nasolabial angle
- Correct postrhinoplasty contour irregularities

For the patient, surgical rhinoplasty can be an expensive procedure that results in significant recovery time due to ecchymosis and postoperative edema. Additional risks may include unsatisfactory aesthetic appearance, breathing difficulties, and/or poor short-term or long-term outcomes such as scarring and loss of skin sensation.<sup>2,3</sup> Importantly, surgery lacks the level of control needed to achieve the desired outcome for correction of certain minor deficits.

From Westside Aesthetics, Los Angeles, Calif.

Received for publication February 8, 2022; accepted June 21, 2022.

Presented at the AAFPRS Annual Conference, Miami Cosmetic Surgery, May 6, 2022.

Copyright © 2022 The Author. Published by Wolters Kluwer Health, Inc. on behalf of The American Society of Plastic Surgeons. This is an open-access article distributed under the terms of the [Creative Commons Attribution-Non Commercial-No Derivatives License 4.0 \(CCBY-NC-ND\)](https://creativecommons.org/licenses/by-nc-nd/4.0/), where it is permissible to download and share the work provided it is properly cited. The work cannot be changed in any way or used commercially without permission from the journal.

DOI: 10.1097/GOX.0000000000004477

**Disclosure:** Dr. Rivkin is a speaker, trainer and ad board consultant for Galderma, Allergan, Suneva Medical, Merz, and Revansee; and a principal investigator for Allergan and Galderma.

Related Digital Media are available in the full-text version of the article on [www.PRSGlobalOpen.com](http://www.PRSGlobalOpen.com).

NSR avoids these risks and affords the ability to augment very small areas, thereby permitting a remarkably precise correction of nasal aesthetic concerns. Although, in most instances, treatment with hyaluronic acid (HA) fillers is appropriate, for a subset of patients, a permanent result is desired, and polymethylmethacrylate (PMMA)-collagen gel (Bellafill; Suneva Medical, Inc., San Diego, Calif.) can be used. In these patients, PMMA-collagen gel allows for a more precise and safe way to achieve aesthetic goals, with the same duration of effect as surgery, and is associated with high patient satisfaction.<sup>4</sup>

The overarching goal of NSR is to achieve an optimal and durable effect while avoiding complications. The nose is the most dangerous area in the face to inject with filler. It is the area most associated with postfiller injection tissue necrosis and is one of the highest-risk areas for filler-induced blindness.<sup>5–10</sup> Additional possible complications for NSR with any filler, beyond expected injection site reactions, include visible or palpable product nodules and ischemia. The lack of redundant dermal blood supply in the tip, ala, and columella and the abundance of subcutaneous fibrous septae there and in the radix make the nose uniquely prone to ischemia and necrosis due to compartment effect and vessel compression.<sup>11</sup> An illustration showing anatomical landmarks and vasculature is shown in Figure 1. This propensity for complications makes injecting the nose a procedure that should only be performed by highly experienced injectors with an in-depth knowledge of facial anatomy who are well prepared to manage adverse events, should they occur.

### Takeaways

**Question:** This article seeks to fill a gap in the medical literature by providing needed information on methods for safe injection of PMMA-collagen gel for nonsurgical rhinoplasty (NSR) from an expert physician injector.

**Findings:** This report details patient selection and injection technique for NSR with PMMA-collagen gel. In carefully selected patients, injection by highly experienced physicians yields positive, durable outcomes. Continued positive outcomes are apparent in 10-year follow-up images.

**Meaning:** This is the first methodological report of non-surgical correction of aesthetic nasal defects with PMMA-collagen gel and provides important information gleaned from 15 years of experience, which can support physicians considering PMMA-collagen gel for NSR.

Filler selection is an important element of NSR. For each of the most commonly used fillers in this setting, including HA fillers, calcium hydroxylapatite (CaHA; Radiesse; Merz North America, Inc., Raleigh, N.C.), and PMMA-collagen gel, use in the nose is off-label.<sup>12,13</sup> Filler choice should be based on the anatomic location of the defect, desired outcome, and product attributes such as reversibility, longevity, viscosity, hydrophilicity, elasticity, and moldability after injection.<sup>14</sup> For instance, HA fillers generally last 6–18 months, are easily moldable, and are reversible at any time following injection; however, they have a minimal collagen

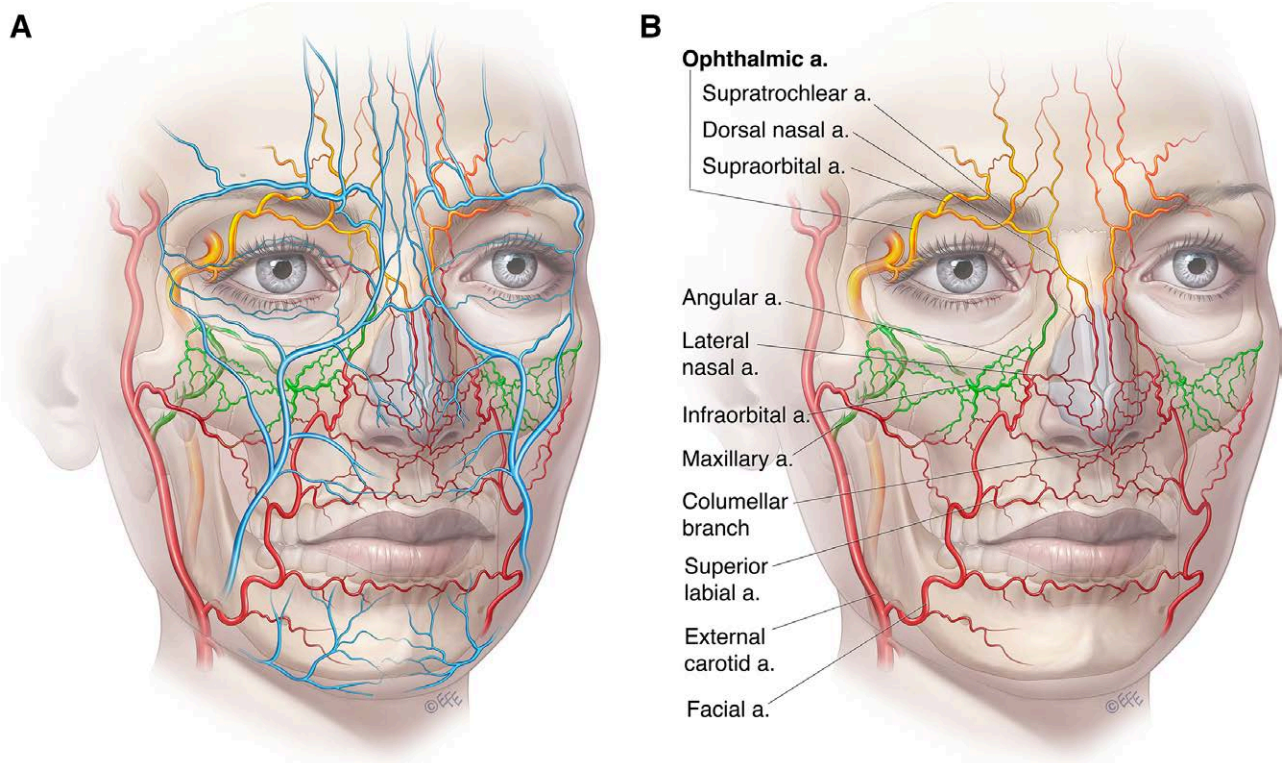


Fig. 1. Illustration showing the nasal arteries and veins (A) and the labeled arteries (B).

stimulating effect.<sup>15,16</sup> Calcium hydroxyapatite is biostimulatory, has a higher viscosity and elastic modulus [ie, stiffness ( $G'$ )] relative to HA fillers, and lasts about 8–12 months, but cannot be reversed.<sup>17–20</sup> In contrast, PMMA-collagen gel is a very long-lasting, most often permanent, biostimulatory filler that achieves a recontouring effect over two to three sessions through collagen deposition and fibroplastic response to the PMMA microspheres.<sup>21</sup> This effect has been demonstrated to last for 5 years in the literature, but clinically, duration is significantly longer.<sup>15,22</sup> Figures 2–4 present examples of 10-year duration of aesthetic effect of PMMA collagen in the nose. Despite PMMA being nonbiodegradable, patients do sometimes return for a touch-up treatment 7–10 years after the initial series of injections, generally to correct tissue volume reduction and resultant decrease in aesthetic effects driven by the aging process, rather than diminution of the filler itself.

Because PMMA-collagen gel is irreversible, its use in NSR should be reserved for the most experienced nasal injectors. Descriptions of a wide array of NSR techniques that utilize various fillers are available in the literature, but none to the authors' knowledge are specific to PMMA-collagen gel.<sup>23–31</sup> Due to its unique properties and longevity, there is a need to define optimal technique and appropriate patient selection and share advanced injection skills for NSR. Here, we provide an overview of how the author selects and treats NSR patients using PMMA-collagen gel.

## METHODS

This methodological overview is based on more than 15 years of experience using PMMA-collagen gel for NSR, among other applications, in selected patients. In the treatment of the patients shown in Figures 2–4, the principles outlined in the Declaration of Helsinki were followed, and consent for photography was obtained.

## RESULTS

In the lead author's practice, more than 20,000 NSR procedures (in >10,000 patients) have been performed, and approximately 2500 of those (in >1000 patients)

have utilized PMMA-collagen gel. An illustration of relevant vascular structure is shown in Figure 1, as knowledge of resident anatomy is critical. Best practices for patient selection and treatment planning are described, and descriptions and videos of injection technique are provided along with a discussion of follow-up and safety. Nontechnical key considerations are also provided.

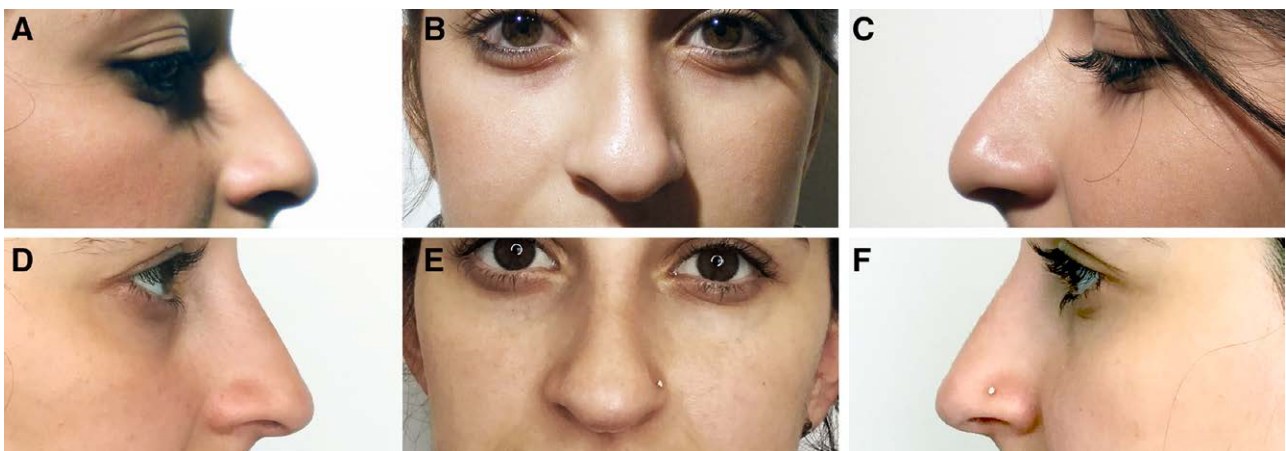
## DISCUSSION

### Patient Selection

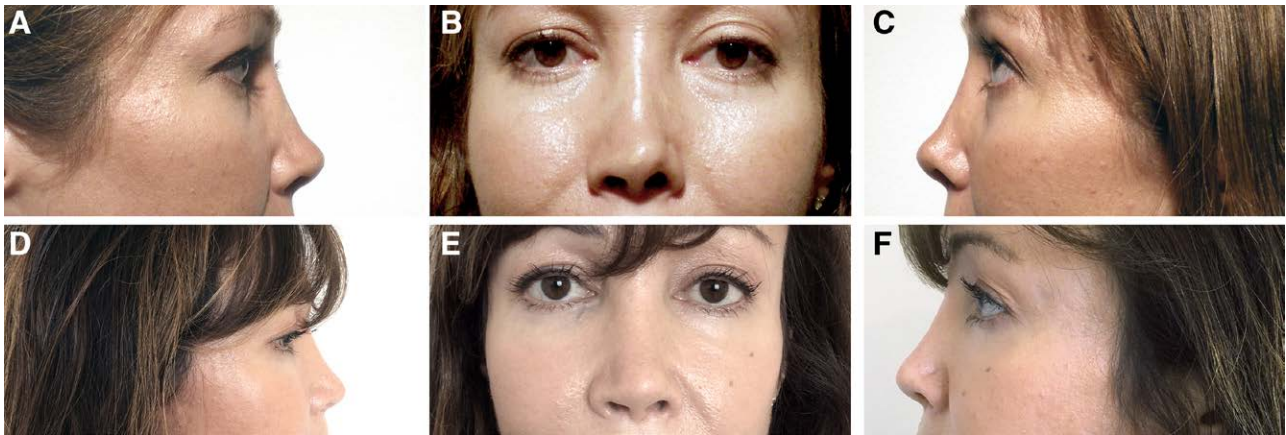NSR can address dorsal hump, deep radix, side wall deformities, tip underprojection, tip under- or overrotation, low dorsum, short nasal length, columella retraction, saddle nose deformity, postsurgical contour irregularities, and various asymmetries in appropriately selected patients. Complete analysis of the deformity, adequate expertise, and proper injection technique are requisite for achieving optimal outcomes and avoiding adverse events and complications.<sup>14</sup> Unlike treatment with HA or CaHA, the tissue response to PMMA-collagen gel injection alters the subcutaneous tissue planes and makes future surgery significantly more difficult, so the patient must be absolutely certain that the results of the nonsurgical procedure meet their aesthetic goals.

Patients should be consented so that they understand the permanence of PMMA-collagen gel for NSR, as well as the inadvisability of having surgical rhinoplasty after PMMA-collagen gel injection in the nose. In the author's practice, the following patient types are considered optimal candidates for PMMA-collagen gel injection:

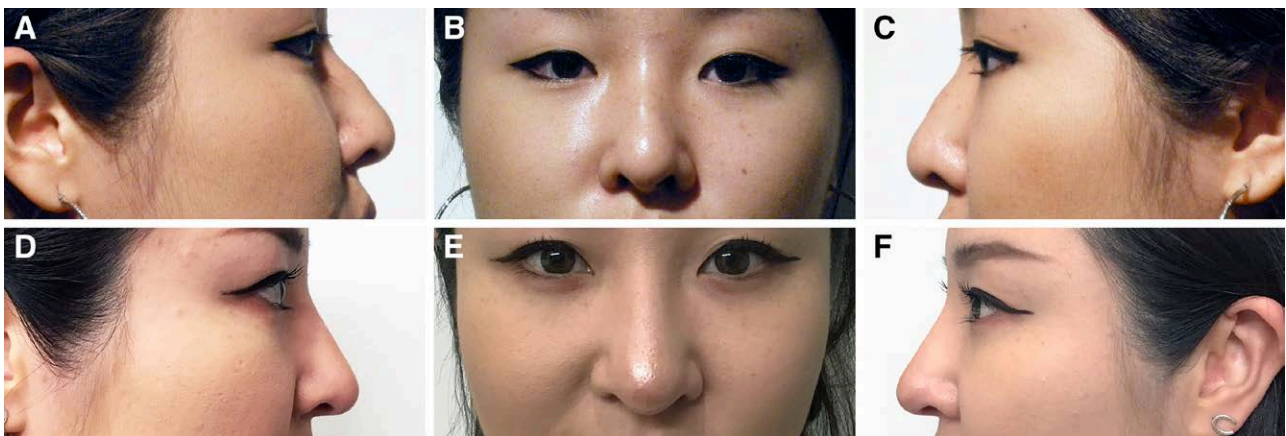1. The patient who has had an NSR with HA or CaHA fillers, is pleased with the nature of the results, and once the original treatment begins to fade, wishes to have similar results with longer durability.
2. The patient who has received their initial treatment with HA or CaHA, and when presenting for touch-up treatment 4–8 weeks later, voices a desire to have longer-lasting results.



**Fig. 2.** A 39-year-old woman at baseline (A–C) and 10 years after (D–F) treatment with 0.8ml of PMMA-collagen gel administered to the radix, dorsum, and tip over the course of three treatments as part of an NSR.



**Fig. 3.** A 49-year-old woman, post two previous surgical rhinoplasty procedures, at baseline (A-C) and 10 years after (D-F) treatment with 0.8 ml of PMMA-collagen gel over two sessions in the dorsum, sidewall, and tip as part of an NSR. Note softened contours, improved tip projection, and improved symmetry.



**Fig. 4.** A 37-year-old woman at baseline (A-C) and 10 years after (D-F) treatment with 1.0 ml of PMMA-collagen gel in the radix, dorsum, and tip as part of an NSR.

3. The patient who has researched their options, insists on PMMA-collagen gel NSR, and voices clear understanding of the irreversibility of the procedure and the commitment involved.
4. Postrhinoplasty patients who are uninterested in revision surgery. These patients generally have specific aesthetic complaints that are most precisely addressed with filler rather than an additional operation. These patients often want to avoid the trauma and downtime of surgery and are concerned about the relatively high cosmetic and functional risk associated with revision rhinoplasty. Patients may voice fear of revision surgery causing a progressively more unnatural nasal appearance. Specific concerns of these patients may include:
  - a. Postsurgical skeletonization of cartilage
  - b. Dorsal or alar cartilage collapse
  - c. Saddle nose deformity
  - d. Sidewall asymmetry
  - e. Polybeak deformity
  - f. Deepened supra-alar crease
  - g. Alar retraction
  - h. Columnellar retraction

In all cases, patients with a history of keloid or hypertrophic scar formation are less than ideal candidates for NSR.

Postsurgical injection is fraught with considerable risk, as scarring from surgery is associated with increased incidence of embolic vascular occlusion due to unpredictable positioning and increased fixation of blood vessels, as well as increased danger of compartment effect ischemia because the blood supply to the skin becomes more tenuous. In a recent review of 2488 NSR procedures performed by the author with a range of fillers, the overall rate of adverse events in postsurgical patients was 10.8%, significantly higher than the rate of adverse events in patients without previous surgery (7.4%;  $P = 0.032$ ).<sup>13</sup> Thus, injection of postrhinoplasty patients with PMMA-collagen gel requires an even higher level of expertise and care.

PMMA-collagen gel NSR patients must understand that the procedure requires two or more sessions spaced 4–6 months apart. In the author’s experience, nearly all patients require at least two visits, and about 30% require three. Utilization of small injection volumes (<0.05 ml) at each injection point is important for optimal safety,

and a slow building of shape and contour with product is ideal given the absence of tools to address overcorrection or product misplacement and the longevity of the injection. Finally, injection of PMMA-collagen gel into the dermis (the plane recommended by the author) causes a firming and thickening of overlying skin. Because this does not occur with HA fillers or CaHA, it is important to inform the patient that this is an expected outcome of treatment. Of the patients the author has injected, none have expressed displeasure with skin changes. As specified in the Bellafill Instructions for Use, patients should have an intradermal test administered to assess for allergy to bovine collagen, and the procedure should be performed 28 days afterward, assuming no positive reaction.<sup>12</sup>

### Treatment

Most patients require injection of more than one nasal subunit during their PMMA-collagen gel NSR. In the author's experience, the radix is the most frequently injected (77% of procedures, alone or in combination), followed by the tip (70%), dorsum (60%), side wall (26%), ala (2%), and columella (<1%).<sup>13</sup> The most common combination is the dorsum, radix, and tip. Regardless of the area, the injector must be vigilant and extremely conservative with the speed, force, and amount of product that they inject.

After careful aesthetic analysis of the nose and treatment planning with the patient, standardized photographs are taken in five or seven views, and anesthetic cream (eg, 20% lidocaine, 6% benzocaine, and 4% tetracaine) can be applied to the nose 30 minutes before injection. (**See Video [online]**, which provides an overview of the procedure.) Some patients choose to forego topical anesthetic, which is preferable for the injector because the cream does cause some erythema and edema. After removal of the cream, the subject should be placed in an upright position. Sterility should be maximized throughout the procedure with repeated cleansing of the nasal skin using isopropyl alcohol and/or other appropriate agents. The PMMA-collagen gel should be brought to room temperature before injection to allow for ease of injection and precise placement into the soft tissue. To minimize asymmetry and prevent vascular complications, the injector may choose to mark the midline on the nasal bridge. Before injection, it is wise to be prepared to manage any adverse event by having warm compress packs, hyaluronidase, nitropaste, aspirin, and oral steroids on hand.

PMMA-collagen gel can be injected using the 27-G, 5/8-inch needles that come with the product or a thin-walled 29-G 1/2-inch needle (Terumo Europe N.V., Belgium). In the author's hands, PMMA-collagen gel yields the greatest biostimulatory effect when placed relatively superficially, in the deep dermal to just subdermal layers of the skin. Unlike other fillers, PMMA-collagen gel is quite soft at room temperature. The structural effect of the filler arises from multiple injection sessions as biostimulation builds layers of collagen and fibroplasia in the injected areas.

To inject, the author inserts the needle at a 45-degree angle to the skin until the bevel of the needle is just under the surface. A 0.02–0.05-ml mini thread of filler is then

placed at that depth, slowly and under low pressure. As the filler is injected, the needle is withdrawn from the skin. Most PMMA-collagen gel NSR sessions utilize less than 1 ml in total. The injector should use the fingers of their free hand to guard against filler moving into neighboring areas during injection. After injection, the PMMA-collagen gel should be molded to the desired contour, and postprocedure photographs should be taken. Care should be taken to distribute the material as evenly as possible to ensure adequate distribution of the PMMA microspheres within the tissue so as to prevent accumulation and subsequent nodule formation.

### Posttreatment Care and Follow-up

Following the procedure, patients should be advised to protect the area from trauma or pressure in the immediate posttreatment period and to avoid excessive facial motion for 24 hours. Heavy glasses should be avoided for 2 weeks if they rest on the areas that were injected. To avoid bruising, patients should avoid vigorous exercise, aspirin, ibuprofen, and alcohol for 24 hours. A normal skin care routine can be resumed 6 hours after the procedure. It is important to advise patients that the initial visible results will fade significantly over the first several weeks as the collagen component is absorbed by the body; however, as PMMA-mediated collagenesis occurs over time, the final results will become apparent (between 12 and 16 weeks).

Patients should return 4–6 months after the initial injection for their second treatment. At this time, the bovine collagen carrier gel should be resorbed and the volume present should derive from native fibroblast activity and collagen deposition. The second session should not be before 4 months to ensure that collagen induction by the PMMA microspheres has peaked.<sup>13</sup> Injecting earlier increases risk of overcorrection. Given that PMMA-collagen gel is long-lasting, a conservative and multisession approach to injection is best. Representative results are shown in **Figures 2–4**.

### Safety

The adverse events commonly observed with PMMA-collagen gel NSR in clinical practice are similar to those with HA fillers and are limited to transient and self-limiting injection site reactions (erythema, bruising, swelling, and tenderness). A rare complication with this procedure is prolonged (lasting longer than 2 weeks) erythema of the nasal tip, which can be resolved with vascular laser treatment. Although also rare, it is possible to encounter tenderness of the tip of the nose after injection. This is most often mild and self-limiting. In five instances encountered by the author over more than 1000 cases, filler collected, most likely, because of facial motion shortly after completion of the procedure. In all five instances, a steroid and saline injection resolved the unevenness, and these patients did not experience any long-term complications (ie, emergence of nodules or granulomas).

Although the majority of NSR adverse events are mild and comprise temporary injection site reactions, the nose has been clearly demonstrated to be the most common site associated with filler-induced embolic vision loss.<sup>7</sup>

Additionally, the risk of ischemia and necrosis is significantly higher for nasal filler injections, as compared with the rest of the face.<sup>5,11</sup> Diligent injection (slow and with low pressure) of PMMA-collagen gel above the superficial musculoaponeurotic system and into the dermal and subdermal planes of the skin should significantly reduce the risk of these events because the needle is superficial to the nasal vasculature.<sup>32</sup>

Although the durability of PMMA in the body warrants particular caution, postmarket surveillance data suggest that there is not an inherently increased risk of adverse events.<sup>33</sup> In addition, a recent preclinical study suggests that PMMA-collagen gel has a reduced propensity for embolic events relative to HA fillers. This may be because of a decreased propensity to form an intravascular embolus due to the inherent low viscosity of the filler and granular nature of its components.<sup>34</sup> Nevertheless, care should be taken when injecting, and the injector should be prepared to recognize and treat the signs and symptoms of vascular occlusion.

If the physician observes blanching of the skin, disproportionate pain, or livedo reticularis and suspects that a vascular event has occurred, injection should be stopped immediately. The area should be massaged vigorously and a warm compress applied. The patient should take 325 mg of aspirin. Although PMMA-collagen gel is not an HA filler, administration of hyaluronidase can disrupt native HA as well as dissolve any residual HA filler from past injections in the area.<sup>35</sup> We are learning from surgeons operating in previously injected areas that HA persists in the body considerably longer than previously thought.<sup>36,37</sup> The enzyme should help improve blood flow, buying the body time to mobilize collateral blood supply. Hyaluronidase should be administered in a high enough dose to cover the area in danger.<sup>38</sup> Topical 2% nitroglycerin paste may also help with blood flow. If the skin does not recover immediately, the patient could be given a first dose of oral steroids in the clinic to limit tissue damage from the local inflammatory response to ischemia. Repeated hourly treatment with hyaluronidase and nitropaste should be performed, along with warm compress and massage.<sup>38</sup> If, despite these measures, the capillary refill remains slow (>2 seconds), and the skin turns dusky, the injector should consider the use of antibiotics, sildenafil, tadalafil, and hyperbaric oxygen therapy.<sup>39–41</sup> Patient progress should be monitored closely, and referral to a plastic surgeon should be considered, if necessary.

If the skin does regain color and capillary refill normalizes, the patient should be observed for at least 1 hour in the clinic. They should send the injector a photograph of their nose 4–6 hours after going home and on the following morning to make sure that ischemia is not progressing. The patient should continue massaging the area at home, applying warm compresses, and taking aspirin every 4 hours for 24 hours. If possible, they should be seen in clinic on the following day. If there is still concern at this time, oral steroids should continue.

## CONCLUSIONS

PMMA-collagen gel is an ideal filler for NSR due to its long-lasting duration of effect and manageable adverse

event profile. Along with the technical guidance provided here, key nontechnical considerations are equally as important for successful treatment. Previous clinical studies have shown that PMMA-collagen gel is well tolerated for NSR and is associated with improvements in appearance and long-term patient satisfaction.<sup>42</sup> Proper patient selection and adequate experience of the injector are critical to ensuring optimal outcomes. Injectors should have a thorough understanding of the nasal anatomy and be prepared to manage any adverse events that occur.

Alexander Rivkin, MD

Westside Aesthetics

11645 Wilshire Blvd 800

Los Angeles, CA 90025

E-mail: arivkin9@gmail.com

## ACKNOWLEDGMENTS

Medical writing assistance was provided by Ginny Vachon, PhD, Principal Medvantage, LLC, Atlanta, GA, under the direction of the author. Funding for this assistance was provided by Suneva Medical, Inc.

## REFERENCES

1. Wang LL, Friedman O. Update on injectables in the nose. *Curr Opin Otolaryngol Head Neck Surg*. 2017;25:307–313.
2. Harb A, Brewster CT. The nonsurgical rhinoplasty: a retrospective review of 5000 treatments. *Plast Reconstr Surg*. 2020;145:661–667.
3. Beck DO, Kenkel JM. Evidence-based medicine: rhinoplasty. *Plast Reconstr Surg*. 2014;134:1356–1371.
4. Radulesco T, De Bonnecaze G, Penicaud M, et al. Patient satisfaction after non-surgical rhinoplasty using hyaluronic acid: a literature review. *Aesthetic Plast Surg*. 2021;45:2896–2901.
5. Ozturk CN, Li Y, Tung R, et al. Complications following injection of soft-tissue fillers. *Aesthet Surg J*. 2013;33:862–877.
6. Beleznyay K, Carruthers JDA, Humphrey S, et al. Update on avoiding and treating blindness from fillers: a recent review of the world literature. *Aesthet Surg J*. 2019;39:662–674.
7. Kapoor KM, Kapoor P, Heydenrych I, et al. Vision loss associated with hyaluronic acid fillers: a systematic review of literature. *Aesthetic Plast Surg*. 2020;44:929–944.
8. Sorensen EP, Council ML. Update in soft-tissue filler-associated blindness. *Dermatol Surg*. 2020;46:671–677.
9. Park KH, Kim YK, Woo SJ, et al. Korean Retina Society. Iatrogenic occlusion of the ophthalmic artery after cosmetic facial filler injections: a national survey by the Korean Retina Society. *JAMA Ophthalmol*. 2014;132:714–723.
10. Carle MV, Roe R, Novack R, et al. Cosmetic facial fillers and severe vision loss. *JAMA Ophthalmol*. 2014;132:637–639.
11. Funt D, Pavicic T. Dermal fillers in aesthetics: an overview of adverse events and treatment approaches. *Clin Cosmet Investig Dermatol*. 2013;6:295–316.
12. Suneva Medical Inc. *Bellafill [instructions for use]*. San Diego, Calif.: Suneva Medical, Inc.; October 2020.
13. Rivkin A. Nonsurgical rhinoplasty using injectable fillers: a safety review of 2488 procedures. *Facial Plast Surg Aesthet Med*. 2021;23:6–11.
14. Johnson ON III, Kontis TC. Nonsurgical rhinoplasty. *Facial Plast Surg*. 2016;32:500–506.
15. Forbat E, Ali FR, Al-Niaimi F. The role of fillers in the management of acne scars. *Clin Exp Dermatol*. 2017;42:374–380.
16. Wang F, Garza LA, Kang S, et al. In vivo stimulation of de novo collagen production caused by cross-linked hyaluronic acid dermal filler injections in photodamaged human skin. *Arch Dermatol*. 2007;143:155–163.

17. Attenello NH, Maas CS. Injectable fillers: review of material and properties. *Facial Plast Surg*. 2015;31:29–34.
18. González N, Goldberg DJ. Evaluating the effects of injected calcium hydroxylapatite on changes in human skin elastin and proteoglycan formation. *Dermatol Surg*. 2019;45:547–551.
19. Meland M, Groppi C, Lorenc ZP. Rheological properties of calcium hydroxylapatite with integral lidocaine. *J Drugs Dermatol*. 2016;15:1107–1110.
20. US Food and Drug Administration. Dermal fillers approved by the Center for Devices and Radiological Health. US Food and Drug Administration website. <https://www.fda.gov/medical-devices/aesthetic-cosmetic-devices/fda-approved-dermal-fillers>. Updated November 9, 2020. Accessed at April 6, 2021.
21. Ronan SJ, Eaton L, Lehman A, et al. Histologic characterization of polymethylmethacrylate dermal filler biostimulatory properties in human skin. *Dermatol Surg*. 2019;45:1580–1584.
22. Cohen S, Dover J, Monheit G, et al. Five-year safety and satisfaction study of PMMA-collagen in the correction of nasolabial folds. *Dermatol Surg*. 2015;41(suppl 1):S302–S313.
23. Segreto F, Marangi GF, Cerbone V, et al. Nonsurgical rhinoplasty: a graft-based technique. *Plast Reconstr Surg Glob Open*. 2019;7:e2241.
24. Kang SH, Moon SH, Kim HS. Nonsurgical rhinoplasty with polydioxanone threads and fillers. *Dermatol Surg*. 2020;46:664–670.
25. Moon HJ. Injection rhinoplasty using filler. *Facial Plast Surg Clin North Am*. 2018;26:323–330.
26. Bertossi D, Lanaro L, Dorelan S, et al. Nonsurgical rhinoplasty: nasal grid analysis and nasal injecting protocol. *Plast Reconstr Surg*. 2019;143:428–439.
27. Williams LC, Kidwai SM, Mehta K, et al. Nonsurgical rhinoplasty: a systematic review of technique, outcomes, and complications. *Plast Reconstr Surg*. 2020;146:41–51.
28. Bravo BSF, Bravo LG, Mariano Da Rocha C, et al. Evaluation and proportion in nasal filling with hyaluronic acid. *J Clin Aesthet Dermatol*. 2018;11:36–40.
29. Jung GS, Chu SG, Lee JW, et al. A safer non-surgical filler augmentation rhinoplasty based on the anatomy of the nose. *Aesthetic Plast Surg*. 2019;43:447–452.
30. Sahan A, Tamer F. Non-surgical minimally invasive rhinoplasty: tips and tricks from the perspective of a dermatologist. *Acta Dermatovenerol Alp Pannonica Adriat*. 2017;26:101–103.
31. Kassir R, Venkataram A, Malek A, et al. Non-surgical rhinoplasty: the ascending technique and a 14-year retrospective study of 2130 cases. *Aesthetic Plast Surg*. 2021;45:1154–1168.
32. Saban Y, Andretto Amodeo C, Bouaziz D, et al. Nasal arterial vasculature: medical and surgical applications. *Arch Facial Plast Surg*. 2012;14:429–436.
33. Lehman A, Pilcher B, Roberts WE, et al. Postmarket experience of polymethylmethacrylate-collagen gel dermal filler. *Dermatol Surg*. 2020;46:1086–1091.
34. Nie F, Xie H, Wang G, et al. Risk comparison of filler embolism between polymethyl methacrylate (PMMA) and hyaluronic acid (HA). *Aesthetic Plast Surg*. 2019;43:853–860.
35. Urdiales-Gálvez F, Delgado NE, Figueiredo V, et al. Treatment of soft tissue filler complications: expert consensus recommendations. *Aesthetic Plast Surg*. 2018;42:498–510.
36. Bennett R, Taher M. Restylane persistent for 23 months found during Mohs micrographic surgery: a source of confusion with hyaluronic acid surrounding basal cell carcinoma. *Dermatol Surg*. 2005;31:1366–1369.
37. Soparkar CN, Patrinely JR, Tschen J. Erasing restylane. *Ophthalmic Plast Reconstr Surg*. 2004;20:317–318.
38. DeLorenzi C. New high dose pulsed hyaluronidase protocol for hyaluronic acid filler vascular adverse events. *Aesthet Surg J*. 2017;37:814–825.
39. Ala M, Mohammad Jafari R, Dehpour AR. Sildenafil beyond erectile dysfunction and pulmonary arterial hypertension: thinking about new indications. *Fundam Clin Pharmacol*. 2021;35:235–259.
40. Karaguzel E, Tok DS, Kazaz IO, et al. Postcircumcisional ischemia of the glans penis treated with pentoxifylline. *Case Rep Urol*. 2013;2013:278523.
41. Kruize RGF, Teguh DN, van Hulst RA. Hyperbaric oxygen therapy in hyaluronic acid filler-induced dermal ischemia. *Dermatol Surg*. 2020;46:1755–1757.
42. Rivkin A. A prospective study of non-surgical primary rhinoplasty using a polymethylmethacrylate injectable implant. *Dermatol Surg*. 2014;40:305–313.