

Mechanism of posterior malleolar fracture of the ankle

A cadaveric study

Naoki Haraguchi, MD^{a,*}, Robert S. Armiger, MSBME^b

Abstract

Objectives: Ankle fracture treatment involves reduction of the bone fragments and stabilization of the joint by reversing the mechanics of injury. For posterior malleolar fracture however, the true mechanism is not understood, leading to a lack of consistent guidance on how to best treat this injury.

Methods: Fifteen cadaver ankles were subjected to fracture loading that replicated the Lauge-Hansen pronation-external rotation mechanism. An axial load was applied to each specimen, which was mounted on a materials testing machine, and the foot was rotated externally to failure. Digital video cameras recorded the failure sequence of specific anatomic structures.

Results: Posterior malleolar fracture occurred in 7 specimens. Of these, 1 was an intra-articular fracture, another was a fracture involving the entire posterior tibial margin consisting of 2 fragments: that of the posterior tubercle and that of the posteromedial margin of the tibial plafond, with the former judged to be a consequence of avulsion by the posterior inferior tibiofibular ligament and the latter a consequence of axial loading from the talus. In the remaining 5 specimens, the posterior malleolar fracture was a small extra-articular avulsion fracture.

Conclusions: Fractures at the posterolateral corner of the distal tibia were shown to be avulsion fractures attributed to the posterior inferior tibiofibular ligament and produced by external rotation of the talus. A fracture involving the entire posterior tibial margin consisting of 2 fragments can be produced by a combination of avulsion by the posterior inferior tibiofibular ligament and axial loading from the talus.

Keywords: ankle fracture, posterior malleolar fracture, fracture mechanism, mechanical testing

1. Introduction

Functional outcomes following ankle fracture involving the posterior malleolus have been reported to be poor,^[1-3] and fixation of the posterior marginal fragment remains a controversial issue in the management of such ankle fractures. Historically,

the size of the fragment has been a major determining factor, and internal fixation has traditionally been recommended only for a posterior fragment that involves at least 25% of the tibial plafond.^[2,4,5] However, in recent years, there have been numerous reports of aggressive fixation even in cases of a relatively small posterior malleolar fragment.^[6-23]

The enthusiasm for surgical fixation of these fractures has evolved from the current trend toward more aggressive management of all periarticular fractures and the belief that restoration of near-normal direct anatomic repair of the tibial insertion of the posterior tibiofibular ligament will result in better outcomes. There is also growing interest in surgical repair of avulsion of the posterior tibiofibular ligament from bone in the absence of avulsion fracture, an injury that cannot be diagnosed by computed tomography (CT). One of the major sources of the considerable enthusiasm for surgical fixation has been the recent CT-based elucidation of posterior malleolar fracture morphology.^[24-27] In the treatment of fractures, not only is an understanding of the fracture morphology important but also that of the fracture mechanism. Knowing the mechanism of injury helps guide appropriate fracture treatment. The optimal reduction technique and stabilization method can be chosen on the basis of the specific fracture mechanism.^[28-34]

Several mechanisms for posterior malleolar fracture have been proposed: avulsion by the posterior inferior tibiofibular ligament,^[35-37] pressure from the externally rotating talus,^[35,37] pressure from the lateral malleolar fragment,^[36] and axial loading from the talus.^[38] Several authors have recently inferred the fracture mechanism on the basis of the CT-depicted morphology,^[24,27,39] and a large posterior malleolar fracture

Source of Funding: Nil.

This paper describes a study we conducted as a follow-up to a study published in another journal in 2009 (Haraguchi N, Armiger RS. A new interpretation of the mechanism of ankle fracture. *J Bone Joint Surg Am.* 2009 Apr;91(4):821-9.)

The authors have no conflicts of interest to disclose. The Postmortem Human Subjects were acquired through the licensed State Anatomy Board, Department of Health and Mental Hygiene, Baltimore, MD.

Supplemental Digital Content is available for this article.

^a Department of Orthopaedic Surgery, St. Marianna University Yokohama Seibu Hospital, Asahi-ku, Yokohama, Kanagawa, Japan, ^b Applied Physics Laboratory, The Johns Hopkins University, Laurel, MD.

* Corresponding author. Address: Department of Orthopaedic Surgery, St. Marianna University Yokohama Seibu Hospital, 1197-1 Yasashicho, Asahi-ku, Yokohama, Kanagawa 241-0811, Japan. Tel: +81 45 366 1111; fax: +81 45 366 1190. E-mail address: naokihg@aol.com (N. Haraguchi).

Copyright © 2020 The Authors. Published by Wolters Kluwer Health, Inc. on behalf of the Orthopaedic Trauma Association.

This is an open access article distributed under the terms of the Creative Commons Attribution-Non Commercial-No Derivatives License 4.0 (CCBY-NC-ND), where it is permissible to download and share the work provided it is properly cited. The work cannot be changed in any way or used commercially without permission from the journal.

OTA (2020) e060

Received: 24 January 2019 / Accepted: 8 December 2019

Published online 23 April 2020

<http://dx.doi.org/10.1097/OI9.000000000000060>

with medial extension is often referred to as a posterior pilon fracture^[18,22,40–42] because it seems to be a result of axial loading forces exerted when the talus is forced into the distal tibia. The true mechanism of the posterior malleolar fracture is not fully understood.

We previously reported that a short oblique fracture of the distal end of the fibula can occur with the foot in the pronated position and that the pattern of ankle fracture is related directly to the applied load.^[43] At the time of our study and subsequent report, there was little debate regarding treatment of posterior malleolar fracture. Later debate led us to re-examine the videos and experimental records of posterior malleolar fracture that we had obtained at the time of our previous study so that we might elucidate the fracture mechanism. We report findings of our re-examination herein.

2. Materials and methods

Materials used in the study were 15 cadaver ankles without any intra-articular defect or degenerative change that had been subjected to fracture loading that replicated the Lauge-Hansen pronation-external rotation mechanism.^[43] The specimens had been obtained from apparently normal, fresh-frozen cadaveric lower extremities and had been stored at -20°C until the time of testing. Donors' average age was 79.5 years (range, 59–97 years) at the time of death (State Anatomy Board, Department of Health and Mental Hygiene, Baltimore, MD). Our study was deemed exempt from Institutional Review Board approval.

The testing protocol was previously reported with an emphasis on distal fibular fracture,^[43] however, details relevant to the observed posterior malleolar fractures are recapitulated in this report. In each specimen and with use of a cutting jig, upper tibial, and fibular osteotomies were performed at the level of the proximal tibiofibular joint. The soft tissues were removed to expose the superficial ligaments and interosseous membrane to allow adequate visualization during testing.

A medullary nail was inserted into the proximal tibia and then used to firmly attach the tibia to the jig. The proximal tibia and fibula were positioned in a square potting cup, and poly (methyl methacrylate) was poured into the cup to a level 2 to 3 cm distal to the proximal tibiofibular joint. The foot was clamped to a plate, and the specimen was then mounted on the load frame of a servohydraulic materials testing system (Model 858; MTS Systems Corp., Eden Prairie, MN) (Fig. 1A). Shims had been added to the foot plate so that it sloped 30° laterally and 15° anteriorly so that the foot would be pronated 30° and dorsiflexed 15° . We mounted the 30° pronated foot on the slider apparatus at 10° medial inclination, which resulted in 20° pronation of the foot relative to the tibia (Fig. 1A and B).

Axial force was applied to the shank at 100N/s and then maintained at 700N, at which point the tibia was rotated internally at a constant rate of $36^{\circ}/\text{s}$ to 90° maximum excursion. During testing, 3 digital video cameras were used to record the failure sequence of specific anatomic structures. After completion of each test, the specimen was dissected, and the posterior failure pattern was recorded.

3. Results

Posterior injury occurred in 11 of the 15 specimens, with posterior malleolar fracture occurring in 7 specimens and injury of the posterior inferior tibiofibular ligament occurring in the remaining 4. The posterior inferior tibiofibular ligament injuries

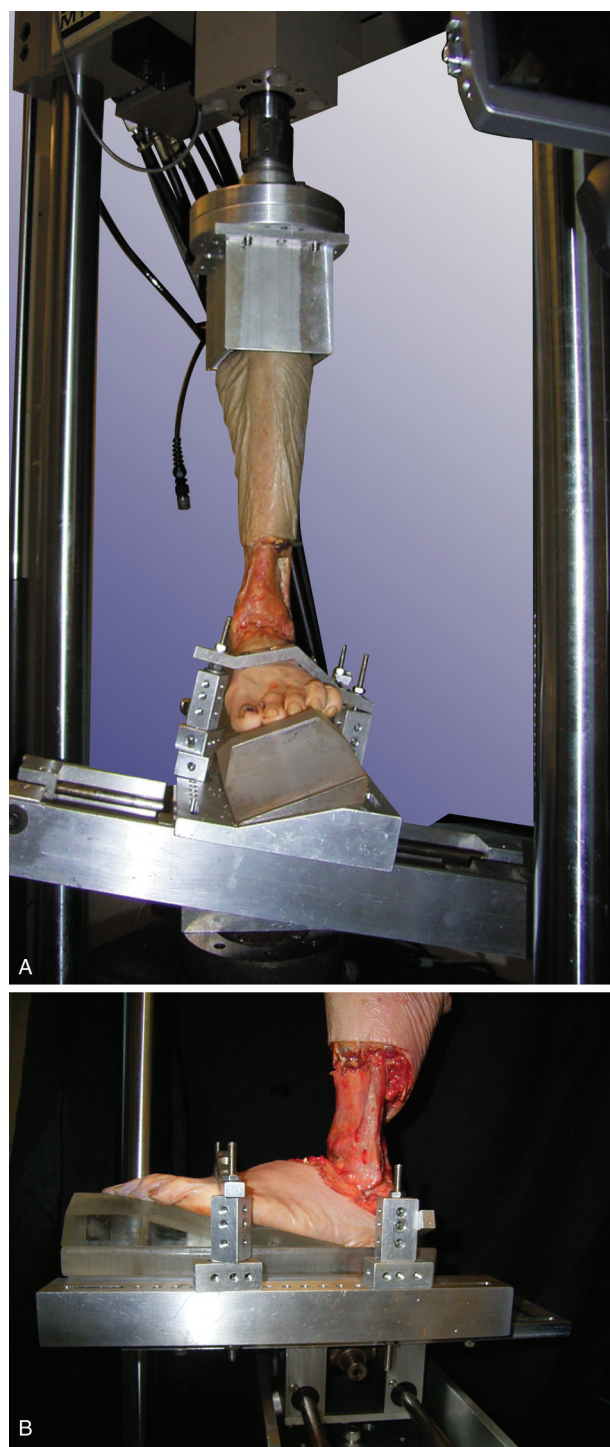


Figure 1. Test configuration. The specimen was mounted on the load frame of a servohydraulic materials testing system, with the foot in pronation relative to the tibia achieved by adding shims to the foot plate. (A) Anterior view. (B) Lateral view.

comprised 3 avulsions from the posterior tibial tubercle without any bony fragmentation (Fig. 2) and 1 mid-substance rupture of the posterior inferior tibiofibular ligament.

The posterior malleolar fractures included 1 intra-articular fracture at the posterior distal tibial tubercle (Fig. 3A and B) that was judged, on the basis of the video images, to be a consequence of avulsion by the posterior inferior tibiofibular ligament. The fragment was attached to the posterior inferior tibiofibular

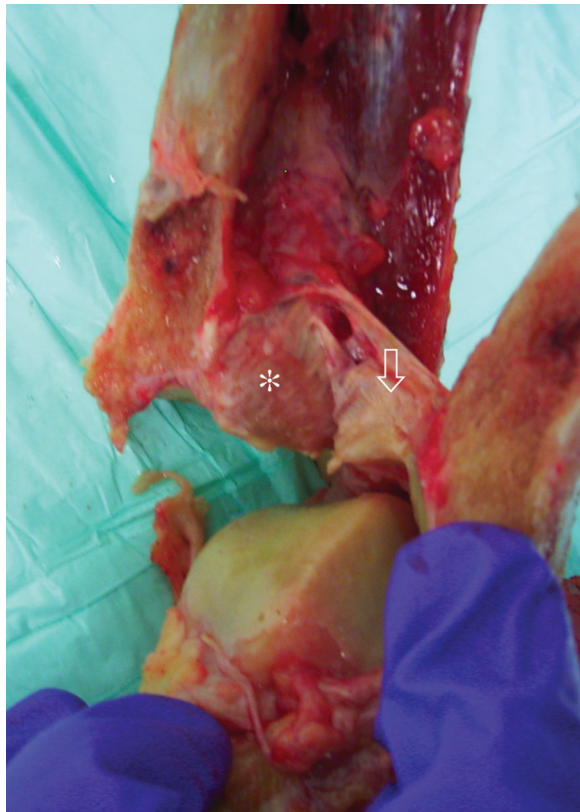


Figure 2. A specimen showing avulsion of the posterior inferior tibiofibular ligament (arrow) from the posterior tibial tubercle (asterisk) without bone fragmentation.

ligament. Another was a fracture involving the entire posterior tibial margin and consisting of 2 fragments, that of the posterior tubercle and that of the posteromedial margin of the tibial plafond. The former was judged, on the basis of the video images,

to be a consequence of avulsion by the posterior inferior tibiofibular ligament and the latter a consequence of axial loading from the talus (Fig. 4). The remaining 5 posterior malleolar fractures were small extra-articular avulsion fractures attributed to the posterior inferior tibiofibular ligament, to which the fragments were attached. All specimens with a posterior malleolar fracture included a short oblique fracture of the fibula with the disruption of the anterior tibiofibular ligament complex as well as medial injury.

The fractures as they occurred are shown in Videos 1 (Supplemental Digital Contents 1 (Avulsion fracture attributed to the posterior tibiofibular ligament occurring after oblique fracture of the distal fibula.), <http://links.lww.com/OTAI/A7> and 2 (Fracture involving the entire posterior tibial margin and consisting of 2 fragments: that of the posterior tubercle and that of the posteromedial margin of the tibial plafond. The former was judged, on the basis of the video images, to be a consequence of avulsion by the posterior inferior tibiofibular ligament and the latter a consequence of axial loading from the talus.), <http://links.lww.com/OTAI/A8>).

4. Discussion

Although several researchers have attempted to understand the mechanisms of ankle fracture on the basis of postinjury radiographs or CT images, it is nearly impossible to determine the fracture mechanisms from the fracture morphology and position of the talus seen on such images.^[27,39,44-46] Biomechanical study, mechanical testing in particular, has provided strong evidence for the specific mechanisms of injuries such as forearm fracture,^[47] acetabular fracture,^[48] talar fracture,^[49] and pilon fracture.^[50]

Although extensive biomechanical analyses have been performed to clarify the various mechanisms of ankle fracture,^[51-55] few investigators have been able to simulate posterior malleolar fracture.^[52-55] In experiments performed to examine ankle fractures, Schaffer and Manoli^[54] were unable to produce

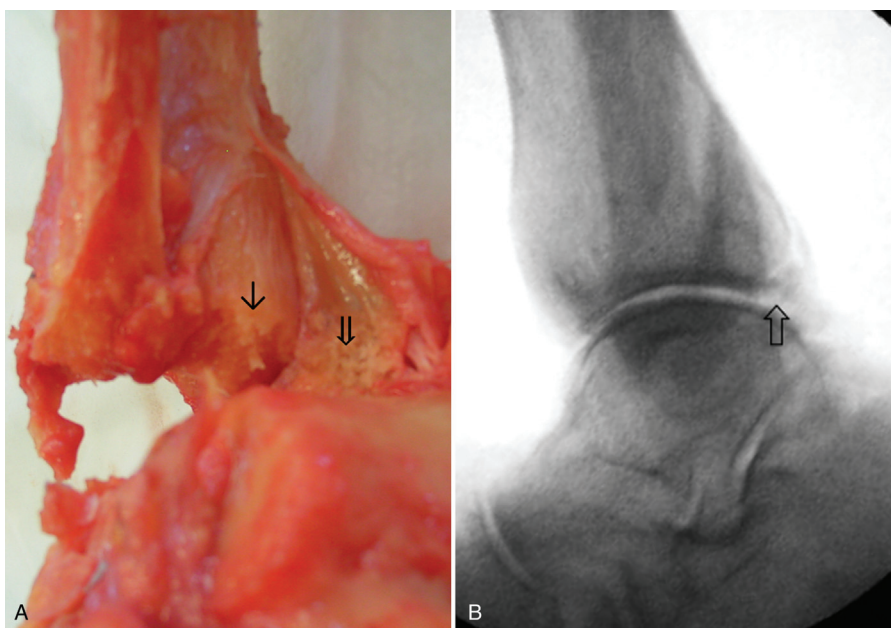


Figure 3. Intra-articular avulsion fracture attributed to the posterior inferior tibiofibular ligament. (A) Photograph showing the fracture site at the posterior tibial tubercle (arrow) and avulsed bone fragment (open arrow). (B) Lateral radiograph of the same specimen showing the posterior malleolar fragment (white arrow).

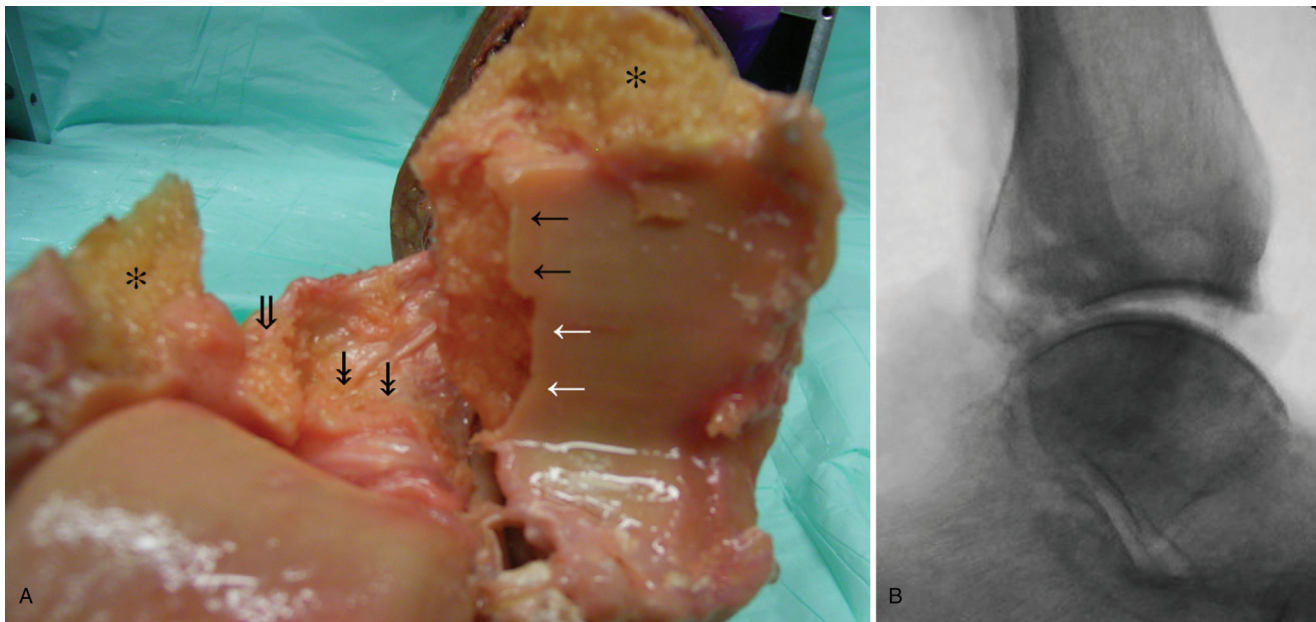


Figure 4. A specimen showing a fracture involving the entire posterior tibial margin and consisting of 2 fragments: (A) Photograph of the specimen showing a fracture involving the entire posterior tibial margin and consisting of 2 fragments, that is, a fragment of the posterior tubercle and a fragment of the posteromedial margin of the tibial plafond. Black arrows show the fracture site from which the fragment of the posterior tubercle (open black arrow) was avulsed, and white arrows show the fracture site where the fracture of the posteromedial margin of the tibial plafond (double-headed arrow) occurred. Note the fracture site at the lateral malleolus (asterisk). (B) Lateral radiograph of the same specimen showing a posterior malleolar fracture with posterior subluxation of the talus.

posterior malleolar fracture or damage to the posterior tibiofibular ligament. Michelson et al^[53] were also unable to produce posterior malleolar fracture. Stiehl et al^[55] produced ankle fractures in 26 specimens, but posterior injury was not observed in any. The true mechanism of posterior malleolar fracture has remained unclear. In the study described herein, we were able to confirm that the fractures at the posterolateral corner of the distal tibia (i.e., Type I according to the CT-based Haraguchi fracture classification^[2,51]) were posterior inferior tibiofibular ligament avulsion fractures resulting from external rotation of the talus. Furthermore, we successfully produced a fracture involving the entire posterior tibial margin and consisting of 2 fragments (i.e., Haraguchi Type II^[2,51]); with the fragment of the posterior tubercle judged to be a consequence of avulsion by the posterior inferior tibiofibular ligament and the fragment of the posteromedial margin of the tibial plafond a consequence of axial loading from the talus.

Recently, several authors inferred the fracture mechanism from CT-depicted fracture morphology,^[24,27,39,46,56] and a large posterior malleolar fracture with medial extension is often referred to as a posterior pilon fracture^[16,22,40–42] because, as mentioned above, it seems to be the result of axial loading forces exerted when the talus is forced into the distal tibia. Mechanisms proposed for this fracture pattern differ: from an abduction external rotation force combined with high axial loading,^[57] to forced hyperplantarflexion,^[45,56] to rotational and axial loading combined.^[5] Vosoughi et al^[46] classified the medial fragment of the fracture involving the entire posterior tibial margin with 2 fragments into 2 categories: small avulsion-type fracture and large pilon-type fracture. They speculated that the small medial fragment is produced by the pull of the intermalleolar ligament, and that the lateral fragment is produced by impaction of the talus into the tibial plafond. They speculated that the pilon-type fracture is produced by an axially loaded talus rotating in the

ankle mortise, first impacting the posterolateral corner of the tibia and then, as it continues to rotate, fracturing the posteromedial corner.^[46] The varying theories regarding the mechanism of posterior malleolus fracture are probably the result of a lack of real biomechanical evidence, with most of the theories arising out of speculation based on postinjury images. It was clear in our study that posterolateral fracture of the tibial plafond was always produced by the pull of the posterior tibiofibular ligament, even in the case of medial extension-type malleolus fracture with 2 fragments.

Pilon fracture has been defined as “a comminuted fracture of the distal tibia and fibula with severe involvement of the tibial plafond, usually as a result of a fall from a height, driving the talus superiorly into the tibia.”^[58] In the instances of posterior malleolar fracture involving the entire posterior plafond, we found that the lateral part of the fracture was caused by a rotational force, not by an axial force. Hence, it is questionable whether pilon fracture is a suitable term for this type of fracture.

The indications for fixation of posterior malleolar fractures have been much debated. Treatment of posterior malleolar fracture^[5,17,59] has recently undergone rapid and widespread change, and there have been many reports of aggressive fixation of such fractures.^[4,6–23] Fixation of the posterior tibial tubercle fragment even in cases of Weber type B fracture (to avoid the need for syndesmosis screw fixation) has been recommended.^[5,13,14,60] White^[61] has strongly warned against the trend toward aggressive fixation because clinical studies have failed to show any significant improvement in patient outcomes, and furthermore have also confirmed an inevitable increased rate in complications. Our study results may provide insight into this issue. Because avulsion fracture of the posterolateral corner of the tibia was produced purely by rotational force, restoration of the lateral and medial components of the ankle provides

stability. Whether fixation of the posterior tibial tubercle fragment is indicated may be determined according to the criteria used for syndesmosis fixation, such as the height of the fibular fracture,^[62–67] or by intraoperative assessment of syndesmosis instability.^[68] Blom et al,^[69] in their study of 194 patients with a surgically treated ankle fracture, showed clearly that posterior malleolar ankle fractures with medial extension of the fracture line (i.e., Haraguchi Type II posterior malleolar fracture^[2,51]) are associated with significantly poorer functional outcomes, partly due to the lack of direct fixation of the posteromedial fragment. Because the posteromedial fragment is produced by axial loading, ankle stability can be obtained only by direct fixation of the fragment.

Our study was limited by lack of muscle-tendon units, and we recognize that the bone quality of the ankles, which had been obtained from cadavers of elderly persons, could have influenced our test results. In addition, the load was applied more slowly than during an actual traumatic event. If we had had muscle-tendon units, the ankle joint would have been more stable, and thus the incidence of posterior malleolar fracture and the size of the fractures would have differed from those that we observed. Both bone quality and loading rate can affect the failure mode. Tensile testing of the femur-anterior cruciate ligament-tibia complex has shown the major mode of failure to be ligament disruption in young adults and avulsion fracture in older adults.^[70] Further, the loading rate has been shown to affect the pattern of bone-ligament-bone complex failure, with slow loading tending to result in avulsion fracture and faster loading tending to result in ligament disruption.^[71]

In conclusion, we found fractures at the posterolateral corner of the distal tibia to be avulsion fractures resulting from avulsion of the posterior inferior tibiofibular ligament caused by external rotation of the talus. Furthermore, we successfully produced a fracture involving the entire posterior tibial margin and consisting of 2 fragments, with the posterior tubercle fragment judged to be a consequence of avulsion by the posterior inferior tibiofibular ligament and the posteromedial marginal fragment of the tibial plafond a consequence of axial loading from the talus. Understanding the injury mechanism of posterior malleolar fracture may provide insight into the indications for fixation and the optimal stabilization method.

References

- Jaskulka RA, Ittner G, Schedl R. Fractures of the posterior tibial margin: their role in the prognosis of malleolar fractures. *J Trauma*. 1989;29:1565–1570.
- McDaniel WJ, Wilson FC. Trimalleolar fractures of the ankle. An end result study. *Clin Orthop Relat Res*. 1977;37–45.
- Tejwani NC, Pahk B, Egol KA. Effect of posterior malleolus fracture on outcome after unstable ankle fracture. *J Trauma*. 2010;69:666–669.
- De Vries JS, Wiggman AJ, Siersevelt IN, et al. Long-term results of ankle fractures with a posterior malleolar fragment. *J Foot Ankle Surg*. 2005;44:211–217.
- Irwin TA, Lien J, Kadakia AR. Posterior malleolus fracture. *J Am Acad Orthop Surg*. 2013;21:32–40.
- Bali N, Aktseelis I, Ramasamy A, et al. An evolution in the management of fractures of the ankle: safety and efficacy of posteromedial approach for Haraguchi type 2 posterior malleolar fractures. *Bone Joint J*. 2017;99-B:1496–1501.
- Duan X, Kadakia AR. Operative treatment of posterior malleolar fractures. *Open Orthop J*. 2017;11:732–742.
- Erdem MN, Erken HY, Burc H, et al. Comparison of lag screw versus buttress plate fixation of posterior malleolar fractures. *Foot Ankle Int*. 2014;35:1022–1030.
- Kim YJ, Lee JH. Posterior inferior tibiofibular ligament release to achieve anatomic reduction of posterior malleolar fractures. *J Foot Ankle Surg*. 2018;57:86–90.
- Hoogendoorn JM. Posterior malleolar open reduction and internal fixation through a posterolateral approach for trimalleolar fractures. *JBJS Essent Surg Tech*. 2017;7:e31.
- Levack AE, Warner SJ, Gausden EB, et al. Comparing functional outcomes after injury-specific fixation of posterior malleolar fractures and equivalent ligamentous injuries in rotational ankle fractures. *J Orthop Trauma*. 2018;32:e123–e128.
- Li M, Collier RC, Hill BW, et al. V. Comparing different surgical techniques for addressing the posterior malleolus in supination external rotation ankle fractures and the need for syndesmosis screw fixation. *J Foot Ankle Surg*. 2017;56:730–734.
- Mak MF, Stern R, Assal M. Repair of syndesmosis injury in ankle fractures: current state of the art. *EFORT Open Rev*. 2018;3:24–29.
- Miller MA, McDonald TC, Graves ML, et al. Stability of the syndesmosis after posterior malleolar fracture fixation. *Foot Ankle Int*. 2018;39:99–104.
- O'Connor TJ, Mueller B, Ly TV, et al. “A to p” screw versus posterolateral plate for posterior malleolus fixation in trimalleolar ankle fractures. *J Orthop Trauma*. 2015;29:e151–e156.
- Shi HF, Xiong J, Chen YX, et al. Comparison of the direct and indirect reduction techniques during the surgical management of posterior malleolar fractures. *BMC Musculoskelet Disord*. 2017;18:109.
- Solan MC, Sakellariou A. Posterior malleolus fractures: worth fixing. *Bone Joint J*. 2017;99:1413–1419.
- Sukur E, Akman YE, Gokcen HB, et al. Open reduction in pilon variant posterior malleolar fractures: radiological and clinical evaluation. *Orthop Traumatol Surg Res*. 2017;103:703–707.
- Tosun B, Selek O, Gok U, et al. Posterior malleolus fractures in trimalleolar ankle fractures: malleolus versus transyndesmal fixation. *Indian J Orthop*. 2018;52:309–314.
- Verhage SM, Boot F, Schipper IB, et al. Open reduction and internal fixation of posterior malleolar fractures using the posterolateral approach. *Bone Joint J*. 2016;98-B:812–817.
- Wang L, Shi ZM, Zhang CQ, et al. Trimalleolar fracture with involvement of the entire posterior plafond. *Foot Ankle Int*. 2011;32:774–781.
- Wang Y, Wang J, Luo CF. Modified posteromedial approach for treatment of posterior pilon variant fracture. *BMC Musculoskelet Disord*. 2016;17:328.
- Zhong S, Shen L, Zhao JG, et al. Comparison of posteromedial versus posterolateral approach for posterior malleolus fixation in trimalleolar ankle fractures. *Orthop Surg*. 2017;9:69–76.
- Bartonicek J, Rammelt S, Kostlivy K, et al. Anatomy and classification of the posterior tibial fragment in ankle fractures. *Arch Orthop Trauma Surg*. 2015;135:505–516.
- Haraguchi N, Haruyama H, Toga H, et al. Pathoanatomy of posterior malleolar fractures of the ankle. *J Bone Joint Surg Am*. 2006;88:1085–1092.
- Mangnus L, Meijer DT, Stufkens SA, et al. Posterior malleolar fracture patterns. *J Orthop Trauma*. 2015;29:428–435.
- Mason LW, Marlow WJ, Widnall J, et al. Pathoanatomy and associated injuries of posterior malleolus fracture of the ankle. *Foot Ankle Int*. 2017;38:1229–1235.
- Amis AA, Miller JH. The mechanisms of elbow fractures: an investigation using impact tests in vitro. *Injury*. 1995;26:163–168.
- Deutch SR, Jensen SL, Tyrdal S, et al. Elbow joint stability following experimental osteoligamentous injury and reconstruction. *J Shoulder Elbow Surg*. 2003;12:466–471.
- Funk JR, Srinivasan SC, Crandall JR. Snowboarder's talus fractures experimentally produced by eversion and dorsiflexion. *Am J Sports Med*. 2003;31:921–928.
- Ivancic PC. Axis ring fractures due to simulated head impacts. *Clin Biomech (Bristol, Avon)*. 2014;29:906–911.
- Ivancic PC. Odontoid fracture biomechanics. *Spine (Phila Pa 1976)*. 2014;39:E1403–E1410.
- Matsuura Y, Rokkaku T, Kuniyoshi K, et al. Smith's fracture generally occurs after falling on the palm of the hand. *J Orthop Res*. 2017;35:2435–2441.
- Wake H, Hashizume H, Nishida K, et al. Biomechanical analysis of the mechanism of elbow fracture-dislocations by compression force. *J Orthop Sci*. 2004;9:44–50.
- Hendelberg T. The roentgenographic examination of the ankle joint in malleolar fractures. *Acta Radiol*. 1946;27:23–42.

36. Lauge-Hansen N. Fractures of the ankle. II. Combined experimental-surgical and experimental-roentgenologic investigations. *Arch Surg.* 1950;60:957–985.
37. Harper MC, Hardin G. Posterior malleolar fractures of the ankle associated with external rotation-abduction injuries. Results with and without internal fixation. *J Bone Joint Surg Am.* 1988;70:1348–1356.
38. Macko VW, Matthews LS, Zwirkoski P, et al. The joint-contact area of the ankle. The contribution of the posterior malleolus. *J Bone Joint Surg Am.* 1991;73:347–351.
39. Yi Y, Chun DI, Won SH, et al. Morphological characteristics of the posterior malleolar fragment according to ankle fracture patterns: a computed tomography-based study. *BMC Musculoskelet Disord.* 2018;19:51.
40. Switaj PJ, Weatherford B, Fuchs D, et al. Evaluation of posterior malleolar fractures and the posterior pilon variant in operatively treated ankle fractures. *Foot Ankle Int.* 2014;35:886–895.
41. Chen DW, Li B, Aubeeluck A, et al. Open reduction and internal fixation of posterior pilon fractures with buttress plate. *Acta Orthop Bras.* 2014;22:48–53.
42. Klammer G, Kadakia AR, Joos DA, et al. Posterior pilon fractures: a retrospective case series and proposed classification system. *Foot Ankle Int.* 2013;34:189–199.
43. Haraguchi N, Armiger RS. A new interpretation of the mechanism of ankle fracture. *J Bone Joint Surg Am.* 2009;91:821–829.
44. Boszczyk A, Fudalej M, Kwapisz S, et al. X-ray features to predict ankle fracture mechanism. *Forensic Sci Int.* 2018;291:185–192.
45. Gardner MJ, Boraiah S, Hentel KD, et al. The hyperplantarflexion ankle fracture variant. *J Foot Ankle Surg.* 2007;46:256–260.
46. Vosoughi AR, Jayatilaka MLT, Fischer B, et al. CT analysis of the posteromedial fragment of the posterior malleolar fracture. *Foot Ankle Int.* 2019;40:648–655.
47. McGinley JC, Hoppood BC, Gaughan JP, et al. Forearm and elbow injury: the influence of rotational position. *J Bone Joint Surg Am.* 2003;85:2403–2409.
48. Lansinger O, Romanus B, Goldie IF. Fracture mechanism in central acetabular fractures. An experimental study. *Arch Orthop Trauma Surg.* 1979;94:209–212.
49. Boon AJ, Smith J, Zobitz ME, et al. Snowboarder's talus fracture. Mechanism of injury. *Am J Sports Med.* 2001;29:333–338.
50. Tochigi Y, Buckwalter JA, Martin JA, et al. Distribution and progression of chondrocyte damage in a whole-organ model of human ankle intra-articular fracture. *J Bone Joint Surg Am.* 2011;93:533–539.
51. De Souza Dias L, Foerster TP. Traumatic lesions of the ankle joint. The supination-external rotation mechanism. *Clin Orthop Relat Res.* 1974;219–224.
52. Markolf KL, Schmalzried TP, Ferkel RD. Torsional strength of the ankle in vitro. The supination-external-rotation injury. *Clin Orthop Relat Res.* 1989;266–272.
53. Michelson J, Solocoff D, Waldman B, et al. Ankle fractures. The Lauge-Hansen classification revisited. *Clin Orthop Relat Res.* 1997;198–205.
54. Schaffer JJ, Manoli A 2nd. The antiglide plate for distal fibular fixation. A biomechanical comparison with fixation with a lateral plate. *J Bone Joint Surg Am.* 1987;69:596–604.
55. Stiehl JB, Skrade DA, Johnson RP. Experimentally produced ankle fractures in autopsy specimens. *Clin Orthop Relat Res.* 1992;244–249.
56. Zhang J, Wang H, Pen C, et al. Characteristics and proposed classification system of posterior pilon fractures. *Medicine (Baltimore).* 2019;98:e14133.
57. Karachalios T, Roidis N, Karoutis D, et al. Trimalleolar fracture with a double fragment of the posterior malleolus: a case report and modified operative approach to internal fixation. *Foot Ankle Int.* 2001;22:144–149.
58. Hoppenfeld S, Michael ZS. *Orthopaedic Dictionary.* Philadelphia, PA: J. B. Lippincott; 1993; 309.
59. Bartoníček J, Rammelt S, Tuček M. Posterior malleolar fractures: changing concepts and recent developments. *Foot Ankle Clin.* 2017;22:125–145.
60. Miller AN, Carroll EA, Parker RJ, et al. Posterior malleolar stabilization of syndesmotic injuries is equivalent to screw fixation. *Clin Orthop Relat Res.* 2010;468:1129–1135.
61. White TO. In defence of the posterior malleolus. *Bone Joint J.* 2018;100-B:566–569.
62. Boden SD, Labropoulos PA, McCowin P, et al. Mechanical considerations for the syndesmosis screw. A cadaver study. *J Bone Joint Surg Am.* 1989;71:1548–1555.
63. Chissell HR, Jones J. The influence of a diastasis screw on the outcome of Weber type-C ankle fractures. *J Bone Joint Surg Br.* 1995;77:435–438.
64. Kennedy JG, Soffe KE, Dalla Vedova P, et al. Evaluation of the syndesmotic screw in low Weber C ankle fractures. *J Orthop Trauma.* 2000;14:359–366.
65. Kortekangas TH, Pakarinen HJ, Savola O, et al. Syndesmotic fixation in supination-external rotation ankle fractures: a prospective randomized study. *Foot Ankle Int.* 2014;35:988–995.
66. van den Bekerom MP, Haverkamp D, Kerkhoffs GM, et al. Syndesmotic stabilization in pronation external rotation ankle fractures. *Clin Orthop Relat Res.* 2010;468:991–995.
67. Yamaguchi K, Martin CH, Boden SD, et al. Operative treatment of syndesmotic disruptions without use of a syndesmotic screw: a prospective clinical study. *Foot Ankle Int.* 1994;15:407–414.
68. Van Heest TJ, Lafferty PM. Injuries to the ankle syndesmosis. *J Bone Joint Surg Am.* 2014;96:603–613.
69. Blom RP, Meijer DT, de Muinck Keizer RO, et al. Posterior malleolar fracture morphology determines outcome in rotational type ankle fractures. *Injury.* 2019;50:1392–1397.
70. Noyes FR, Grood ES. The strength of the anterior cruciate ligament in human and rhesus monkeys. Age-related and species-related changes. *J Bone Joint Surg Am.* 1976;58:1074–1082.
71. Noyes FR, DeLucas JL, Torvik PJ. Biomechanics of anterior cruciate ligament failure: an analysis of strain-rate sensitivity and mechanisms of failure in primates. *J Bone Joint Surg Am.* 1974;56:236–253.