

Pilomatrix Carcinoma in the Chest Wall Around an Eloesser Open Window

— A case report —

In-Seok Jeong, M.D.*, Bong-Suk Oh, M.D.*, Soon-Jin Kim, M.D.*, Chi-Hyeong Yun, M.D.*,
Min-Sun Beom, M.D.*, Do-Wan Kim, M.D.*

Pilomatrix carcinoma originates in the matrix cell and is marked by exophytic growing and common local recurrence. There is no established treatment for wide local invasion and metastasis of the pilomatrix besides wide surgical resection. We report a case of rapidly progressive pilomatrix carcinoma, which arose around an Eloesser open window with direct invasion to the adjacent tissue.

Key words: 1. Chest wall
2. Neoplasm
3. Chest wall neoplasms

CASE REPORT

The patient was a 47-year-old male who had undergone an Eloesser procedure due to intractable empyema from a traumatic esophageal rupture in our hospital. During outpatient follow-up at the other hospital, he visited the hospital due to multiple raised masses and pain he was experiencing around the open wound boundary of an Eloesser open flap he had undergone 17 months prior. One month before being transferred to our hospital, he was suffering from multiple erythematous nodules around the open window, which became larger and elevated lesions, and then grew rapidly and showed bleeding and pus for the 2 weeks prior to presenting at our hospital.

The patient had undergone surgery for the primary repair of the lower esophagus through a left thoracotomy after trauma, which had been performed one month earlier. He was

transferred to our hospital because of leakage from the primary repair site on postoperative day 10. After performing a closed thoracostomy in the left thorax, we administered broad spectrum antibiotics for mediastinitis with the patient fasting. On the seventh day after the transfer, we performed a laparotomy and interposed the right colon conduit between the cervical esophagus and the stomach, placing it substernally. He started oral intake on the seventh postoperative day. However, he required surgery for the Eloesser's open flap procedure due to intractable left side empyema, and was transferred to a hospital near his home.

Biopsy of the masses confirmed that the diagnosis was pilomatrix carcinoma (Fig. 1). Positron Emission Tomography (PET) (Fig. 2) identified lesions with a standardized uptake value over 8.0 on the chest wall around the open wound, the intrathoracic area, and in the left lower lobe. Radiation therapy was therefore initiated. The mass increased in size with

*Department of Thoracic and Cardiovascular Surgery, Chonnam National University Hospital, College of Medicine, Chonnam National University
Received: September 6, 2010, Revised: October 17, 2010, Accepted: May 11, 2011

Corresponding author: Bong-Suk Oh, Department of Thoracic and Cardiovascular Surgery, Chonnam National University Hospital, College of Medicine, Chonnam National University, 5, Hak 1-dong, Dong-gu, Gwangju 501-757, Korea
(Tel) 82-62-220-6546 (Fax) 82-62-227-1636 (E-mail) bsoh@chonnam.ac.kr

© The Korean Society for Thoracic and Cardiovascular Surgery. 2011. All right reserved.

© This is an open access article distributed under the terms of the Creative Commons Attribution Non-Commercial License (<http://creativecommons.org/licenses/by-nc/3.0>) which permits unrestricted non-commercial use, distribution, and reproduction in any medium, provided the original work is properly cited.

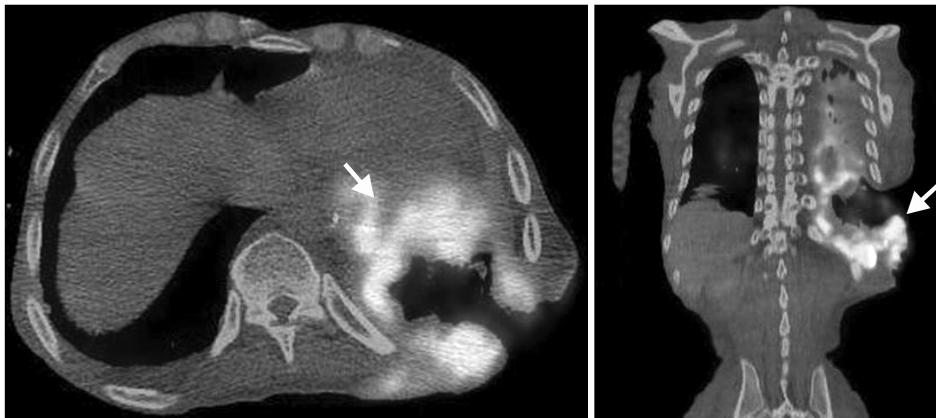

Fig. 1. Whole body PET-CT reveals the hypermetabolic lesions in left lower chest wall around Eloessor open window with widely direct invasion to pleural cavity and left lower lung.

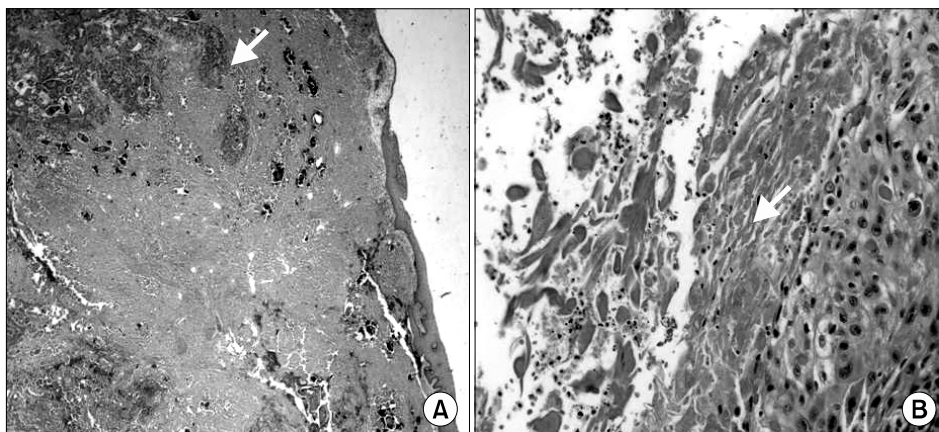


Fig. 2. (A) Infiltrative atypical cell nests with calcification were shown below epidermis (H&E, ×20). (B) Abrupt keratinization, suggestive for trichilemmal differentiation, was shown (H&E, ×200).

out responding to the treatment and the patient's condition grew poor. Radiation therapy was discontinued. Treatment was halted and the patient was transferred to a hospital for hospice care. He died in supportive care 6 months after the initial diagnosis.

DISCUSSION

Malherbe and Chenantais [1] reported pilomatrixoma to be a benign mass originating from the sebaceous glands for the first time in 1880. Lever and Griesemer [2] reported it to be a benign mass originating from the pilomatrix in 1949. Pilomatrix carcinoma is so rare a disease that only 80 cases have been reported since Gromiko [3] observed pilomatrix carcinoma invading adjacent tissues and recurring for the first time in 1927.

The mean age of the patients who are diagnosed is 46

years. The ratio of male to female occurrence is 3 to 1. The most common site of pilomatrix carcinoma is the head and neck, occurring in 60% of patients, and followed by upper extremities, trunk, lower extremities [4]. In contrast, pilomatrixoma affects males to females in a ratio of 2 to 3, and tends to occur in patients under 20 years of age, which accounts for about 60% of patients [5].

Pilomatrix carcinoma is a locally invasive tumor which exhibits exophytic growth and often recurs. Without wide resection, simple excision can result in local recurrences in over 60% of patients [6]. Distant metastasis is very rare. There have only been 8 reported cases of metastasis to the lymph nodes, lungs, or bone since 1984. Gould et al. [7] reported the first case of distant metastasis to both lungs, which occurred 4 years after operative excision. Metastases were identified from 4 months to 4 years after the first diagnosis. Mean life expectancy was reported to be from 3 months to 2

years. If wide local invasion or metastasis is identified, surgical excision and postoperative radiation therapy or chemotherapy can be done, but there are no standard treatments known to produce good results [8]. The present case under study showed a rapid and direct growth and invasion of pilomatrix carcinoma originating from the skin around the Eloesser flap, into the thorax and lungs through the open wound. Postoperative radiotherapy after simple excision of an elevated mass may not be an adequate treatment. If a mass is confirmed as a pilomatrix carcinoma, a wide resection including adjacent normal tissues must be performed.

REFERENCES

1. Malherbe A, Chenantais J. *Note sur l'epitheliome calcifie des glandes sebées*. Prog Med 1880;8:826-8.
2. Lever WF, Griesemer RD. *Calcifying epithelioma of Malherbe; report of 15 cases, with comments on its differentiation from calcified epidermal cyst and on its histogenesis*. Arch Derm Syphilol 1949;59:506-18.
3. Gromiko N. *Zur Kenntnis der bosartigen Umwandlung des verkalkten Hautepithelioms*. Arch Pathol Anat 1927;265:103-16.
4. Bassarova A, Nesland JM, Sedloev T, Danielsen H, Christova S. *Pilomatrix carcinoma with lymph node metastases*. J Cutan Pathol 2004;31:330-5.
5. Hashimoto K, Lever WF. *Tumors of skin appendages*. In: Freedberg IM, Eisen AZ, Wolff K, et al. *Fitzpatrick's dermatology in general medicine*. 5th ed. New York: McGraw-Hill. 1999;904-6.
6. Khammash MR, Todd DJ, Abalkhail A. *Concurrent pilomatrix carcinoma and giant pilomatrixoma*. Australas J Dermatol 2001;42:120-3.
7. Gould E, Kurzon R, Kowaczyk AP, Saldana M. *Pilomatrix carcinoma with pulmonary metastasis*. Cancer 1984;54:370-2.
8. Bremnes RM, kvamme JM, Stalsberg H, Jacobson EA. *Pilomatrix carcinoma with multiple metastasis: report of a case and review of the literature*. Eur J Cancer 1999;35:433-7.