

## Delayed Presentation in Chiari Malformation

### Abstract

**Introduction:** Chiari malformations are a group of clinicopathological entities with a variety of clinical presentations, different pathophysiology, and variable outcomes. It has a typical set of clinical presentation. In this study is to observe the different clinical presentations of the patients with Chiari malformation in our population. As the time of initial presentation is delayed that might change the sign and symptoms with which patient initially presents. **Materials and Methods:** This was a cross-sectional observational study with prospectively collected data of 46 patients with Chiari malformation. The duration of the study is from 2017 to 2020. Patient's data will be compiled and analyzed through Statistical Package for Social Sciences (SPSS) Version 25. Qualitative variables are presented as frequencies and percentages. Quantitative variables are presented as mean  $\pm$  standard deviation. Effect modifiers are controlled through stratification. The Chi-square test is used for finding association between categorical variables.  $P \leq 0.05$  is considered as statistically significant. **Results:** According to our data 36% of our patients presented with motor weakness which is followed by sensory deficit, however in previous literature headache was the commonest clinical presentation. **Conclusion:** Clinical presentation in our population differs from other studies and the reason behind this is the delayed presentation of the patient and lack of awareness of disease and ultimately it will alter the outcome of disease and treatment.

**Keywords:** Chiari presentation, chiari, clinical symptoms

### Background

Chiari malformations are a group of clinicopathological entities with a variety of clinical presentations, different pathophysiology, and variable outcomes. Cerebellar ectopia is the term used to describe this condition. The first case was reported in 1883 by Cleland, and later in 1891 detailed description was done by a pathologist Professor Chiari.<sup>[1,2]</sup>

This syndrome is a developmental malformation of the occipital mesodermal somite that express as herniation of variable degree of different hindbrain structures, commonly associated with hydrocephalous and syringomyelia. This syndrome is divided into five subtypes.

Chiari Type 1 malformation is the caudal descent of cerebellar tonsils through the foramen magnum up to 3–5 mm.<sup>[3,4]</sup> Chiari Type 2 was described in 1896 and consists of the descent of cerebellar vermis, fourth ventricle, and lower brain stem and has a strong association with myelomeningocele. This type is called Arnold Chiari

malformation and this is the most common form of Chiari malformation among its sub-types.<sup>[3,5]</sup> Chiari Type 3 malformation is associated with the presence of occipital encephalocele with hindbrain structures in it.<sup>[3]</sup> Chiari Type 4 malformation is the cerebellar hypoplasia without the actual herniation and it is the least common form.<sup>[3]</sup> A relatively new subtype of Chiari malformation was described in the past few years, it consists of an alteration of Cerebrospinal Fluid (CSF) dynamics at the foramen magnum level. It also has some tilt of the brain stem including pons and medulla and it has a low level of obex.<sup>[6,7]</sup> Another rare form of Chiari malformation was described, this subgroup has caudal cerebellar displacement and cerebellar ectopia without spina bifida. This term was coined as Chiari 1.5.<sup>[8]</sup>

In Chiari malformation Type 1, there is overcrowding of posterior fossa<sup>[9]</sup> and this is associated with other conditions that are not directly related to the hypoplasia of the skull base. These conditions include hydrocephalous,<sup>[5]</sup> tethered cord syndrome,<sup>[9]</sup> craniosynostosis,<sup>[10]</sup> intracranial mass,<sup>[11]</sup> and some connective tissue disorders.<sup>[12]</sup> Some

This is an open access journal, and articles are distributed under the terms of the Creative Commons Attribution-NonCommercial-ShareAlike 4.0 License, which allows others to remix, tweak, and build upon the work non-commercially, as long as appropriate credit is given and the new creations are licensed under the identical terms.

For reprints contact: WKHLRPMedknow\_reprints@wolterskluwer.com

**How to cite this article:** Rafay M, Gulzar F, Jafri HM, Sharif S. Delayed presentation in chiari malformation. *Asian J Neurosurg* 2021;16:701-5.

**Submitted:** 21-Mar-2021 **Revised:** 17-May-2021  
**Accepted:** 07-Jun-2021 **Published:** 18-Dec-2021

**Muhammad Rafay,  
Farhan Gulzar,  
Hassan Masood  
Jafri,  
Salman Sharif**

*Department of Neurosurgery,  
Liaquat National Hospital,  
Karachi, Pakistan*

### Address for correspondence:

*Dr. Muhammad Rafay,  
Department of Neurosurgery,  
Liaquat National Hospital,  
National Stadium Road,  
Karachi 74800, Pakistan.  
E-mail: drmuhammadrafay@  
yahoo.com*

### Access this article online

**Website:** www.asianjns.org

**DOI:** 10.4103/ajns.AJNS\_120\_21

### Quick Response Code:



causes explain the diversity of clinical presentation of patients with Chiari malformation.

The clinical presentation of Chiari malformation is usually due to either cerebellar compression, brain stem compression, syringomyelia, hydrocephalous, or hydromyelia (impairment of normal CSF circulation). According to some studies, the majority of symptoms are due to spinal cord syrinx formation.<sup>[13-15]</sup> Patients can present with pain, weakness, and/or sensory disturbance involving the upper limbs. Signs on presentation are hand muscle atrophy and weakness, lower limb spasticity, sensory dysaesthesia, urinary incontinence, or scoliosis.

Strain-related headaches are typical for disturbances in normal CSF flow. Valsalva-related activities all are considered as trigger factors for this type of headaches. These headaches are brief and localized to the occipital region occurs in 80%–100% of the cases.<sup>[16]</sup> There may be some atypical headaches such as generalized and retro-orbital headaches and these are longer in duration.<sup>[17]</sup> Patients with Chiari zero may present with these types of symptoms.<sup>[6]</sup> This CSF dynamics can also disturb perilymph flow and this is responsible for symptoms such as tinnitus, dizziness, and hearing loss.<sup>[14]</sup>

Visual impairments including blurring of vision, diplopia, and nystagmus are common signs of brain stem compression in Chiari malformation,<sup>[18]</sup> and downbeat nystagmus is characteristic of Craniovertebral junction abnormalities occurs in 75% of cases.<sup>[19]</sup> This occurs due to impaired function of the brain stem nuclei and traction on cranial nerves, especially the 4<sup>th</sup>, 6<sup>th</sup>, and 3<sup>rd</sup> cranial nerves. Brain stem descent causes compression and traction on cerebellar pathways and result in balance difficulties and usually truncal ataxia in 40% of the cases.<sup>[14,20]</sup> Swallowing difficulties occurs in 6%–45% of cases.<sup>[14]</sup> Autonomic disturbances including drop attacks, bradycardia, dyspnea, syncopal episode, and palpitations were reported in up to 10% of the cases.<sup>[21-23]</sup> Syncope, bradycardia, and respiratory difficulties all occurs due to pressure on the brain stem as a result of tonsillar descent.<sup>[22,24,25]</sup>

Symptoms due to cerebellar descent are either due to direct pressure on the cerebellum or traction of cerebellar pathways secondary to brain stem herniation as described earlier. These symptoms include truncal ataxia, nystagmus, and dizziness. The hoarseness, swallowing difficulties, and tongue fasciculations are due to involvement and traction on lower cranial nerves.

The rationale of this study is to observe the different clinical presentations of the patients with Chiari malformation in our population. As the time of initial presentation is delayed that might change the sign and symptoms with which the patient initially presents.

## Materials and Methods

This was a cross-sectional observational study with prospectively collected data of 46 patients with Chiari

malformation who were presented to the Department of Neurosurgery, Liaquat National Hospital Karachi Pakistan. Liaquat National Hospital is one of the few major hospitals in the city providing neurosurgical expertise. It has a catchment area of two million people also people are been referred to this hospital for neurosurgical care from other hospitals and clinics.

These patients were included in the study from the outpatient department of our hospital and were characterized accordingly. The demographic data, clinical presentations, and radiological findings were retrieved from the data bank of the Neurosurgery Department and the Health Information and Management Services Department by the resident R5 and a medical officer. The duration of the study is from 2017 to 2020. The institutional review board approved the research protocols and analyzed using IBM Corp. Released 2017. IBM SPSS Statistics for Windows, Version 25.0. Armonk, NY: IBM Corp.

## Statistical analysis

The patient's data will be compiled and analyzed through the Statistical Package for IBM Corp. Released 2017. IBM SPSS Statistics for Windows, Version 25.0. Armonk, NY: IBM Corp. Qualitative variables are presented as frequencies and percentages. Quantitative variables are presented as mean  $\pm$  standard deviation. Effect modifiers are controlled through stratification. A Chi-square test is used for finding an association between categorical variables.  $P \leq 0.05$  is considered as statistically significant.

## Results

According to our data, a total of 46 patients with Chiari malformation were included in the study. Thirty one were male and 15 were female. The patients were divided into five groups according to age as shown in Table 1. The majority of patients were in the second decade of life followed by those within 10 years.

As shown in Figure 1, the majority of patients presented with motor weakness alone that account of 36% of the patients, around 23% had both motor and sensory deficit, 17% had an only sensory deficit, and only 8% of the patients presented with headache alone. Table 2 shows

**Table 1: Demography**

Characteristics	n (%)
Gender	
Male	31 (67.4)
Female	15 (32.6)
Age group (years)	
$\leq 10$	11 (23.9)
11-20	13 (28.3)
21-30	8 (17.4)
31-40	9 (19.6)
$\geq 40$	5 (10.9)

a detailed description of motor weakness and sensory weakness in upper and lower limbs according to different age groups.

Chiari malformation is a syndrome associated with the involvement of other systems also. The most common associated anomalies are myelomeningocele,

diastematomyelia, and curvature deformity. Table 3 shows patients with different Chiari-associated conditions in a different age groups.

The time of presentation plays an important factor. As the disease progress, the symptoms become more severe and signs become more typical and this may change the presenting scenario. In case of Chiari malformation progressive and continuous traction on posterior fossa structures including cerebellum, brain stem, and cranial nerves causes the symptoms to progress and cause further pathological changes that generate new symptoms, for example, if the CSF flow is continuously disturbed it will lead to the formation of the syrinx and can cause hydrocephalous to develop that further precipitate the condition and changes the clinical presentation. Data regarding syrinx formation and hydrocephalous in our study are described in Table 4.

Figure 2 shows the frequency of different signs elicited on the first encounter with the patient.

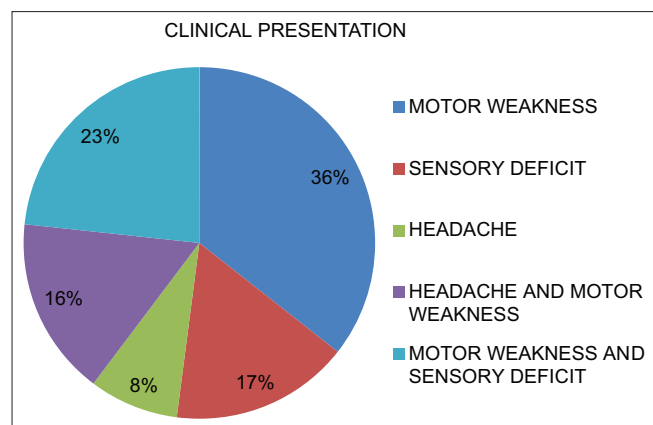


Figure 1: Presenting complaints of Chiari patients

Table 2: Pattern of motor and sensory deficit

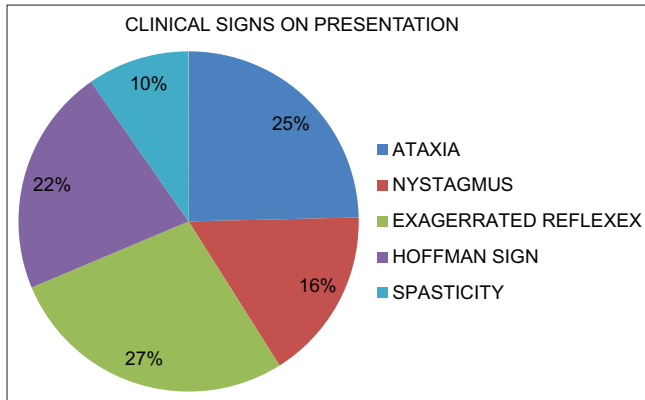
	Age groups					P
	≤10 years (n=11), n (%)	11-20 years (n=13), n (%)	21-30 years (n=8), n (%)	31-40 years (n=9), n (%)	≥40 years (n=5), n (%)	
<b>Motor weakness</b>						
Lower limb power >3	1 (9.1)	0	1 (12.5)	1 (11.1)	1 (20)	0.054**
Lower limbs power <3	5 (45.5)	1 (7.7)	0	1 (11.1)	0	
Upper limb power <3	0	0	1 (12.5)	1 (11.1)	0	
Upper limbs power >3	0	3 (23.1)	3 (37.5)	1 (11.1)	2 (40)	
Upper and lower limbs power <3	0	0	1 (12.5)	0	0	
Upper and lower limbs power >3	1 (9.1)	0	0	2 (22.2)	0	
None	4 (36.4)	9 (69.2)	2 (25)	3 (33.3)	2 (40)	
<b>Sensory deficit</b>						
Left side of body	1 (9.1)	1 (7.7)	0	0	0	0.379**
Numbness in all four limbs	0	0	0	1 (11.1)	0	
Patchy deficit	0	2 (15.4)	2 (25)	2 (22.2)	0	
Upper limb deficit	0	1 (7.7)	2 (25)	0	0	
None	10 (90.9)	9 (69.2)	4 (50)	6 (66.7)	5 (100)	

Table 3: Associated conditions with Chiari Malformation

Associated conditions	≤10 years(n=11), n (%)	11-20 years(n=13), n (%)	21-30 years(n=8), n (%)	31-40 years(n=9), n (%)	≥40 years(n=5), n (%)	P
	MMC	3 (27.3)	0	1 (12.5)	0	
Arachnoiditis	1 (9.1)	0	0	0	0	
Diastometamyelia	1 (9.1)	0	0	0	0	
Scoliosis	0	4 (30.8)	0	0	0	
MMC, tethered cord syndrome	3 (27.3)	0	0	0	1 (20)	
MMC, diplomyelia and diestomytemilia	1 (9.1)	0	0	0	0	
intercerebral arachnoid cyst						
None	2 (18.2)	9 (69.2)	7 (87.5)	9 (100)	4 (80)	
MMC Myelomeningocele						

**Table 4: Association of hydrocephalous and syrinx formation with Chiari malformation**

	≤10 years (n=11), n (%)	11-20 years (n=13), n (%)	21-30 years (n=8), n (%)	31-40 years (n=9), n (%)	≥40 years (n=5), n (%)	P
Hydrocephalus						
Present	9 (81.8)	3 (23.1)	1 (12.5)	1 (11.1)	3 (60)	0.002*
Absent	2 (18.2)	10 (76.9)	7 (87.5)	8 (88.9)	2 (40)	
Syringomyelia						
Cervical	0	3 (23.1)	1 (12.5)	1 (11.1)	0	0.448**
Dorsal	1 (9.1)	0	0	1 (11.1)	0	
Cervical + dorsal	3 (27.3)	6 (46.2)	5 (62.5)	3 (33.3)	4 (80)	
None	7 (63.6)	4 (30.8)	2 (25)	4 (44)	1 (20)	

**Figure 2: Clinical signs on presentation**

## Discussion

Conventionally, the major presenting clinical features of Chiari malformation are debilitating headaches, neck pain, dizziness, and visual disturbances.<sup>[26]</sup> This pattern of presentation is present in both adult as well as pediatric populations.<sup>[27]</sup> Studies suggested that the involvement of different parts of the brain stem, tracts, nuclei, and cranial nerves will lead to different symptoms, age, and duration of the symptoms also has a role to play. Furthermore, disturbed CSF dynamics and the presence or absence of hydrocephalous also contribute to the clinical presentation of the patients. Disturbed CSF dynamics will also lead to syrinx formation in the spinal cord and it presents as motor weakness involving muscle atrophy, altered reflexes, and spasticity. This excessive accumulation of fluid in the central canal of the spinal cord will cause the same pathology as in central cord syndrome.<sup>[28]</sup>

There are several theories have been developed o explain the development of syringomyelia and hydromyelia. One theory is Gardner's theory<sup>[29]</sup> it states that there is delayed opening of the fourth ventricle which results in the transmission of the arterial pulse through a patent obex, producing a water hammer effect that enlarges the central canal. Another theory is William's theory<sup>[30]</sup> it states that hydro syringomyelia results from the pressure difference between two cavities, that is cranial and spinal cavities.

Herniation of cerebellar tonsils further augments the pressure difference between the two cavities.

Other clinical presentations are due to compression on different structures of the brain as discussed earlier. Balance, gait difficulty, and nystagmus occurs as a part of compression on the cerebellum, while hoarseness, swallowing difficulties, facial weakness, and hearing weakness results when there is direct pressure or traction on the lower cranial nerves. Moreover, compression on the brain stem causes respiratory difficulties and autonomic nervous system disturbances.

As discussed earlier, the most common presenting symptom is the occipital headache that increases on straining, coughing, or sneezing, and the frequency is around 80%–100%, but in our study, the data have suggested that the most common presenting symptom is motor weakness and commonly involving the upper limb followed by sensory weakness and headache which are present in less number of patients, this explains the factor of delayed presentation and lack of awareness regarding the disease. The lower limb involvement is either due to syrinx formation or cerebellum involvement. However, nystagmus was also present in a significant number of cases.

Most of our patients had hydrocephalous and myelomeningocele and most of them were children as described previously in results. We have done CSF diversion in around 30% of cases and this will lead to resolution of the symptoms and syrinx.

Owing to delayed presentation in our population mostly patients present with motor weakness and walking difficulties and delayed presentation can affect the outcome of treatment.

## Conclusion

Clinical presentation in our population differs from other studies. Motor weakness and sensory deficits are being the most common complaint on initial presentation. The reason behind this is the delayed presentation of the patient and lack of awareness of the disease and ultimately it will alter the outcome of disease and treatment.

## Financial support and sponsorship

Nil.

## Conflicts of interest

There are no conflicts of interest.

## References

1. H Chiari. Concerning Alterations in the Cerebellum Resulting from Cerebral Hydrocephalus 1987 ;17:1172-5.
2. T Naidich, D McLone, K Fulling, The Chiari II malformation: Part IV. The hindbrain deformity 1986;63:71-116.
3. Schijman E. History, anatomic forms, and pathogenesis of Chiari I malformations. Childs Nerv Syst 2004;20:323-8.
4. Elster AD, Chen MY. Chiari I malformations: Clinical and radiologic reappraisal. Radiology 1992;183:347-53.
5. H Chiari. Concerning Alterations in the Cerebellum Resulting from Cerebral Hydrocephalus 1987 ;17:1172-5.
6. Iskandar BJ, Hedlund GL, Grabb PA, Oakes WJ. The resolution of syringohydromyelia without hindbrain herniation after posterior fossa decompression. J Neurosurg 1998;89:212-6.
7. Tubbs RS, Elton S, Grabb P, Dockery SE, Bartolucci AA, Oakes WJ. Analysis of the posterior fossa in children with the Chiari 0 malformation. Neurosurgery 2001;48:1050-5.
8. Weprin BE, Iskandar BJ, Hedlund GL, Grabb PA, Oakes WJ. The resolution of syringohydromyelia without hindbrain herniation after posterior fossa decompression. J Neurosurg 1998;89:212-6.
9. Milhorat TH, Bolognese OA, Nishikawa M, Francomano CA, McDonnell NB, Roonprapunt C, *et al.* Association of Chiari malformation type I and tethered cord syndrome: Preliminary results of sectioning filum terminale. Surg Neurol 2009;72:20-35.
10. Cinalli G, Spennato P, Sainte-Rose C, Arnaud E, Aliberti F, Brunelle F, *et al.* Chiari malformation in craniosynostosis. Childs Nerv Syst 2005;21:889-901.
11. Morioka T, Shono T, Nishio S, Yoshida K, Hasui K, Fukui M. Acquired Chiari I malformation and syringomyelia associated with bilateral chronic subdural hematoma. Case report. J Neurosurg 1995;83:556-8.
12. Milhorat TH, Bolognese PA, Nishikawa M, McDonnell NB, Francomano CA. Syndrome of occipitotlantoaxial hypermobility, cranial settling, and chiari malformation type I in patients with hereditary disorders of connective tissue. J Neurosurg Spine 2007;7:601-9.
13. Anwer UE, Fisher M. Acute and atypical presentations of syringomyelia. Eur Neurol 1996;36:215-8.
14. Milhorat TH, Chou MW, Trinidad EM, Kula RW, Mandell M, Wolpert C, *et al.* Chiari I malformation redefined: Clinical and radiographic findings for 364 symptomatic patients. Neurosurgery 1999;44:1005-17.
15. Oaks W. Chiari malformations and syringohydromyelia. In: Regenchary S, Wilkins R, editors. Principles of Neurosurgery. Elsevier publication: Mosby-Wolfe; 1994. p. 2-18.
16. Ellenbogen RG, Armonda RA, Shaw DW, Winn HR. Toward a rational treatment of Chiari I malformation and syringomyelia. Neurosurg Focus 2000;8:1-10.
17. Bejjani GK, Cockerham KP. Adult Chiari malformation. Contemp Neurosurg 2001;23:1-7.
18. Dobkin BH. The adult Chiari malformation. Bull Los Angeles Neurol Soc 1977;42:23-7.
19. Menezes AH, Smoker WR, Dyste GN. Syringomyelia, Chiari malformations, and hydromyelia. In: Youmans JR, editor. Neurological Surgery. 3<sup>rd</sup> ed., Ch. 46. Philadelphia: W B Saunders Co; 1990. p. 1421-59.
20. Paul KS, Lye RH, Strang FA, Dutton J. Arnold-Chiari malformation. Review of 71 cases. J Neurosurg 1983;58:183-7.
21. Dyste GN, Menezes AH, VanGilder JC. Symptomatic Chiari malformations. An analysis of presentation, management, and long-term outcome. J Neurosurg 1989;71:159-68.
22. Selmi F, Davies KG, Weeks RD. Type I Chiari deformity presenting with profound sinus bradycardia: Case report and literature review. Br J Neurosurg 1995;9:543-5.
23. Goncalves da Silva JA, de Farias Britto JC, Virgolino da Nóbrega P. Neurovegetative Störungen bei 230 Fällen basilarer Impression und Arnold-Chiari-Malformation. Neurochirurgia 1992;35:183-8.
24. Weig SG, Buckthal PE, Choi SK, Zellem RT. Recurrent syncope as the presenting symptom of Arnold-Chiari malformation. Neurology 1991;41:1673-4.
25. Williams B. Chronic herniation of the hindbrain. Ann R Coll Surg Engl 1981;63:9-17.
26. Fischbein R, Saling JR, Marty P, Kropp D, Meeker J, Amerine J, *et al.* Patient-reported Chiari malformation type I symptoms and diagnostic experiences: A report from the national Conquer Chiari Patient Registry database. Neurol Sci 2015;36:1617-24.
27. Dyste GN, Menezes AH. Presentation and management of pediatric Chiari malformations without myelodysplasia. Neurosurgery 1988;23:589-97.
28. Garcia-Uria J, Leunda G, Carrillo R, Bravo G. Syringomyelia: Long-term results after posterior fossa decompression. J Neurosurg 1981;54:380-3.
29. Gardner WJ. Hydrodynamic mechanism of syringomyelia: Its relationship to myelocoele. J Neurol Neurosurg Psychiatry 1965;28:247-59.
30. Williams B. On the pathogenesis of syringomyelia: A review. J R Soc Med 1980;73:798-806.