

PFUI-RELATED COMPLICATIONS REVIEW

The mechanism of continence after posterior urethroplasty



Herman S. Bagga *, Kenneth W. Angermeier

Center for Genitourinary Reconstruction, Glickman Urological and Kidney Institute, Cleveland Clinic, Cleveland, OH, USA

Received 2 November 2014, Accepted 26 November 2014

Available online 7 February 2015

KEYWORDS

Posterior urethroplasty;
Urinary continence;
Genitourinary trauma;
Urethral trauma;
Pelvic fracture

ABBREVIATIONS

PFUI, pelvic fracture urethral injury;
PU, posterior urethroplasty

Abstract The standard of care after a pelvic fracture urethral injury is a repair via a one-stage anastomotic posterior urethroplasty using a step-wise perineal approach. The initial injury, immediate postoperative management, and surgical repair can all affect urinary continence in these patients. Proximal continence mechanisms, particularly the bladder neck, are particularly important in maintaining urinary continence in these patients. Patients with bladder neck dysfunction should be counselled about the greater risk of urinary incontinence.

© 2015 Production and hosting by Elsevier B.V. on behalf of Arab Association of Urology. This is an open access article under the CC BY-NC-ND license (<http://creativecommons.org/licenses/by-nc-nd/3.0/>).

The anatomy of pelvic fracture urethral injury (PFUI)

In a typical man urinary continence depends on two urethral segments, conceptually separated at the level of the prostatic verumontanum. Proximally is the internal

sphincter, comprising the bladder neck and proximal prostatic urethra. Distally there are several features, including a small segment of remaining prostatic urethra, the membranous urethra, and the external sphincter, which includes the urethral sphincter mechanism and the extrinsic pelvic floor musculature [1–3].

The urethral pressure responsible for continence is normally greatest at the membranous urethra, where the skeletal urethral sphincter applies its maximum pressure [4]. During trauma associated with PFUI in men, this region of the urethra is at particular risk, putting the continence mechanisms in jeopardy. This location of injury is due to tethering of the posterior urethra with

* Corresponding author at: Cleveland Clinic, 9500 Euclid Avenue, Q10, Cleveland, OH 44195, USA.

E-mail address: hermanbagga@gmail.com (H.S. Bagga).

Peer review under responsibility of Arab Association of Urology.



Production and hosting by Elsevier

the pubic arch by the puboprostatic ligaments and the perineal membrane. It is between these two relatively fixed points that the membranous urethra and the urethral sphincter mechanism lie. The region is therefore vulnerable to injury during pelvic fracture. Such trauma begins with a stretch injury and can progress to partial or complete urethral rupture, particularly when a ligamentous attachment is torn from the urethra. Adherence is thought to be tighter at the puboprostatic ligament, leaving the distal site of attachment more vulnerable to injury. Therefore, although the effects of the injury can be wider, the disruption itself is most commonly noted at the level of the bulbomembranous junction, just distal to the urethral sphincter mechanism [5–9].

This pattern of injury is in contrast to that occurring in females, where it is more common to see a partial anterior urethral tear rather than a complete urethral disruption. Injury to children can also vary, as they have less developed prostate glands which have decreased support, and thus tend more commonly to have proximal injuries through the bladder neck or prostatic urethra [7,8,10,11].

Effects of the initial management

In addition to the direct urethral damage caused by PFUI, subsequent management can result in additional urethral compromise which can further affect urinary continence. The standard of care for management begins with the immediate placement of a suprapubic catheter for urinary drainage. This is sometimes accompanied by immediate primary realignment over a catheter. If early realignment is used the patient is then managed expectantly. In cases of failure future interventions might include anastomotic urethroplasty. Historically, realignment was done as an open procedure. The invasiveness of this approach was found to cause a greater risk of urinary incontinence for the patient [12,13]. In the modern era, open realignment is rarely indicated, except if there are concomitant bladder, bladder neck, or rectal injuries. In these cases immediate open repair and realignment is recommended to prevent urinary incontinence or pelvic sepsis. Currently, immediate primary realignment is generally achieved by endoscopic means through a cystotomy, with no retropubic or perineal exploration. No additional risk to urinary incontinence has been noted for those who undergo this mode of immediate management [7].

The effects of posterior urethroplasty (PU)

Ultimately, the standard of care for managing urethral obliteration as a result of PFUI is a single-stage anastomotic urethroplasty. Generally, a perineal approach is adequate (and preferred), but a combined abdominoperineal procedure is sometimes required when a tension-free anastomosis cannot be made from below.

Before anastomosis, the scarred urethral and periurethral tissue must be resected from the obliterated portions of the bulbar and membranous urethra, with additional excision of adjacent injured tissue. Given that the dismembered region of the urethra is most often near the bulbomembranous junction, the repair is at times a bulbomembranous anastomosis. However, if the injured and scarred urethra continues proximally, it must also be excised before the anastomosis. Therefore, although there is the potential for preserving at least part of the urethral sphincter mechanism, the entire distal continence component can be put at risk during repair [1,5,7,8,14].

The mechanism of continence after surgery

After PU the proximal urethral component (comprising the bladder neck and supramontanal urethra), might serve as the primary urinary continence mechanism. For some patients, the smooth muscle of this region might represent the only remaining active part of the sphincter. However, this area is known to contribute a lower pressure to the urethral continence mechanism than its distal counterpart [1,8,14]. Koraitim et al. [14] investigated the urethral pressures after anastomotic PU in these patients, and confirmed this fact. They found a lower maximum urethral pressure and urethral closing pressure in repaired patients than in healthy controls, with decreased pressures of 39 and 48 cm H₂O vs. 65 and 75 cm H₂O, respectively.

In the same study the functional urethral length of repaired patients was found to be half of that in normal patients, at 2.4 vs. 4.8 cm. Under stress conditions intra-abdominal pressure changes were transmitted throughout this entire shortened functional urethra in repaired patients, compared to just the proximal urethral portion of healthy controls [14]. Anatomically this is not surprising, given that the proximal urethra is supported in a retropubic, intra-abdominal position. However, this finding gives more support to the contention that the proximal urethra might serve as the primary continence mechanism in patients after anastomotic urethroplasty for PFUI. In their study, Koraitim et al. [14] also investigated the contribution of periurethral skeletal muscles to continence after PU. From pressure studies while patients were asked to use a 'hold manoeuvre', they found an increased urethral pressure in all normal patients, but only in 65% of patients who had PU. This further reinforces the importance of the proximal urethral component for continence in these patients.

Bladder neck dysfunction might be secondary to sacral nerve or pelvic plexus injury, but a more common cause would be direct trauma to the bladder neck itself [1,7,14,15]. Such bladder neck injury in men is generally a longitudinal anterior rupture that extends from the prostatic urethra to the bladder neck. This injury has been described as secondary to a tearing force from the puboprostatic ligaments being pulled apart, most

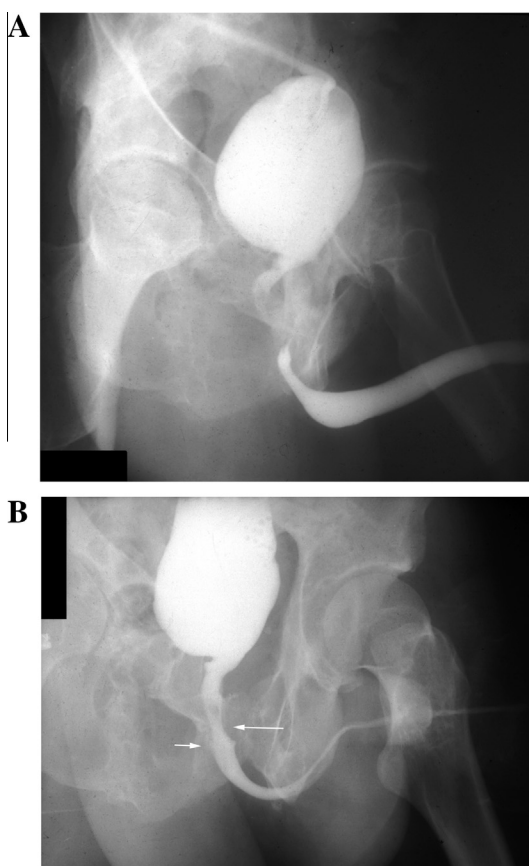


Figure 1 (A) A cystogram showing an open bladder neck, indicating a probable compromise to the proximal urinary continence mechanism. A simultaneous retrograde urethrogram shows the length of the urethral defect. (B) A voiding cystourethrogram after PU, showing a patent anastomosis (short arrow). The long arrow indicates a region of a still-present distal sphincter mechanism. The patient was completely continent after surgery.

commonly occurring after lateral compression or pelvic ‘open book’ fractures [16]. By contrast, transverse bladder neck injury is less common in men, but more likely in children, as previously described [11]. Regardless of the mechanism of bladder neck injury, it is important that these injuries are identified prospectively and repaired around the time of the initial trauma if possible. Bladder neck and prostatic urethral injuries often do not close quickly on their own, and continued urinary extravasation can result in cavitation or a focus of persistent infection. This process can result in a bladder-neck scar, usually anteriorly, leading to an open fixed bladder neck with insufficient coaptation to provide adequate continence. Early repair at the time of suprapubic catheter placement or primary realignment might decrease this risk to some degree [1,7,11,16].

Therefore, traditional teaching has emphasised that patients with bladder neck dysfunction should be carefully counselled that they are at greater risk of incontinence after PU for PFUI. However, surgeons

should consider that this risk might not be as clinically dramatic as has been suspected. This may be related to variability in the severity of the bladder neck injury, and/or the potential for preserving a significant portion of the membranous urethra and external sphincter when the disruption is near the bulbomembranous junction. Using preoperative cysto-urethrography before PU for PFUI, Iselin and Webster [1] found that most patients with an open bladder neck on preoperative imaging were actually continent after repair. However, those who were incontinent after PU had longer open bladder necks. The mean length of the bladder neck and prostatic urethral opening was significantly greater in patients who were incontinent after PU (1.68 cm) than in those who were continent (0.9 cm). We use preoperative cysto-urethrograms to counsel patients about the risk of incontinence after repair and have similarly found that an open bladder neck on preoperative imaging is not indicative of definite incontinence after PU (Fig. 1). However, for those patients who do have bothersome incontinence after PU, a second operation, such as intrinsic tube reconstruction of the bladder neck, injection of collagen as a bulking agent, or implantation of a urethral sling or artificial urinary sphincter, can be considered for management [1,17].

Continence outcomes after PU

Despite the limited remaining continence mechanisms of patients after PU for PFUI, the reported continence after repair seems to be adequate. Cooperberg et al. [18] reported postoperative voiding function in 103 accessible men after repair and found that nearly 90% of patients reported no symptoms of incontinence. In this series, only one patient had incontinence significant enough to prompt the placement of an artificial urinary sphincter. Ennemoser et al. [19] also reported good continence after such repair, reporting no incontinence during a mean follow-up of 8.6 years in 42 patients. Similarly, the Indian experience reported by Singh et al. [20] showed no urinary incontinence in a retrospective analysis of 172 patients after repair.

Conclusion

The surgical management of PFUI remains challenging; the standard of care is a one-stage anastomotic PU via a stepwise perineal approach. Although urinary continence rates remain high after such repair, the success depends on an intimate understanding of urinary continence mechanisms in both normal and repaired patients. In the latter, the proximal continence mechanism, particularly the bladder neck, is especially important. It must often compensate for damage inflicted to the distal continence mechanism during the time of injury and subsequent management.

Conflict of interest

None.

Source of funding

None.

References

- [1] Iselin CE, Webster GD. The significance of the open bladder neck associated with pelvic fracture urethral distraction defects. *J Urol* 1999;**162**:347–51.
- [2] Gosling J. The structure of the bladder and urethra in relation to function. *Urol Clin North Am* 1979;**6**:31–8.
- [3] Delmas V, Benoit G, Gillot C, Hureau J. Anatomical basis of the surgical approach to the membranous urethra. *Anat Clinica* 1984;**6**:69–78.
- [4] McGuire E. Urethral sphincter mechanisms. *Urol Clin North Am* 1979;**6**:39–49.
- [5] Andrich DE, Mundy AR. The nature of urethral injury in cases of pelvic fracture urethral trauma. *J Urol* 2001;**165**:1492–5.
- [6] Andrich DE, Day AC, Mundy AR. Proposed mechanisms of lower urinary tract injury in fractures of the pelvic ring. *BJU Int* 2007;**100**:567–73.
- [7] Gómez RG, Mundy T, Dubey D, El-Kassaby AW, Firdaoessaleh, Kodama R, et al. SIU/ICUD consultation on urethral strictures and pelvic fracture urethral injuries. *Urology* 2014;**83**:S48–58.
- [8] Koraitim MM. Pelvic fracture urethral injuries: the unresolved controversy. *J Urol* 1999;**161**:1433–41.
- [9] Mouraviev V, Santucci RA. Cadaveric anatomy of pelvic fracture urethral injury: most injuries are distal to the external urinary sphincter. *J Urol* 2005;**173**:869–72.
- [10] al-Rifaei MA, Gaafar S, Abdel-Rahman M. Management of posterior urethral strictures secondary to pelvic fractures in children. *J Urol* 1991;**145**:353–6.
- [11] Koraitim MM. Assessment and management of an open bladder neck at posterior urethroplasty. *Urology* 2010;**76**:476–9.
- [12] Dalpiaz O, Mitterberger M, Kerschbaumer A, Pinggera GM, Bartsch G, Strasser H. Anatomical approach for surgery of the male posterior urethra. *BJU Int* 2008;**102**:1448–51.
- [13] Pratap A, Agrawal CS, Pandit RK, Sapkota G, Anchal N. Factors contributing to a successful outcome of combined abdominal transpubic perineal urethroplasty for complex posterior urethral disruptions. *J Urol* 2006;**176**:2514–7.
- [14] Koraitim MM, Atta MA, Fattah GA, Isamail HR. Mechanism of continence after repair of post-traumatic posterior urethral strictures. *Urology* 2003;**61**:287–90.
- [15] Koraitim MM. The male urethral sphincter complex revisited: an anatomical concept and its physiological correlate. *J Urol* 2008;**179**:1683–9.
- [16] Mundy AR, Andrich DE. Pelvic fracture-related injuries of the bladder neck and prostate: their nature, cause and management. *BJU Int* 2010;**105**:1302–8.
- [17] Al-Rifaei MA, Al-Rifaei AM, Al-Angabawy A. Management of urinary incontinence after bulboprostatic anastomotic urethroplasty for posterior urethral obstruction secondary to pelvic fracture. *Scand J Urol Nephrol* 2004;**38**:42–6.
- [18] Cooperberg MR, McAninch JW, Alsikafi NF, Elliot SP. Urethral reconstruction for traumatic posterior urethral disruption. Outcomes of a 25-year experience. *J Urol* 2007;**178**:2006–10.
- [19] Ennemoser O, Colleselli K, Reissigl A, Poisel S, Janetschek G, Bartsch G. Posttraumatic posterior urethral stricture repair. Anatomy, surgical approach and long-term results. *J Urol* 1997;**157**:499–505.
- [20] Singh SK, Pawar DS, Khandelwal AK, Jagmohan. Transperineal bulboprostatic anastomotic repair of pelvic fracture urethral distraction defect and role of ancillary maneuver: a retrospective study in 172 patients. *Urol Ann* 2010;**2**:53–7.