

Evaluation of palatal rugae pattern in different sagittal skeletal relationship adolescent subjects

Ekrem Oral, DDS, MSD^a, S. Kutalmış Buyuk, DDS, PhD^{b,*}, Huseyin Simsek, DDS, PhD^c

Abstract

The purpose of this study was to evaluate the morphological structure of palatal rugae in Turkish orthodontic subjects with different sagittal skeletal malocclusions. Orthodontic dental casts of 105 patients (Class I [23 females, 12 males]; 35, Class II [18 females, 17 males]; and 35, Class III [14 females, 21 males] 10–22 years old) were analyzed for rugae patterns. Palatal rugae pattern and number, direction of rugae alignment, shape of incisive papilla were analyzed. Modified Thomas and Kotze classification was performed to analyze palatal rugae characteristics. The data were analyzed using the Kruskal–Wallis test. Wavy and curved types were the most common types of rugae pattern in all groups (Class I, Class II, Class III). As regards to the number of primary and secondary rugae on the left and right sides, there was no statistically significant difference among subjects with different skeletal malocclusions. Droplet-shaped incisive papilla was the most common form of incisive papillae among different skeletal malocclusion groups. The most common palatal rugae were direction type arranged in the horizontal direction. All rugae patterns were unique for each individual. The use of antemortem or postmortem palatal rugae records may facilitate identification of the suspects in forensic investigations by enabling facial reconstruction through skeletal malocclusions.

Abbreviations: PPR = primary palatal rugae, SPR = secondary palatal rugae.

Keywords: dental cast, forensic dentistry, palatal rugae pattern, skeletal malocclusion

1. Introduction

Palatal rugae are transverse ridges of the mucosa located at the upper jaw, on the anterior portion of the hard palate.^[1] The number, shape, width, height, and location of palatal rugae vary from the left side of the palate to the right side as well as from one person to another, and are unique to every individual.^[2] Recent studies have suggested that palatal rugae could be used in forensic identification.^[3,4] Palatal rugae remain stable throughout life and therefore they are commonly used by dental clinicians as a reference point to evaluate the extent of tooth movement.^[1]

Palatal rugae are specific to individuals and remain unchanged, and thus, this area can be used to identify individuals where other methods have failed.^[5,6] The facts that palatal rugae remain unchanged even after death and they are easily analyzed, make this body area important in elucidating forensic cases.^[7,8] Having a unique structure and being protected by the cheek, tongue, and teeth in the oral cavity, palatal rugae have a particular

importance in forensic dentistry.^[9,10] By their protected localization, palatal rugae are much less affected by burns, physical trauma, and other factors.^[7,11] In addition, number, shape, and localization of palatal rugae remain unchanged throughout life and studies have suggested that they could be used as a fingerprint in most forensic cases.^[1,12] Their applicability in cases of edentulous people highlights the superiority of forensic identification by palatal rugae.^[13]

Although the literature has various studies that evaluated differences in morphological structure of palatal rugae in different populations,^[2,14–16] no study has been conducted on individuals with various sagittal skeletal malocclusion. The aim of the present study was to investigate morphological structure of palatal rugae in Turkish orthodontic subjects with various sagittal skeletal malocclusion.

2. Methods

2.1. Analyzing of the palatal rugae patterns

The study subjects comprised of 105 individuals aged 10 to 22 years who were admitted to the Department of Orthodontics at Ordu University Faculty of Dentistry for orthodontic treatment. The research was designed as a retrospective study and archive materials were used, therefore ethics approval was not required for this study. The subjects were grouped as Class I, Class II, and Class III according to the ANB angle measured on lateral cephalometric radiographs in order to perform skeletal classification of the study participants (Class I: ANB angle 0° to 4°; Class II: ANB angle > 4°; Class III: ANB angle < 0°). Of these subjects, 35 were classified into Class I (23 females, 12 males); 35, into Class II (18 females, 17 males); and 35, into Class III (14 females, 21 males). The subjects who previously underwent surgery in the palatal area and received orthodontic treatment were excluded from the study. The subjects whose palatal rugae were clearly

Editor: Giovanni Tarantino.

The authors have no funding and conflicts of interest to disclose.

^a Private practice, Master of Orthodontics, Kayseri, ^b Department of Orthodontics, ^c Department of Pediatric Dentistry, Faculty of Dentistry, Ordu University, Ordu, Turkey.

* Correspondence: S. Kutalmış Buyuk, Department of Orthodontics, Faculty of Dentistry, Ordu University, Ordu, Turkey (e-mail: skbuyuk@gmail.com).

Copyright © 2017 the Author(s). Published by Wolters Kluwer Health, Inc. This is an open access article distributed under the terms of the Creative Commons Attribution-Non Commercial-No Derivatives License 4.0 (CCBY-NC-ND), where it is permissible to download and share the work provided it is properly cited. The work cannot be changed in any way or used commercially without permission from the journal.

Medicine (2017) 96:14(e6440)

Received: 30 January 2017 / Received in final form: 27 February 2017 /

Accepted: 1 March 2017

<http://dx.doi.org/10.1097/MD.0000000000006440>

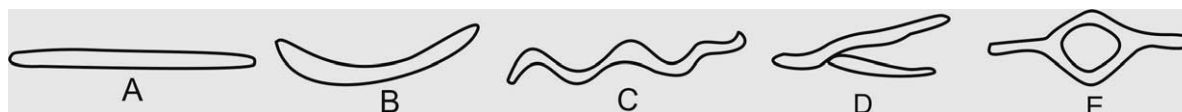

Figure 1. Modified Thomas and Kotze classification of the palatal rugae: (A) straight, (B) curve, (C) wavy, (D) unification, (E) annular pattern.

visible on the cast models were included in the study. The number and pattern of palatal rugae were determined from maxillary cast models before orthodontic treatment in all groups. Maxillary dental cast models were produced using high-quality plaster. Digital photographs of the cast models were taken in a standard position focusing on the palatal rugae. The distance between the model and the camera lens was standardized. Each photo was assessed using the Adobe Photoshop CS3 software in its original size. The modified Thomas and Kotze classification system was used to determine the types of palatal rugae.^[17] The number and pattern of palatal rugae, shape of the incisive papillae, and direction of rugae pattern were evaluated on the cast models of maxilla (Figs. 1 and 2).

2.2. Statistical analysis

All data were analyzed using SPSS (version 20.0, SPSS Inc., Chicago, IL) software. The Kolmogorov–Smirnov test was used to test if the data were normally distributed. The Kruskal–Wallis test was used to compare the number of primary palatal rugae (PPR) and secondary palatal rugae (SPR) among the groups. In order to determine intra-observer reliability, 20 cast models were reassessed by the same observer 4 weeks after the first assessment. Kappa statistics were used to evaluate intra-observer correlation. P values of less than 0.05 were considered statistically significant.

3. Results

The direction of palatal rugae, shape of the incisive papillae, and the shapes of PPR and SPR secondary rugae were reassessed on 20 cast models 1 month after the initial assessment. More than 80% concordance was achieved between the 2 measurements in all assessments. Morphological distribution of PPR and SPR in subjects with different sagittal skeletal malocclusion is presented in Table 1. Wavy and curved types were the most common types

of rugae pattern in all groups (Class I, Class II, Class III). As regards to the number of PPR and SPR on the left and right sides, there was no statistically significant difference among subjects with different skeletal malocclusions (Table 2). Droplet-shaped incisive papilla was the most common form of incisive papillae among different skeletal malocclusion groups (Fig. 3). In all groups, most of the palatal rugae were arranged in the horizontal direction (Fig. 4).

4. Discussion

Forensic identification through palatal rugae becomes important in cases where fingerprints are unavailable.^[18] Palatal rugae are

Table 1 Distribution of number of primary rugae in different sagittal relationships.

	Groups	Straight	Curved	Wavy	Annular	Unification
Right						
Primer Ruga 1	Class I	7	15	1	0	12
	Class II	4	17	4	1	9
	Class III	4	13	3	0	15
Primer Ruga 2	Class I	2	16	11	0	6
	Class II	4	12	17	0	2
	Class III	3	7	20	0	5
Primer Ruga 3	Class I	0	8	19	0	2
	Class II	1	4	29	0	0
	Class III	0	3	26	0	3
Primer Ruga 4	Class I	0	5	10	0	0
	Class II	1	1	15	0	0
	Class III	0	1	11	2	0
Primer Ruga 5	Class I	1	0	0	0	0
	Class II	0	0	0	0	0
	Class III	0	1	2	0	0
Primer Ruga 6	Class I	0	0	2	0	0
	Class II	0	0	1	0	0
	Class III	0	0	0	0	0
Left						
Primer Ruga 1	Class I	3	19	4	2	7
	Class II	4	17	3	4	7
	Class III	7	12	3	1	12
Primer Ruga 2	Class I	7	10	12	1	5
	Class II	4	12	15	0	4
	Class III	9	9	9	1	7
Primer Ruga 3	Class I	0	4	27	0	2
	Class II	5	2	22	1	3
	Class III	0	5	19	1	5
Primer Ruga 4	Class I	1	4	12	0	1
	Class II	2	2	12	0	1
	Class III	3	2	11	0	1
Primer Ruga 5	Class I	0	0	2	0	1
	Class II	1	0	3	0	0
	Class III	0	0	4	0	0
Primer Ruga 6	Class I	0	0	1	0	0
	Class II	0	0	1	0	0
	Class III	0	0	0	0	0



Figure 2. Palatal rugae anatomic landmarks: (A) incisive papilla, (B) primary palatal rugae, (C) secondary palatal rugae.

Table 2
Distribution of primary and secondary rugae palatina number in different sagittal skeletal relationships.

	Class I (35)		Class II (35)		Class III (35)		P*
	N	Mean (SD)	N	Mean (SD)	N	Mean (SD)	
Right							
Primary rugae	119	3.40 (1.01)	124	3.54 (0.70)	116	3.37 (0.73)	0.541
Secondary rugae	71	2.15 (1.35)	58	2.00 (0.89)	70	2.12 (0.99)	0.916
Left							
Primary rugae	127	3.63 (0.70)	125	3.57 (0.85)	119	3.46 (0.89)	0.740
Secondary rugae	72	2.25 (1.05)	62	2.07 (1.02)	61	2.16 (1.09)	0.521

N=number of rugae, SD=standard deviation.
 *Kruskal-Wallis test.

composed of collagen fibers that are resistant to stretching and abrasion, allowing postmortem examination of this area.^[16] In addition, studies have reported that palatal rugae are unique to every individual.^[14,19-21] Similarly, in this present study, each subject’s palatal rugae were found to be unique. Some authors suggest that palatal rugae remain unchanged as of 12th weeks of intrauterine life,^[10,22] whereas other authors suggest that palatal rugae may change in number with increasing age but retain their general configuration.^[23] The present study did not investigate the changed in palatal rugae in different period time, but evaluated the number and shape of the palatal rugae among different skeletal malocclusion groups.

Due to their unique and stable structure, palatal rugae can be used in forensic identification.^[24] Several authors analyzed palatal rugae and proposed various classifications to evaluate them.^[4,15,25,26] Lysell has been the first to define their shapes.^[10] Subsequently, other classification systems were proposed by other researchers.^[14,15,25] The method described by Thomas and Kotze, which is the most commonly used and simplest method, was used in the present study to define the types of rugae pattern.^[17]

The number of PPR ranged from 2 to 6 in the subjects examined in the present study. In addition, there was no significant difference among different sagittal skeletal malocclusion groups in terms of the number of PPR and SPR on either sides of the palate. These findings are consistent with those reported by Suhartono et al.^[2] As a result, PPR and SPR showed symmetric distribution in terms of their numbers on either sides of the palate among different skeletal malocclusion groups.

Some studies have provided evidence that the structure of palatal rugae remained unchanged even in postmortem period,

and that an individual could be reliably identified based on the structure of palatal rugae.^[27] The number and shape of palatal rugae on the right and left sides of the palate differ between males and females in different populations checked in various studies.^[16,28] However, to the best of our knowledge, this is the first study that compared morphological structure of palatal rugae in different sagittal skeletal malocclusion groups. In this study, which is the first study in the literature to evaluate the shape and number of palatal rugae in different sagittal skeletal malocclusion groups, no significant difference was detected among the groups.

Distribution of the shape of palatal rugae in a population shows racial differences.^[4,14,15,29,30] In the present study, wavy type of rugae was the most common pattern in different sagittal skeletal malocclusion groups of Turkish background. The studies by Azab et al^[29] and Kapali et al^[4] also reported wavy type of rugae as the most commonly observed rugae pattern. Consistent with these studies, the wavy type of rugae was the most common rugae pattern in the present study.

5. Conclusion

Further studies on a larger number of subjects are required in order to confirm the relationship between the pattern of palatal rugae and sagittal skeletal malocclusion. This may allow identification of potential suspects through skeletal malocclusions and palatal rugae and lead the path in forensic dentistry. Moreover, the use of antemortem or postmortem palatal rugae records may facilitate identification of the suspects in forensic investigations by enabling facial reconstruction through skeletal malocclusions.

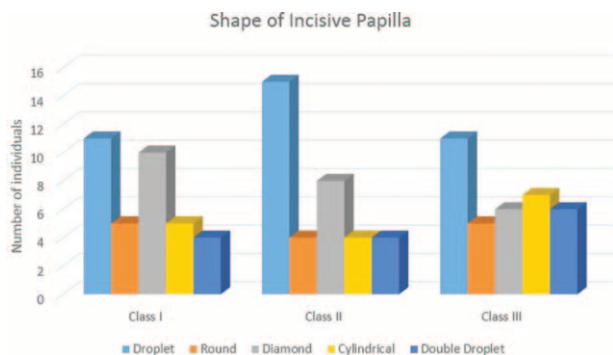


Figure 3. Shape of incisive papilla in different sagittal skeletal malocclusions.

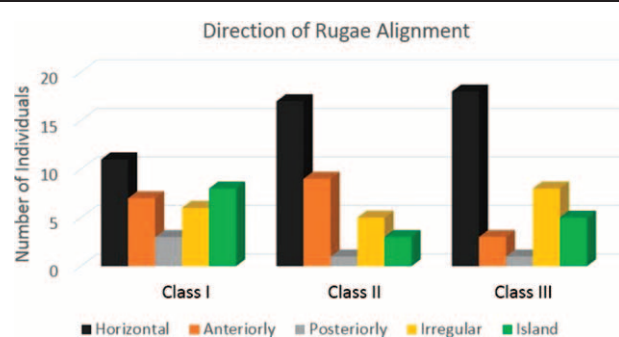


Figure 4. Direction of palatal rugae alignment in different sagittal skeletal malocclusions.

Acknowledgements

The authors thank to Research Assistant E. Genc for support and technical assistance.

References

- [1] Patil MS, Patil SB, Acharya AB. Palatine rugae and their significance in clinical dentistry: a review of the literature. *J Am Dent Assoc* 2008;139:1471–8.
- [2] Suhartono AW, Syafitri K, Puspita AD, et al. Palatal rugae patterning in a modern Indonesian population. *Int J Legal Med* 2016;130:881–7.
- [3] Taneva ED, Johnson A, Viana G, et al. 3D evaluation of palatal rugae for human identification using digital study models. *J Forensic Dent Sci* 2015;7:244–52.
- [4] Kapali S, Townsend G, Richards L, et al. Palatal rugae patterns in Australian aborigines and Caucasians. *Aust Dent J* 1997;42:129–33.
- [5] Shukla D, Chowdhry A, Bablani D, et al. Establishing the reliability of palatal rugae pattern in individual identification (following orthodontic treatment). *J Forensic Odontostomatol* 2011;29:20–9.
- [6] English WR, Robison SF, Summitt JB, et al. Individuality of human palatal rugae. *J Forensic Sci* 1988;33:718–26.
- [7] Muthusubramanian M, Limson K, Julian R. Analysis of rugae in burn victims and cadavers to simulate rugae identification in cases of incineration and decomposition. *J Forensic Odontostomatol* 2005;23:26–9.
- [8] Bansode SC, Kulkarni MM. Importance of palatal rugae in individual identification. *J Forensic Dent Sci* 2009;1:77–81.
- [9] Allen H. The palatal rugae in man. *J Acad Nat Sci Phila* 1888;40:254–72.
- [10] Lysell L. Plicae palatinae transversae and papilla incisiva in man; a morphologic and genetic study. *Acta Odont Scand* 1955;13:5–137.
- [11] Syed S, Alshahrani I, Alshahrani A, et al. Conversion of palatal rugae pattern to scanable Quick Response code in an Arabian population. *J Dent Sci* 2016;11:253–60.
- [12] De Angelis D, Riboli F, Gibelli D, et al. Palatal rugae as an individualising marker: reliability for forensic odontology and personal identification. *Sci Justice* 2012;52:181–4.
- [13] Ohtani M, Nishida N, Chiba T, et al. Indication and limitations of using palatal rugae for personal identification in edentulous cases. *Forensic Sci Int* 2008;176:178–82.
- [14] Eboh DE. Palatal rugae patterns of Urhobos in Abraka, South-Southern Nigeria. *Int J Morphol* 2012;30:709–13.
- [15] Santos C, Caldas IM. Palatal rugae pattern in a Portuguese population: a preliminary analysis. *J Forensic Sci* 2012;57:786–68.
- [16] Hermosilla VV, San Pedro VJ, Cantin LM, et al. Palatal rugae: systematic analysis of its shape and dimensions for use in human identification. *Int J Morphol* 2009;27:819–25.
- [17] Thomas C, Kotze T. The palatal ruga pattern in six southern African human populations. Part I: a description of the populations and a method for its investigation. *J Dent Assoc S Afr* 1983;38:158–65.
- [18] Carrea J. La identificación humana por lãs rugosidades palatinas. *Rev Ortodont* 1991;18:309–13.
- [19] Saraf A, Bedia S, Indurkar A, et al. Rugae patterns as an adjunct to sex differentiation in forensic identification. *J Forensic Odontostomatol* 2011;29:14–9.
- [20] Gandikota C, Venkata YP, Challa P, et al. Comparative study of palatal rugae pattern in class II div 1 and class I individuals. *J Pharm Bioallied Sci* 2012;4:S358–363.
- [21] Rath R, Reginald BA. Palatal rugae: an effective marker in population differentiation. *J Forensic Dent Sci* 2014;6:46–50.
- [22] Simmons J, Moore R, Erickson L. A longitudinal study of anteroposterior growth changes in the palatine rugae. *J Dent Res* 1987;66:1512–5.
- [23] Tonge C, Luke D. Dental anatomy: the palate. *Dent Update* 1985;12:461–2.
- [24] Caldas IM, Magalhaes T, Afonso A. Establishing identity using cheiloscopy and palatoscopy. *Forensic Sci Int* 2007;165:1–9.
- [25] Dawasaz AA, Dinkar AD. Rugoscopy: predominant pattern, uniqueness, and stability assessment in the Indian goan population. *J Forensic Sci* 2013;58:1621–7.
- [26] Nayak P, Acharya AB, Padmini AT, et al. Differences in the palatal rugae shape in two populations of India. *Arch Oral Biol* 2007;52:977–82.
- [27] Kamala R, Gupta N, Bansal A, et al. Palatal rugae pattern as an aid for personal identification: a forensic study. *JIAOMR* 2011;23:173–8.
- [28] Fahmi FM, Al-Shamrani SM, Talic YF. Rugae pattern in a Saudi population sample of males and females. *Saudi Dent J* 2001;13:92–5.
- [29] Azab SMS, Magdy R, El Deen MAS. Patterns of palatal rugae among adult Egyptian population. *Egyptian J Forensic Sci* 2015;6:78–83.
- [30] Kotrashetti VS, Hollikatti K, Mallapur M, et al. Determination of palatal rugae patterns among two ethnic populations of India by logistic regression analysis. *J Forensic Legal Med* 2011;18:360–5.