

Contents lists available at [ScienceDirect](http://www.sciencedirect.com)

## International Journal of Surgery Case Reports

journal homepage: [www.casereports.com](http://www.casereports.com)

## Aortic dissection associated with blunt chest trauma diagnosed by elevated D-dimer

Joshua L. Penn<sup>a</sup>, Jennfier L. Martindale<sup>a</sup>, Leslie W. Milne<sup>b</sup>, Keith A. Marill<sup>b,\*</sup><sup>a</sup> Harvard Affiliated Emergency Medicine Residency, Department of Emergency Medicine, Harvard Medical School, 75 Francis Street, Neville House - 236A, Boston, Massachusetts 02115, USA<sup>b</sup> Department of Emergency Medicine, Massachusetts General Hospital, Harvard Medical School, Zero Emerson Place, Suite 3B, Boston, Massachusetts 02114, USA

## ARTICLE INFO

## Article history:

Received 4 February 2015

Accepted 13 March 2015

Available online 20 March 2015

## Keywords:

Aortic dissection

Chest trauma

D-dimer

Bovine-type aortic arch

## ABSTRACT

**INTRODUCTION:** Similar to spontaneous aortic dissection, traumatic aortic dissection is diagnosed with a careful history and physical exam, chest radiograph, and ultimately, dedicated aortic imaging. The diagnosis of spontaneous aortic dissection may be aided by using the serum D-dimer test. The use of D-dimer for diagnosing aortic injury in the setting of blunt trauma has not previously been reported.

**PRESENTATION OF CASE:** We present a case of aortic dissection in a 61-year-old male diagnosed when the patient presented with chest pain after blunt chest trauma.

**DISCUSSION:** The patient had no known history or risk factors for aortic disease. None of the classic findings were present by history, physical examination or chest radiograph and the diagnosis was made as the result of an elevated D-dimer. We discuss how the D-dimer test fortuitously led to the diagnosis in this case, and the implications.

**CONCLUSION:** D-dimer could be helpful in diagnosing aortic injuries in low-risk chest trauma patients.

© 2015 The Authors. Published by Elsevier Ltd. on behalf of Surgical Associates Ltd. This is an open access article under the CC BY-NC-ND license (<http://creativecommons.org/licenses/by-nc-nd/4.0/>).

## 1. Introduction

Patients with spontaneous aortic dissection often complain of chest or back pain, particularly of a tearing nature. History, physical exam, electrocardiogram, and evidence of a wide mediastinum, blurred aortic knob, or other findings on chest radiograph are used to assess the likelihood of dissection [1]. D-dimer is also useful due to its relatively high sensitivity [2].

Traumatic aortic injury most commonly manifests as an instantaneous aortic rupture resulting from sudden deceleration forces. The mechanism of injury is usually a high-speed motor vehicle collision and the patient most often dies at the scene [3]. Aortic injury, however, consists of a spectrum of pathology ranging from subclinical intimal tears to complete rupture [4–6]. Injury may be limited to the intima and media of the vessel, allowing a subset of trauma patients to survive to hospital care and beyond. Clinical presentation of traumatic aortic injury is varied and sometimes delayed, and many patients do not show external evidence of chest injury. The D-dimer test could be useful to diagnose traumatic aortic injury too. The use of D-dimer for diagnosing aortic injury in the setting of blunt trauma has not previously been reported.

## 2. Presentation of case

A 61-year-old previously healthy male presented to our emergency department (ED) complaining of chest discomfort and shortness of breath. He was in his usual state of good health until one day prior when he was struck in the chest by a snowboarder on the side of a mountain while skiing at a resort approximately 2–3 h drive from his home. He got up without event, but 30 min later developed pain along the left side of his sternum that quickly resolved. Later that afternoon, he complained to his wife of a “hollow sensation” in his chest, worse with deep inspiration, and some mild shortness of breath with exertion. He presented the afternoon following his injury at the urging of his wife. On initial evaluation, he denied any nausea, vomiting, diaphoresis, back pain, fever, and was comfortable at rest. There were no neurologic complaints. He did note a contusion of his left lower leg from a fall on ice one week prior. He had no past medical history, did not take any medications, did not smoke, exercised regularly, and had no family history of cardiac or connective tissue disease.

His triage vital signs were: blood pressure 100/80 mm Hg, pulse 70 beats/min, respiratory rate 20 breaths/min, oxygen saturation 100% on room air, and temperature of 37.6 °C (99.7 °F). The physical examination demonstrated normal heart sounds without any murmurs, clear lungs to auscultation bilaterally, and the absence of any tenderness to palpation of the sternum or ribs or external signs of trauma. He had a soft, non-tender abdomen. A small hematoma

\* Corresponding author at: 3600 Forbes Avenue, Suite 400A, Pittsburgh, PA 15261, USA. Tel.: +1 412 421 1716.

E-mail address: [kmarill@mgh.harvard.edu](mailto:kmarill@mgh.harvard.edu) (K.A. Marill).

<http://dx.doi.org/10.1016/j.ijscr.2015.03.027>

2210-2612/© 2015 The Authors. Published by Elsevier Ltd. on behalf of Surgical Associates Ltd. This is an open access article under the CC BY-NC-ND license (<http://creativecommons.org/licenses/by-nc-nd/4.0/>).

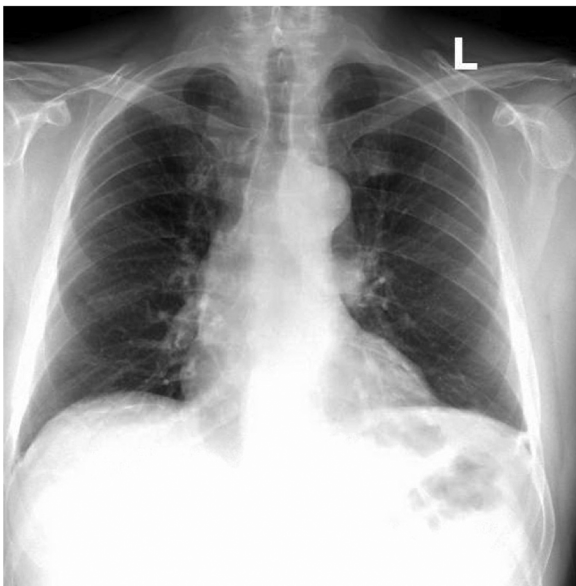


Fig. 1. Postero-anterior (PA) chest X-ray.

was noted on the left calf. Neurologic examination was grossly normal.

An electrocardiogram demonstrated normal sinus rhythm with minimal non-specific *t*-wave abnormalities. The chest X-ray did not show any evidence of pneumothorax, pulmonary contusion, rib fractures, or widened mediastinum (Fig. 1).

The initial differential diagnosis focused on pneumothorax, rib/sternal fracture, or pulmonary contusion. With the unremarkable chest X-ray, the differential diagnosis was modified and broadened to include pulmonary embolus, cardiac contusion, acute coronary syndrome, or musculoskeletal chest pain. The possibility of a traumatic aortic injury remained low on the differential given the mechanism of trauma, absence of widened mediastinum or aortic knob on chest X-ray, and the patient's well appearance.

Notable laboratory studies obtained to assess for the conditions considered included normal complete blood count, basic chemistry panel, CK-MB and Troponin-I, and a D-dimer of 6400 ng/ml (normal <500 ng/ml). A computed tomography (CT) scan of his chest with contrast timed to evaluate for a pulmonary embolus was obtained which demonstrated bovine-type aortic arch with both carotid arteries arising from the brachiocephalic artery, and a type A aortic dissection extending from the aortic root to beyond the bilateral renal arteries (Fig. 2A and B).

The patient was taken emergently to the operating room where he was found to have a linear intimal tear in the mid transverse aortic arch between the brachiocephalic and left subclavian artery takeoffs with antegrade and retrograde aortic dissection. The aortic valve was normal. The patient underwent repair of the ascending aorta with a Dacron graft and suture closure of the linear mid-arch tear.

The patient spent 6 days in the hospital, and was discharged home in good condition after a rapid and uneventful recovery. Post-operative aortic pathology demonstrated minimal atherosclerosis without evidence of aortitis.

### 3. Discussion

Aortic dissection can occur spontaneously or secondary to blunt trauma. In this case, type A aortic dissection was diagnosed in the setting of blunt chest trauma, but a causal relationship cannot be proven. A traumatic origin is suggested because the patient presented to the ED due to pain that began after the patient suffered

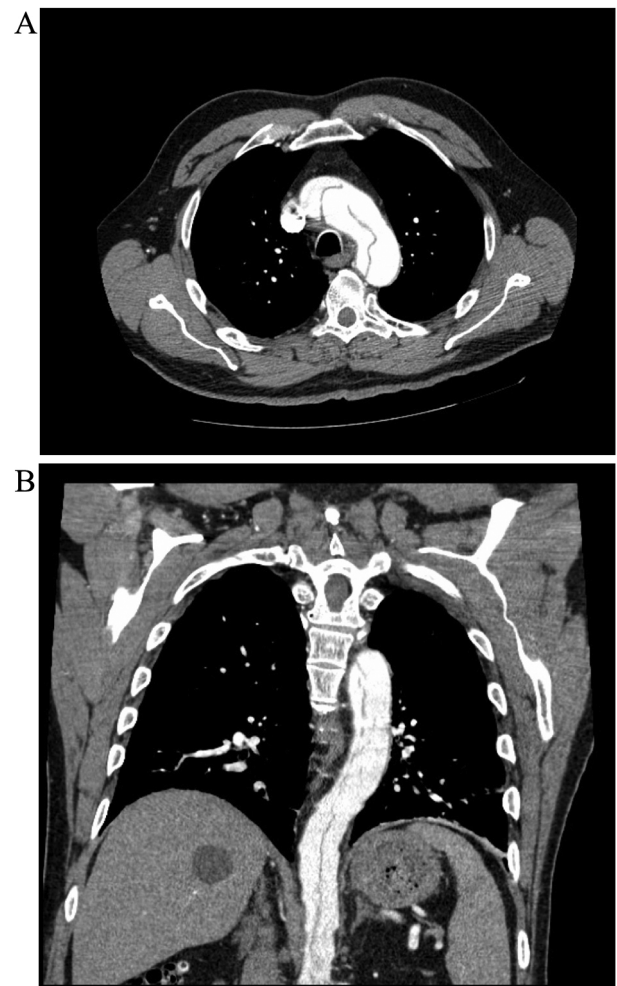


Fig. 2. (A) CT slice of aortic arch with evidence of dissection flap. (B) Reconstructed coronal CT image of the chest with evidence of extensive antegrade extension of the aortic dissection.

blunt trauma to the chest on the side of a ski slope. However, the temporal relationship of aortic dissection and blunt chest trauma may have been coincidental. The patient was also diagnosed with a bovine-type aortic arch. While this is present in approximately 15% of the general population, an association of bovine-type arch with thoracic aortic disease and possibly dissection has been described [7,8]. The patient had no other risk factors for spontaneous aortic disease, and pathology demonstrated no aortitis.

Serious aortic injury most commonly occurs after severe deceleration injuries associated with a motor vehicle accident, but other non-deceleration mechanisms such as trauma by blunt object have been described [9]. Traumatic aortic injuries most commonly occur at the level of the isthmus, but also occur in the arch, ascending portion, and elsewhere, and they may or may not be associated with hematoma formation [4,6,9]. A spectrum of severity of aortic injuries is now well described with advanced imaging [5,6]. It may be that this patient was predisposed to aortic dissection due to his anatomy, and blunt chest trauma caused or exacerbated the intimal tear that led to antegrade and retrograde dissection emanating from the aortic arch. Transient hypertension associated with injury may have also played a role.

Symptoms, vital signs, and physical exam findings are insensitive markers for aortic dissection. While chest pain is the most common symptom, it is a non-specific complaint. A history of migratory pain may be helpful, but is present in only a minority of patients with aortic dissections [10]. While hypertension plays

a role in the pathophysiology of spontaneous aortic dissection, it may not be a reliable marker for spontaneous or traumatic injury and patients may present with normal or low blood pressures as well [10].

Chest radiography is a moderately sensitive screening tool for traumatic aortic injury in trauma patients as well as for spontaneous aortic dissection. Radiographic hallmarks of aortic injury (mediastinal widening, loss of the aorticopulmonary window, rightward tracheal shift, apical capping, deviated nasogastric tube) are helpful when present. Widened mediastinum, the most notable finding, is present in 85% of patients with blunt aortic injury [11]. Mediastinal widening can be absent in 37% of patients with type A dissection as was the case in our patient [10]. A normal chest X-ray may be present in as many as 7–44% of patients with traumatic aortic injury, and as many as 12–36% of patients with spontaneous aortic dissection [2,10,12,13].

Helical CT is the preferred imaging study to detect aortic injury because of its superior sensitivity (approaching 100%) to angiography (92%), noninvasive nature, and ability to identify alternate diagnoses [11]. Helical CT is used in identifying minor intimal defects in patients with blunt chest trauma. Some of these defects heal without intervention, while others develop into pseudoaneurysms over the course of weeks [5].

Serum D-dimer has been shown to be elevated in spontaneous aortic dissection. Retrospective studies have demonstrated sensitivities greater than 90%, and several prospective studies have demonstrated sensitivities as high as 100% [2,14–17]. Some authors including one of us postulate, based on its low negative likelihood ratio and high negative predictive value, that a normal D-dimer test is useful to lower further the likelihood of acute aortic dissection in patients at low risk based on the history, normal vital signs and physical exam, and a negative chest X-ray. This may obviate the need for advanced aortic imaging in some patients [2,15,17]. Other authors caution against using D-dimer as a rule-out test based on false negatives encountered in retrospective and prospective studies of patients with aortic dissection [18,19].

The use of D-dimer to diagnose acute traumatic aortic injury in patients with blunt chest trauma, to our knowledge, has not been studied or described. The classic teaching that aortic injury secondary to blunt trauma is associated with a major mechanism, significant physical findings, and abnormalities of chest radiography is not universally true [5,9,10,13]. In this patient who presented with only mild symptoms temporally associated with a traumatic event, aortic dissection was discovered in pursuit of an unrelated diagnosis using a D-dimer test.

There could be some diagnostic value in a D-dimer test in patients with chest pain who present after blunt trauma and a relatively minor mechanism of injury. A positive D-dimer may help to increase the level of suspicion for traumatic aortic or other vascular injury suggesting the need for further diagnostic imaging [20]. Traumatic aortic injuries that are survivable in the field are still associated with high mortality when the diagnosis is missed or delayed in the ED, necessitating that consideration be given to all useful diagnostic modalities available.

In this single case, aortic dissection in association with blunt chest trauma was identified and surgically repaired as a result of an elevated serum D-dimer. If further studies suggest that serum D-dimer can be used to help assess for acute traumatic aortic dissection, a number of related questions remain. The patient described had a markedly elevated D-dimer of 6400 ng/ml. Current data suggests the optimal threshold for a positive test for both pulmonary embolism (PE) and acute spontaneous aortic dissection is approximately 500 ng/ml. The optimal threshold and resulting test sensitivity and specificity if applied to traumatic injury are unknown. Furthermore, a markedly elevated value might be of some value in differentiating aortic injury from other conditions

with elevated D-dimer such as PE or deep vein thrombosis (DVT). Finally, a markedly elevated D-dimer could suggest the need for further testing in those rare cases where the CT is falsely negative.

#### 4. Conclusion

A patient was diagnosed with type A aortic dissection temporally associated with blunt chest trauma. Despite an initial normal chest X-ray, a timely diagnosis was made because of an elevated serum D-dimer fortuitously obtained in pursuit of an alternate diagnosis. This case reinforces recent observations that a spectrum of aortic injuries is possible. Most importantly, it introduces the intriguing possibility that the serum D-dimer could be used to help assess the likelihood of aortic injury in selected low risk patients.

#### Conflicts of interest

There are no known conflicts of interest.

#### Ethical approval

It is the policy of our institutional review board (IRB) at Massachusetts General Hospital that ethical approval is not required for anonymous report of a single case and none was obtained.

#### Author contribution

Dr. Penn provided care for the patient and drafted the manuscript.

Dr. Martindale helped research the subject matter and helped edit the manuscript.

Dr. Milne supervised the patient's care and helped edit the manuscript.

Dr. Marill helped draft and edit the manuscript.

#### Consent

Written informed consent was obtained from the patient for publication of this case report and accompanying images. A copy of the written consent is available for review by the Editor-in-Chief of this journal on request.

#### Guarantor

Keith A. Marill.

#### Acknowledgements

This work was supported by the NIH NHLBI with grant #5K12HL109068-03 (KAM). The study sponsor had no involvement in any aspects of the execution or submission of this report.

#### References

- [1] M. Klompas, Does this patient have an acute thoracic aortic dissection? *JAMA* 287 (2002) 2262–2272.
- [2] T. Suzuki, A. Distant, A. Zizza, S. Trimarchi, M. Villani, J.A. Salerno Uriarte, et al., Diagnosis of acute aortic dissection by D-dimer: the international registry of acute aortic dissection substudy on biomarkers (IRAD-Bio) experience, *Circulation* 119 (2009) 2702–2707.
- [3] R. Smith, F. Chang, Traumatic rupture of the aorta: still a lethal injury, *Am. J. Surg.* 152 (1986) 660–663.
- [4] D.G. Neschis, T.M. Scalea, W.R. Flinn, B.P. Griffith, Blunt aortic injury, *N. Engl. J. Med.* 359 (2008) 1708–1716.
- [5] A.K. Malhotra, T.C. Fabian, M.A. Croce, D.S. Weiman, M.L. Gavant, J.W. Pate, Minimal aortic injury: a lesion associated with advancing diagnostic techniques, *J. Trauma* 51 (2001) 1042–1048.

- [6] V.X. Mosquera, M. Marini, D. Guillas, I. Cao, J. Muñiz, J.M. Herrera-Noreña, et al., Minimal traumatic aortic injuries: meaning and natural history, *Interact. Cardiovasc. Thorac. Surg.* 14 (2012) 773–778.
- [7] M. Hornick, R. Moomiaie, H. Mojibian, B. Ziganshin, Z. Almuwaqqat, E.S. Lee, et al., 'Bovine' aortic arch – a marker for thoracic aortic disease, *Cardiology* 123 (2012) 116–124.
- [8] K.M. Wanamaker, C.C. Amadi, J.S. Mueller, R.J. Moraca, Incidence of aortic arch anomalies in patients with thoracic aortic dissections, *J. Card. Surg.* 28 (2013) 151–154.
- [9] L.F. Parmley, T.W. Mattingly, W.C. Manion, E.J. Jahnke Jr., Nonpenetrating traumatic injury of the aorta, *Circulation* 17 (1958) 1086–1101.
- [10] P. Hagan, C. Nienaber, E. Isselbacher, D. Bruckman, D.J. Karavite, P.L. Russman, et al., The international registry of acute aortic dissection (IRAD): new insights into an old disease, *JAMA* 283 (2000) 897–903.
- [11] T. Fabian, J. Richardson, M. Croce, J.S. Smith Jr, G. Rodman Jr, P.A. Kearney, et al., Prospective study of blunt aortic injury: Multicenter Trial of the American Association for the Surgery of Trauma, *J. Trauma* 42 (1997) 374–380, Discussion 80–83.
- [12] D. Demetriades, H. Gomez, G. Velmahos, J.A. Asensio, J. Murray, E.E. Cornwell 3rd, et al., Routine helical computed tomographic evaluation of the mediastinum in high-risk blunt trauma patients, *Arch. Surg.* 133 (1998) 1084–1088.
- [13] J. Woodring, The normal mediastinum in blunt traumatic rupture of the thoracic aorta and brachiocephalic arteries, *J. Emerg. Med.* 8 (1990) 467–476.
- [14] H. Eggebrecht, C. Naber, C. Bruch, K. Kröger, C. von Birgelen, A. Schmermund, et al., Value of plasma fibrin D-dimers for detection of acute aortic dissection, *J. Am. Coll. Cardiol.* 44 (2004) 804–809.
- [15] A. Perez, P. Abbet, M. Drescher, D-dimers in the emergency department evaluation of aortic dissection, *Acad. Emerg. Med.* 11 (2004) 397–400.
- [16] P. Ohlmann, A. Faure, O. Morel, H. Petit, H. Kabbaj, N. Meyer, et al., Diagnostic and prognostic value of circulating D-dimers in patients with acute aortic dissection, *Crit. Care Med.* 34 (2006) 1358–1364.
- [17] K.A. Marill, Serum D-dimer is a sensitive test for the detection of acute aortic dissection: a pooled meta-analysis, *J. Emerg. Med.* 34 (2008) 367–376.
- [18] J. Wiegand, M. Koller, R. Bingisser, Does a negative D-dimer test rule out aortic dissection? *Swiss Med. Wkly.* 137 (2007) 462.
- [19] D. Paparella, P. Malvindi, G. Scarscia, D. de Ceglia, C. Rotunno, F. Tunzi, et al., D-dimers are not always elevated in patients with acute aortic dissection, *J. Cardiovasc. Med. (Hagerstown)* 10 (2009) 212–214.
- [20] J.V. O'Connor, C. Byrne, T.M. Scalea, B.P. Griffith, D.G. Neschis, Vascular injuries after blunt chest trauma: diagnosis and management, *Scand. J. Trauma Resusc. Emerg. Med.* 17 (2009) 42.

#### Open Access

This article is published Open Access at [sciendoirect.com](http://sciendoirect.com). It is distributed under the [IJSCR Supplemental terms and conditions](#), which permits unrestricted non commercial use, distribution, and reproduction in any medium, provided the original authors and source are credited.