

Utility of endoscopic ultrasound in the diagnosis and management of esophagogastric varices

An-Jiang Wang*, Bi-Min Li*, Xue-Lian Zheng¹, Xu Shu, Xuan Zhu

Department of Gastroenterology and Hepatology and ¹Department of Pharmacy, The First Affiliated Hospital of Nanchang University, Nanchang 330006, China

ABSTRACT

Endoscopic ultrasound (EUS) has significantly improved our understanding of the complex vascular structural changes in patients with portal hypertension. At present, EUS is a useful diagnostic tool for the evaluation of esophagogastric varices (EGVs) and guidance of endoscopic therapy. Several studies have employed this new technique for the diagnosis and management of esophageal and gastric varices, respectively. In the present review, we have summarized the current status of EUS for the diagnosis and management of EGVs and clarified the clinical feasibility of this procedure. New indications for EUS can be developed in the future after adequate validation.

Key words: Endoscopic ultrasound, esophageal varices, gastric varices, portal hypertension

INTRODUCTION

Bleeding from esophagogastric varices (EGVs) is one of the most common causes of death among patients with portal hypertension. The successful diagnosis and management of EGVs can significantly improve the outcomes for such patients. There are several types of endoscopic treatment for EGVs, such as endoscopic injection sclerotherapy (EIS), endoscopic variceal ligation (EVL), or cyanoacrylate glue (CYA) injection under conventional endoscopy. However, these approaches are performed blindly because the exact location of the varix under or outside the wall of the esophagus and stomach cannot be observed directly.

Recently, endoscopic ultrasound (EUS) has provided advantages in the diagnosis and management of EGVs. The largest advantage of EUS is that it allows endoscopists to observe the varix lumen directly under or outside the wall of the esophagus and stomach. In this review, we aimed to highlight the utility of EUS in the diagnosis and management of EGVs. Articles for this review were selected from a PubMed review of English-language articles. Furthermore, references were reviewed to retrieve additional articles related to this field.

This is an open access article distributed under the terms of the Creative Commons Attribution-NonCommercial-ShareAlike 3.0 License, which allows others to remix, tweak, and build upon the work non-commercially, as long as the author is credited and the new creations are licensed under the identical terms.

For reprints contact: reprints@medknow.com

How to cite this article: Wang AJ, Li BM, Zheng XL, Shu X, Zhu X. Utility of endoscopic ultrasound in the diagnosis and management of esophagogastric varices. *Endosc Ultrasound* 2016;5:218-24.

Access this article online

Quick Response Code:



Website:

www.eusjournal.com

DOI:

10.4103/2303-9027.187840

*These two authors contributed equally to this work.

Address for correspondence

Dr. Xuan Zhu, Department of Gastroenterology and Hepatology, The First Affiliated Hospital of Nanchang University, 17, Yongwai Zheng Street, Nanchang 330006, China. E-mail: jyyfyzx@163.com

Received: 2015-09-09; **Accepted:** 2016-04-01

GRADING OF ESOPHAGOGASTRIC VARICES

Grading of esophageal varices

Grading of esophageal varices (EVs) by endoscopy is subjective. At present, there are three grading systems, including those put forth by Dagradi,^[1] the Japanese Research Society for Portal Hypertension (JRSPH),^[2] and the North Italian Endoscopy Club for the Study and Treatment of EVs (NIEC).^[3] In 1972, Dagradi classified EVs into five Grades: I: EVs measuring 1–2 mm in diameter with a straight or sigmoid shape; II: EVs similar to Grade I but visible without occluding blood flow in the vessel; III: EVs 3–4 mm in diameter and straight or tortuous; IV: EVs 4–5 mm in diameter, tortuous, often coiled, and observed in all quadrants of the esophagus; and V: EVs larger than 5 mm in diameter, tightly packed, grape-like, and covered by thin, wrinkled mucosa with overlying cherry-red spots and telangiectasias. In 1980, the JRSPH system classified varices according to location, form, color, and the red color sign as follows: (1) The location of the varices may be the upper, middle, or lower third of the esophagus or upper stomach; (2) the form of the varices is classified as small and straight (F1), enlarged and tortuous (F2), or large and coil-shaped (F3); (3) the color of the varices is graded as white (Cw) or blue (Cb); (4) the red color sign is present in cases with dilated, small vessels (red wale sign), and telangiectasias or cherry-red spots on the surface of the varices. In 1988, the NIEC index-graded EVs based on the following factors: (1) The Child-Pugh Class of Cirrhosis (A, B, or C), (2) variceal size (small, medium, or large), and (3) the presence of red color signs (absent, mild, moderate, or severe).

Grading of gastric varices

Gastric varices (GVs) are generally classified using Sarin's classification^[4,5] based on the location and direction of blood flow. Gastroesophageal varices 1 (GOV1) is the most common type and accounts for 74% of all GVVs; this type consists of EVs extending along the lesser curvature of the stomach. GOV2 is used to define EVs extending along the greater curvature near the fundus. IGV1 (isolated GVVs) describes isolated GVVs localized to the fundus, with no association with EVs; these GVVs emerge from splenorenal or gastorenal shunts, in which the feeding vessel emerges from the splenic hilum and drains into the left renal vein via the gastric cardia or fundus veins. IGV2 describes isolated GVVs presenting elsewhere other than the fundus, which drains in a similar fashion

into the left renal vein but with multiple tributaries. GOV2 and IGV1 account for 80% of all bleeding GV patients, although they are less prevalent than GOV1 varices. Another commonly used classification of GVVs is based on the shape of the varices (tortuous = F1, nodular = F2, and tumorous = F3), their location (anterior = La, posterior = Lp, lesser curvature = Ll, greater curvature = Lg, the cardia, and fundic area = Lf) and their color (white = Cw or red = Cr).^[6]

VISUALIZATION AND EVALUATION OF ESOPHAGOGASTRIC VARICES

Visualization and evaluation of esophageal varices

EUS was found to be inferior to conventional endoscopy in detecting and grading EVs (14% in Grade 1, 50% in Grade 2, and 78% in Grade 3) but superior in the detection of periesophageal veins (57% in Grade 1, 89% in Grade 2, and 100% in Grade 3) and gastric fundal veins. Moreover, the detection of periesophageal veins with EUS increased with an increasing diameter of EVs at endoscopy. Similar observations were made in another study, suggesting the sensitivity of EUS may increase with higher endoscopic grade of EVs.^[7]

Visualization and evaluation of gastric varices

A number of studies have confirmed the superiority of EUS over conventional endoscopy in the detection of GVVs.^[8–12] A recent study indicated that the GV diameter, which was independent from the variceal form, Child-Pugh Classification and the presence of hepatocellular carcinoma was closely related to the GV flow volume.^[13]

Visualization and evaluation of the portal vein, portosystemic shunt, andazygous vein

Wiersema *et al.*^[14] used duplex and color Doppler (CD) EUS to assess 20 asymptomatic volunteers and 11 patients with suspected splenic and/or portal thrombosis or a portosystemic shunt. In 10 of the 11 patients, duplex endosonography provided a correct diagnosis in 10/11 patients, while transabdominal ultrasound failed to provide a correct diagnosis in all of the patients. This finding indicated that patients with suspected splenic and/or portal thrombosis or a portosystemic shunt should undergo EUS when transabdominal ultrasound is nondiagnostic. Another study also compared the detection rate of curved linear array (CLA) EUS for gastorenal

shunts with that of contrast-enhanced computed tomography (CECT). These results showed that CLA echo-endoscopy could successfully identify a gastrosplenic shunt and provide similar accuracy with CECT.^[15] The diameter of the azygous vein using EUS at its distal and proximal margins was also significantly greater in patients with portal hypertension. Moreover, the study indicated the diameter also increased with the variceal grade.^[18]

PREDICTION OF BLEEDING AND EVALUATION OF THE TREATMENT RESPONSE

Prediction of bleeding

EUS can identify hematocystic spots on the surface of EVs, whose presence is closely associated with a high risk of esophageal variceal rupture. These appear as saccular aneurysms, similar to projections on the variceal surface as observed using high-resolution endoluminal sonography.^[16] Moreover, paraesophageal and paragastric varices detected by EUS have been shown to correlate with the presence and severity of portal hypertension and may be a risk factor for variceal bleeding.

Several studies have classified these collaterals as large if they were >5 mm^[17] or wider than the splenic vein.^[18] Faigel studied 36 cirrhotic patients (31 with prior hemorrhage) and 32 control patients, and paraesophageal varices were detected in 97% of cirrhotic patients and 3% of control patients. In addition, the gastric mucosa and submucosa were thicker for cirrhotic compared to control patients, and paraesophageal varices (odds ratio [OR] 3.1) and paragastric varices (OR 3.7) were larger in hemorrhage patients.^[19] A study by Miller *et al.*^[20] showed that EUS could measure the severity of EVs by summing the cut surface area (CSA) using a digitized image. These authors demonstrated a 76-fold increase per year in the risk of variceal rebleeding for each 1 cm² increase in variceal CSA. Using a cutoff value of 0.45 cm² for the CSA, the sensitivity and specificity for future variceal bleeding above and below this value were 83% and 75%, respectively.

Evaluation of the endoscopic treatment response

One study used EUS to examine 38 patients who had undergone EIS. EUS found a significantly higher incidence of severe-type periesophageal collateral veins

and significantly larger and more perforating veins in patients with endoscopic recurrences of EVs compared to patients without recurrence.^[21] Another study used CD-EUS to study 306 patients in which EVs had been treated with EIS. These patients underwent CD-EUS before EIS and 3–5 months after EIS and the results showed that the predictors of early recurrence of EVs within 1 year included more perforating veins and the inflowing type of perforating veins before EIS and more cardiac intramural veins and perforating veins and the inflowing type of perforating veins after EIS.^[22] EUS also enabled visualization of the left gastric vein (LGV). The branching pattern of the LGV was also found to be closely associated with the early recurrence of EVs as the dominance of the anterior branch may be responsible for directing LGV blood flow toward varices at the level of the proximal stomach.^[23] Hepatofugal flow velocity was also shown to increase with varices of an increasing size.^[24] Kuramochi *et al.*^[25] included 68 patients treated for moderate or large EVs who underwent CD-EUS after EVL and sclerotherapy. Patients with a high hepatofugal flow velocity in the LGV (>12 cm/s) or an anterior branch dominant pattern were classified into a high-risk group. Half of the patients showed a recurrence of EVs within half a year, whereas it took nearly 2 years for half of the patients in the other group to exhibit a recurrence. The hazard ratio of these features for early recurrence was 3.0. Another study collected thirty consecutive patients with EVs at high risk for bleeding, and simultaneous conventional endoscopy and EUS were performed before endoscopic therapy. This study showed that EUS revealed cardiac submucosal varices in all patients, while conventional endoscopy showed varices in 70% of patients. Furthermore, patients with recurrent EVs were more likely to have severe-grade perforating veins prior to treatment (71.4%) compared to patients without recurrence (12.5%), and patients with severe as opposed to mild-grade perforating veins before treatment had a significantly higher recurrence rate (90.9% *vs.* 21.0%).^[10]

Evaluation of the pharmaceutical and surgical treatment response

With EUS, the azygos vein diameter as well as valuable quantitative and qualitative data, such as the blood flow volume index, can be obtained.^[26] Azygos blood flow (AzBF) and diameter can serve as an index of blood flow via gastroesophageal collateral vessels and varices in portal hypertension.^[26,27] Lee *et al.*^[28] studied the feasibility of assessing AzBF

using CD-EUS and of monitoring the effects of vasoactive agents on AzBF, and these authors found that there was a marked decrease in AzBF after 1, 5, and 10 min bolus injections of terlipressin and somatostatin. However, the control group showed no significant change in AzBF. Liao *et al.*^[29] used EUS to evaluate the volumetric change of paraesophageal varices in patients treated with propranolol who achieved EV eradication using primary EVL. These authors concluded that EUS is an objective and useful tool to measure PEV and to predict the recurrence of EV. Another study included 42 cirrhotic patients with EGV treated with devascularization surgery for variceal hemorrhage and demonstrated that combined percutaneous transhepatic portography and EUS was very helpful in determining the adequate modalities of devascularization surgery.^[30]

ASSISTANCE IN ENDOSCOPIC THERAPY

Assistance in endoscopic therapy on esophageal varices

The injection of sclerosant has been generally performed under conventional endoscopy to treat EV. The injection is “blind” and may be paravariceal. Delivery of sclerosant under EUS guidance through a standard fine-needle aspiration (FNA) needle has the advantage of enabling real-time confirmation of delivery into the varix lumen. EUS can display the main “perforator” feeding vein. Targeting the perforating vessel rather than the varix lumen reduced the amount of sclerosant needed to achieve obliteration of varices and reduced the risk of rebleeding and complication. It may also decrease the recurrence rate of EVs after initial obliteration.^[31] A randomized controlled trial compared the efficacy of EIS and EUS-guided sclerotherapy of esophageal collateral veins. The results showed that the recurrence of EVs was less frequent and occurred later, although a significant difference was not achieved [Figure 1].^[32] However, this trial has some limitations, such as one-center experience and small sample size. This conclusion needs to be confirmed in more multicenter trials with large sample size. Only after proving the superiority of EUS over conventional endoscopy, we could recommend routine use of EUS for treating EGVs.

Assistance in endoscopic therapy on gastric varices

It is known that delivery of CYA under EUS guidance has the advantage of enabling precise delivery of the glue into the varix lumen. EUS also enables an assessment using Doppler to confirm vessel obliteration

after treatment. However, targeting the perforating feeder vessel rather than the varix lumen itself may theoretically minimize the amount of CYA needed to achieve obliteration of GVs and thereby reduce the risk of embolization. Romero-Castro *et al.*^[33] assessed the efficacy of EUS-guided CYA injection at the entrance of the perforating veins to obtain variceal obturation in five consecutive GV patients. These patients successfully underwent the procedure without recurrent bleeding or other complications during the study follow-up period. However, one limitation of this approach is that identification of the perforating vessel with EUS can be difficult and time-consuming. Liao *et al.*^[34] used a miniature ultrasound probe (MUP) to evaluate the adequacy of tissue adhesive obturation of GVs in patients with bleeding. These authors demonstrated that MUP could evaluate inadequate obturation of GVs and guide the reinjection of CYA, which may reduce the probability of rebleeding. A multicenter study retrospectively compared the feasibility, safety, and application of CYA injection and EUS-guided coil application (ECA) embolization of feeding GVs.^[35] Thirty consecutive patients with localized GVs in tertiary medical centers received either CYA injection (19 patients) or ECA (11 patients) and they were followed up to 6 months after treatment. The results showed no significant difference in the GV obliteration rate between the two groups (94.7% in CYA *vs.* 90.9% in ECA). However, adverse events occurred much more frequently in the CYA group (57.9%) compared to the ECA group (9.1%), although no patients died from causes related to the procedures or bleeding. This study also revealed that ECA required fewer endoscopies and tended to have fewer adverse events compared with CYA injection in treating localized GVs. Another study reported a fistula-like communication between the gastric wall and paragastric collateral vessels suspected by EUS in a patient after CYA injection for GV bleeding.^[36] Conventional

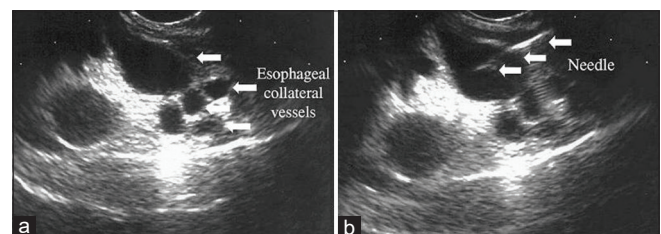


Figure 1. Endoscopic ultrasound-guided sclerotherapy. (a) Endoscopic ultrasound image showing esophageal collateral vessels (arrows); (b) endoscopic ultrasound-guided sclerotherapy for esophageal varices (arrows indicate needle location) (reprinted with permission from Elsevier)

endoscopic examination showed no active bleeding, and only a small ulcer-like mucosal depression over the previous CYA injection site was ever found. EUS-guided CYA injection into the paragastric collateral vessels, and the amount of CYA required for obliteration of the injected vessel was also determined under EUS.

Assistance in endoscopic transesophageal therapy on gastric varices

The gastric fundus is well visualized on EUS with the transducer positioned in the distal esophagus. In addition to enabling EUS-guided access to the GFV, the transesophageal approach is not hindered by gastric contents, such as blood and food. There is also no disruption of the gastric mucosa overlying the varix. One study assessed the feasibility, safety, and efficacy of transesophageal EUS-guided therapy of GFV with combined coil and CYA injection.^[37] These investigators enrolled thirty patients with gastric fundal varices between 2009 and 2011, and these patients successfully underwent EUS-guided transesophageal treatment of GFV. Their results demonstrated that the mean number of treatments was 1.3 per patient, and the mean volume of CYA was 1.4 mL per varix. Hemostasis of acute bleeding was achieved in all patients, and GFVs were obliterated after a single treatment session in 96% of patients. Rebleeding occurred in only 16.6% of patients, and none of the cases of rebleeding was due to GFV. Furthermore, no procedure-related complications were found. However, this was a pilot study at a single center, and the safety and efficacy of this novel technique warrant further investigation [Figures 2 and 3].

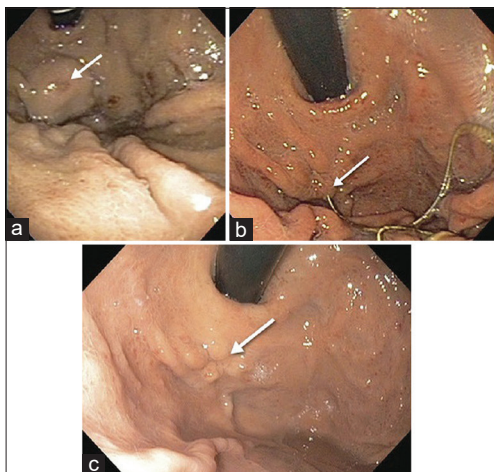


Figure 2. Endoscopic views (a) gastric varices with stigmata of recent bleeding (arrow) by using the forward-view curved linear array endoscopic ultrasound; (b) coil and glue extrusion (arrow) 1 month after treatment; (c) eradication of gastric varices (arrow) 3 months after treatment (reprinted reference with permission from Elsevier)

Assistance in endoscopic intrahepatic portosystemic shunt

The ability to access the portal vein via the stomach or duodenum may provide potential future therapeutic use, such as the direct placement of an EUS-guided intrahepatic portosystemic shunt (IPSS). Buscaglia *et al.*^[38] studied the feasibility of EUS-guided IPSS creation in a live porcine model. Under linear-array EUS guidance, these authors punctured the hepatic vein and subsequently the portal vein using a 19-gauge FNA needle, and a metal stent was deployed under EUS and fluoroscopic guidance. The distal end of the stent was positioned inside the portal vein, and the proximal end was within the hepatic vein [Figure 4]. There was no evidence of bleeding or damage to any intraperitoneal organs after the entire procedure. There were also no complications during the follow-up period over the next 2 weeks. Taken together, these data suggest that EUS-guided creation of an IPSS might become a useful alternative to conventional transjugular intrahepatic portosystemic stent-shunt.

CONCLUSION

EUS plays an important role in the diagnosis and management of EGVs [Table 1]. Indeed, its use in EGVs and portal hypertension has expanded with the increasing availability of this instrument

Table 1. Utility of endoscopic ultrasound in the diagnosis and management of esophagogastric veins

Diagnosis
Visualization and evaluation of EGVs (including peri- and para-esophagogastric varices, perforating veins, and LGVs)
Visualization of portal and azygos venous system changes (including portosystemic shunts)
Management
Prediction of bleeding of EGVs
Prediction of variceal rebleeding and recurrence of EGVs after therapy
Assessment of pharmacological effects of drugs on PH
Determining adequate modalities of devascularization surgery for EGV
Assistance in endoscopic therapy
EUS-guided sclerotherapy for EV and cyanoacrylate injection for GV
EUS-guided coil application with/without cyanoacrylate injection for GV
EUS-guided endoscopic transesophageal therapy for GV
EUS-guided creation of an IPSS

EUS: Endoscopic ultrasound, EGVs: Esophagogastric veins, LGV: Left gastric veins, PH: Portal hypertension, EV: Esophageal varices, GV: Gastric varices, IPSS: Intrahepatic portosystemic shunt

worldwide and has improved our understanding and training in endosonography. However, EUS-guided therapy has some concerns as well. Few single-centered randomized trials with small sample size have proved the superiority of EUS-guided approach

over conventional endoscopic one. As EUS-guided therapy of EGVs is more expensive for patients and more experience-demanding for endoscopists than conventional endoscopy approach, the cost benefit of the EUS-guided treatment of varices has to be considered as well. With regards to the injection for the treatment of EV and GV, there is currently no consensus on the location of injection, number of injections in each session, type of agents, and volume of each injection, which have an influence on the efficacy and safety of the procedure. There are large variations in these aspects among procedures by different endoscopists due to their technical level and experiences. However, we believe that the use of EUS in the diagnosis and therapy of EGVs is expanding and will continue to play a more significant role in this field in the future.

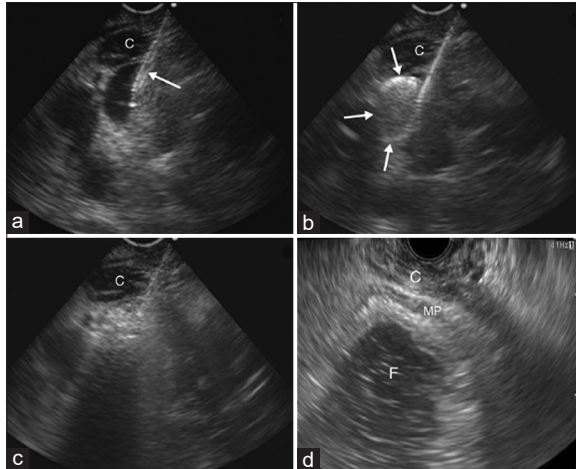


Figure 3. Endoscopic ultrasound-guided treatment of gastric varices with combined coiling and glue injection. (a) Transesophageal endoscopic ultrasound views (forward-view curved linear array endoscopic ultrasound) showing gastric varices targeted with a 19 gauge needle (arrow), (b) deployment of coil (arrows) through the 19 gauge needle, (c) injection of 1 mL glue through the 19 gauge needle to obliterate the gastric varice, and (d) eradication of gastric varices (conventional curved-linear endoscopic ultrasound). C: Crus muscle; F: Gastric fundus; MP: Muscularis propria of the gastric wall (reprinted from with permission from Elsevier)

Financial support and sponsorship

This study was financially supported by the National Natural Science Fund (No. 81460122) and the Project in the Science and Technology Pillar Program of Jiangxi Provincial Department of Science and Technology (No. 20161BBG70166).

Conflicts of interest

There are no conflicts of interest.

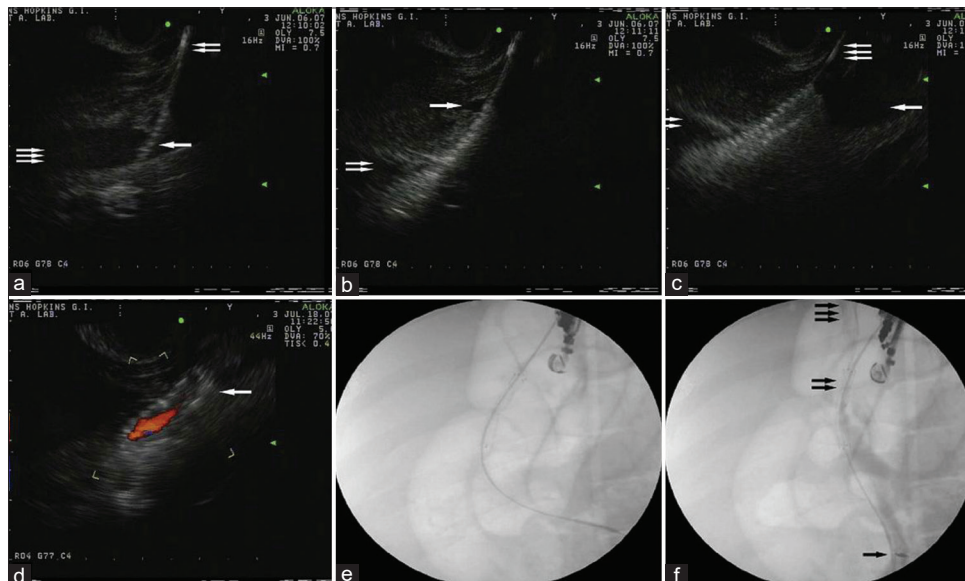


Figure 4. Endoscopic ultrasound and fluoroscopic view of endoscopic ultrasound-guided transjugular intrahepatic portosystemic shunt. (a) The stent (one arrow) is advanced over the guidewire (two arrows) into the HV (three arrows) and (b) deployment of the stent started from its distal end. The stent was inside the HV (one arrow) and the PV (two arrows), (c) the stent was fully deployed inside the HV (one arrow) and the PV (two arrows) over the guidewire (three arrows), (d) fluoroscopic view showing the stent was fully deployed, (e) endoscopic ultrasound with color Doppler demonstrating blood flow through the fully deployed stent (one arrow), (f) fluoroscopy demonstrated the flow of contrast injected into the PV (one arrow) through the stent (two arrows) and into the HV (three arrows) (reprinted with permission from Elsevier)

REFERENCES

- Dagradi AE. The natural history of esophageal varices in patients with alcoholic liver cirrhosis. An endoscopic and clinical study. *Am J Gastroenterol* 1972;57:520-40.
- Idezuki Y. General rules for recording endoscopic findings of esophagogastric varices (1991). Japanese Society for Portal Hypertension. *World J Surg* 1995;19:420-2.
- North Italian Endoscopic Club for the Study and Treatment of Esophageal Varices. Prediction of the first variceal hemorrhage in patients with cirrhosis of the liver and esophageal varices. A prospective multicenter study. *N Engl J Med* 1988;319:983-9.
- Sarin SK, Kumar A. Gastric varices: Profile, classification, and management. *Am J Gastroenterol* 1989;84:1244-9.
- Sarin SK, Lahoti D, Saxena SP, et al. Prevalence, classification and natural history of gastric varices: A long-term follow-up study in 568 portal hypertension patients. *Hepatology* 1992;16:1343-9.
- Hashizume M, Kitano S, Yamaga H, et al. Endoscopic classification of gastric varices. *Gastrointest Endosc* 1990;36:276-80.
- Burtin P, Calès P, Oberti F, et al. Endoscopic ultrasonographic signs of portal hypertension in cirrhosis. *Gastrointest Endosc* 1996;44:257-61.
- Caletti G, Brocchi E, Baraldini M, et al. Assessment of portal hypertension by endoscopic ultrasonography. *Gastrointest Endosc* 1990;36 2 Suppl: S21-7.
- Choudhuri G, Dhiman RK, Agarwal DK. Endosonographic evaluation of the venous anatomy around the gastro-esophageal junction in patients with portal hypertension. *Hepatogastroenterology* 1996;43:1250-5.
- Konishi Y, Nakamura T, Kida H, et al. Catheter US probe EUS evaluation of gastric cardia and perigastric vascular structures to predict esophageal variceal recurrence. *Gastrointest Endosc* 2002;55:197-203.
- Lo GH, Lai KH, Cheng JS, et al. Prevalence of paraesophageal varices and gastric varices in patients achieving variceal obliteration by banding ligation and by injection sclerotherapy. *Gastrointest Endosc* 1999;49(4 Pt 1):428-36.
- Pontes JM, Leitão MC, Portela FA, et al. Endoscopic ultrasonography in the treatment of oesophageal varices by endoscopic sclerotherapy and band ligation: Do we need it? *Eur J Gastroenterol Hepatol* 1995;7:41-6.
- Imamura H, Irisawa A, Shibukawa G, et al. Echo-endoscopic analysis of variceal hemodynamics in patient with isolated gastric varices. *Endosc Ultrasound* 2014;3:238-44.
- Wiersema MJ, Chak A, Kopecky KK, et al. Duplex Doppler endosonography in the diagnosis of splenic vein, portal vein, and portosystemic shunt thrombosis. *Gastrointest Endosc* 1995;42:19-26.
- Kakutani H, Hino S, Ikeda K, et al. Use of the curved linear-array echo endoscope to identify gastrosplenic shunts in patients with gastric fundal varices. *Endoscopy* 2004;36:710-4.
- Schiano TD, Adrain AL, Vega KJ, et al. High-resolution endoluminal sonography assessment of the hemocystic spots of esophageal varices. *Gastrointest Endosc* 1999;49(4 Pt 1):424-7.
- Leung VK, Sung JJ, Ahuja AT, et al. Large paraesophageal varices on endosonography predict recurrence of esophageal varices and rebleeding. *Gastroenterology* 1997;112:1811-6.
- Nakamura H, Endo M, Shimoyama K, et al. Esophageal varices evaluated by endoscopic ultrasonography: Observation of collateral circulation during non-shunting operations. *Surg Endosc* 1990;4:69-74.
- Faigel DO, Rosen HR, Sasaki A, et al. EUS in cirrhotic patients with and without prior variceal hemorrhage in comparison with noncirrhotic control subjects. *Gastrointest Endosc* 2000;52:455-62.
- Miller L, Banson FL, Bazir K, et al. Risk of esophageal variceal bleeding based on endoscopic ultrasound evaluation of the sum of esophageal variceal cross-sectional surface area. *Am J Gastroenterol* 2003;98:454-9.
- Irisawa A, Saito A, Obara K, et al. Endoscopic recurrence of esophageal varices is associated with the specific EUS abnormalities: Severe periesophageal collateral veins and large perforating veins. *Gastrointest Endosc* 2001;53:77-84.
- Sato T, Yamazaki K, Toyota J, et al. Endoscopic ultrasonographic evaluation of hemodynamics related to variceal relapse in esophageal variceal patients. *Hepatol Res* 2009;39:126-33.
- Hino S, Kakutani H, Ikeda K, et al. Hemodynamic analysis of esophageal varices using color Doppler endoscopic ultrasonography to predict recurrence after endoscopic treatment. *Endoscopy* 2001;33:869-72.
- Hino S, Kakutani H, Ikeda K, et al. Hemodynamic assessment of the left gastric vein in patients with esophageal varices with color Doppler EUS: Factors affecting development of esophageal varices. *Gastrointest Endosc* 2002;55:512-7.
- Kuramochi A, Imazu H, Kakutani H, et al. Color Doppler endoscopic ultrasonography in identifying groups at a high-risk of recurrence of esophageal varices after endoscopic treatment. *J Gastroenterol* 2007;42:219-24.
- Kassem AM, Salama ZA, Zakaria MS, et al. Endoscopic ultrasonographic study of the azygos vein before and after endoscopic obliteration of esophagogastric varices by injection sclerotherapy. *Endoscopy* 2000;32:630-4.
- Bosch J, Mastai R, Kravetz D, et al. Measurement of azygos venous blood flow in the evaluation of portal hypertension in patients with cirrhosis. Clinical and haemodynamic correlations in 100 patients. *J Hepatol* 1985;1:125-39.
- Lee YT, Sung JJ, Yung MY, et al. Use of color Doppler EUS in assessing azygos blood flow for patients with portal hypertension. *Gastrointest Endosc* 1999;50:47-52.
- Liao WC, Chen PH, Hou MC, et al. Endoscopic ultrasonography assessment of para-esophageal varices predicts efficacy of propranolol in preventing recurrence of esophageal varices. *J Gastroenterol* 2015;50:342-9.
- Hsieh JS, Jan CM, Lu CY, et al. Preoperative evaluation of endoscopic ultrasonography and portography in selecting devascularization surgery for esophagogastric varices. *Am Surg* 2005;71:439-44.
- Lahoti S, Catalano MF, Alcocer E, et al. Obliteration of esophageal varices using EUS-guided sclerotherapy with color Doppler. *Gastrointest Endosc* 2000;51:331-3.
- de Paulo GA, Ardengh JC, Nakao FS, et al. Treatment of esophageal varices: A randomized controlled trial comparing endoscopic sclerotherapy and EUS-guided sclerotherapy of esophageal collateral veins. *Gastrointest Endosc* 2006;63:396-402.
- Romero-Castro R, Pellicer-Bautista FJ, Jimenez-Saenz M, et al. EUS-guided injection of cyanoacrylate in perforating feeding veins in gastric varices: Results in 5 cases. *Gastrointest Endosc* 2007;66:402-7.
- Liao SC, Yang SS, Ko CW, et al. A miniature ultrasound probe is useful in reducing rebleeding after endoscopic cyanoacrylate injection for hemorrhagic gastric varices. *Scand J Gastroenterol* 2013;48:1347-53.
- Romero-Castro R, Ellrichmann M, Ortiz-Moyano C, et al. EUS-guided coil versus cyanoacrylate therapy for the treatment of gastric varices: A multicenter study (with videos). *Gastrointest Endosc* 2013;78:711-21.
- Lin MS, Liao SC, Peng YC, et al. Application of endoscopic US-guided tissue adhesive injection as a rescue therapy for post-tissue adhesive variceal obturation-related gastric wall bleeding. *Gastrointest Endosc* 2014;79:514-5.
- Binmoeller KF, Weilert F, Shah JN, et al. EUS-guided transesophageal treatment of gastric fundal varices with combined coiling and cyanoacrylate glue injection (with videos). *Gastrointest Endosc* 2011;74:1019-25.
- Buscaglia JM, Dray X, Shin EJ, et al. A new alternative for a transjugular intrahepatic portosystemic shunt: EUS-guided creation of an intrahepatic portosystemic shunt (with video). *Gastrointest Endosc* 2009;69:941-7.