

OPEN

Simplified, Readily Available Method for the Treatment of Band Keratopathy With Ethylenediaminetetraacetic Acid

Julio Narvaez, MD,*† Matthew Chang, BS,‡ Jeffrey Ing, MD,† Daniel De Chance,§ and Joshua J. Narvaez*

Purpose: To compare 3 methods for creating ethylenediaminetetraacetic acid (EDTA) solution using readily available Vacutainer tubes for the treatment of band keratopathy.

Methods: All 3 protocols used commercially available Vacutainer blood collection tubes coated with K₂EDTA. An osmometer was used to measure and compare the concentration of EDTA created using 3 different protocols. The time required for preparation of the solution was measured and compared to evaluate its efficiency for everyday clinical use. In addition, volume of EDTA solution obtained was measured for method 1. The most promising protocol for clinical use was then used for treatment of a series of patients.

Results: Average osmolarity was 532, 285, and 422 for methods 1, 2, and 3, respectively (ANOVA $P < 0.01$, all Tukey honestly significant difference $P < 0.01$). For the respective mixtures, average concentration was 65, 35, and 52 mg/mL, and average time to create solution was 189, 38, and 83 seconds (ANOVA $P < 0.01$, all Tukey honestly significant difference $P < 0.01$). The most promising, method 3, was found to be safe and effective in removing calcium from the corneal stroma in a series of 5 patients with 6 eyes treated. It also yielded 25% more solution for clinical use than method 1.

Conclusions: Method 3 using a single 10-mL Vacutainer tube with 18 mg of K₂-EDTA had the best balance of effective concentration of EDTA, time to preparation, and simplicity of methodology, when compared with previously published methods 1 and 2. It also yielded a greater final volume of solution.

Key Words: band keratopathy, EDTA, ethylenediaminetetraacetic acid, chelation, treatment

(*Cornea* 2021;40:1360–1362)

Calcific band keratopathy (CBK) is a degenerative condition of the cornea that primarily affects Bowman layer. Fine grayish-white calcium opacities form a horizontal band toward the central cornea and, as the condition progresses, can cause loss of vision and increased glare and result in corneal erosion-like symptoms and ulceration.¹ A variety of conditions increase susceptibility to CBK: corneal exposure, calcium-phosphate imbalance, alteration in tear osmolality, alkalosis, and chronic ocular inflammation.²

Ethylenediaminetetraacetic acid (EDTA) is the most widely used method of treating CBK.³ EDTA is a chelating agent that is commonly used as a food additive and in cosmetic products and can also be found in standard blood collection tubes where it is used as an anticoagulant. EDTA for ophthalmic use was originally derived from Na₂EDTA but that formulation has lost approval from the FDA and can now only be obtained at specially equipped compounding pharmacies. It is recommended to treat CBK with a 3% to 4% solution of disodium EDTA (concentration = 30–40 mg/mL).⁴

Lee et al⁵ proposed a novel and useful method of producing EDTA by dissolving the K₂EDTA lining found in blood collection tubes. Using this method, the authors discovered that, although effective, preparation was complex, relatively time consuming, and yielded only a small amount of useable solution due to transfer loss through 5 different tubes. This often necessitated repeating the process to obtain enough EDTA solution to treat a patient. We sought to create a protocol that created an EDTA solution of at least the currently accepted concentration that was easier and faster to create than the previously published protocol. We tested the method of Lee et al and 2 other methods of producing a solution of EDTA for treatment of CBK and found one that is significantly faster and simpler yet yields an effective concentration of EDTA with a larger volume to allow for multiple applications.

MATERIALS AND METHODS

We compared 3 methods of EDTA preparation. In method 1, outlined by Lee et al, 0.3 mL of sterile water was injected into a purple-topped 3-mL K₂EDTA Vacutainer blood collection tube (Becton, Dickinson and Company, Franklin

Received for publication September 8, 2020; revision received October 13, 2020; accepted November 2, 2020. Published online ahead of print December 21, 2020.

From the *Delta Eye Medical Group, Stockton, Lodi, and Tracy, CA; †Department of Ophthalmology, Loma Linda University, Loma Linda, CA; ‡Loma Linda University School of Medicine, Loma Linda, CA; and §Walla Walla University, College Place, WA.

The authors have no funding or conflicts of interest to disclose.

Supplemental digital content is available for this article. Direct URL citations appear in the printed text and are provided in the HTML and PDF versions of this article on the journal's Web site (www.corneajrnl.com).

Correspondence: Julio Narvaez, MD, Delta Eye Medical Group, 1617 St. Mark's Plaza, Suite D, Stockton, CA 95207 (e-mail: narvaezjd@gmail.com).

Copyright © 2020 The Author(s). Published by Wolters Kluwer Health, Inc. This is an open-access article distributed under the terms of the Creative Commons Attribution-Non Commercial-No Derivatives License 4.0 (CCBY-NC-ND), where it is permissible to download and share the work provided it is properly cited. The work cannot be changed in any way or used commercially without permission from the journal.

TABLE 1. Average Osmolarity With SD, Calculated Concentration, and Preparation Time With SD for 3 Methods of Creating “Off-the-Shelf” EDTA Solution, With Standard Treatment as Comparison

	Method 1	Method 2	Method 3	3% EDTA Solution
Mean osmolarity (\pm SD), mOsm/L	531.7 (\pm 34.3)	285.3 (\pm 86.7)	421.9 (\pm 67.4)	244.29
Concentration (mg/mL)*	65.3	35.04	51.81	30
Mean preparation time (\pm SD) (s)	188.7 (\pm 18.9)	38.4 (\pm 6.6)	83.1 (\pm 8.8)	

*Osmolarity was converted to concentration of EDTA in mg/mL using the equation: $\text{mOsm/L} \times 1/3 \times 368.42 \text{ mg/mmol} \times 1\text{L}/1000 \text{ mL}$.

Lakes, NJ) containing 5.4 mg of K_2EDTA . The diluent was swirled to dissolve the K_2EDTA coating the inside of the tube. The solution was then transferred from tube to tube, and the process was repeated for 5 tubes.⁵ The end solution volume was measured after repeating the process 5 different times.

In method 2, 0.3 mL of sterile water was injected into a single 10-mL K_2EDTA Vacutainer blood collection tube containing 18 mg of K_2EDTA was used (Becton, Dickinson and Company) and swirled to dissolve the K_2EDTA coating the inside of the tube. In method 3, the tube cap was removed, and 0.3 mL of sterile water was injected into the 10-mL K_2EDTA tube containing 18 mg of K_2EDTA , then a sterile, dry cotton-tipped applicator was used to absorb the fluid in the tube before then sweeping along the entire interior surface of the tube to dissolve the K_2EDTA coating the inside (see Video, Supplemental Digital Content 1, <http://links.lww.com/ICO/B153>, which demonstrates method 3). The end point was absence of a gritty sensation from the K_2EDTA salt as the cotton-tipped applicator rubbed and dissolved the EDTA.

Ten trials were repeated for each method. Osmolarity was measured with the Osmol Single-Sample Micro-Osmometer from Advanced Instruments (Norwood, MA). Residual fluid at the bottom of the tubes was sampled in all 3 methods. The preparation time for each of the 10 trials in the 3 different methods was also measured. The results were averaged within their respective method. Differences between the 3 methods were analyzed using ANOVA and Tukey honestly significant difference (HSD) tests from *astatsa.com* for post hoc analysis.

Method 3 had the best characteristics for clinical use, and it was used in a series of patients who gave informed consent for treatment of their band keratopathy. This study conformed to the ethical principles found in the Declaration of Helsinki.

RESULTS

Using method 1, the average osmolarity was 531.7 mOsm/L (SD = 34.3; calculated concentration: 65.30 mg/mL). The

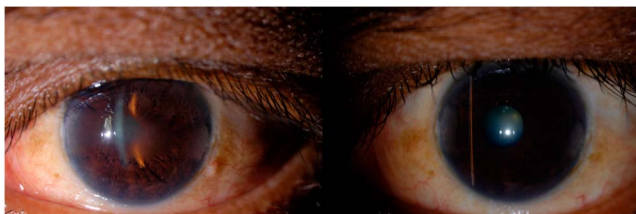


FIGURE 1. Photographs before (left) and after (right) treatment with EDTA derived from method 3. (The full color version of this figure is available at www.corneajrnl.com.)

preparation time took, on average, 188.7 seconds (SD = 18.9), and the average pH was 5.

Using method 2, the average preparation time was 38.4 seconds (SD = 6.6). The average osmolarity was 285.3 mOsm/L (SD = 86.7; calculated concentration 35.04 mg/mL), and the average pH was 4.25.

Using method 3, average preparation time was 83.1 seconds (SD = 8.8), and average osmolarity was 421.9 mOsm/L (SD = 67.4; calculated concentration 51.81 mg/mL); the average pH was 4.5. The results are summarized in the Table 1.

There were significant differences when comparing osmolarity [ANOVA $F(2,27) = 34.5$, $P < 0.01$; Tukey HSD, all $P < 0.01$] and preparation time (ANOVA $F(2,27) = 374.6$, $P < 0.01$; Tukey HSD, all $P < 0.01$) between the 3 methods. We found clinically significant differences in preparation time between methods 1 and 3, but no clinically significant differences in concentration between methods 1 and 3.

Method 1 had an average yield of 0.24 mL of solution. Method 3 had, on average, 25% more volume for clinical use than method 1.

All patients treated with method 3 experienced no complications, and no delayed healing. Figure 1 shows photographs of 1 patient before and after treatment with EDTA produced with method 3. Uncorrected visual acuity before and after chelation therapy for our series of patients is summarized in Table 2.

DISCUSSION

K_2EDTA has been shown to be an effective alternative to Na_2EDTA , which is both expensive and inconvenient to obtain. It is also cost-effective and widely available. At the time of writing, we found that the average cost of an ophthalmic preparation of Na_2EDTA was \$117 (range \$70–\$195), whereas 10-mL blood collection tubes cost \$35.99 to \$46.99 per 100 tubes.

Method 1 for producing K_2EDTA as outlined by Lee et al took a substantial amount of time and had the greatest complexity. It had the highest concentration solution but less volume for use. Method 2 was the fastest to prepare but yielded the lowest concentration of K_2EDTA . Method 3 struck a good balance with a greatly reduced the preparation time, greater simplicity of preparation, while achieving a higher concentration of EDTA than that commonly used to treat CBK (3%–4% disodium EDTA with concentration of 30–40 mg/mL).⁴ Method 3 also yielded greater volumes of solution than that by method 1, because method 1 requires transfer of fluid between 5 different vials, and residual fluid remains in the walls of the vials after transfer that cannot be

TABLE 2. Visual Acuity Before and After EDTA Chelation for Band Keratopathy With Patients' Age, Sex, and Diagnoses

Patient Demographic, Age/Sex	Eye Affected	Preoperative Visual Acuity	Postoperative Visual Acuity	Diagnosis
77/Female	OS	Light perception	Counting finger	CRVO
63/Female	OD	Light perception	Light perception	Dense cataract
49/Male	OU	Count finger OU	20/100 OD, 20/80 OS	Stage V CKD, T1DM
85/Male	OD	Count finger	Count finger	S/p corneal transplant
77/Female	OS	20/40	20/40	Keratoconjunctivitis sicca, glaucoma

CKD, chronic kidney disease; CRVO, central retinal vein occlusion; s/p, status post; T1DM, type 1 diabetes mellitus.

retrieved. Method 3, most importantly, had good clinical efficacy. We found its clinical effectiveness indistinguishable from our previous clinical experience with method 1, and our impression is that both methods 1 and 3 are considerably faster in removing CBK than using the standard compounded 3% EDTA.

ACKNOWLEDGMENTS

The authors wish to acknowledge Roberta Pearce, CLS (ASCP), Chemistry Supervisor and POC Coordinator at Dignity Health, St. Joseph's Medical Center, for allowing use of the osmometer for this study.

REFERENCES

1. Al-Hity A, Ramaesh K, Lockington D. EDTA chelation for symptomatic band keratopathy: results and recurrence. *Eye (Lond)*. 2018;32:26–31.
2. Jhanji V, Rapuano CJ, Vajpayee RB. Corneal calcific band keratopathy. *Curr Opin Ophthalmol*. 2011;22:283–289.
3. Bokosky JE, Meyer RF, Sugar A. Surgical treatment of calcific band keratopathy. *Ophthalmic Surg*. 1985;16:645–647.
4. Bagheri N, Wajda BN; Wills Eye Hospital (Philadelphia, PA). Chapter 4 cornea: 4.10 band keratopathy. In: *The Wills Eye Manual: Office and Emergency Room Diagnosis and Treatment of Eye Disease*. 7th ed. Philadelphia, PA: Lippincott Williams and Wilkins; 2017: 64–65.446.
5. Lee ME, Ouano DP, Shapiro B, et al. “Off-the-Shelf” K2-EDTA for calcific band keratopathy. *Cornea*. 2018;37:916–918.