

ORIGINAL ARTICLE

Post-operative Rehabilitation of Atypical Femoral Fracture in a Single Center

Yasuhiko Mizutani, MD^a Hiroshi Horiuchi, MD, PhD^{a,b} Yoshiyuki Nakamura, MD^a
Masataka Mochizuki, MD^a Yoshiyuki Kotoda, MD^a Tsuyoshi Toyata, MD^a
Taketomo Ozaki, MD^a and Tsutomu Takizawa, MD, PhD^a

Objective: Increasing numbers of reports have described atypical femoral fracture (AFF) in patients being treated with oral bone resorption inhibitors, such as bisphosphonates. Most AFF patients undergo surgical treatment. However, there is little information about post-operative rehabilitation and patient activity levels after surgery for such fractures. Here we report the outcome of surgical treatment and postoperative rehabilitation for AFF at a single center in Japan. **Methods:** We retrospectively reviewed 13 patients (14 AFFs) who underwent surgery at Nagano Matsushiro General Hospital between January 2013 and December 2016. The clinical backgrounds of the patients were evaluated. **Results:** The patients comprised 1 man (1 AFF) and 12 women (13 AFFs). The mean age at surgery was 77.7±7.1 years (mean±SD). Before AFF occurred, 12 of the 13 patients had used bisphosphonates for osteoporosis. An intramedullary nail was inserted in all patients. Partial weight bearing was started on average 2 weeks after surgery, and full weight-bearing gait was permitted on average 3 weeks after surgery. The average time to bone union was 9.9±6.1 months, ranging from 3 to 23 months. None of the patients required additional surgical procedures, including revision surgery for pseudoarthrosis (nonunion) or delayed union. Before AFF, 12 patients walked independently, and 1 patient walked with a single cane. At the final follow-up (mean duration: 34.5±15.7 months), 8 patients could walk independently and 5 patients walked with a single cane. **Conclusions:** We recognized that rigid fixation for AFF supported early weight-bearing gait after surgery.

Key words: atypical femoral fracture; bisphosphonates; post-operative rehabilitation; surgical treatment

INTRODUCTION

Bisphosphonates (BPs) are often used as first-line treatment for osteoporosis. These agents are known to inhibit bone resorption and prevent fractures of the vertebral bodies and the proximal femur in postmenopausal women.¹⁻⁴ However, there have been increasing numbers of reports of atypical femoral fracture (AFF) in patients taking oral bone resorption inhibitors such as BPs. Although AFF can occur in patients who have never been treated with BPs, prolonged

use of these agents is known to increase the risk of AFF; moreover, discontinuation of BPs reduces the risk of AFF.⁵ Histological examination of patients with AFF has shown that long-term administration of bone resorption inhibitors induces a low bone-turnover state.⁶ AFF often occurs as a result of minor trauma in patients with such a bone state. AFF has characteristic imaging findings, presenting as a simple transverse fracture (which is rare in traumatic femoral fractures) associated with a unicortical beak and cortical hypertrophy.⁷ Additional anatomical risk factors for AFF

Received: December 18, 2019, Accepted: March 30, 2020, Published online: April 14, 2020

^a Department of Orthopaedic Surgery, Nagano Matsushiro General Hospital, Nagano, Japan

^b Department of Rehabilitation Medicine, Shinshu University Hospital, Matsumoto, Japan

Correspondence: Hiroshi Horiuchi, MD, PhD, 183 Matsushiro, Matsushiro-Machi, Nagano 381-1231, Japan, Email: horiuchih@shins-hu-u.ac.jp

Copyright © 2020 The Japanese Association of Rehabilitation Medicine



This is an open-access article distributed under the terms of the Creative Commons Attribution Non-Commercial No Derivatives (CC BY-NC-ND) 4.0 License. <http://creativecommons.org/licenses/by-nc-nd/4.0/>

have been identified, such as excessive bowing deformity of the femur.⁸⁾ While accurate diagnosis is important for understanding the etiology and/or pathology of AFF, historically, the definition of this fracture was not clear. However, there is currently consensus that the task force report of the American Society for Bone and Mineral Research (ASBMR)⁹⁾ provides useful diagnostic criteria for AFF. Therefore, it is now possible to accurately evaluate the etiology and clinical outcomes of AFF.

Bone union is often difficult to achieve in patients with AFF because conditions are not favorable for fracture healing. One factor is that long-term bisphosphonate therapy causes low bone turnover and decreases intrinsic bone strength.⁶⁾ Even if surgical treatment is performed, the nonunion rate is high compared to that for ordinary proximal femoral fractures and femoral shaft fractures.¹⁰⁾

Because AFF is uncommon, few multicenter studies on this fracture have been published, especially with regard to treatment outcomes. Moreover, the operative procedures employed to treat AFF show wide variation, which limits the usefulness of multicenter studies for assessing surgical outcomes and postoperative rehabilitation. Furthermore, there have been few reports about AFF in Asian patients based on the ASBMR task force definition. To the best of our knowledge, there is no previous report that describes postoperative rehabilitation and patient activity after surgical treatment for AFF. Consequently, we performed a retrospective investigation of the surgical outcomes and rehabilitation in patients with AFF diagnosed according to the ASBMR task force definition and treated at a single center in Japan.

PATIENTS AND METHODS

The medical records of patients with AFF who underwent surgery at our hospital between January 2013 and December 2016 were reviewed. Patients with femoral fracture were identified, excluding those with femoral neck fracture, trochanteric fracture, pathological fracture, and peri-prosthetic fracture. Patients were then selected if their fractures met the ASBMR Task Force 2013 Revised Case Definition of AFF (i.e., the fracture must be located along the femoral diaphysis from just distal to the lesser trochanter to just proximal to the supracondylar flare). Furthermore, four or more of the following five major features were met by each patient: (1) The fracture was associated with minimal or no trauma, such as a fall from standing height or less. (2) The fracture line originated at the lateral cortex and was substantially transverse in orientation, although it could become oblique as it progressed

medially across the femur. (3) If the fracture was complete, it extended through both cortices and could be associated with a medial spike; incomplete fractures involved the lateral cortex only. (4) There was minimal or no comminution of the fracture. (5) There was localized periosteal or endosteal thickening of the lateral cortex at the fracture site (i.e., so called “beak” or “flare”). The following minor features were not required for diagnosis, but may be associated with AFF: (1) generalized increase of cortical thickness at the femoral diaphysis, (2) unilateral or bilateral prodromal symptoms such as dull or aching pain in the groin or thigh, (3) bilateral or complete fracture of the femoral diaphysis, and (4) delayed healing of the fracture. The diagnosis of AFF was made by two orthopedic surgeons (YM and HH), who independently performed evaluation of the radiographic findings. AFF was diagnosed when both surgeons considered that the fracture conformed to the ASBMR criteria.

We recognized that AFF, including incomplete fracture, is indicated for surgical treatment and immediately performed surgery. The post-operative rehabilitation program was as follows. The patients were allowed to undertake non-weight-bearing gait from the day after surgery. With reference to radiographical evaluation, 10-kg weight bearing was allowed 2 weeks after surgery. From 4 weeks after surgery, full weight bearing was started. Weight bearing was delayed if the gap between fragments after surgery was comparatively large; alternatively, weight bearing could be brought forward if the patient's condition permitted (e.g., the opposite sides of the femur had radiolucency on the lateral cortex). The following information was obtained from the medical records and imaging files: medications prescribed for the treatment of osteoporosis and the duration of use before AFF, the surgical methods employed to treat AFF, the implant used, postoperative rehabilitation (e.g., the timing of weight bearing), the presence/absence of bone union, the time to achieve bone union, and the activities of daily life at the final follow-up. All patients attended the orthopedic outpatient clinic of our hospital every 1–3 months after surgery and underwent standard postoperative examinations, including imaging studies. Bone union was considered to have been achieved when formation of new bone over the fracture line was confirmed on frontal and lateral plain X-ray films. The evaluation of postoperative imaging findings was also performed independently by two orthopedic surgeons (YM and HH), both of whom judged the timing of bone union (if they disagreed, the later time of union was accepted).

The patient and/or the patient's family were informed that data from the case would be submitted for publication; all

Table 1. Patient demographic profiles

Age (years)	77.1±7.2
Sex (male/female)	1/12 (7.7%/92.3%)
Medications	
Bisphosphonate	12 (92.3%)
Duration of bisphosphonate therapy (years)	7.8±5.4
Vitamin D analog	6 (46.2%)
Glucocorticoid	1 (7.7%)
Proton pump inhibitor	3 (23.1%)
Collagen disease	0 (0%)
Diabetes mellitus	0 (0%)

gave consent. This study was approved by the ethics committee of our hospital.

RESULTS

Between January 2013 and December 2016, 67 patients with 68 femoral fractures underwent surgery at our hospital, excluding those with femoral neck, trochanteric, pathological, and peri-prosthetic fractures. The fracture was subtrochanteric in 38 patients (38 fractures), whereas the fracture affected the femoral shaft in 21 patients (22 fractures) and was supracondylar in 8 patients (8 fractures). Among these 67 patients, AFF was confirmed in 13 (14 AFFs: 14/68, 20.6%). These patients included 1 man (1 AFF) and 12 women (13 AFFs) with a mean age of 77.7±7.1 years (mean±SD) at operation. The demographic features of the patients are shown in **Table 1**. Among the patients with AFF, the fracture was located in the femoral shaft in 12 patients (13 AFFs), whereas it was subtrochanteric in 1 patient (1 AFF).

Twelve of the 13 patients with AFF had received BP therapy (alendronate, risedronate, or minodronate) for osteoporosis before the fracture occurred. One of these patients had previously developed multiple compression fractures while on oral risedronate and had been switched to teriparatide for 2 years followed by oral minodronate therapy. The duration of BP therapy for osteoporosis prior to AFF was determined as precisely as possible from the medical records and referral letters from other hospitals. It was ≥3 years to <5 years in four patients, ≥5 years in four patients, and unknown in four patients.

Table 2 lists the patients with AFF. In case 3, the patient also separately developed a fracture on the opposite side, so descriptions are provided for both fractures. In case 8, AFF was incomplete. There was no fracture line on plain X-ray films, but signal changes were noted on magnetic

resonance imaging. Because the patient complained of pain at the site corresponding to these changes, impending AFF was diagnosed and surgery was performed. In all patients, an antegrade intramedullary nail was inserted to treat the AFF. The implants used are described in **Table 2**. There were no iatrogenic fractures during surgery. The post-operative rehabilitation schedule was as described in Patients and Methods. In case 8 (incomplete fracture) and case 13, patients were allowed full weight bearing on the day after surgery because reduction and fixation were recognized as ideal. Partial weight bearing was started after an average of 2 weeks (mean±SD, 13.1±10.3 days; range, 1–28 days), and full weight bearing was permitted after an average of 3 weeks (22.5±15.8 days, 1–48 days). All AFF patients could perform partial weight bearing on the day that it was permitted. Full weight bearing was either undertaken on the day it was permitted or on the following day.

In the follow-up period, there was no medullary nail breakage, although breakage of an interlocking screw was seen in one patient 3 months postoperatively. Bone union was achieved after only 3 months in some patients, but the time required for union varied widely, and it took 23 months in one patient. The mean time to bone union was 9.9±6.1 months. None of the 13 AFF patients required additional surgery, including revision surgery for nonunion or delayed union. Eight AFF patients received teriparatide after surgery, and low-intensity pulsed ultrasound (LIPUS) was performed on four AFF patients (**Table 3**).

Before injury, 12 patients could walk independently, and 1 patient walked with a single cane in our series. At the final follow-up (mean: 34.5±15.7 months), eight patients could walk independently and five patients walked with a single cane. Nine patients regained their original walking level, whereas, four patients required a cane after surgery. No patients required a wheelchair or a walker in the present study.

Table 2. Characteristics and clinical data of patients with AFFs

Case	Sex	Age (years)	ASBMR case definition	Pre-fracture BP	Duration of BP	GCs	PPI	Location	Implants	PWB (days)	FWB (days)	LIPUS	Union (months)	Pre-fracture ambulation	Ambulation (last follow-up)
1	F	63	All major 1 minor	ALN	Unknown	-	-	FS	T2GTN	11	18	-	4	Independent	Independent
2	M	70	All major 2 minor	-	-	-	-	FS	T2GTN	12	26	-	21	Independent	Independent
3	F	83	All major 3 minor	ALN	8Y	-	-	FS	T2GTN	6	21	-	15	Independent	Single t-cane
4	F	74	All major 1 minor	RIS	3Y or more	-	LPZ	FS	TAN	27	48	-	7	Independent	Independent
3	F	85	All major 2 minor	ALN	8Y	-	-	FS	T2GTN	18	32	-	3	Independent	Single t-cane
5	F	77	All major 2 minor	ALN	Unknown	-	-	FS	TAN	1	14	-	13	Independent	Independent
6	F	76	All major 1 minor	RIS	6Y	PSL 3 mg	OMZ	FS	Gamma3	20	34	-	7	Independent	Independent
7	F	73	All major 2 minor	ALN	4Y	-	-	FS	T2GTN	12	26	-	23	Independent	Single t-cane
8	F	73	All major 3 minor	ALN	3Y or more	-	-	FS	T2GTN	1	1	-	*	Independent	Independent
9	F	89	All major 2 minor	MIN	5Y or more	-	-	FS	Gamma3	14	14	+	9	Single t-cane	Single t-cane
10	F	83	All major 2 minor	MIN	Unknown	-	-	FS	TFNA	28	28	+	11	Independent	Single t-cane
11	F	74	All major 1 minor	ALN	4Y	-	-	FS	TFNA	28	48	+	4	Independent	Independent
12	F	83	All major 1 minor	ALN	17Y	-	-	ST	TFNA	4	4	-	4	Independent	Independent
13	F	85	4 major 2 minor	RIS	Unknown	-	EMZ	FS	TFNA	1	1	+	7	Independent	Single t-cane

ALN: alendronate, RIS: risedronate, MIN: minodronate, GCs: glucocorticoids, PSL: prednisolone, PPI: proton pump inhibitor, LPZ: lansoprazole, OMZ: omeprazole, EMZ: esomeprazole, FS: femoral shaft, ST: subtrochanteric, PWB: partial weight bearing, FWB: full weight bearing, LIPUS: low-intensity pulsed ultrasound, T2GTN: T2 Greater Trochanter Entry Femoral Nailing System, Stryker, TAN: TRIGEN Trochanteric Antegrade Nail, Smith & Nephew, Gamma3: Gamma 3 Long Nail, Stryker, TFNA: TFN Advanced Proximal Femoral Nailing System, Depuy & Synthes.

* Case 8 had incomplete fracture.

Table 3. Postoperative outcomes

Time to partial weight bearing (days)	14.1±10.3
Time to full weight bearing (days)	22.5±15.8
Mean time to radiological union (months)	9.9±6.1
Postoperative use of teriparatide (patients)	8 (66.7%)
Postoperative use of low-intensity pulsed ultrasound	4 (31.0%)

CASE PRESENTATION (CASE 1)

A 63-year-old woman who had been on oral alendronate therapy (prescribed by another clinic) for an unknown duration developed a fracture of the right femoral shaft after a simple fall. There was no history of steroid or proton pump inhibitor use. Radiographs revealed a transverse fracture of the right femur with a medial/posterior spike (Fig. 1a,b). Closed reduction and internal fixation with an antegrade femoral nail were performed. Partial weight bearing was started after 11 days, and full weight bearing was permitted and actually started after 18 days and 24 days, respectively. Complete bone union was achieved at 4 months after surgery (Fig. 1c-f). At 4.5 years postoperatively, the patient has no restriction of daily activities, including walking.

DISCUSSION

This retrospective study investigated the clinical results and patient activity after surgical treatment for AFF. To the best of our knowledge, this is the first report that reviews in detail the post-operative rehabilitation for AFF. We recognize that a single-center study, rather than a multi-center study, is more appropriate for these analyses.

We evaluated the surgical outcomes of 13 Japanese patients with 14 AFFs treated at a single center. All 14 fractures were treated with an intramedullary nail, and there was no nonunion or requirement for additional/revision surgery. During post-operative rehabilitation, patients were allowed to undergo partial weight-bearing on average 13.1 days postoperatively, and full weight-bearing gait was allowed on average 22.5 days after surgery. Among patients with femoral fracture other than AFF (54 patients with 54 fractures), partial weight bearing was started after an average of 2 weeks (17.1±15.6 days, range 1–70 days), and full weight bearing was permitted after an average of 4 weeks (28.3±22.2 days, range 1–90 days). There was no significant difference in the time to weight bearing between AFF and femoral fracture other than AFF. During the study period, no revision surgery was required in AFF or non-AFF fracture patients in our

hospital. These results indicated that, if rigid fixation was required, AFF patients could receive the same rehabilitation program as non-AFF femoral fracture patients. Nine AFF patients regained the same walking ability as before the injury. However, for four AFF patients, gait ability declined from walking without a cane to walking with a cane.

A single-center study of 109 AFFs was performed in Korea.¹¹⁾ Bone union was achieved within 6 months in 76 AFFs (69.7% of the fractures), whereas there was nonunion in six AFFs (two patients underwent revision surgery and four declined further surgery). In the present study, bone union was achieved within 6 months in 3 of 13 AFFs (excluding case 8 with an incomplete fracture), so the rate was slightly lower at 31%. However, none of the patients ultimately had nonunion or required revision surgery. According to a report from Singapore,¹²⁾ 10 of 30 patients (33%) with AFF treated at a single center required revision surgery, and implant failure occurred in 6 fractures (20%). Prasarn et al.¹³⁾ treated 25 BP-related fractures and reported intraoperative fracture in 5 (20%) and postoperative implant failure in 3 (12%). Another study reported implant failure in 2 of 12 alendronate-related subtrochanteric fractures.¹⁴⁾ However, these articles did not describe the post-operative rehabilitation protocol in detail. In the present series, there were no iatrogenic fractures during surgery, and implant failure (breakage of an interlocking screw) affected only one AFF. Recently, Koh performed a systematic review of AFF by analyzing treatment outcomes for 733 patients (834 fractures) aged from 35 to 93 years with complete or incomplete AFF.¹⁵⁾ There were 632 limbs with complete fracture, including 182 limbs with subtrochanteric fracture, 172 limbs with shaft fracture, and 278 limbs with no details of the fracture site. The mean time to bone union was 7.3 months (range, 2–31 months). Intramedullary nailing was considered to be superior to plate fixation, based on its biomechanical and biological advantages. We used intramedullary nails in all our AFF patients, expecting superior fixation compared to plates, and achieved favorable outcomes. Many of our patients had marked femoral bowing; therefore, it is also likely that the selection and use of suitable implants for a curved femur based on preoperative templates improved the

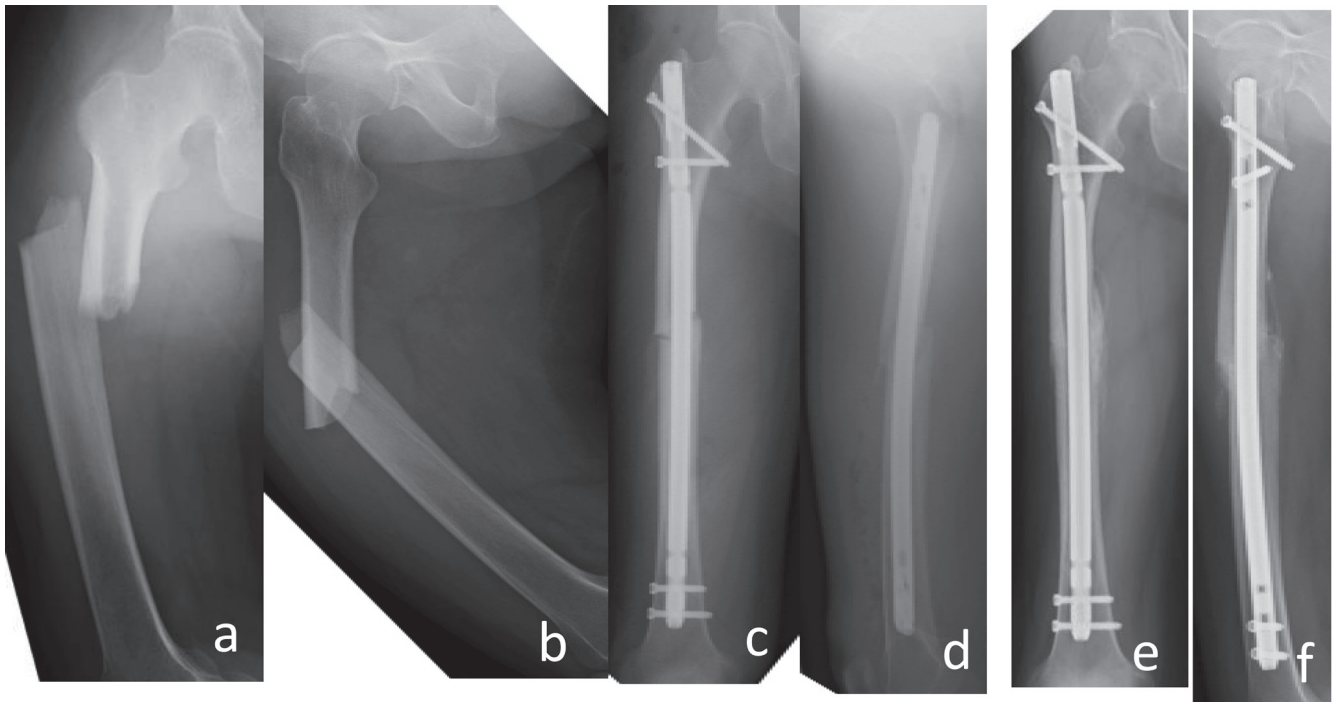


Fig. 1. The patient in case 1 was a 63-year-old woman. Antero-posterior (a) and lateral (b) X-rays of the right femur at injury showed a transverse fracture with a medial/posterior spike. Antero-posterior (c) and lateral (d) X-rays of the right femur just after surgery. Antero-posterior (e) and lateral (f) X-rays of the right femur at 4 months after surgery, showing complete bony union.

outcomes. We believe that rigid fixation for AFF supports early weight-bearing gait after surgery.

A report on 3150 femoral fractures over a 5-year period at a major trauma center in the United Kingdom identified only 10 AFFs (0.32%).¹⁶⁾ After excluding fractures of the femoral neck (including periprosthetic and pathological fractures), the 10 AFFs accounted for 1.1% of 872 femoral fractures. Seven of the 10 AFF patients had a history of exposure to BPs. In a study performed over a 6-year period at six centers in Japan,¹⁷⁾ 2238 hip and femoral shaft fractures were treated, including 14 AFFs (0.63%). Among 402 limbs with femoral subtrochanteric fractures and femoral shaft fractures, the 14 AFFs accounted for 3.5%. In the present series, the frequency of AFF was relatively high, accounting for 14 of 67 limbs (21%) with subtrochanteric or femoral shaft fractures. This difference could partly be due to the patient mix, because our hospital does not have a full-scale emergency department and accepts a relatively small number of patients with multiple trauma or high-energy trauma. Furthermore, we speculate that this difference might be because the proportion of elderly people is high in our medical catchment area, and many elderly people receive osteoporosis treatment with

BPs. However, we recognize that further study is necessary to clarify the reason.

While AFF can occur in patients who have never used BPs, it has been reported that long-term BP therapy increases the risk of this fracture and that discontinuation of these drugs decreases the risk.⁵⁾ Koh et al. reported that 291 of 733 patients were prescribed BPs before AFF occurred, and the cause of fracture was severe suppression of bone turnover resulting from long-term BP use.¹⁵⁾ In the above-mentioned six-center Japanese study,¹⁷⁾ nine of ten patients had a history of BP use, with a mean duration of 4.9 years (four patients had used BPs for 3–5 years, and five patients had used them for ≥ 5 years). A study performed at 11 centers in Japan¹⁸⁾ found a history of BP use in 31 of 34 AFF patients (91.2%), with a mean treatment duration of 5.1 years. In the present series, 12 of 13 AFF patients (92.3%) had a history of BP use. However, similar to other reports, 1 of the 13 patients who developed AFF had no history of BP use. Other possible risk factors reported for AFF include lateral bowing of the femur,⁸⁾ diabetes and glucocorticoids,¹⁸⁾ and proton pump inhibitors,¹⁹⁾ but none of these factors applied to our patient who had not used BP. Moreover, age, height, and body weight

are reportedly associated with the fracture site.¹⁸⁾ However, most of our AFF patients (13 of 14, 92.9%) had femoral shaft fracture. Because only one patient had a subtrochanteric fracture and there was no supracondylar fracture in this series, we were not able to evaluate the association between the fracture site and these patient factors.

Recently, lateral bowing of the femur and vitamin D deficiency²⁰⁾ have been found to affect the occurrence of AFF. Naturally, the bowing of the femur affected the choice of the intramedullary nail. Unfortunately, we did not examine the serum vitamin D levels in this series. However, we recognize that neither the bowing of the femur nor vitamin D deficiency influenced the clinical results in this series because the rehabilitation protocol was decided without considering the shape of the femur or vitamin D levels.

Whether prophylactic surgery should be performed for incomplete fractures remains controversial. Saleh et al. performed conservative treatment for 14 symptomatic incomplete AFFs (9 with a radiolucent line and 5 without a radiolucent line).²¹⁾ They reported that daily administration of teriparatide led to clinical and radiographic bone union in 2 of 9 fractures with a radiolucent line and in all 5 fractures without a radiolucent line. The other 7 fractures with a radiolucent line did not heal and were managed by prophylactic surgery. Ha et al.²²⁾ reported that displacement occurred and required surgery in 5 of 14 incomplete AFFs, and another 5 incomplete AFFs were also treated surgically because of intractable pain. The remaining 4 AFFs (with persistent pain) failed to achieve radiographic bone union. They concluded that prophylactic fixation of incomplete AFFs was warranted when such fractures are identified. Banffy et al.²³⁾ treated six patients with incomplete AFFs by discontinuation of BP therapy and non-weight bearing. While one incomplete AFF achieved bone union, the remaining five progressed to complete fracture and required surgical treatment. Based on these results, they recommended surgical treatment for incomplete AFF. Egol et al.²⁴⁾ treated 21 of 43 incomplete AFFs with surgery and managed the remaining 22 incomplete AFFs with non-weight bearing. As a result, 81% of the surgically treated AFFs became pain free and all 21 fractures healed. In contrast, 64% of the fractures treated with non-weight bearing became pain free and only 18% achieved bone union after an average of 11 months. They concluded that patients should be counseled regarding the potential benefits of prophylactic surgery for incomplete AFF. In case 8 in the present series, we recognized that, although the patient had incomplete AFF, complete fracture was imminent based on pain at the affected site. As a result, we performed

surgery after providing a detailed explanation and obtaining the patient's consent. The patient was able to walk with full weight bearing from the day after surgery and she then went on to walk without cane. She was able to regain the level of activity she had before the injury.

We prescribed LIPUS and/or teriparatide for AFF patients who were recognized as being at high risk of delayed bony union. However, it is still controversial whether LIPUS and teriparatide should be used after internal fixation in AFF patients. Further clinical study is required to clarify the applicability of these treatments.

This study had several limitations. First, it was a single-center study, and statistical analysis could not be performed because the sample size was small. However, although one systematic review has analyzed several hundred articles relating to AFF,¹⁵⁾ a previous multicenter study reported 38 AFFs,¹⁸⁾ suggesting that 14 AFFs is reasonable for a single center. Second, medical records were incomplete for patients who were referred to our hospital, which meant that we could not determine the exact duration of treatment with BPs and bone resorption inhibitors. Third, while postoperative management (e.g., the timing of weight bearing) was performed according to the same protocol, the use of LIPUS was not uniform in this series. However, the advantages of this single-center observational study included a nearly uniform treatment policy and the ability to perform detailed postoperative follow-up of the patients.

In conclusion, we evaluated the clinical results of surgical treatment and post-operative rehabilitation in 13 Japanese patients with 14 AFFs from a single center. Twelve of the 13 patients had a history of BP use, strongly suggesting an association between AFF and BP therapy, as has been reported previously.^{5,25,26)} All patients underwent surgery using an intramedullary nail. Partial weight bearing was allowed on average 13.1 days postoperatively, and full weight-bearing gait was allowed on average 22.5 days after surgery. We established that, if rigid fixation was required, AFF patients could follow the same rehabilitation schedule as patients with non-AFF femoral fracture. Detailed postoperative follow-up revealed that none of the patients required further surgery for nonunion or other complications. Intramedullary nailing seems to be a reasonable first-line surgical procedure for AFF from the biomechanical perspective.

CONFLICTS OF INTEREST

We have no conflicts of interest to declare.

REFERENCES

1. Wells GA, Cranney A, Peterson J, Boucher M, Shea B, Welch V, Coyle D, Tugwell P: Etidronate for the primary and secondary prevention of osteoporotic fractures in postmenopausal women. *Cochrane Database Syst Rev* 2008;CD003376. DOI:10.1002/14651858.CD003376.pub3, PMID:18254018
2. Wells GA, Cranney A, Peterson J, Boucher M, Shea B, Welch V, Coyle D, Tugwell P: Alendronate for the primary and secondary prevention of osteoporotic fractures in postmenopausal women. *Cochrane Database Syst Rev* 2008;CD001155. DOI:10.1002/14651858.CD001155.pub2, PMID:18253985
3. Wells GA, Cranney A, Peterson J, Boucher M, Shea B, Welch V, Coyle D, Tugwell P: Risedronate for the primary and secondary prevention of osteoporotic fractures in postmenopausal women. *Cochrane Database Syst Rev* 2008;CD004523. DOI:10.1002/14651858.CD004523.pub3, PMID:18254053
4. Matsumoto T, Hagino H, Shiraki M, Fukunaga M, Nakano T, Takaoka K, Morii H, Ohashi Y, Nakamura T: Effect of daily oral minodronate on vertebral fractures in Japanese postmenopausal women with established osteoporosis: a randomized placebo-controlled double-blind study. *Osteoporos Int* 2009;20:1429–1437. DOI:10.1007/s00198-008-0816-7, PMID:19101754
5. Schilcher J, Michaëlsson K, Aspenberg P: Bisphosphonate use and atypical fractures of the femoral shaft. *N Engl J Med* 2011;364:1728–1737. DOI:10.1056/NEJMoa1010650, PMID:21542743
6. Lloyd AA, Gludovatz B, Riedel C, Luengo EA, Saiyed R, Marty E, Lorich DG, Lane JM, Ritchie RO, Busse B, Donnelly E: Atypical fracture with long-term bisphosphonate therapy is associated with altered cortical composition and reduced fracture resistance. *Proc Natl Acad Sci USA* 2017;114:8722–8727. DOI:10.1073/pnas.1704460114, PMID:28760963
7. Kwek EB, Goh SK, Koh JS, Png MA, Howe TS: An emerging pattern of subtrochanteric stress fractures: a long-term complication of alendronate therapy? *Injury* 2008;39:224–231. DOI:10.1016/j.injury.2007.08.036, PMID:18222447
8. Sasaki S, Miyakoshi N, Hongo M, Kasukawa Y, Shimada Y: Low-energy diaphyseal femoral fractures associated with bisphosphonate use and severe curved femur: a case series. *J Bone Miner Metab* 2012;30:561–567. DOI:10.1007/s00774-012-0358-0, PMID:22610061
9. Shane E, Burr D, Abrahamsen B, Adler RA, Brown TD, Cheung AM, Cosman F, Curtis JR, Dell R, Dempster DW, Ebeling PR, Einhorn TA, Genant HK, Geusens P, Klaushofer K, Lane JM, McKiernan F, McKinney R, Ng A, Nieves J, O’Keefe R, Papapoulos S, Howe TS, van der Meulen MC, Weinstein RS, Whyte MP: Atypical subtrochanteric and diaphyseal femoral fractures: second report of a task force of the American Society for Bone and Mineral Research. *J Bone Miner Res* 2014;29:1–23. DOI:10.1002/jbmr.1998, PMID:23712442
10. Odvina CV, Zerwekh JE, Rao DS, Maalouf N, Gottschalk FA, Pak CY: Severely suppressed bone turnover: a potential complication of alendronate therapy. *J Clin Endocrinol Metab* 2005;90:1294–1301. DOI:10.1210/jc.2004-0952, PMID:15598694
11. Lim HS, Kim CK, Park YS, Moon YW, Lim SJ, Kim SM: Factors associated with increased healing time in complete femoral fractures after long-term bisphosphonate therapy. *J Bone Joint Surg Am* 2016;98:1978–1987. DOI:10.2106/JBJS.15.01422, PMID:27926679
12. Teo BJ, Koh JS, Goh SK, Png MA, Chua DT, Howe TS: Post-operative outcomes of atypical femoral subtrochanteric fracture in patients on bisphosphonate therapy. *Bone Joint J* 2014;96-B:658–664. DOI:10.1302/0301-620X.96B5.32887, PMID:24788502
13. Prasarn ML, Ahn J, Helfet DL, Lane JM, Lorich DG: Bisphosphonate-associated femur fractures have high complication rates with operative fixation. *Clin Orthop Relat Res* 2012;470:2295–2301. DOI:10.1007/s11999-012-2412-6, PMID:22669553
14. Das De S, Setiobudi T, Shen L, Das De S: A rational approach to management of alendronate-related subtrochanteric fractures. *J Bone Joint Surg Br* 2010;92-B:679–686. DOI:10.1302/0301-620X.92B5.22941, PMID:20436006
15. Koh A, Guerado E, Giannoudis PV: Atypical femoral fractures related to bisphosphonate treatment. *Bone Joint J* 2017;99-B:295–302. DOI:10.1302/0301-620X.99B3.BJJ-2016-0276.R2, PMID:28249967
16. Eisenstein N, Kasavkar G, Bhavsar D, Khan FS, Paskins Z: Incidence and medical management of bisphosphonate-associated atypical femoral fractures in a major trauma centre: a retrospective observational study. *BMC Musculoskelet Disord* 2017;18:29. DOI:10.1186/s12891-017-1392-9, PMID:28114975

17. Saita Y, Ishijima M, Mogami A, Kubota M, Baba T, Kaketa T, Nagao M, Sakamoto Y, Sakai K, Homma Y, Kato R, Nagura N, Miyagawa K, Wada T, Liu L, Matsuoka J, Obayashi O, Shitoto K, Nozawa M, Kajihara H, Gen H, Kaneko K: The incidence of and risk factors for developing atypical femoral fractures in Japan. *J Bone Miner Metab* 2015;33:311–318. DOI:10.1007/s00774-014-0591-9, PMID:24852205
18. Hyodo K, Nishino T, Kamada H, Nozawa D, Mishima H, Yamazaki M: Location of fractures and the characteristics of patients with atypical femoral fractures: analyses of 38 Japanese cases. *J Bone Miner Metab* 2017;35:209–214. DOI:10.1007/s00774-016-0747-x, PMID:27026435
19. Giusti A, Hamdy NA, Papapoulos SE: Atypical fractures of the femur and bisphosphonate therapy. *Bone* 2010;47:169–180. DOI:10.1016/j.bone.2010.05.019, PMID:20493982
20. Girgis CM, Sher D, Seibel MJ: Atypical femoral fractures and bisphosphonate use. *N Engl J Med* 2010;362:1848–1849. DOI:10.1056/NEJMc0910389, PMID:20463351
21. Saleh A, Hegde VV, Potty AG, Schneider R, Cornell CN, Lane JM: Management strategy for symptomatic bisphosphonate-associated incomplete atypical femoral fractures. *HSS J* 2012;8:103–110. DOI:10.1007/s11420-012-9275-y, PMID:23874247
22. Ha YC, Cho MR, Park KH, Kim SY, Koo KH: Is surgery necessary for femoral insufficiency fractures after long-term bisphosphonate therapy? *Clin Orthop Relat Res* 2010;468:3393–3398. DOI:10.1007/s11999-010-1583-2, PMID:20865463
23. Banffy MB, Vrahas MS, Ready JE, Abraham JA: Non-operative versus prophylactic treatment of bisphosphonate-associated femoral stress fractures. *Clin Orthop Relat Res* 2011;469:2028–2034. DOI:10.1007/s11999-011-1828-8, PMID:21350886
24. Egol KA, Park JH, Prenskey C, Rosenberg ZS, Peck V, Tejwani NC: Surgical treatment improves clinical and functional outcomes for patients who sustain incomplete bisphosphonate-related femur fractures. *J Orthop Trauma* 2013;27:331–335. DOI:10.1097/BOT.0b013e31827240ae, PMID:22986315
25. Dell RM, Adams AL, Greene DF, Funahashi TT, Silverman SL, Eisemon EO, Zhou H, Burchette RJ, Ott SM: Incidence of atypical nontraumatic diaphyseal fractures of the femur. *J Bone Miner Res* 2012;27:2544–2550. DOI:10.1002/jbmr.1719, PMID:22836783
26. Gedmintas L, Solomon DH, Kim SC: Bisphosphonates and risk of subtrochanteric, femoral shaft, and atypical femur fracture: a systematic review and meta-analysis. *J Bone Miner Res* 2013;28:1729–1737. DOI:10.1002/jbmr.1893, PMID:23408697