

CASE REPORT

Metastasis to the lateral lingual lymph node located behind the submandibular gland: A case of squamous cell carcinoma of the tongue

Masami Suzuki^{1,2} | Kohtaro Eguchi³ 

¹Department of Head and Neck Surgery, Gunma Prefectural Cancer Center, Ohta, Japan

²Department of Otolaryngology-Head and Neck Surgery, Jichi Medical University Saitama Medical Center, Omiya, Japan

³Department of Head and Neck Surgery, National Cancer Center Hospital, Chuo-ku, Japan

Correspondence

Kohtaro Eguchi, Department of Head and Neck Surgery, National Cancer Center Hospital, 5-1-1, 104-0045 Chuo-ku, Tokyo, Japan.
Email: kohtaro.eguchi@gmail.com

Abstract

Inconsistency in the definition of LLNs may be a hurdle in ensuring the accuracy of the evidence. Refinements in the classification of LLNs, based on the fascial anatomy and lymphatic vessels, are warranted.

KEYWORDS

deep cervical fascia, hypoglossal nerve, lingual lymph node, metastasis, tongue cancer

1 | INTRODUCTION

Metastasis to lateral lingual lymph nodes (LLNs) located lateral to the hyoglossus muscle behind the submandibular gland have not been reported in the English literature, although this group of LLNs were illustrated by Rouvière. Here, we present the first case of such metastasis from squamous cell carcinoma of the tongue.

Lingual lymph nodes (LLNs) are intervening lymph nodes that appear inconstantly in the lymphatic vessels from the tongue. Rouvière classified LLNs into median LLNs located between the genioglossus muscles (Figure 1A) and lateral LLNs located lateral to the genioglossus muscle or the hyoglossus muscle (HGM) (Figure 1B,C).¹ Lateral LLNs located lateral to the HGM behind the submandibular gland (SMG) (Figure 1C) were illustrated by Rouvière.¹ Recently, Ando et al and Ananian et al have also reported LLNs located along the lingual artery (LA) around the cornu of the hyoid bone (Figure 1D).^{2,3} Ozeki et al⁴ first reported a case

of LLN metastasis in 1985, and subsequent cases have since been reported.^{2,5-7} However, metastasis to the lateral LLN located behind the SMG has not been reported in the English literature, although this group of LLNs were illustrated by Rouvière. Here, we present the first case of metastasis to the lateral LLN located behind the SMG from squamous cell carcinoma (SCC) of the tongue.

2 | CASE PRESENTATION

A 59-year-old man presented to our department with pain in the right side of the tongue. There was a neoplastic lesion in the right margin of the tongue, measuring 30 mm in length; biopsy revealed SCC. Computed tomography showed 9.8 mm in depth of invasion and no obvious metastatic lesions (Figure 2). The patient was diagnosed with tongue cancer (T2N0M0: UICC classification, 8th edition) and underwent a partial glossectomy with conservative (elective) supraomohyoid neck dissection

This is an open access article under the terms of the Creative Commons Attribution-NonCommercial-NoDerivs License, which permits use and distribution in any medium, provided the original work is properly cited, the use is non-commercial and no modifications or adaptations are made.

© 2021 The Authors. *Clinical Case Reports* published by John Wiley & Sons Ltd.

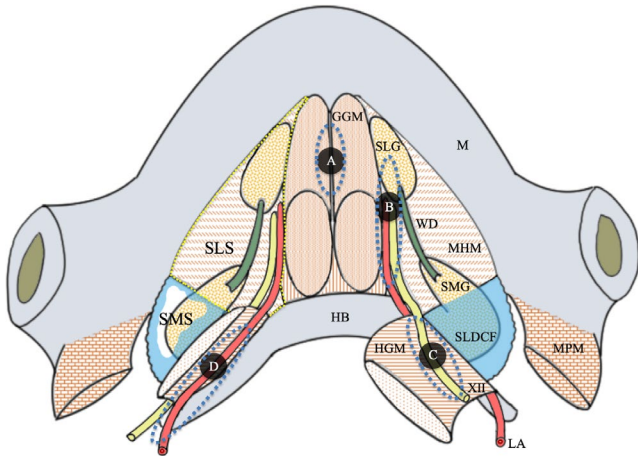


FIGURE 1 Schematic representation of the lingual lymph nodes. LA, lingual artery; XII, hypoglossal nerve; SMG, submandibular gland; SLG, sublingual gland; HB, hyoid bone; M, mandible; WD, Wharton's duct; HGM, hyoglossus muscle; MHM, mylohyoid muscle; MPM, medial pterygoid muscle; GGM, genioglossus muscle; SMS, submandibular space; SLS, sublingual space; SLDCF, superficial layer of the deep cervical fascia. A, lingual lymph nodes located between the genioglossus muscles (in the lingual septum), B, lingual lymph nodes located lateral to the genioglossus muscle or the hyoglossus muscle (in the sublingual space), C, lingual lymph nodes located lateral to the hyoglossus muscle behind the submandibular gland, D, lingual lymph nodes located along the lingual artery around the cornu of the hyoid bone

(ND). After ND, a firm mass ($7 \times 5 \times 5$ mm) was found at the posterior margin of the mylohyoid muscle (MHM) beneath a thin fascia, which was the superficial layer of the deep cervical fascia (SLDCF) along the hypoglossal nerve (XII) (Figure 3). The mass was resected independently. The pathological diagnosis was metastatic SCC to a lymph node (Figure 4). From the intraoperative findings, pathological diagnosis, and anatomy concerning LLNs, we diagnosed the lesion as a metastatic lateral LLN located behind the SMG (Figure 5). The pathological diagnosis of the tongue cancer was pT2N2b (UICC classification, 8th edition). The patient underwent adjuvant radiation

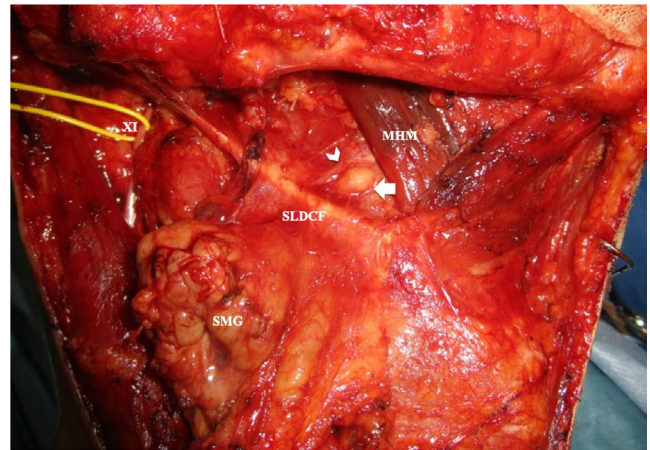


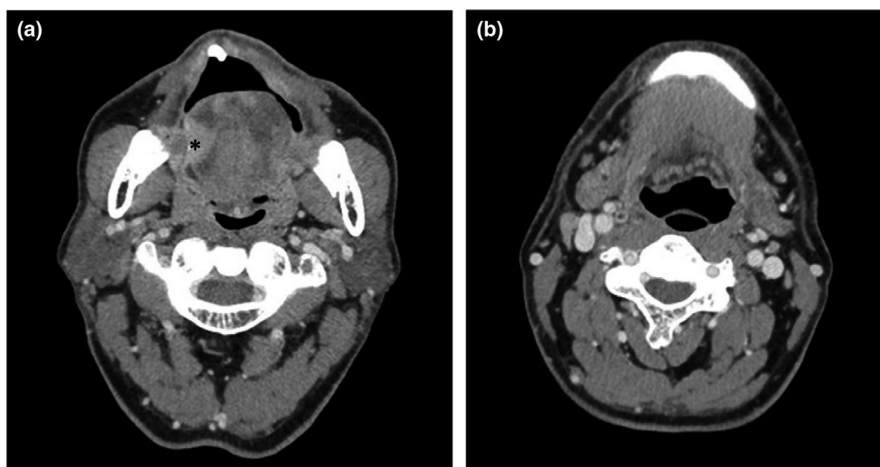
FIGURE 3 Intraoperative view after right conservative neck dissection. MHM, mylohyoid muscle; SMG, submandibular gland; SLDCF, superficial layer of the deep cervical fascia; XII, accessory nerve. Arrow indicates a metastatic lateral lingual lymph node located lateral to the hyoglossus muscle. Arrowhead indicates the hypoglossal nerve

therapy. Lung metastasis was detected 30 months after surgery, which was treated with thoracoscopic partial resection of the lung. The patient is alive with no evidence of disease at 14 months after the last treatment.

3 | DISCUSSION

We report the first case of metastasis to the lateral LLN located behind the SMG. This group of lymph node metastasis has not been described in the English literature, which could be due to the lack of understanding of the fascial anatomy, LLNs, or lymphatic vessels from the margin of the tongue.

Lymphatic vessels from the margin of the tongue first descend medial to the sublingual gland (SLG). After passing the SLG, lymphatic vessels descend in two routes: the hypoglossal nerve route, which is lateral to the HGM along XII, and the



level of primary lesion

level of submandibular gland

FIGURE 2 Preoperative computed tomography images. A, level of primary lesion, B, level of submandibular gland, Asterisk: the primary lesion

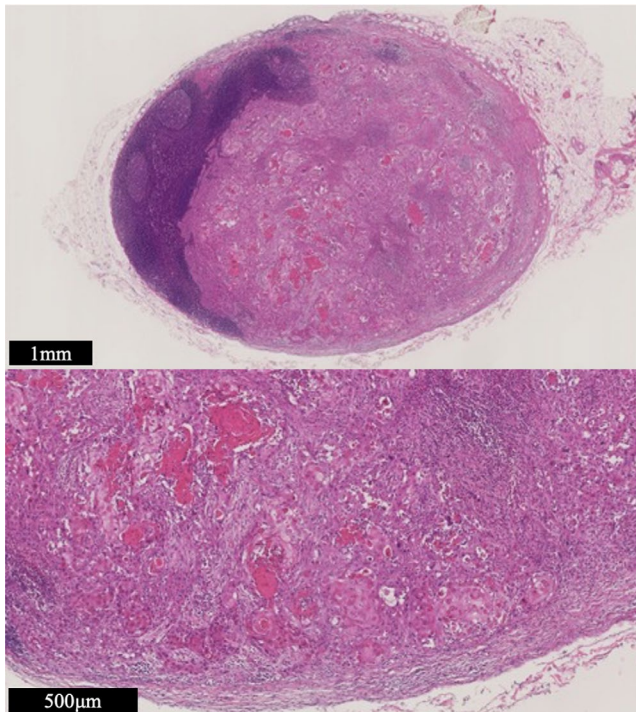


FIGURE 4 Pathological finding of lingual lymph node metastasis (Hematoxylin and eosin staining). The lymph node is occupied with metastatic squamous cell carcinoma. Fibrous coating membrane of the lymph node is intact: extra nodal extension is negative

lingual artery route, which is medial to the HGM along the LA.¹ Lateral LLNs located behind the SMG are not in the submandibular space (SMS) because they are in the hypoglossal nerve route and XII does not run in the SMS (Figure 1). The SMS forms a bag shape with the SLDCF, and the posterior medial wall of the SMS is composed of the deep portion of the SLDCF.^{8,9} When conservative ND is performed, the deep portion of the SLDCF is preserved, covering XII beneath.^{9,10}

The findings of this case correspond to the described theory (Figure 3). Previous descriptions of LLNs, such as those by Rouvière¹ and DiNardo,¹¹ did not refer to the fascial anatomy; this may explain the confusion between LLNs located behind the SMG and level IB nodes in previous studies. Lymph nodes located superficial to the deep portion of the SLDCF should be considered as level IB nodes, which can be dissected routinely via conservative ND, whereas lateral LLNs located behind the SMG are considered to be located beneath the deep portion of the SLDCF, which are, thus, outside the region of conservative ND (Figure 5). Metastasis to LLNs regarding this area could have been under reported due to the confusion of the classification and may require more careful surgical inspection.

Researchers have had different opinions regarding LLNs.¹² Based on the anatomical evidence⁸⁻¹⁰ and clinical experience, we present an idea of classifying LLNs into four groups, namely median, anterior lateral, posterior lateral, and parathyroid LLNs (Figure 1A,B,C,D). Increasing evidence of LLN metastasis has been presented in recent years^{13,14}; incidence reported to be 1.3%-17.1%.¹² LLN metastasis has been reported to significantly worsen locoregional control rate, indicating the necessity of thorough dissection.¹⁴ However, the inconsistency in the definition of LLNs may be a hurdle in ensuring the accuracy of the evidence. Given that a new conception of LLNs regarding the area behind the SMG was indicated from the presented case, refinements in the classification of LLNs, based on the fascial anatomy and lymphatic vessels, are warranted.

4 | CONCLUSION

We report the first case of metastasis to the lateral LLN located behind the SMG. This case indicates the existence of LLNs located beneath the SLDCF, behind the SMG.

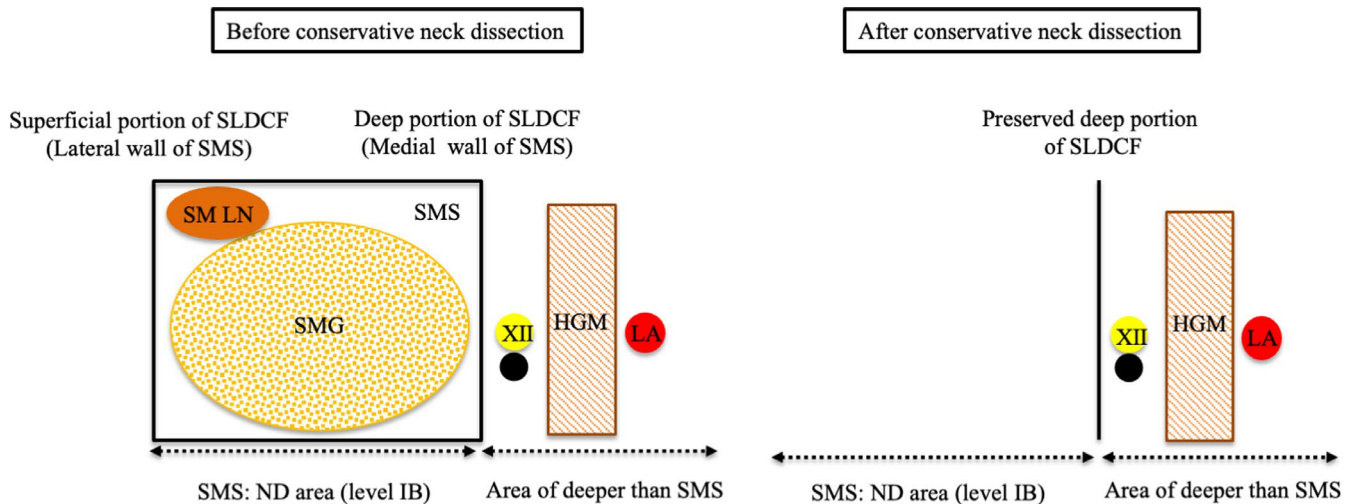


FIGURE 5 Schematic representation local surgical findings. LA, lingual artery; XII, hypoglossal nerve; SMG, submandibular gland; HGM, hypoglossus muscle; SMS, submandibular space; SM LN, submandibular lymph node; ND, neck dissection; SLDCF, superficial layer of the deep cervical fascia. Black circle indicates a metastatic lingual lymph node located lateral to the hypoglossus muscle behind the submandibular gland

ACKNOWLEDGMENTS

The authors would like to thank Dr Seiichiro Kitamura for advice on the article.

CONFLICT OF INTEREST

The authors have no conflicts of interest to declare.

AUTHOR CONTRIBUTIONS

MS and KE: contributed equally to the conception and design of the work, and writing the manuscript.

ETHICAL APPROVAL

Written informed consent was obtained from the patient for publication of the report.

DATA AVAILABILITY STATEMENT

Data sharing not applicable to this article as no datasets were generated or analyzed during the current study.

ORCID

Kohtaro Eguchi  <https://orcid.org/0000-0002-0922-9245>

REFERENCES

1. Rouvière H. Lymphatics of the tongue and of the salivary gland. In: *Anatomy of the human lymphatic system*. Ann Arbor, MI: Edward Brothers, Inc.; 1938:44-51.
2. Ando M, Asai M, Asakage T, et al. Metastatic neck disease beyond the limits of a neck dissection: attention to the 'para-hyoid' area in T1/2 oral tongue cancer. *Jpn J Clin Oncol*. 2009;39:231-236.
3. Ananian SG, Gvetadze SR, Ilkaev KD, et al. Anatomic-histologic study of the floor of the mouth: the lingual lymph nodes. *Jpn J Clin Oncol*. 2015;45:547-554.
4. Ozeki S, Tashiro H, Okamoto M, Matsushima T. Metastasis to the lingual lymph node in carcinoma of the tongue. *J Maxillofac Surg*. 1985;13:277-281.
5. Dutton JM, Graham SM, Hoffman HT. Metastatic cancer to the floor of mouth: the lingual lymph nodes. *Head Neck*. 2002;24:401-405.
6. Han W, Yang X, Huang X, Hu Q, Wang Z. Metastases to lingual lymph nodes from squamous cell carcinoma of the tongue. *Br J Oral Maxillofac Surg*. 2008;46:376-378.
7. Tomblinson CM, Nagel TH, Hu LS, Zarka MA, Hoxworth JM. Median lingual lymph nodes: prevalence on imaging and potential implications for oral cavity cancer staging. *J Comput Assist Tomogr*. 2017;41:528-534.
8. Kitamura S. Anatomy of the fasciae and fascial spaces of the maxillofacial and the anterior neck regions. *Anat Sci Int*. 2018;93:1-13.
9. Kitamura S, Takahashi A, Miyamoto Y. Subcutaneous tissue of the anterior cervical regions and the submandibular regions. In: Kitamura S, ed. *Atlas of oral maxillofacial region anatomy for dental clinicians*. Tokyo, Japan: Ishiyaku Publishers, Inc.; 2009:74-81. (in Japanese).
10. Eguchi K, Muro S, Miwa K, Yamaguchi K, Akita K. Deep cervical fascia as an anatomical landmark of lingual lymph nodes: an anatomic and histologic study. *Auris Nasus Larynx*. 2020;47:464-471.
11. DiNardo LJ. Lymphatics of the submandibular space: an anatomic, clinical, and pathologic study with applications to floor-of-mouth carcinoma. *Laryngoscope*. 1998;108:206-214.
12. Gvetadze SR, Ilkaev KD. Lingual lymph nodes: anatomy, clinical considerations, and oncological significance. *World J Clin Oncol*. 2020;11:337-347.
13. Jia J, Jia MQ, Zou HX. Lingual lymph nodes in patients with squamous cell carcinoma of the tongue and the floor of the mouth. *Head Neck*. 2018;40:2383-2388.
14. Fang Q, Li P, Qi J, Luo R, Chen D, Zhang X. Value of lingual lymph node metastasis in patients with squamous cell carcinoma of the tongue. *Laryngoscope*. 2019;129:2527-2530.

How to cite this article: Suzuki M, Eguchi K. Metastasis to the lateral lingual lymph node located behind the submandibular gland: A case of squamous cell carcinoma of the tongue. *Clin Case Rep*. 2021;9:1763–1766. <https://doi.org/10.1002/ccr3.3898>