

## Epithelioid Sarcoma of Lumbar Spine: A Rare Mesenchymal Tumor Masquerading as Infection

### Abstract

Epithelioid sarcoma of the spine has been rarely reported in the literature. Its diagnosis is challenging due to nonspecific findings. We report a case of 42-year-old gentleman with back pain. Magnetic resonance imaging (MRI) revealed lesion in the L4 vertebral body extending into the spinal canal with pre and paravertebral involvement. He underwent posterior spinal decompression and instrumentation with biopsy. Histopathological examination was nonspecific. Considering clinical and radiological features, antitubercular treatment was initiated. The patient developed acute onset weakness of both lower extremities 1 month post-surgery. Repeat MRI and positron emission tomography (PET) computed tomography revealed an increase in the extent of lesion which required revision decompression. Histopathological examination showed cells with epithelioid appearance, positive for Vimentin, and epithelioid membrane antigen in immunohistochemistry. Radiotherapy was planned but the patient expired due to multiorgan dysfunction. Epithelioid sarcomas are rare soft-tissue neoplasms with poor prognosis. They can mimic infection and a high degree of suspicion is required in these cases to diagnose and treat them early.

**Keywords:** Epithelioid sarcoma, infection, lumbar spine

### Introduction

Epithelioid sarcoma is a rare soft-tissue neoplasm of mesenchymal origin characterized by epithelioid cell-like features accounting for <1% of all soft-tissue sarcomas.<sup>[1,2]</sup> The condition was first described in 1961 by Laskowski and clearly characterized by F. M Enzinger. He reported 62 cases of a peculiar form of sarcoma that has been confused with a chronic inflammatory process, a necrotizing granuloma in 1970.<sup>[3]</sup> It commonly presents in the extremities of young adults<sup>[4]</sup> and very rarely in the axial skeleton. Its diagnosis is often difficult as it mimics a benign reactive granuloma and resembles a chronic inflammatory process.<sup>[3,5-9]</sup> Epithelioid sarcomas have no definitive cell of origin, but are alleged to show ultrastructural and immunophenotypic evidence of epithelial differentiation with myofibroblastic characteristics.<sup>[2,10]</sup> This mixed differentiation of the tumor can make the differential diagnosis challenging. Epithelioid sarcoma has a poor prognosis due to its aggressive behavior and is known

for its high recurrence.<sup>[5]</sup> It is also capable of lymphatic and hematogenous metastasis making the prognosis unpredictable.<sup>[5-7]</sup> These events, as well as progression and aggressiveness, are predictive of an overall worse outcome. The overall 5-year survival rate for Epithelioid sarcoma is anywhere from 25% to 78%.<sup>[11]</sup> 10-year and 15-year survival rate is significantly low.<sup>[12,13]</sup> Positive outcome factors are younger age, female gender, proximal location, smaller tumor size, and negative margins upon tumor resection.<sup>[3,13,14]</sup> To our knowledge, only very few case reports of epithelioid sarcoma of the spine (lumbosacral junction, sacrum, lumbar, and thoracic spine) has been reported in the literature. Epithelioid sarcoma involving lumbar spine is extremely rare and here we report a similar case presenting as an infection that threw challenges in early diagnosis and management.

### Case Report

A 42-year-old previously asymptomatic healthy male presented to our outpatient

**G. Sudhir,  
S. Vignesh  
Jayabalan,  
Amith Ram,  
Saikrishna Gadde,  
Karthik Kailash**

*Department of Spine Surgery,  
Sri Ramachandra Institute of  
Higher Education and Research,  
Porur, Chennai, Tamil Nadu,  
India*

**Address for correspondence:**  
*Dr. S. Vignesh Jayabalan,  
Sri Ramachandra Institute of  
Higher Education and Research,  
Porur, Chennai - 600 116, Tamil  
Nadu, India.  
E-mail: spinesurgeonsudhir@  
gmail.com*

This is an open access journal, and articles are distributed under the terms of the Creative Commons Attribution-NonCommercial-ShareAlike 4.0 License, which allows others to remix, tweak, and build upon the work non-commercially, as long as appropriate credit is given and the new creations are licensed under the identical terms.

For reprints contact: WKHLRPMedknow\_reprints@wolterskluwer.com

**How to cite this article:** Sudhir G, Jayabalan SV, Ram A, Gadde S, Kailash K. Epithelioid sarcoma of lumbar spine: A rare mesenchymal tumor masquerading as infection. Asian J Neurosurg 2021;16:191-5.

**Submitted:** 02-May-2020      **Revised:** 07-Sep-2020  
**Accepted:** 28-Dec-2020      **Published:** 23-Feb-2021

#### Access this article online

**Website:** www.asianjns.org

**DOI:** 10.4103/ajns.AJNS\_190\_20

#### Quick Response Code:



department with complaints of diffuse Lower back pain which started 15 days earlier and suddenly increased for the past 2 days. The pain was constant dull aching without diurnal variations, radiating to bilateral lower limbs affecting his daily routine. He gave no other significant contributing history. On physical examination, he was well built and nourished with no gait or postural abnormalities and visible deformities. On palpation, mild tenderness was present over L3, L4, L5 vertebral spinous processes along with adjacent Paraspinal muscle spasms. The neurological status was normal. His blood examination revealed raised erythrocyte sedimentation rate of 84 mm/h. Rest of the blood parameters were normal. Plain radiograph of the lumbosacral spine revealed a mild reduction in the height of the L4 vertebral body with sclerosis [Figure 1]. Magnetic resonance imaging (MRI) of the lumbosacral spine showed heterogeneous signal intensity and fracture of L4 vertebral body with associated epidural and paravertebral abscess collections causing mass effect on Cauda Equina and filum terminale [Figure 2a-d]. Contrast

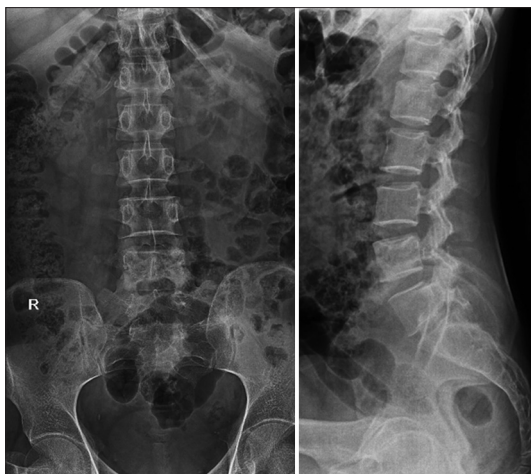

Figure 1: Preoperative X-ray showing sclerosis of L4 vertebral body

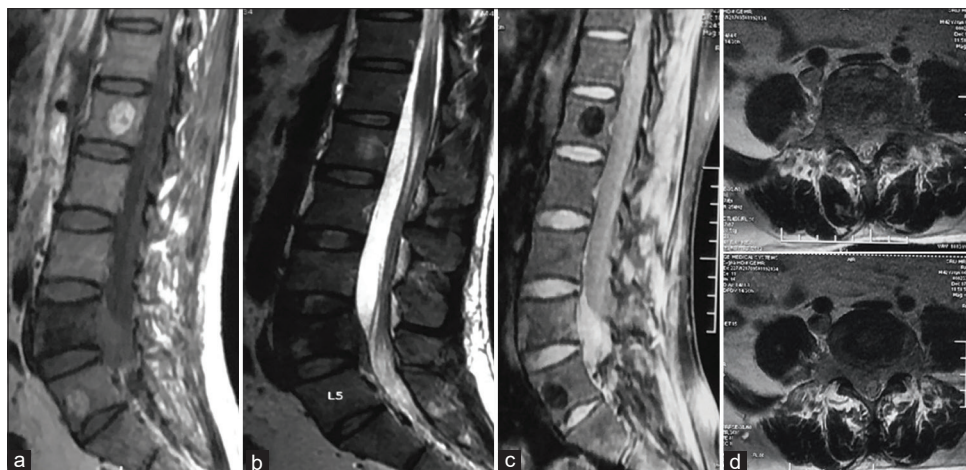

Figure 2: (a and b) Sagittal T1 and T2 weighted magnetic resonance imaging respectively showing heterogeneous signal intensity and mild collapse of L4 vertebral body with extradural collection compressing the dura, (c) Sagittal STIR sequence showing hyperintense lesion involving L4 body with extension into the epidural space, (d) Axial T2 weighted magnetic resonance imaging showing near complete occlusion of the spinal canal

MRI showed homogenous enhancement of the lesion in the L4 body and the canal [Figure 3a-c]. He underwent L3-5 posterior spinal instrumentation with pedicle screws and rods and posterior spinal decompression at stenotic level [Figure 4]. Biopsy samples were obtained from the L4 vertebral body through transpedicular approach and from the intracanalicular tissue. Biopsy samples and fluid collected were subjected to histopathological and microbiological analysis. Intra-operative and immediate postoperative periods were uneventful. Tissue staining and cultures were negative. Polymerase chain reaction (PCR) for tuberculosis (TB) was negative. Histopathological examination of the biopsy material showed bony spicules interspersed with fibro collagenous tissue, marrow elements along with areas of focal congestion and foci of mild chronic inflammation. No evidence of malignancy was traced and immunohistochemistry (IHC) studies were negative. Based on clinical and radiological evidences, impression of tuberculous spondylitis was made since TB is very common in our region though PCR was negative and medical treatment for the same was initiated. The patient was functionally better for 1 month until he developed sudden onset of progressive weakness with no associated sensory disturbances of both the lower extremities. On examination, the power was Grade 1 in bilateral L4, L5, and S1. Bowel and bladder were spared and had normal bilateral lower extremities sensations. MRI of the lumbar spine revealed increase in the soft tissue component compared to the previous report extending from L3 to L5 vertebra causing complete canal stenosis along with pre and para vertebral involvement [Figure 5a-c]. Positron emission tomography (PET) computed tomography revealed increased fluorodeoxyglucose uptake in the L4 body and in the prevertebral, paravertebral regions and in the spinal canal [Figure 6]. He was taken up for revision decompression considering his progressive lower limbs weakness. Intra operatively, we found

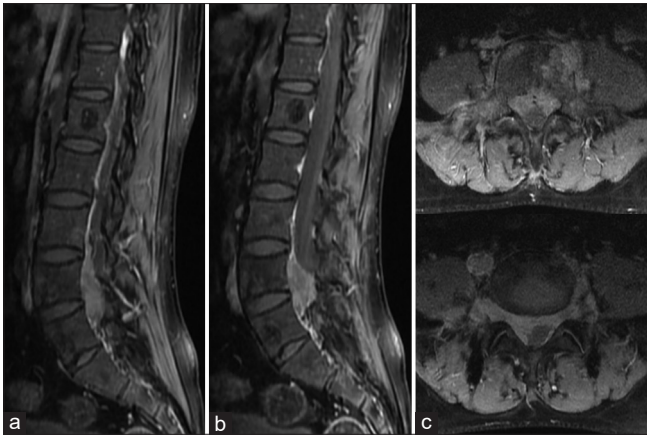


Figure 3: (a-c) Contrast magnetic resonance imaging showing homogenous enhancement of the lesion in L4 body with extension into the spinal canal, pre vertebral and paravertebral region

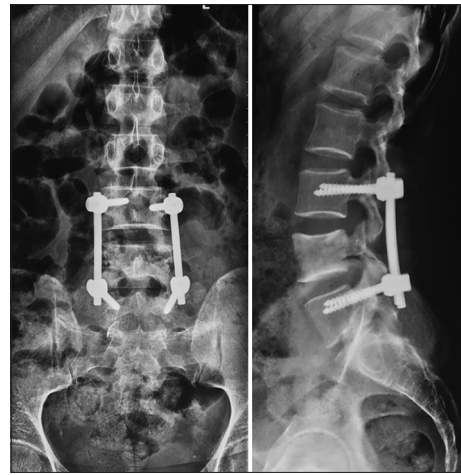

Figure 4: Postoperative X-ray at 1 month follow up showing the implants *in situ* without further collapse of L4

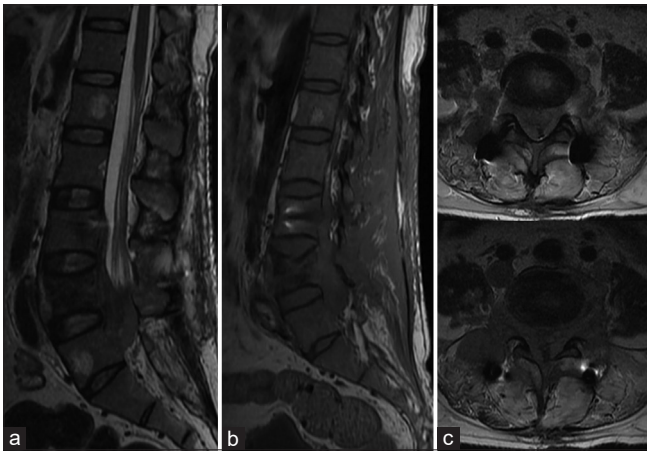


Figure 5: (a-c) Sagittal T2, Sagittal T1 and axial T2 weighted magnetic resonance imaging respectively at the end of one month following initial surgery showing increase in the lesion and wide involvement of the L4 body and extension of the lesion into the spinal canal

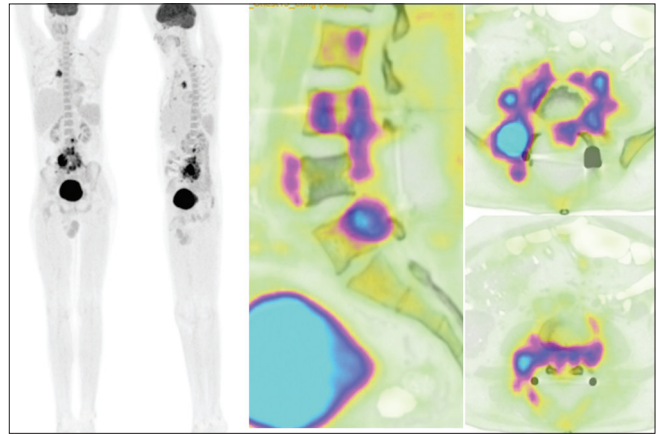


Figure 6: Intraoperative image showing friable tissue engulfing the dural sac during revision procedure

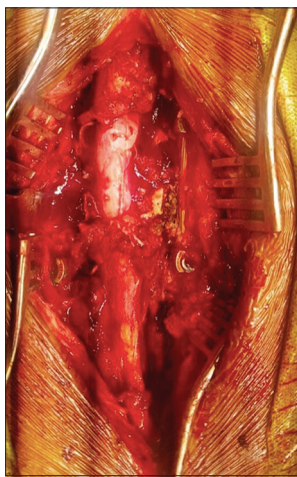


Figure 7: Positron emission tomography computed tomography showing increased fluorodeoxyglucose uptake in the L4 body and in the pre, para vertebral regions and in the spinal canal

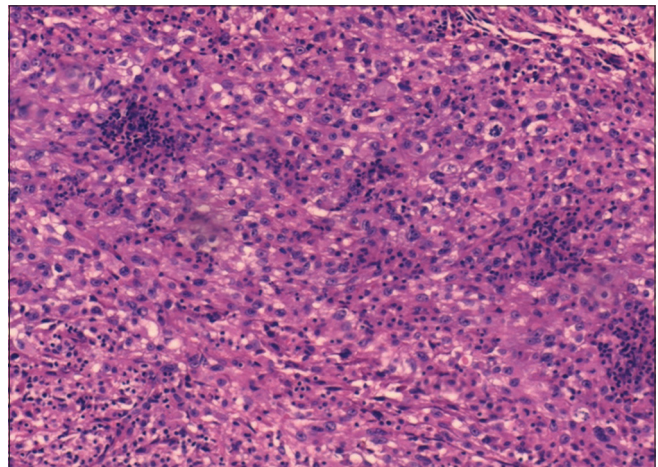
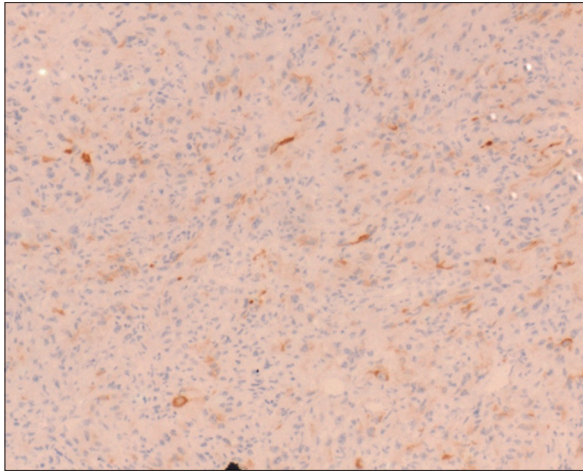


Figure 8: HPE showing epithelioid cells with deeply stained eosinophilic cytoplasm and intercellular deposition of hyalinised collagen

extensive friable tissue engulfing and surrounding the dura at L4 vertebral level for which extensive debulking

was carried out [Figure 7]. The debulked tissue was sent for histopathological and microbiological analysis. Microbiological reports were inconclusive as no organism was isolated. PET scan showed features in favor of infective



**Figure 9: Immunohistochemistry showing cells positive for Epithelioid Membrane Antigen**

etiology and no similar lesions elsewhere. According to the histopathology report the biopsy tissue had features in favor of Epithelioid Sarcoma. Microscopic appearance showed neoplastic tissue with infiltration by tumor cells which are round to oval shape with nuclear pleomorphism, irregular nuclear membrane, and moderate cytoplasm. Many cells showed prominent cells with the epithelioid appearance and eosinophilic nuclei with adjacent lymphoid cells [Figure 8]. Subsequently, the tissue was also subjected to IHC in which the tumor cells were positive for Vimentin and Epithelioid Membrane Antigen (EMA), thereby reconfirming the diagnosis of Epithelioid Sarcoma [Figure 9]. Fever was managed with antipyretics and rehabilitative physiotherapy was initiated. Wound healing was good. There was no improvement in the neurological status. Radiotherapy and Chemotherapy were planned but the patient died 4 weeks postoperative due to multiorgan dysfunction.

## Discussion

Epithelioid sarcoma is rare tumors which is common in the extremities<sup>[10]</sup> but it is extremely rare in the spine. It commonly strikes young adults, yet no age group is immune. The male:female ratio is 2:1. It can metastasize to regional lymph nodes, lung, brain, bone, and other locations, including the scalp.<sup>[1]</sup> Epithelioid sarcoma known for its aggressive behavior, has higher rates of relapse after initial treatment and tends to recur locally.<sup>[7]</sup> Studies have cited the inactivation of SMARCB1 gene<sup>[15,16]</sup> to be a major contributor for disease activation. SMARCB1 gene has been shown to be a potent tumor suppressor gene<sup>[17,18]</sup> and its inactivation is responsible for the unregulated cellular growth and the formation of cancer tumors.<sup>[12]</sup> Epithelioid sarcoma is known to simulate a benign process by showcasing protracted growth and usually a painless scenario<sup>[1,2,9]</sup> like our patient who had diffuse backache for only 15 days without any other symptoms. Radiologically MR signal intensity of the epithelioid sarcoma is isointense to muscle on T1-weighted image and hyperintense

on T2-weighted image with strong enhancement. Large soft-tissue mass with necrosis or hemorrhage is characteristic of epithelioid sarcoma.<sup>[6,19-21]</sup> Histologically, epithelioid Sarcoma is commonly characterized by multiple granulomatous nodules. In the center of the nodules, necrosis, hemorrhage and cystic changes commonly appear. In addition, infiltration of chronic inflammatory cells like lymphocytes can also be found. The nodules are surrounded by large epithelioid cells, which are polygonal, round, or ovoid. The neoplastic nuclei tend to be circular or ovoid, and the atypia is relatively mild. Apart from that, small nucleoli can be noted.<sup>[22]</sup> This lymphocytic infiltration and central necrosis give a pseudo granulomatous picture which can masquerade as a granulomatous infection and thereby misguide us in planning the treatment. For the immunohistochemical features, Epithelioid Sarcoma demonstrates positive stain for cytokeratin and EMA in >90% of the cases. Vimentin also is usually positive in most cases. The differential diagnosis can be granuloma, epithelioid angiosarcoma, malignant melanoma, synovial sarcoma, malignant extrarenal rhabdomyoid tumor.<sup>[19]</sup>

The prognosis of epithelioid sarcoma is poor and the recurrence rate can be as much as 19%–56% within 1 year.<sup>[12,23-26]</sup> The truncal location of the tumor, tumor size >5 cm, infiltration into the surrounding structures, lymph node involvement, pulmonary metastases, rhabdoid cytomorphology with necrosis, and local recurrence are considered poor prognostic factors and can result in multi-organ dysfunction.<sup>[12,23]</sup> The primary line of treatment of Epithelioid sarcoma is the radical excision of the tumor mass with tumor-free margins. In the spine, total eradication of the tumor by radical or en-bloc excision is difficult due to the presence of neural structures. Thus, the intralesional resection is the left out option.<sup>[8,9]</sup> Histologically, tumor-free surgical margin is the basis for higher disease-free survival and even the microscopically left out tumor cells are potent enough to cause a recurrence.<sup>[13]</sup> Though the chances to prevent the local recurrence were uncertain. Radiotherapy is to be resorted in patients in whom complete resection of tumor cannot be accomplished and tumor-free margin cannot be obtained.<sup>[24]</sup> In case of recurrence, repeat radical resection has to be performed and spinal implants contaminated with the tumor cells have to be exchanged.

In our case, though the radiological findings, including the PET scan, were guiding us to the provisional diagnosis of an infection, the high power histopathological morphology and immunohistochemical pattern supported the diagnosis of epithelioid sarcoma. Except metastasis, our patients had all the other poor prognostic factors. The scope of misdiagnosing the disease is quite high due to its uncertain radiology and low power histological appearance simulating an infection or a chronic inflammatory change masking the underlying lesion. This is the clinical scenario where the

suspicion of the treating surgeon and communication with the investigating pathologist comes into play.

Spinal epithelioid sarcoma is an extremely rare neoplasm and challenging to diagnose as it masquerades an infection. It is a highly aggressive tumor with poor prognosis, lymphovascular metastasis, and high recurrence rate. It is always advisable to consider intraoperative tissue analysis to attain tumor-free margins by involving the pathologist right from the time of surgical planning and proceed with special immunohistochemical studies to determine the possibility of epithelioid sarcoma in patients with spinal lesions having paraspinal involvement and mass invading the extradural space, thereby diagnosis of such aggressive neoplasms cannot be missed.

### Acknowledgment

I hereby acknowledge the details furnished.

### Declaration of patient consent

The authors certify that they have obtained all appropriate patient consent forms. In the form the patient(s) has/have given his/her/their consent for his/her/their images and other clinical information to be reported in the journal. The patients understand that their names and initials will not be published and due efforts will be made to conceal their identity, but anonymity cannot be guaranteed.

### Financial support and sponsorship

Nil.

### Conflicts of interest

There are no conflicts of interest.

### References

1. Armah HB, Parwani AV. Epithelioid sarcoma. *Arch Pathol Lab Med* 2009;133:814-9.
2. Fisher C. Epithelioid sarcoma of Enzinger. *Adv Anat Pathol* 2006;13:114-21.
3. Enzinger FM. Epithelioid sarcoma. A sarcoma simulating a granuloma or a carcinoma. *Cancer* 1970;26:1029-41.
4. Steinberg BD, Gelberman RH, Mankin HJ, Rosenberg AE. Epithelioid sarcoma in the upper extremity. *J Bone Joint Surg Am* 1992;74:28-35.
5. Prat J, Woodruff JM, Marcove RC. Epithelioid sarcoma: An analysis of 22 cases indicating the prognostic significance of vascular invasion and regional lymph node metastasis. *Cancer* 1978;41:1472-87.
6. Romero JA, Kim EE, Moral IS. MR characteristics of epithelioid sarcoma. *J Comput Assist Tomogr* 1994;18:929-31.
7. Ross HM, Lewis JJ, Woodruff JM, Brennan MF. Epithelioid sarcoma: Clinical behavior and prognostic factors of survival. *Ann Surg Oncol* 1997;4:491-5.
8. Steib JP, Pierchon F, Farcy JP, Lang G, Christmann D, Gnassia JP. Epithelioid sarcoma of the spine: A case report. *Spine* 1996;21:634-8.
9. Weisskopf M, Munker R, Hermanns-Sachweh B, Ohnsorge JA, Siebert C. Epithelioid sarcoma in the thoracic spine. *Eur Spine J* 2006;15 Suppl 5:604-9.
10. Guillou L, Wadden C, Coindre JM, Krausz T, Fletcher CD. "Proximal-type" epithelioid sarcoma, a distinctive aggressive neoplasm showing rhabdoid features. Clinicopathologic, immunohistochemical, and ultrastructural study of a series. *Am J Surg Pathol* 1997;21:130-46.
11. Levy A, Le Pécoux C, Terrier P, Bouaita R, Domont J, Mir O, *et al.* Epithelioid sarcoma: Need for a multimodal approach to maximize the chances of curative conservative treatment. *Ann Surg Oncol* 2014;21:269-76.
12. Dina L. Epigenetic reprogramming of epithelioid sarcoma: A role for INI1-HDAC crosstalk. Archived from the original on 2015-04-22.
13. Casanova M, Ferrari A, Collini P, Bisogno G, Alaggio R, Cecchetto G, *et al.* Epithelioid sarcoma in children and adolescents: A report from the Italian Soft Tissue Sarcoma Committee. *Cancer* 2006;106:708-17.
14. Umar JM, Jason E, Elijah SM, Sean PS. Prognostic factors for survival in patients with epithelioid sarcoma: 441 cases from the SEER database. *Clin Orthop Relat Res* 2009;467:2939-48.
15. Jason LH, Paola DC, Christopher DM. Loss of INI1 Expression is Characteristic of Both Conventional and Proximal-type Epithelioid Sarcoma. *Am J Surg Pathol* 2009;33:542-50.
16. Piergiorgio M, Elena L, Federica F, Lisa G, Manuel RT, Silvana P, *et al.* SMARCB1/INI1 tumor suppressor gene is frequently inactivated in epithelioid sarcomas. *Cancer Res* 2005;65:4012-9.
17. Lushnikova T, Knuutila S, Miettinen M. DNA copy number changes in epithelioid sarcoma and its variants: A comparative genomic hybridization study. *Mod Pathol* 2000;13:1092-6.
18. Bhaskar K, Jinlong Y, Stefanie BM, Kenneth WT, Shermi YL, Li L, *et al.* The silencing of the SWI/SNF subunit and anticancer gene BRM in Rhabdoid tumor. *Oncotarget* 2014;5:3316-32.
19. Chase DR, Enzinger FM. Epithelioid sarcoma. Diagnosis, prognostic indicators, and treatment. *Am J Surg Pathol* 1985;9:241-63.
20. Yamato M, Nishimura G, Yamaguchi T, Tamai K, Saotome K. Epithelioid sarcoma with unusual radiological findings. *Skeletal Radiol* 1997;26:606-10.
21. Yoo J. Epithelioid sarcoma of the spine: A case report and review. *Open J Clin Diagn* 2011;1:1-4.
22. Li Y, Cao G, Tao X, Guo J, Wu S, Tao Y. Clinicopathologic features of epithelioid sarcoma: Report of seventeen cases and review of literature. *Int J Clin Exp Pathol* 2019;12:3042-8.
23. de Visscher SA, van Ginkel RJ, Wobbes T, Veth RP, Ten Heuvel SE, Suurmeijer AJ, *et al.* Epithelioid sarcoma: Still an only surgically curable disease. *Cancer* 2006;107:606-12.
24. Baratti D, Pennacchioli E, Casali PG, Bertulli R, Lozza L, Olmi P, *et al.* Epithelioid sarcoma: Prognostic factors and survival in a series of patients treated at a single institution. *Ann Surg Oncol* 2007;14:3542-51.
25. Chbani L, Guillou L, Terrier P, Decouvelaere AV, Grégoire F, Terrier-Lacombe MJ, *et al.* Epithelioid sarcoma: A clinicopathologic and immunohistochemical analysis of 106 cases from the French sarcoma group. *Am J Clin Pathol* 2009;131:222-7.
26. Chanplakorn P, Chanplakorn N, Pongtippan A, Jaovisidha S, Laohacharoensombat W. Recurrent epithelioid sarcoma in the thoracic spine successfully treated with multilevel total en bloc spondylectomy. *Eur Spine J* 2011;20 Suppl 2:S302-8.