

## Case report

## Renal failure after placement of an articulating, antibiotic impregnated polymethylmethacrylate hip spacer

Robert P. Runner, MD<sup>\*</sup>, Amanda Mener, BS, Thomas L. Bradbury, MD

Department of Orthopaedics, Emory University School of Medicine, Atlanta, GA, USA

## ARTICLE INFO

## Article history:

Received 28 January 2017

Received in revised form

10 February 2017

Accepted 10 February 2017

Available online 29 March 2017

## Keywords:

Antibiotic spacer

Acute renal failure

Septic arthritis

Hemodialysis

Antibiotic impregnated cement

## ABSTRACT

A 58-year-old male presented with native joint septic arthritis of the hip and osteomyelitis. After treatment with an articulating antibiotic spacer, he developed acute renal failure requiring dialysis. He continued to have elevated serum tobramycin levels exclusively from the antibiotic spacer elution as no intravenous tobramycin was used. Subsequent explantation was required to correct his renal failure. Although renal failure after antibiotic impregnated cement placement is rare, the risk of this potential complication should be considered preoperatively and in the postoperative management of these patients.

© 2017 The Authors. Published by Elsevier Inc. on behalf of The American Association of Hip and Knee Surgeons. This is an open access article under the CC BY-NC-ND license (<http://creativecommons.org/licenses/by-nc-nd/4.0/>).

## Introduction

Acute septic arthritis in native joints is a rare condition affecting 2–12/100,000 per year up to 30–70/100,000 in high-risk groups [1–9]. It occurs more commonly in children, the elderly and males [5] with inpatient hospital mortality ranging from 2%–10% [1,2,7,10]. The incidence is rising with advanced age, orthopaedic procedures, skin infections, intraarticular corticosteroid injections, and diabetes as potential risk factors [8,11]. The most frequent organism isolated is *Staphylococcus* in 35%–56% of cases [1,2,10,12]. *Streptococcus* is the second most common organism isolated, followed by gram negatives accounting for 20% of cases [1,3,6,13,14]. As virulence factors produced by bacteria, such as toxins and enzymes, can directly contribute to eroding the affected joint [15], prompt diagnosis and management is essential to prevent permanent damage.

Diagnosis of acute septic arthritis is based on clinical symptoms: acute onset joint pain, erythema, swelling, decreased range of

motion, and possibly the inability to ambulate. Elevated inflammatory markers with serum white blood cells (WBCs) >11,000/ $\mu$ L, erythrocyte sedimentation rate (ESR) >20 mm/h, and aspirated WBCs in the joint fluid (cell count) >50,000/ $\mu$ L have sensitivities of 75%, 75%, and 50% and specificities of 55%, 11%, and 88%, respectively. However, the combined sensitivity of WBCs, ESR, and cell count is 100% when all 3 tests are positive [16]. Although some patients present with sweats, rigors, and a history of fever, none are required for diagnosis, as fever is present in only 50.9% of patients [17] with sweats and rigors as low as 15% and 6%, respectively [4]. Although elevated WBCs and ESR combined with patient symptoms can indicate a high likelihood of acute septic arthritis, the diagnosis is confirmed when bacteria are isolated from the synovial fluid [18]. Direct inoculation from traumatic or iatrogenic causes or hematologic spread of bacteria can cause acute septic arthritis. Concomitant bacteremia is common with 50%–70% of patients having positive blood cultures [12], likely indicating hematogenous seeding. Immunosuppressed patients or hospitalized patients can acquire bacteria via intravascular devices, catheters, or recent orthopaedic procedures [11]. Acute septic arthritis is most commonly treated by surgical debridement and oral or intravenous antibiotics; with concurrent osteomyelitis, bony resection may be required.

During surgical management of acute septic arthritis with concomitant osteomyelitis, antibiotic impregnated cement (AIC) may be used both as a spacer and to control long-term joint

One or more of the authors of this paper have disclosed potential or pertinent conflicts of interest, which may include receipt of payment, either direct or indirect, institutional support, or association with an entity in the biomedical field which may be perceived to have potential conflict of interest with this work. For full disclosure statements refer to <http://dx.doi.org/10.1016/j.artd.2017.02.005>.

<sup>\*</sup> Corresponding author. 59 Executive Park South, Atlanta, GA 30329, USA. Tel.: +1 404 778 1567.

E-mail address: [rrunner@emory.edu](mailto:rrunner@emory.edu)

infections [19]. Studies show that AIC leads to local concentrations above the minimum inhibitory concentration for most pathogens, whereas systemic concentrations remain relatively below levels associated with nephrotoxicity [20,21], thus conferring an advantage over intravenous antibiotic administration. Systemic intravenous antibiotic administration can cause significant renal dysfunction, with 12.9%–14% of patients of aminoglycoside-treated and 8%–18% of vancomycin-treated patients experiencing a decline in renal function postadministration [22,23]. Vancomycin and aminoglycosides have a synergistic effect on the risk of renal toxicity when used in combination [24]. Even the addition of a vancomycin to cefazolin for routine perioperative prophylaxis in primary joint arthroplasty was associated with a significantly higher incidence of acute kidney injury (13%) compared to the 8% incidence when cefazolin is administered alone [25]. Although renal toxicity associated with AIC is rare, it can occur. Previous studies have reported incidence rates of acute kidney injury after AIC placement ranging from 4.8%–20% [26,27].

This case report presents an isolated case of acute kidney injury after placement of tobramycin impregnated cement to treat acute septic arthritis with osteomyelitis. Symptoms and laboratory evidence of renal damage resolved after explantation of the AIC, indicating direct kidney injury mediated by AIC.

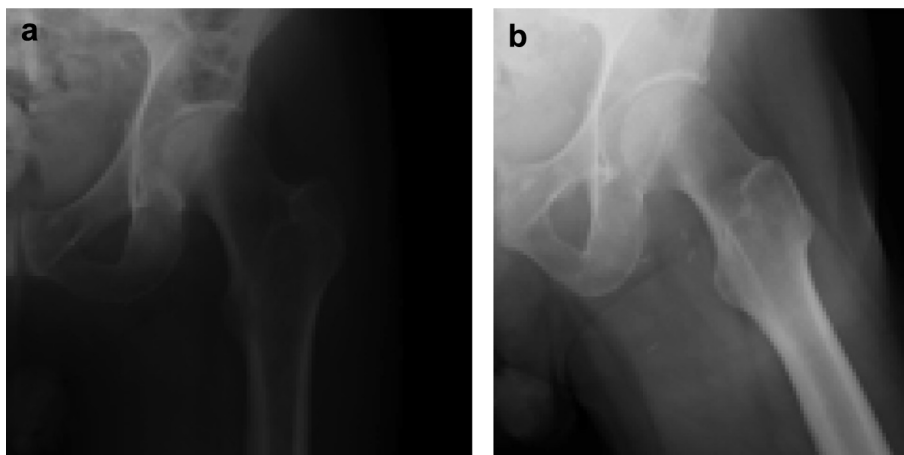
Informed consent for the authorization of medical case study and publication was obtained from the patient.

### Case history

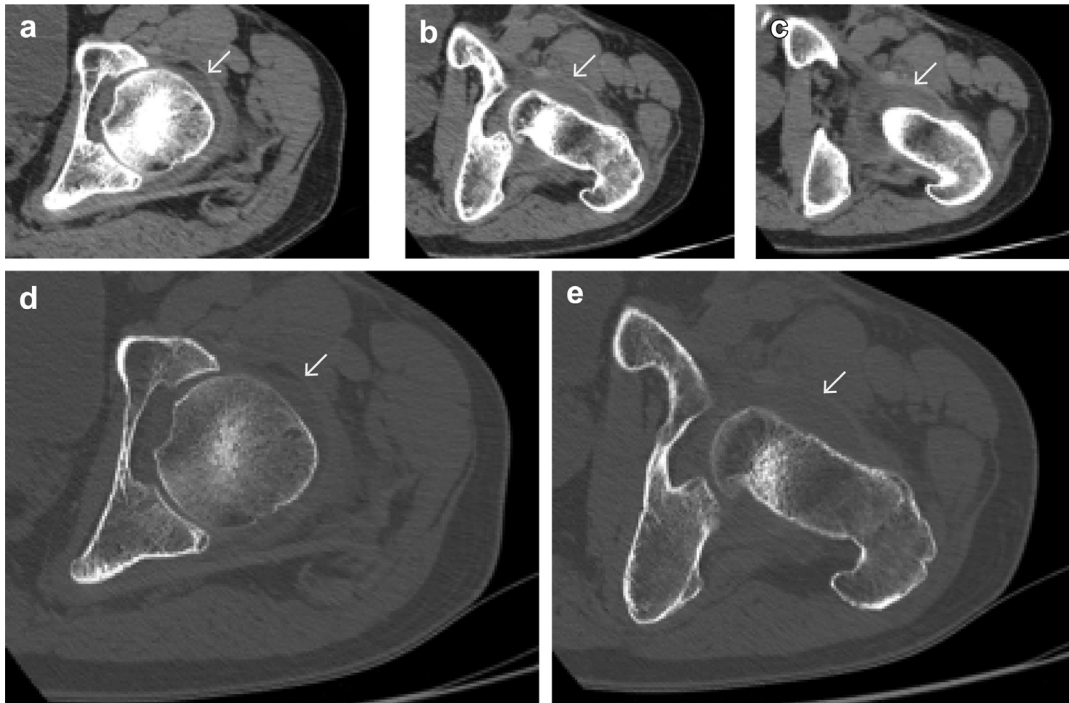
A 58-year-old male with a history of metastatic melanoma stage IV status post recent parietal craniotomy with no further evidence of disease presented to the emergency department with worsening left leg pain for 2 days, inability to bear weight, and fevers. After his neurosurgical procedure, he was placed on high-dose corticosteroids and was discharged on a dexamethasone taper. Initial radiographs showed no fracture or lytic lesion (Fig. 1). Duplex ultrasound for venous thrombosis was negative. The patient was febrile to 38.9°C and urinalysis showed evidence of a urinary tract infection; urine culture and blood cultures grew gram-negative rods. During physical therapy, he was unable to ambulate because of left hip pain. Computed tomography imaging revealed a moderate left hip effusion (Fig. 2). Infectious disease was consulted and recommended piperacillin-tazobactam 3.375 g IV q8hr and orthopaedic consultation for possible septic arthritis. Interventional radiology (IR) performed a fluoroscopically guided aspiration of the left hip, yielding 20 mL of purulent material which grew pansensitive *Escherichia coli*.

Magnetic resonance imaging of the pelvis showed bilateral hip effusions with femoral head avascular necrosis (AVN; Fig. 3). His left hip was significantly tender to range of motion, whereas his right hip was relatively asymptomatic. He underwent an open irrigation and debridement (I&D) of the left hip through an anterolateral Heuter approach with closure over a drain. He continued piperacillin-tazobactam and started ceftriaxone. He convalesced on the floor, but remained febrile despite appropriate organism-specific antibiotic therapy. On postoperative day 3, he had worsening right hip symptoms. Given his effusion on magnetic resonance imaging, his right hip was aspirated (26,500 cells/ $\mu$ L, 94% neutrophils, positive for *E. coli*) then underwent I&D via Heuter approach with closure over a drain. *E. coli* cultured from his urine, blood, and bilateral hips was sensitive to levofloxacin and his antibiotic therapy was narrowed to this single drug, 750 mg PO qday  $\times$  6 weeks. On the day of discharge, new blood and urine cultures showed no growth, ESR was 96 mm/h and C-reactive protein was 235.89 mg/L.

The patient returned to the emergency department 3 days after discharge with worsening bilateral hip pain, painful range of motion, and limp. Serum WBC count was 14,500 cells/ $\mu$ L; C-reactive protein improved to 195.79 mg/L and ESR was similar at 103 mm/h. Orthopaedics was consulted for concerns of recurrence of bilateral hip joint sepsis. The patient was placed on broad spectrum vancomycin and piperacillin-tazobactam for a possible second organism. IR aspiration obtained 80 mL of purulent fluid from the left hip (107,000 cells/ $\mu$ L, 100% neutrophils) and 10 cc of purulent fluid from the right hip (72,000 cells/ $\mu$ L, 98% neutrophils). The patient returned to the operating room. Upon entering the left hip, a massive recurrent purulent fluid collection was found. After resection of the femoral head, the anterior aspect of the femoral head was cut in the coronal plane and showed evidence of AVN without frank collapse. There was a small area of fragmentation of articular cartilage anteriorly that communicated with the avascular lesion. The left hip was reconstructed with an articulating, antibiotic impregnated polymethylmethacrylate spacer (PROSTALAC). One pack of Cobalt HV polymethylmethacrylate cement with 0.5 g gentamicin (Biomet Orthopedics, Warsaw, IN) with a mixture of 3.0 g vancomycin and 3.6 g tobramycin was used for the acetabulum. A second pack of Cobalt HV polymethylmethacrylate cement with 0.5 g gentamicin (Biomet Orthopedics, Warsaw, IN) with a mixture of 3.0 g vancomycin and 3.6 g tobramycin was used for the femoral component. Antibiotic dosages were chosen based on previous studies that indicated no morbidity associated with these dosages [28–32]. The patient was repped and draped for the right hip I&D, where 70 cc of purulent material was found. Repeat irrigation



**Figure 1.** Initial anteroposterior (AP) radiograph of left hip (a) and lateral radiograph (b) showing no fracture or major bony lesion.

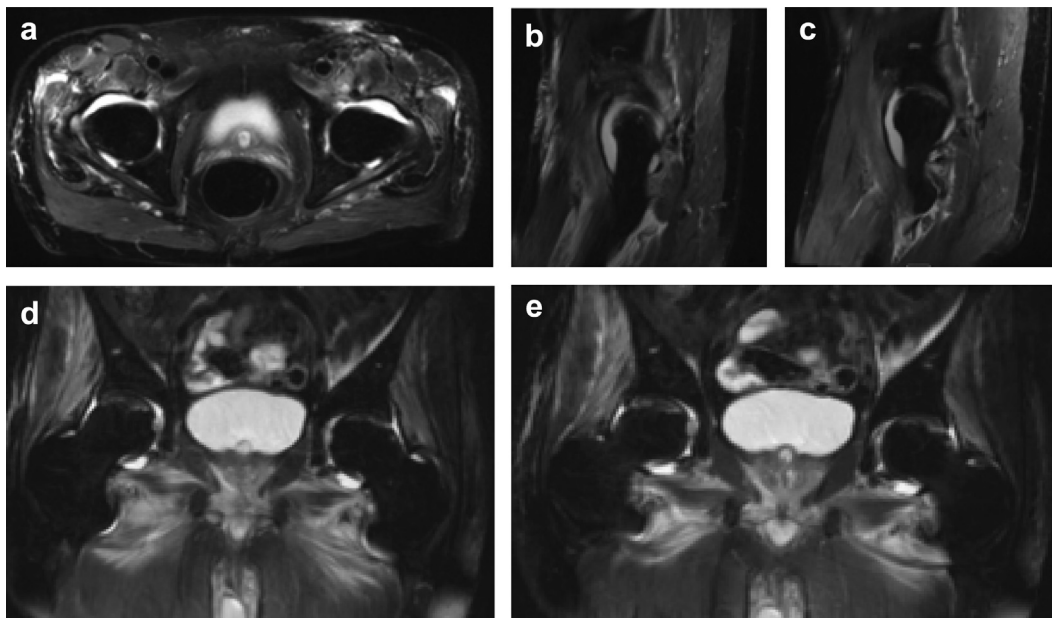


**Figure 2.** Axial computed tomography imaging without contrast of the left hip showing a moderate effusion indicated by arrows. Soft tissue window (a-c) and bone window (d and e) are shown.

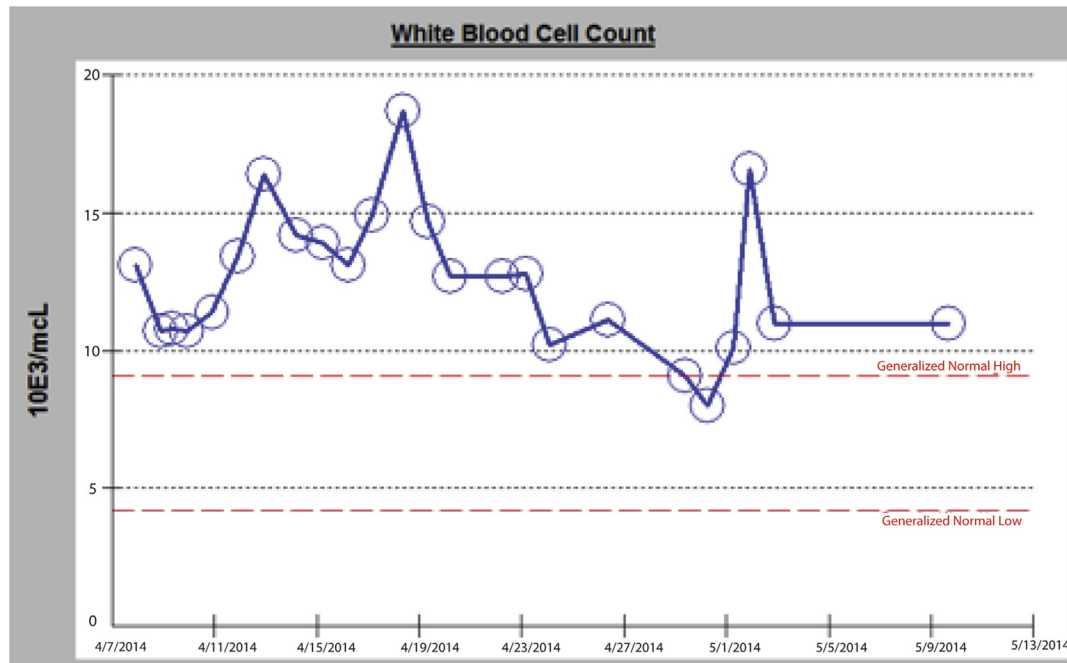
and debridement was performed on the right with closure over an intra-articular drain. Permeant pathology of the left femoral head found bone and cartilage with focal degenerative changes and acute inflammation with viable resection margins.

The repeat IR aspirations and intraoperative cultures were negative. Vancomycin and piperacillin-tazobactam were continued postoperatively with appropriate monitoring and dosing by the pharmacy. His initial creatinine on readmission was 1.0 mg/dL. On postoperative day 1, it rose to 1.39 mg/dL and continued to rise to

3.87 mg/dL on postoperative day 2. Random vancomycin level was 50.2 µg/mL. Hospital medicine and infectious disease were consulted for acute renal failure and antibiotic management. The patient was started on aztreonam and levofloxacin. He subsequently developed a cutaneous rash over the trunk and extremities. The aztreonam was subsequently discontinued. His urine output remained appropriate. Urine eosinophils were positive; his creatinine continued to rise to 5.96 mg/dL despite IV fluid hydration. Renal ultrasound was unremarkable. Nephrology diagnosed nonoliguric



**Figure 3.** Axial (a), sagittal (b and c), and coronal (d and e) T2-weighted MRI of the pelvis showing bilateral hip effusions and edema and avascular necrosis of the femoral heads.



**Figure 4.** Serum white blood cell count from initial admission with septic arthritis through hospital discharge.

acute kidney injury likely secondary to acute interstitial nephritis given his previous antibiotics of piperacillin-tazobactam and ceftriaxone, prior rash, and positive urine eosinophils. Prednisone 40 mg PO qday was initiated along with hydration goals and blood pressure goals (mean arterial pressure > 65 mmHg, systolic blood pressure > 100 mmHg) to avoid episodes of hypotension. A renal biopsy was performed showing acute interstitial nephritis with eosinophils and associated brisk interstitial fibroblastic response. In addition, acute tubular necrosis was found and toxic isometric vacuolization of the tubular epithelial cells, which nephrology thought to be due to an effect of tobramycin. At no point in the patient's course was he treated with IV tobramycin nor did he have any history of kidney disease or antibiotic sensitivity.

The patient's serum creatinine continued to rise, peaking at 6.52 mg/dL on postoperative day 8. Hemodialysis was initiated to minimize tobramycin exposure to the kidney. Despite hemodialysis over a 2-week period, his tobramycin levels remained persistently above 1 µg/mL. After discussing continued hemodialysis vs AIC explantation, the patient underwent removal of antibiotic cement and revision left hip PROSTALAC spacer with 2.5 packs of plain Cobalt polymethylmethacrylate 25 days after initial implantation. No organisms grew on repeat left hip cultures. His tobramycin level normalized after the procedure and his WBC count was within normal limits at 10,100 cells/µL (Fig. 4). His serum creatinine decreased after AIC removal to 2.67 mg/dL on postoperative day 1 and 2.4 mg/dL on postoperative day 2 (Fig. 5). Two days after AIC removal, the patient was discharged home, ambulatory with a walker with 6 weeks of oral levofloxacin.

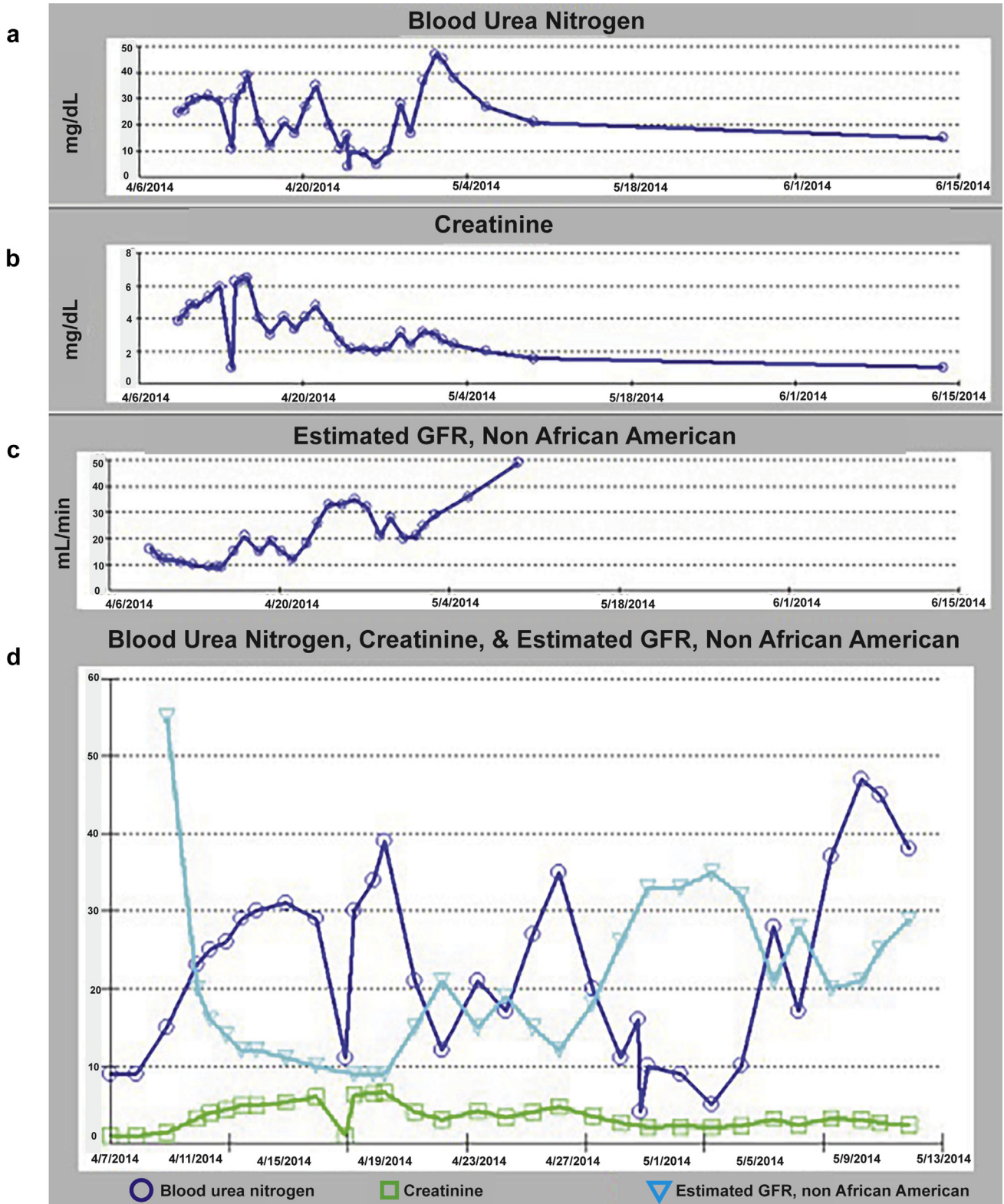
At his first clinic follow-up, he was ambulatory with a cane, had completed his cranial radiation therapy and had continued improvement of his creatinine to 1.5 mg/dL (Fig. 5). His surgical wounds were healed. By 6 weeks postop, his right hip had continued provocative pain with progressive AVN and chondrolysis while the left hip hardware was unchanged (Fig. 6a and b). Bilateral hip ultrasound-guided aspirations yielded minimal normal bloody fluid with no bacterial growth. Given his pain and symptoms, he underwent an uneventful right total hip arthroplasty. Final pathology of the femoral head was consistent with AVN without

evidence of infection. Two years postop, he is ambulating well without assist device and final radiographs show appropriate alignment of his bilateral hip arthroplasties without evidence of mechanical complication (Fig. 7).

## Discussion

With more than 250,000 joint replacements occurring in the United States each year and infections rates ranging from 1%–4%, AIC is commonly used for local antibiotic delivery to control infections. However, antibiotic spacers are not without complication as AIC-associated systemic renal toxicity is possible. James and Larson [33] described a 69-year-old female who developed elevated systemic tobramycin (5.8 µg/mL) at 24 hours postoperatively after implantation of an antibiotic spacer using Biomet Cobalt cement with 10.8 g tobramycin and 12 g vancomycin to create the spacers and 3.6 g tobramycin and 4 g vancomycin used to cement in the implants. She did not require hemodialysis but did have a prolonged 17-day hospital course and eventually underwent an above knee amputation. Combinations of vancomycin with gentamycin [34] or tobramycin with cefazolin [35] impregnated spacers can also cause acute renal failure. In contrast to findings in a study by Springer et al. [29], these studies and our report demonstrate that AIC can cause systemic toxicities.

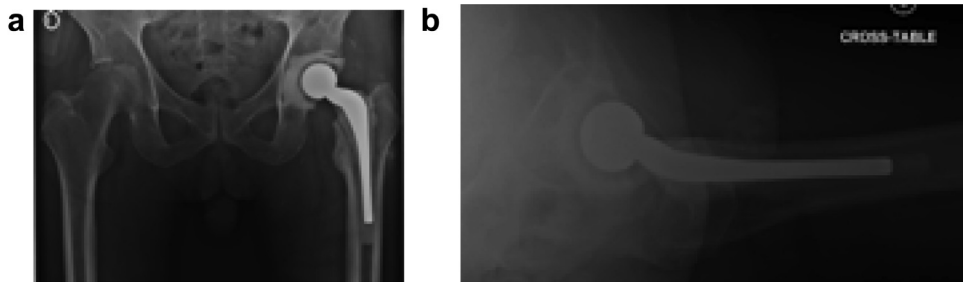
Variability in the timing and development of complications associated with AIC has been shown by Patrick et al. [36] in 2 elderly patients, who developed renal failure at 5 and 1.5 months postimplantation with elevated tobramycin levels peaking at 5.5 µg/mL and 2.9 µg/mL; both required explantation. Indeed, other studies have reported that use of at least 3.6 g tobramycin per package of cement may cause antibiotic elution for up to 4 months postimplantation [37], whereas the dose of vancomycin within the cement did not affect its elution. Furthermore, the elution of antibiotics from cement spacers may differ depending on the brand of bone cement [38]. Patient-specific risk factors, intraoperative blood transfusions, use of nonsteroidal anti-inflammatory drugs postoperatively [27] or angiotensin-converting enzyme inhibitors [39] can affect nephrotoxicity after implantation with AIC.



**Figure 5.** Blood urea nitrogen levels (a), creatinine (b), and estimated glomerular filtration rate (c) from admission through discharge and follow-up. Superimposed blood urea nitrogen, creatinine, and estimated glomerular filtration rate is shown during the same period (d).

In our case, the patient received 3.0 g vancomycin and 3.6 g tobramycin per pack of cement, in accordance with dosage recommendations from Hanssen et al. [30,31] demonstrating serum tobramycin levels lower than 3 mg/L and no evidence of renal

insufficiency in patients who received as much as 3.6 g tobramycin in each pack of cement. Furthermore, Springer et al. also reported that no renal insufficiency occurred in patients who received an average of 10.5 g vancomycin and 12.5 g gentamicin per spacer [29].



**Figure 6.** Anteroposterior pelvis radiograph (a) and cross-table lateral radiograph of left hip (b) after antibiotic spacer.

However, even with spacers containing antibiotic dosages at or below levels indicated by previous studies, renal toxicity and elevated serum tobramycin levels developed in this case within 8 days of AIC implantation requiring hemodialysis and subsequent explanation. It can be difficult to predict which patients will develop systematic toxicity from AIC, thus appropriate judgment for the type and dose of antibiotics within AIC should be used to minimize risk for these patients, especially in frail patients with more complex medical histories, as seen in our patient. Given studies indicating that high antibiotic dosages may compromise the mechanical and shear strength of cement [30,40,41], this may not only contribute to preventing future FDA approval for higher dose AIC, but may also help inform clinicians' decisions regarding antibiotic dosage. Based on our experience, we recommend random assessment of serum levels of the antibiotics used in AIC on the first postoperative day. This information should be used to guide subsequent IV antibiotic therapy as the combination of systemic

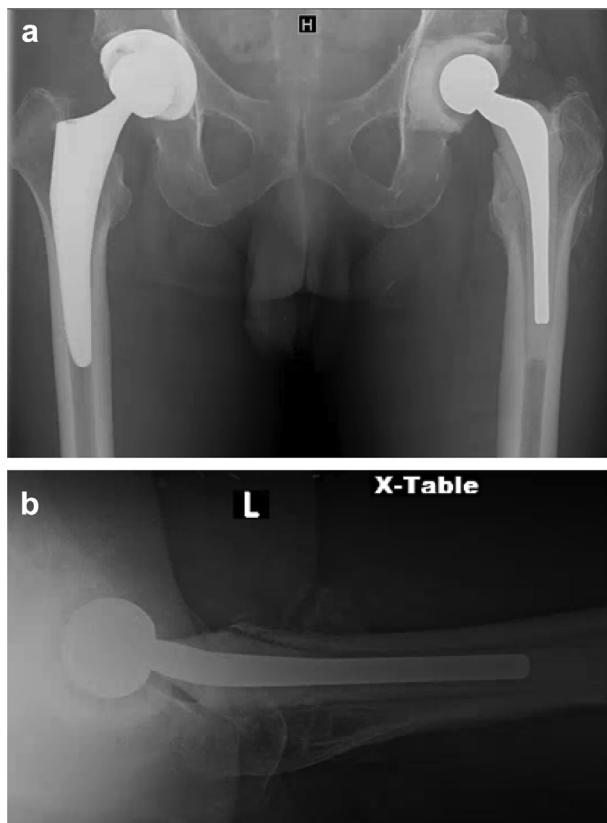
antibiotic exposure with AIC and IV therapy can pose an increased risk of antibiotic associated end organ damage.

### Summary

Acute septic arthritis with concomitant osteomyelitis can require I&D with placement of AIC. Although local antibiotic delivery via AIC has been shown to lead to minimum inhibitory concentrations above what is necessary to treat pathogens, systemic exposure to antibiotics used in AIC can pose a risk of end organ damage. Here, we report a case of acute renal failure associated with placement of AIC with tobramycin. The patient experienced elevated serum creatinine and tobramycin levels, requiring hemodialysis. Explanation of the AIC resulted in normalization of the patient's serum creatinine. Thus, this case illustrates the potential for systemic exposure to antibiotics used in AIC. Random serum levels of the antibiotic used with AIC in the early postoperative period may help guide treatment and minimize the risk of renal or other end organ toxicity.

### References

- [1] Garcia-Arias M, Balsa A, Mola EM. Septic arthritis. *Best Pract Res Clin Rheumatol* 2011;25(3):407.
- [2] Kennedy N, Chambers ST, Nolan I, et al. Native joint septic arthritis: epidemiology, clinical features, and microbiological causes in a New Zealand population. *J Rheumatol* 2015;42(12):2392.
- [3] Kaandorp CJ, Dinant HJ, van de Laar MA, et al. Incidence and sources of native and prosthetic joint infection: a community based prospective survey. *Ann Rheum Dis* 1997;56(8):470.
- [4] Gupta MN, Sturrock RD, Field M. A prospective 2-year study of 75 patients with adult-onset septic arthritis. *Rheumatology (Oxford)* 2001;40(1):24.
- [5] Nade S. Septic arthritis. *Best Pract Res Clin Rheumatol* 2003;17(2):183.
- [6] Weston VC, Jones AC, Bradbury N, Fawthrop F, Doherty M. Clinical features and outcome of septic arthritis in a single UK Health District 1982–1991. *Ann Rheum Dis* 1999;58(4):214.
- [7] Swan A, Amer H, Dieppe P. The value of synovial fluid assays in the diagnosis of joint disease: a literature survey. *Ann Rheum Dis* 2002;61(6):493.
- [8] Morgan DS, Fisher D, Merianos A, Currie BJ. An 18 year clinical review of septic arthritis from tropical Australia. *Epidemiol Infect* 1996;117(3):423.
- [9] Garcia-De La Torre I. Advances in the management of septic arthritis. *Rheum Dis Clin North Am* 2003;29(1):61.
- [10] Ross JJ. Septic arthritis. *Infect Dis Clin North Am* 2005;19(4):799.
- [11] Mathews CJ, Weston VC, Jones A, Field M, Coakley G. Bacterial septic arthritis in adults. *Lancet* 2010;375(9717):846.
- [12] Goldenberg DL. Septic arthritis. *Lancet* 1998;351(9097):197.
- [13] Tarkowski A. Infection and musculoskeletal conditions: infectious arthritis. *Best Pract Res Clin Rheumatol* 2006;20(6):1029.
- [14] Dubost JJ, Soubrier M, De Champs C, et al. No changes in the distribution of organisms responsible for septic arthritis over a 20 year period. *Ann Rheum Dis* 2002;61(3):267.
- [15] Abdelnour A, Arvidson S, Bremell T, Ryden C, Tarkowski A. The accessory gene regulator (agr) controls *Staphylococcus aureus* virulence in a murine arthritis model. *Infect Immun* 1993;61(9):3879.
- [16] Li SF, Cassidy C, Chang C, Gharib S, Torres J. Diagnostic utility of laboratory tests in septic arthritis. *Emerg Med J* 2007;24(2):75.
- [17] Eder L, Zisman D, Rozenbaum M, Rosner I. Clinical features and aetiology of septic arthritis in northern Israel. *Rheumatology (Oxford)* 2005;44(12):1559.
- [18] Mathews CJ, Kingsley G, Field M, et al. Management of septic arthritis: a systematic review. *Ann Rheum Dis* 2007;66(4):440.



**Figure 7.** The most recent anteroposterior pelvis radiograph showing appropriate right total hip arthroplasty and left cement spacer (a) and cross table lateral radiograph of left hip (b).

- [19] Vrabec G, Stevenson W, Elguizaoui S, Kirsch M, Pinkowski J. What is the intraarticular concentration of tobramycin using low-dose tobramycin bone cement in TKA: an in vivo analysis? *Clin Orthop Relat Res* 2016;474(11):2441.
- [20] Bertazzoni Minelli E, Benini A, Magnan B, Bartolozzi P. Release of gentamicin and vancomycin from temporary human hip spacers in two-stage revision of infected arthroplasty. *J Antimicrob Chemother* 2004;53(2):329.
- [21] Sterling GJ, Crawford S, Potter JH, Koerbin G, Crawford R. The pharmacokinetics of Simplex-tobramycin bone cement. *J Bone Joint Surg Br* 2003;85(5):646.
- [22] Kahlmeter G, Dahlager JI. Aminoglycoside toxicity - a review of clinical studies published between 1975 and 1982. *J Antimicrob Chemother* 1984;13(Suppl A):9.
- [23] Vance-Bryan K, Rotschafer JC, Gilliland SS, et al. A comparative assessment of vancomycin-associated nephrotoxicity in the young versus the elderly hospitalized patient. *J Antimicrob Chemother* 1994;33(4):811.
- [24] Goetz MB, Sayers J. Nephrotoxicity of vancomycin and aminoglycoside therapy separately and in combination. *J Antimicrob Chemother* 1993;32(2):325.
- [25] Courtney PM, Melnic CM, Zimmer Z, Anari J, Lee GC. Addition of vancomycin to cefazolin prophylaxis is associated with acute kidney injury after primary joint arthroplasty. *Clin Orthop Relat Res* 2015;473(7):2197.
- [26] Luu A, Syed F, Raman G, et al. Two-stage arthroplasty for prosthetic joint infection: a systematic review of acute kidney injury, systemic toxicity and infection control. *J Arthroplasty* 2013;28(9):1490.
- [27] Aeng ES, Shalansky KF, Lau TT, et al. Acute kidney injury with tobramycin-impregnated bone cement spacers in prosthetic joint infections. *Ann Pharmacother* 2015;49(11):1207.
- [28] Penner MJ, Masri BA, Duncan CP. Elution characteristics of vancomycin and tobramycin combined in acrylic bone-cement. *J Arthroplasty* 1996;11(8):939.
- [29] Springer BD, Lee GC, Osmon D, et al. Systemic safety of high-dose antibiotic-loaded cement spacers after resection of an infected total knee arthroplasty. *Clin Orthop Relat Res* 2004;(427):47.
- [30] Jiranek WA, Hanssen AD, Greenwald AS. Antibiotic-loaded bone cement for infection prophylaxis in total joint replacement. *J Bone Joint Surg Am* 2006;88(11):2487.
- [31] Hanssen AD, Spangehl MJ. Practical applications of antibiotic-loaded bone cement for treatment of infected joint replacements. *Clin Orthop Relat Res* 2004;(427):79.
- [32] Hanssen AD. Prophylactic use of antibiotic bone cement: an emerging standard—in opposition. *J Arthroplasty* 2004;19(4 Suppl 1):73.
- [33] James A, Larson T. Acute renal failure after high-dose antibiotic bone cement: case report and review of the literature. *Ren Fail* 2015;37(6):1061.
- [34] Dovas S, Liakopoulos V, Papatheodorou L, et al. Acute renal failure after antibiotic-impregnated bone cement treatment of an infected total knee arthroplasty. *Clin Nephrol* 2008;69(3):207.
- [35] Curtis JM, Sternhagen V, Batts D. Acute renal failure after placement of tobramycin-impregnated bone cement in an infected total knee arthroplasty. *Pharmacotherapy* 2005;25(6):876.
- [36] Patrick BN, Rivey MP, Allington DR. Acute renal failure associated with vancomycin- and tobramycin-laden cement in total hip arthroplasty. *Ann Pharmacother* 2006;40(11):2037.
- [37] Masri BA, Duncan CP, Beauchamp CP. Long-term elution of antibiotics from bone-cement: an in vivo study using the prosthesis of antibiotic-loaded acrylic cement (PROSTALAC) system. *J Arthroplasty* 1998;13(3):331.
- [38] Stevens CM, Tetsworth KD, Calhoun JH, Mader JT. An articulated antibiotic spacer used for infected total knee arthroplasty: a comparative in vitro elution study of Simplex and Palacos bone cements. *J Orthop Res* 2005;23(1):27.
- [39] Reed EE, Johnston J, Severing J, Stevenson KB, Deutscher M. Nephrotoxicity risk factors and intravenous vancomycin dosing in the immediate postoperative period following antibiotic-impregnated cement spacer placement. *Ann Pharmacother* 2014;48(8):962.
- [40] Seldes RM, Winiarsky R, Jordan LC, et al. Liquid gentamicin in bone cement: a laboratory study of a potentially more cost-effective cement spacer. *J Bone Joint Surg Am* 2005;87(2):268.
- [41] Moran JM, Greenwald AS, Matejczyk MB. Effect of gentamicin on shear and interface strengths of bone cement. *Clin Orthop Relat Res* 1979;(141):96.