

# Cryoglobulinemia revealed by a Purtscher-like retinopathy

Arnaud Sauer<sup>1</sup>  
 Xavier Nasica<sup>2</sup>  
 Frédérique Zorn<sup>3</sup>  
 Philippe Petitjean<sup>4</sup>  
 Patrick Bader<sup>5</sup>  
 Claude Speeg-Schatz<sup>1</sup>  
 Patrick Lenoble<sup>2</sup>

<sup>1</sup>Department of Ophthalmology, Hôpitaux universitaires de Strasbourg, Strasbourg, France; <sup>2</sup>Department of Ophthalmology, Centre hospitalier de Mulhouse, France; <sup>3</sup>Department of Cardiology, Hôpitaux universitaires de Strasbourg, France; <sup>4</sup>Department of Nephrology, Centre hospitalier de Mulhouse, France; <sup>5</sup>Department of hepatology, Centre hospitalier de Mulhouse, France

**Purpose:** To demonstrate the importance of collaboration between ophthalmologists and internists.

**Design:** Cryoglobulinemia is a systemic vascularite. Ophthalmologic complications are rare and not well known. Purtscher-like retinopathy may occur in this context.

**Case report:** We report the case of a patient who presented a severe visual loss in the course of a hepatitis C. The ophthalmic examination shows a both ischemic and hemorrhagic bilateral retinopathy called Purtscher-like retinopathy. Cryoglobulinemia complicating a hepatitis C was discovered in our patient.

**Conclusions:** This case illustrates a cryoglobulinemia complicating by a Purtscher-like retinopathy. The diagnosis has been possible thanks to collaboration between ophthalmologists and internists.

We propose a few hypotheses to explain retinopathy pathogeny.

**Keywords:** cryoglobulinemia, hepatitis C, Purtscher-like retinopathy, visual loss

## Introduction

Cryoglobulinemia is defined by presence of serum immunoglobulines that precipitate with cold temperature and resolubilize during warming. They are part of systemic vascularites by immune complex agents often linked to chronical infectious diseases as hepatitis C.

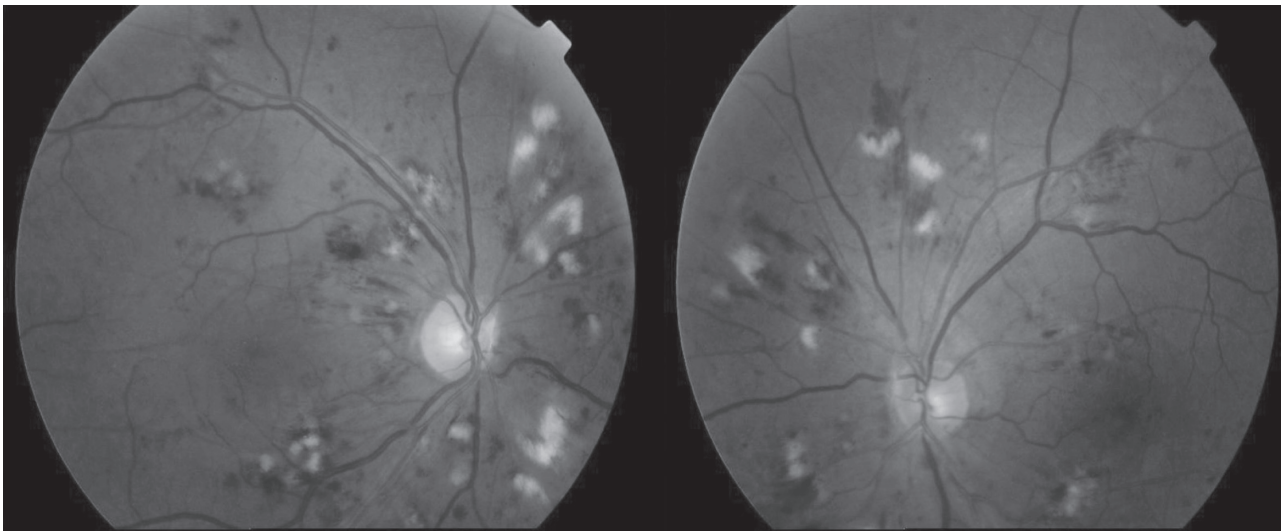
We study the case of a Purtscher-like retinopathy associated with cryoglobulinemia appeared with the waning of a hepatitis C.

## Case report

A 47-year-old man complained about visual loss for some weeks in a context of hepatitis C. Visual acuity was 20/50 (Snellen 20 feet) (OD) and 20/25 (OS). Bilateral fundoscopic examination revealed both retinal ischemic infarcts (cotton-wool spots) and flame-shaped hemorrhages (Figure 1). Angiofluorography (Figure 2) showed a diffusion of coloring agent from arterioles, capillaries and venules in the aerie of white retinal lesions. Examination by optical coherence tomography reveals the presence of a slight of the neuroepithelium of the right eye. Both the A-waves and B-waves of the mfERG were depressed suggesting damage to both outer and inner retinal layers.

The patient's medical history revealed active chronic hepatitis C. We noticed ascite, bilateral leg edema, blood pressure 180/100 mmHg by admission (there was no history of hypertension before). Biological exams revealed creatinine clearance 45 mL/mn showing acute renal insufficiency (creatinine clearance >60 mL/mn before) but normal pancreatic enzymes. Platelets were 265,000/mm<sup>3</sup> excluding thrombocytopenic purpura. The renal biopsy concluded in membranoproliferative glomerulonephritis with intravascular deposits of polyclonal Ig. The C4 fraction had collapsed in the

Correspondence: Arnaud Sauer  
 Service d'Ophthalmologie, Hôpitaux universitaires de Strasbourg, 1 Place de l'hôpital, BP 426, 67091 Strasbourg Cedex, France  
 Tel +33 3 88 11 62 58  
 Fax +33 3 88 11 63 55  
 Email arnaud.sauer@chru-strasbourg.fr



**Figure 1** Purtscher-like retinopathy fundoscopic examination. Whitening of superficial retina, cotton-wool spots and hemorrhages encircling disks which are normal.

serum. Finally, the research of a cryoglobulinemia turned out to be positive.

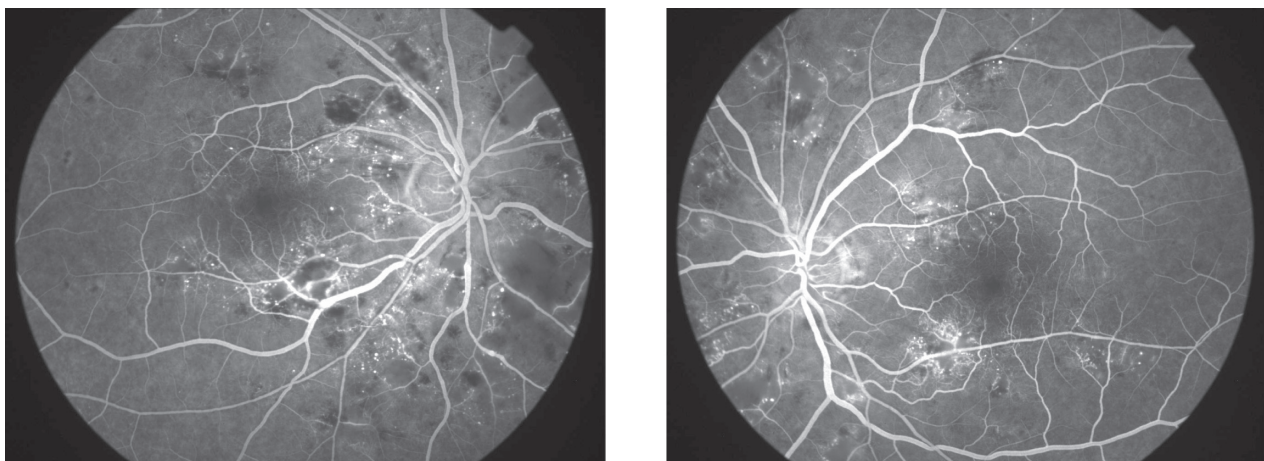
The treatment of the vascularite being that of its etiology, an association of pegylated interferon and ribavirine and an anti-hypertensive treatment by nicardipine allowed a total recovery of visual acuity in 6 months. Fundoscopic examination was quasi normal (Figure 3). The treatment also allowed an improvement of the general state both on clinical and biological aspect.

## Discussion

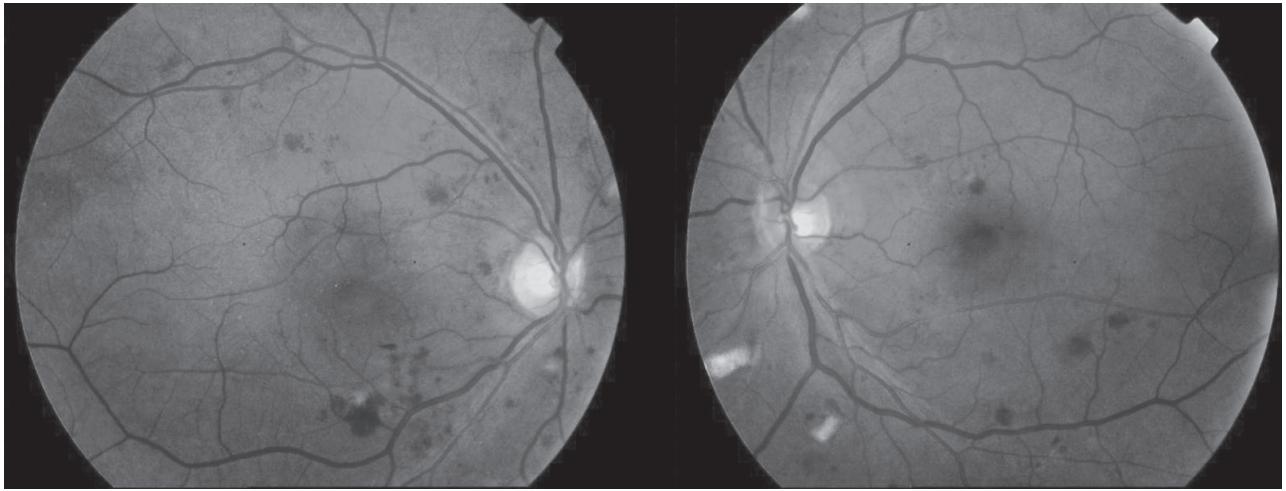
The Purtscher retinopathy fundoscopic aspect is rather unequivocal; the most-prevalent bilateral signs include white ischemic infarcts (cotton-wool spots) and hemorrhages (dot and blot, pre-retinal, or flame). It is usually associated

with cephalic or thoracic compression. Similar lesions (Purtscher-like retinopathy), were also noticed during pancreatitis, collagenoses, vascularites (Agrawal 2006).

The clinical appearance would suggest embolic occlusion of the pre-capillary arterioles as the most likely pathogenesis, although other factors may also contribute. Pathogenic mechanisms remain very controversial and reflect the multiplicity of etiologies (blood pressure, embolism, vascularite). Initial attack may be on vascular endothelium. Secondly, disseminated intravascular coagulation or agglomeration of granulocytes in the retinal vascular tree give arterioles blockage. Recently, leucocytes intravascular agglomeration, accomplishing micro-thrombi, in reply to an abnormal activation of complement was recalled as possible reason of Purtscher-retinopathy (Myers 2001). Multifocal



**Figure 2** Purtscher-like retinopathy fluorescein angiography. Diffusion of fluorescein from arterioles, capillaries and retinal venules in the aerie of white retinal lesions.



**Figure 3** Fundoscopic examination after 3 months treatment. Quasi-disappearing of cotton-wool spots and reduction of hemorrhages.

ERG suggests damage to outer and inner retinal layers (Haq 2002).

In this case report, VHC infects lymphoid cells and causes lymphocytes B mono or polyclonal proliferation with production of antibodies (including cryoglobulins) conducting to deposits of immune complex and circulating complement in the vessels of small calibre (Iguchi 1996). The ocular localization is a rare form. Our clinical case puts in an obvious place the association between hepatitis C and retinopathy caused by deposits of cryoglobulins. This relation is rare enough to be reminded as well as the

importance of the collaboration between ophthalmologists and internists.

## References

- Agrawal A, McKibbin MA. 2006. Purtscher's and Purtscher-like retinopathies: a review. *Surv Ophthalmol*, 51:129–36.
- Haq F, Vajaranant TS, Szlyk JP, et al. 2002. Sequential multifocal electroretinogram findings in a case of Purtscher-like retinopathy. *Am J Ophthalmol*, 134:125–8.
- Iguchi S, Toba K, Fuse I, et al. 1996. Severe cryoglobulinemia in a patient with asymptomatic hepatitis C virus infection. *Intern Med*, 35:712–16.
- Myers JP, Di Bisceglie AM, Mann ES. 2001. Cryoglobulinemia associated with Purtscher-like retinopathy. *Am J Ophthalmol*, 131:802–4.

