



Case report

Endobronchial lipoma causing progressive dyspnea

Rajany V. Dy^{a,*}, Sumit Patel^a, Kassem Harris^b, M. Jeffery Mador^{a,c}^a Department of Medicine, Division of Pulmonary, Critical Care and Sleep Medicine, University at Buffalo, State University of New York, USA^b Department of Thoracic Oncology, Roswell Park Cancer Institute, Buffalo, NY, USA^c Western New York Veterans Administration Healthcare System, 3495, Bailey Avenue, Buffalo, NY, USA

ARTICLE INFO

Article history:

Received 22 February 2017

Received in revised form

5 July 2017

Accepted 5 July 2017

Keywords:

Endobronchial lipoma

Snare electrocautery

Therapeutic bronchoscopy

ABSTRACT

We describe a 63-year-old male who presented with progressive exertional dyspnea, post-obstructive pneumonia and chest CT findings of an endobronchial lesion. Bronchoscopy revealed an endobronchial lipoma, which was resected using snare electrocautery. Complete resolution of the patient's symptoms was noted following bronchoscopic resection.

© 2017 The Authors. Published by Elsevier Ltd. This is an open access article under the CC BY-NC-ND license (<http://creativecommons.org/licenses/by-nc-nd/4.0/>).

1. Introduction

Tumors involving the tracheobronchial tree are usually malignant. Benign pulmonary tumors are rare, and endobronchial lipomas represent about 0.1%–0.5% of all lung tumors [1].

2. Case vignette

A 63-year-old man was referred to the pulmonary clinic for abnormal Chest Computed Tomography (CT) findings. He was recently treated for pneumonia and a chest CT performed at that time revealed an endobronchial lesion in the left main bronchus (Fig. 1). He had undergone bronchoscopy with bronchial brushings at a different facility. The results were reported as negative for malignancy. Since then, he had been complaining of progressive exertional dyspnea with no other symptoms of cough, sputum production, chest discomfort or hemoptysis. Repeat imaging showed that the left main-stem endobronchial lesion had not changed in size. The patient had a 30-pack year smoking history, and no family history of lung cancer. No abnormalities were noted on physical examination. His vital signs were within normal range with no evidence of hypoxia.

Flexible bronchoscopy revealed an occluded left mainstem bronchus that was completely occupied with an endobronchial tumor (Fig. 2). The tumor had a rounded, smooth and shiny surface

with an area of vascularity. The flexible scope was passed through the obstruction with minimal resistance and thick secretions were suctioned from the distal airways.

A snare electrocautery was used to ablate the tumor in pieces, which were then removed using flexible forceps. The forceps was also used for tumor debulking. Argon plasma coagulation (APC) was then used to ablate the tumor bed. At the end of the procedure, the airway was completely patent (Fig. 3). Bleeding was minimal and self-limited and did not require administration of cold saline or epinephrine.

Histopathological examination of the extracted tumor showed fatty tissue with areas of benign bronchial mucosa consistent with lipoma (Fig. 4).

3. Discussion

Endobronchial lipomas are rare, benign tumors that are mainly found in men, with an average age of 60 years. The majority of endobronchial lipomas are located on the right and are usually seen within the first three subdivisions [2]. These rare tumors arise from the submucosal layer of the bronchus, which has fat tissue in its walls. Endobronchial lipomatous hamartomas, however, originate from bronchial wall mesenchymal tissue and contain adipose, cartilage, fibrous, and epithelial elements [3]. The gross appearance of endobronchial lipomas is usually soft, rounded, circumscribed with yellow white tissue and with little to no vascularization [4].

Postulated risk factors for developing endobronchial lipomas are heavy smoking history and obesity [2]. However, on the basis of

* Corresponding author.

E-mail addresses: rajany.dy.md@gmail.com, rajanydy@buffalo.edu (R.V. Dy).

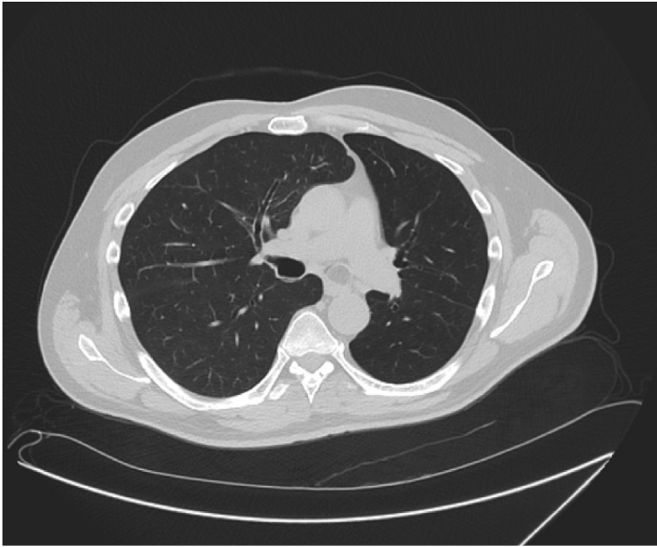

Fig. 1. Computed Tomography (CT) of the chest showing the obstructing endobronchial lesion in the left mainstem bronchus.

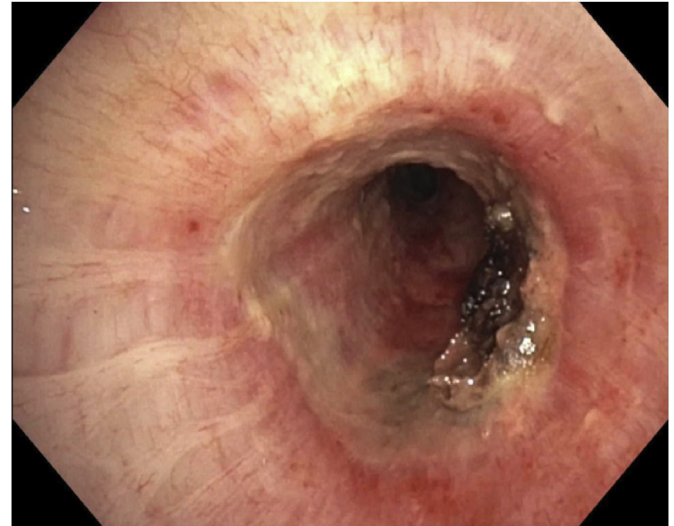


Fig. 3. Patent left mainstem bronchus after removal of endobronchial tumor.

published reports, the occurrence of endobronchial lipomas in association with cigarette smoking is unclear. Patients complain of unrelenting cough, hemoptysis, exertional dyspnea, fever, chest discomfort or recurrent pneumonias. Several case reports describe endobronchial lipomas mimicking symptoms of asthma, COPD or carcinoid tumors. However, up to 25% of cases may be asymptomatic [5].

The diagnosis of endobronchial lipomas can be suggested with fat attenuation on chest CT (Hounsfield Units between 70 and 140) and lack of enhancement after contrast administration [6]. In contrast, endobronchial hamartomas usually appear as collections of fat alternating with foci of calcification [3].

Once the diagnosis is made, treatment options include either thoracotomy or bronchoscopic resection. The decision between the two modalities depends on the tumor size and the degree of lung damage distal to the tumor. Endoscopic therapy is the treatment of choice using laser, cryotherapy, or electrocautery with mechanical debulking [2,7,8]. Indications for endoscopic resection include an endoluminal tumor in a central location with limited extension into the endobronchial tree. Thoracotomy should be reserved for when there is extraluminal extension, uncertain tumor etiology or parenchymal destruction due to atelectasis and long-standing pneumonitis [7,9]. In a study conducted by Nassiri et al. enrolling 38 patients, laser and mechanical debulking were performed in 29 cases, cryotherapy and mechanical debulking in seven patients, and

mechanical debulking alone in 2 patients. No cases of recurrence were detected during the follow up period [10]. Their study suggested that endoscopic resection should be considered first, after a full clinical and radiological evaluation had been completed, in subjects who were symptomatic but had no evidence of severe

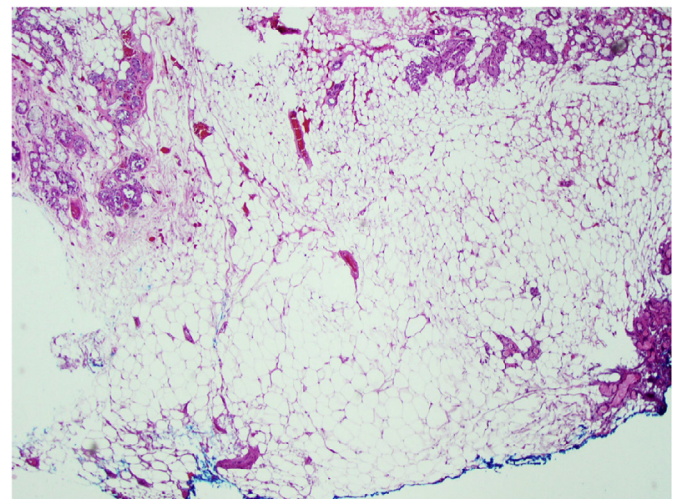


Fig. 4. Microscopic image of the removed endobronchial tumor showing fatty tissue (Hematoxylin and Eosin).

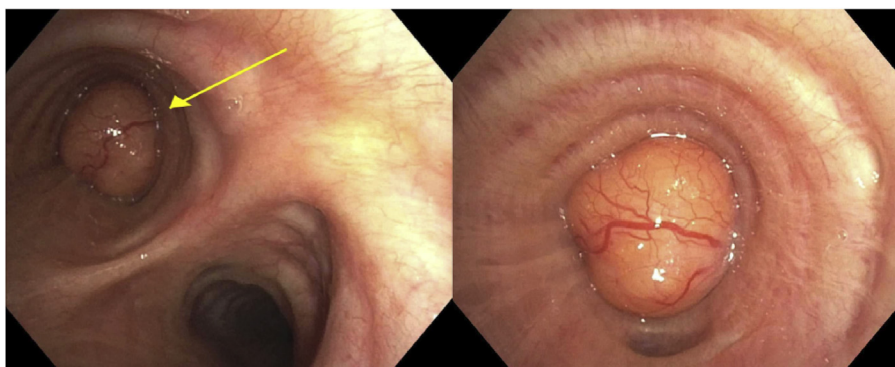


Fig. 2. Endobronchial tumor obstructing the left mainstem bronchus next to an accessory airway.

distal bronchiectasis or permanent lung damage distal to the tumor. The presence of significant airway obstruction in association with the patient's symptoms prompted the decision for resection. Since there were minimal post-obstructive parenchymal changes seen radiologically, we elected to perform bronchoscopic resection using snare electrocautery.

The patient had significant improvement of his dyspnea after the resection. On a follow-up telephone encounter after 2 months, the patient reported that his functional status had returned to normal. In view of the possibility of long-term relapse, a repeat bronchoscopy was arranged in 6 months.

4. Conclusion

Endobronchial lipomas are rare benign tumors that can present insidiously. The extent of airway obstruction determines the clinical symptoms and the type of intervention needed. Based on previous case reports, the prognosis appears favorable with minimal rates of recurrence. Some authors, given the possibility of relapse, recommend careful monitoring following resection.

Support

None.

Disclaimers

None.

References

- [1] M.S. Jensen, A.H. Petersen, Bronchial lipoma, *Scand. Thorac. Cardiovasc Surg.* 4 (1970) 131–134.
- [2] M. Muraoka, T. Oka, S. Akamine, T. Nagayasu, M. Iseki, N. Suyama, et al., Endobronchial lipoma: review of 64 cases reported in Japan, *Chest* 123 (1) (2003) 293–296.
- [3] S. Nurhan, A. Susur, T. Goskel, S. Paksoy, F. Erel, An unexpected cause of hemoptysis: endobronchial lipomatous hamartoma, *Med. Arch.* 68 (1) (2014) 65–66.
- [4] Dianbo Cao, Yutian Sun, Sirui Yang, Endobronchial lipoma: an unusual cause of bronchial obstruction, *Case Rep. Med.* (2011), 939808, <http://dx.doi.org/10.1155/2011/939808>, 4 pages, 2011.
- [5] C. Huisman, K.W. Van Kralingen, P.E. Postmus, T.G. Sutedja, Endobronchial lipoma: a series of three cases and the role of electrocautery, *Respiration* 67 (2000) 689–692.
- [6] E. Rodriguez, F. Pombo, C. Gallego, et al., Endobronchial lipoma. Computed tomography and magnetic resonance, *Chest* 105 (1994) 1628.
- [7] Carlos Galvez, et al., Single-incision video-assisted anatomical segmentectomy with handsewn bronchial closure for endobronchial lipoma, *Ann. Transl. Med.* 4.15 (2016) 284. PMC. Web. 21 Nov. 2016.
- [8] K. Harris, S. Dhillon, M. Huang, A. Kumar, J. Qui, Endobronchial Lipoma: bronchoscopy, imaging, and pathology, *Ther. Adv. Respir. Dis.* 8 (5) (Oct 2014) 162–164.
- [9] C.T. Bolliger, T.G. Sutedja, J. Strausz, L. Freitag, Therapeutic bronchoscopy with immediate effect: laser, electrocautery, argon plasma coagulation and stents, *Eur. Respir. J.* 27 (6) (2006) 1258–1271.
- [10] A.H. Nassiri, H. Dutau, D. Breen, A. Colchen, J.J. Quiot, B. Nguyen, et al., GELF Grouped' Endoscopie de Langue Francaise. A multicenter retrospective study investigating the role of interventional bronchoscopic techniques in the management of endobronchial lipomas, *Respiration* 75 (1) (2008) 79–84.