

Teaching Point
(Section Editor: A. Meyrier)

Neurogenic pulmonary oedema post-haemodialysis

Andrew Davenport

Center for Nephrology, Hampstead Campus, Royal Free & University College Medical School, London NW3 2PF, UK

Keywords: cerebral oedema; intermittent haemodialysis; neurogenic pulmonary oedema; paracetamol acetaminophen

Introduction

Pulmonary oedema can develop due to many causes (Table 1). In the patient with renal failure, pulmonary oedema typically occurs in the setting of raised pulmonary arterial pressure due to extracellular fluid expansion, due to a combination of excessive inter-dialytic weight gain and failure to achieve 'dry' or 'post-dialysis target' weight, often associated with cardiac dysfunction. However, increased lung interstitial fluid can also occur in conditions, typified by normal pulmonary arterial pressures.

Pulmonary complications are well recognized in both acute and chronic liver failure. Excessive pulmonary vasodilatation, in combination with high levels of vasopressin, catecholamines and sympathetic nervous system activity, leads to shunting, with increased V/Q mismatch, termed the hepatopulmonary syndrome [1]. In addition, increased circulating endotoxin and pro-inflammatory cytokines lead to increased pulmonary endothelial activation and increased pulmonary interstitial fluid formation [2]. This can be exacerbated by a concomitant reduction in plasma colloid oncotic pressure.

In cases of neurogenic pulmonary oedema, pulmonary hydrostatic pressure and endothelial activation combine to increase lung interstitial water [3]. A case of acute pulmonary oedema occurring after intermittent haemodialysis treatment is reported in a patient, 9 days after paracetamol (acetaminophen) self-poisoning, due to neurogenic pulmonary oedema.

Case

A 30-year-old woman was transferred 2 days after taking 50 g paracetamol (acetaminophen), with deteriorating liver

function, lactate 13 mmol/l (normal <2.0), prothrombin time 91.7 s (normal <12), international normalized prothrombin ratio (INR) 8.0, ALT 9964 IU/l (normal <42), AST 9581 IU/l (normal <42), urea 13.1 mmol/l and creatinine 235 μ mol/l. She was hyperventilating but not clinically encephalopathic. Continuous haemodiafiltration was started, as she had become oliguric, and she received standard supportive care for acute liver failure in the intensive care unit (ICU). Her condition stabilized then improved; 4 days later she was transferred to the liver ward, with an INR of 1.7. The patient remained oliguric, tachycardic with a blood pressure of 100/60 mmHg. Over the following 24 h, the serum creatinine increased from 148 to 275 μ mol/l, and then to 328 μ mol/l the day after, despite a fluid challenge. In view of the rising serum creatinine and potassium (Table 2), it was decided to haemodialyse the patient some 9 days after the original overdose, using a midflux polysulfone dialyzer (Fresenius F80, Bad Homburg, Germany), primed with isotonic (0.9%) saline, dialysate sodium 142 mmol/l, potassium 1.0 mmol/l, calcium 1.35 mmol/l, bicarbonate 35 mmol/l, temperature 35°C and dialysate flow 800 ml/min. No anticoagulation was used. The blood flow rate was 220 ml/min, and the net ultrafiltration was 600 ml. Prior to dialysis her blood pressure was 160/94 mmHg, with a sinus tachycardia of 126/min, the INR was 1.6, serum bicarbonate 21 mmol/l and albumin 28 g/l. During the 3-h dialysis session, the minimum blood pressure recorded was 155/95 mmHg and the peripheral oxygen saturation was maintained at 97–98%.

Towards the end of haemodialysis treatment she became agitated and complained of increasing dyspnoea. Her dyspnoea became progressively worse, as did her mental state. She was noted to have a third heart sound, and had widespread wheezing throughout her lung fields. A chest X-ray showed florid pulmonary oedema (Figure 1), and despite 15 l oxygen/min, she was hypoxic, PaO₂ 9.3 kPa (normal 12–14.5) [70 mmHg, normal 90–109], PaCO₂ 5.9 kPa (normal 4.7–6.0) [44 mmHg, normal 35–45], pH 7.34 (normal 7.35–7.45) with a base excess of –4.6 (normal \pm 2) and a lactate of 5.4 mmol/l (normal <2.0).

The patient was transferred to the ICU, intubated, ventilated and continuous haemodiafiltration recommenced. Non-invasive cardiac monitoring estimated a cardiac output of >11.0 l/min. She was extubated after 2 days and

Correspondence and offprint requests to: Andrew Davenport, Center for Nephrology, Hampstead Campus, Royal Free & University College Medical School, London NW3 2PF, UK; E-mail: Andrew.davenport@royalfree.nhs.uk

Table 1. Causes of pulmonary oedema

	↑ HP	↓ OP	↑ EP	↓ LD	↓ IP	↓ SA
Multi-organ failure	+++	+++	+++	++	-	+
Liver failure	++	+++	+++	-	-	-
Kidney failure	++	+	+++	-	-	-
Neurogenic oedema	+++	+	+++			
Volume overload	+++	+				
Pulmonary embolus	+++	-	+++	-	-	-
Heart failure	+++	+	++	-	-	-
Carcinomatosis	-	++	++	+++	-	-
High altitude oedema	+++	+	+++	-	-	-
Re-expansion oedema	+	-	+++	-	+++	-

HP = hydrostatic pressure, OC = oncotic pressure, EP = endothelial permeability, LD = lymphatic drainage, IP = interstitial pressure, SA = surfactant.

Table 2. Pre- and immediately post-dialysis blood test results

	Pre-dialysis	Post-dialysis	6-h post-dialysis
Sodium (mmol/l)	132	139	135
Potassium (mmol/l)	6.0	4.1	5.2
Urea (mmol/l)	17.2	9.6	11.2
Creatinine (μ mol/l)	328	205	234
Glucose (mmol/l)	6.4	4.2	5.4
Osmolality (mOsm/kg)	299.6	300	297

Osmolality = (sodium + potassium) * 2 + glucose + urea.

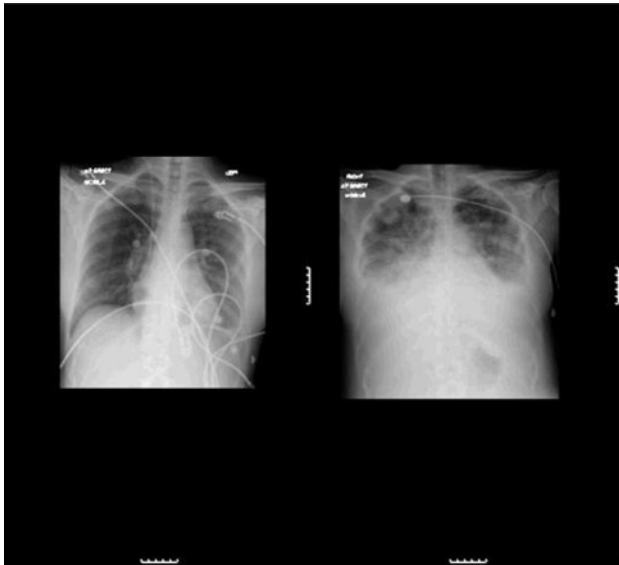


Fig. 1. (a) Chest X-ray taken on first ICU discharge, 2 days prior to dialysis. (b) Chest X-ray taken post-dialysis showing gross pulmonary oedema.

renal support withdrawn after 3 days, as her urine output increased. However, she remained confused and was noted to have dysconjugate eye movements. A CT brain scan noted a posterior encephalopathy, due to increased vascular permeability (Figure 2). Over the next few days her condition improved and she was discharged home, with no clinically apparent neurological sequelae.

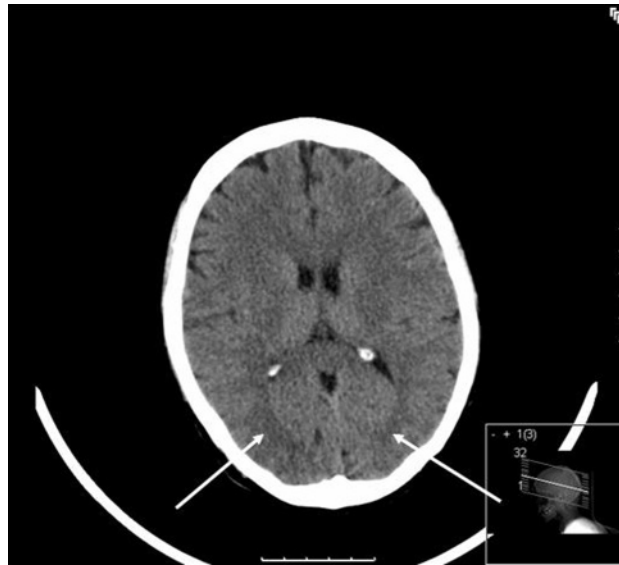


Fig. 2. CT scan showing brain stem swelling (arrows). Patients with acute hepatic necrosis are susceptible to brain stem swelling [11] due to breakdown of the endothelial integrity of the blood–brain barrier. Cerebral white matter oedema due to increased endothelial permeability in the subtentorial compartment is termed posterior encephalopathy.

Discussion

In routine nephrological practice, the most common cause of pulmonary oedema in haemodialysis patients is an increase in lung hydrostatic pressure due to extracellular fluid overload, often in combination with left ventricular dysfunction. However, oedema can also result from pulmonary endothelial inflammation, and increased permeability, due to infections, vasculitis, drugs and blood products, toxins, irradiation and both hepatic and severe uraemia [1]. Occasionally oedema follows pulmonary lymphatic obstruction, marked reduction in plasma colloid pressure and alveolar septal tissue interstitial pressure (Table 1). Neurogenic oedema follows marked sympathetic vasoconstriction, due to ischaemic damage to the nucleus of the tractus solitarius in the medulla and/or its connections to the hypothalamus. As a consequence of systemic vasoconstriction, blood is shifted from the systemic to the pulmonary circulation, resulting in severe pulmonary hypertension, which is exacerbated by pulmonary venous constriction, further increasing pulmonary capillary hydrostatic pressure. This initially leads to hydrostatic oedema, followed by endothelial damage and increased local permeability [3].

Cerebral oedema is a well-recognized feature of acute liver failure, particularly following paracetamol (acetaminophen) self-poisoning [4]. Cerebellar herniation is a recognized cause of death in acute liver failure [5], and in our patient, when sedatives had worn off, she had dysconjugate gaze due to brain stem compression. Typically liver damage is greatest some 3–4 days after the overdose, and then starts to resolve in those patients who survive without liver transplantation [4]. In addition to the effects of acute severe liver failure on renal function, one of the metabolites of paracetamol (acetaminophen), *N*-acetyl-*p*-benzoquinone, is toxic to the renal tubules and can lead to

acute kidney injury in patients who do not develop severe liver failure, typically 7–10 days following the overdose [6].

Although this patient had ingested a potentially lethal amount of paracetamol (acetaminophen), she was brought to a local hospital a few hours after the overdose, and promptly treated with *n*-acetylcysteine, which was continued during her first ICU stay. Prolonging the administration of *n*-acetylcysteine has been shown to both reduce the severity of acute liver injury and improve spontaneous recovery [4].

Routine intermittent haemodialysis is well recognized as causing mild cerebral swelling in patients with established chronic kidney disease attending for regular outpatient haemodialysis. However, in patients with pre-existing cerebral oedema, such as those with acute liver failure, intermittent haemodialysis and/or filtration can potentially result in brain coning and death, due to exacerbation of the oedema [7]. There are several theories as to the aetiology of increased cerebral oedema. During intermittent haemodialysis, plasma urea falls rapidly during the first two hours of treatment [8]. The transfer of urea across cell membranes is some 20 times slower than that of water [9]. Thus, although there is a rapid fall in plasma urea concentration, tissue urea concentrations lag behind, setting up an oncotic pressure gradient, allowing diffusion of water back into tissues, to equalize the osmotic pressure gradient. In addition, the rapid infusion of supraphysiological concentrations of bicarbonate from the dialysate [10] increases plasma pH, but as bicarbonate is charged, it does not readily cross cell membranes. This allows for an imbalance between bicarbonate and carbon dioxide concentrations, with the paradoxical development of an intracellular acidosis, leading to respiratory centre depression, and breakdown of intracellular moieties to buffer the intracellular acidosis [11]. This again leads to increased osmotic gradient and further intracellular water accumulation.

In acute liver failure, the brain is more susceptible to cerebral oedema, due to the combination of a very high blood flow with endothelial damage, compromising the integrity of the blood–brain barrier [12]. In this case, the patient had developed a posterior encephalopathy, due to increased vascular permeability. As space in the sub-tentorial compartment is very limited, only minor brain swelling causes symptoms. Many years ago, it was well recognized that patients with acute liver failure could die due to cerebellar herniation, due to increased pressure in the sub-tentorial compartment [13]. In this case, increased pressure in this area led to brain stem compression with consequent neurogenic oedema, and during subsequent recovery the patient was noted to have dysconjugate eye movements. In cases of acute liver failure, the cerebral circulation may be thus compromised, such that forced ultrafiltration can lead to a reduction in cerebral blood flow, with a rebound surge in intracranial pressure following critical reductions in the cerebral perfusion pressure [14].

Hypotension is a relative common complication of intermittent haemodialysis [14], and hypotension can lead to a reduction in cerebral blood flow in patients with acute liver failure. Several authors have reported that a bundle of

treatments during haemodialysis can lead to an improvement in cardiovascular stability in critically ill patients treated by intermittent haemodialysis [15,16]. This approach was followed by using a high sodium dialysate compared to the plasma sodium, in conjunction with cooled dialysate, synthetic bio-compatible membrane and slow blood flow rates, with an ultrafiltration rate of 200 ml/h, and no anticoagulation. As such, there was no difference in calculated serum osmolality following the dialysis session. However despite this, the patient deteriorated rapidly, due to increased vasogenic oedema in the hind brain, resulting in neurogenic pulmonary oedema.

Thus, although this patient was some 9 days after the paracetamol (acetaminophen) self-poisoning episode, and clinically did not have any signs of hepatic coma, the brain had not fully recovered, and was still susceptible to haemodialysis-induced damage. Previous studies following paracetamol (acetaminophen) self-poisoning have also noted patient deaths from cerebral oedema, despite patients initially appearing to have a good prognosis [5]. Low volume continuous modes of renal replacement therapy cause much fewer changes in intracranial pressure and are to be preferred in cases of patients at risk of cerebral oedema [17]. Slow extended daily treatments, with low blood and dialysate flows such as the Genius[®] system, would also be expected to cause minimal changes in cerebral perfusion.

Teaching points

1. Patients with acute liver failure are at increased risk of cerebral oedema.
2. Even though patients may not appear to have clinically apparent hepatic encephalopathy, this does not mean cerebral function is normal.
3. Intermittent haemodialysis potentially increases cerebral interstitial fluid.
4. Despite using high sodium and cooled dialysates, with low blood flow rates, intermittent haemodialysis can still lead to patient deterioration.
5. Low volume continuous modes of renal replacement therapy cause much fewer changes in cerebral perfusion and intracranial pressure, and are to be preferred in patients at risk of cerebral oedema.

Conflict of interest statement. None declared.

References

1. Varghese J, Ilias-Basha H, Dhanaselaran R *et al.* Hepatopulmonary syndrome—past to present. *Ann Hepatol* 2007; 6: 135–142
2. Leaver SK, Evans TW. Acute respiratory distress syndrome. *Br Med J* 2007; 335: 389–394
3. Baumann A, Audibert G, McDonnell J *et al.* Neurogenic pulmonary oedema. *Acta Anaesthesiol Scand* 2007; 51: 447–455
4. Larson AM. Acetaminophen hepatotoxicity. *Clin Liver Dis* 2007; 11: 525–548
5. Jalan R. Intracranial hypertension in acute liver failure: pathophysiological basis of rational management. *Semin Hepatol* 2003; 23: 271–282

6. Davenport A, Finn R. Paracetamol (acetaminophen) poisoning resulting in acute renal failure without hepatic coma. *Nephron* 1988; 50: 55–56
7. Davenport A, Will EJ, Davison AM *et al.* Changes in intracranial pressure during haemofiltration in oliguric patients with grade IV hepatic encephalopathy. *Nephron* 1989; 53: 142–146
8. Arieff AI. Dialysis disequilibrium syndrome: current concepts on pathogenesis and prevention. *Kidney Int* 1994; 45: 629–635
9. Trinh-Trang-Tan MM, Carton JP, Bankir L. Molecular basis for the dialysis disequilibrium syndrome: altered aquaporin and urea transporter expression in the brain. *Nephrol Dial Transplant* 2005; 20: 1984–1988
10. Jones JG, Bembridge JL, Sapsford DT *et al.* Continuous measurement of oxygenation saturation during haemodialysis. *Nephrol Dial Transplant* 1992; 7: 110–116
11. Arieff AI, Guisado R, Massry SG *et al.* Central nervous system pH in uremia and the effects of hemodialysis. *J Clin Invest* 1976; 58: 306–310
12. Ware AJ, D'Agostino A, Coombes B. Cerebral oedema: a major complication of massive hepatic necrosis. *Gastroenterol* 1971; 61: 877–884
13. Davenport A, Will EJ, Losowsky MS. Rebound surges of intracranial pressure as a consequence of forced ultrafiltration used to control intracranial pressure in patients with severe hepatorenal failure. *Am J Kidney Dis* 1989; 14: 516–519
14. Davenport A. Intradialytic complications during hemodialysis. *Hemodial Int* 2006; 10: 162–167
15. Schortgen F, Soubrier N, Delclaux C *et al.* Haemodynamic tolerance of intermittent haemodialysis in critically ill patients. *Am J Respir Crit Care Med* 2000; 162: 197–202
16. Vinsonneau C, Camus C, Combes A *et al.* Hemodiafe Study Group. Continuous venovenous haemodiafiltration versus intermittent haemodialysis for acute renal failure in patients with multiple-organ dysfunction syndrome: a multicentre randomised trial. *Lancet* 2006; 368: 379–85
17. Davenport A. Renal replacement therapy in the patient with acute brain injury. *Am J Kidney Dis* 2001; 37: 457–466

Received for publication: 21.9.07

Accepted in revised form: 11.10.07