

# Application of cystourethroscopy during tracheobronchial foreign body removal in children

Journal of International Medical Research

2018, Vol. 46(9) 3741–3747

© The Author(s) 2018

Article reuse guidelines:

[sagepub.com/journals-permissions](http://sagepub.com/journals-permissions)

DOI: 10.1177/0300060518778477

[journals.sagepub.com/home/imr](http://journals.sagepub.com/home/imr)



Bifan Deng<sup>1</sup>, Weiguang Tang<sup>1</sup>, Feiqun Su<sup>2</sup>,  
Hua Li<sup>3</sup>, Wanqiang Lai<sup>1</sup>, Ruibin Xie<sup>4</sup>,  
Ruqing Yan<sup>5</sup>, Qiangwen Chen<sup>6</sup>, Lianxing Zhou<sup>7</sup>  
and Shaofeng Liu<sup>5</sup> 

## Abstract

**Objective:** This study aimed to describe preliminary experiences associated with removal of tracheobronchial foreign bodies (TFBs) by cystourethroscopy (CU).

**Methods:** We performed a retrospective analysis of 127 paediatric cases of TFB removal by CU at our centre from January 2009 to August 2016. Data that were extracted from the medical records included age, sex, location and nature of the TFBs, operation time, and complications.

**Results:** All TFBs were successfully removed by CU. The mean time of the procedure was  $3.38 \pm 2.86$  minutes. A total of 102 (80.31%) patients had successful removal of TFBs by CU during the initial trial, 19 (14.96%) were successfully treated in the second trial, and six (4.72%) required a third trial. Otolaryngologists with 2, 5, and 7 years of professional CU training showed a mean TFB removal time of  $3.38 \pm 2.13$ ,  $3.40 \pm 3.60$ , and  $3.37 \pm 2.86$  minutes, respectively. In the operations, oxygen saturation fell below 90% at an average occurrence of 0.39 times, but no patients showed a decrease below 85%. Only one patient experienced laryngeal oedema after the procedure.

**Conclusion:** CU is a useful technique and minimizes complications and operational risks during removal of paediatric TFBs.

<sup>1</sup>Department of Otolaryngology Head and Neck Surgery, Hezhou City People's Hospital, Hezhou, China

<sup>2</sup>Department of Nursing, Hezhou City People's Hospital, Hezhou, China

<sup>3</sup>Department of Pediatrics, Hezhou City People's Hospital, Hezhou, China

<sup>4</sup>Department of Cardiovascular Medicine, Hezhou City People's Hospital, Hezhou, China

<sup>5</sup>Department of Pharmacy, Hezhou City People's Hospital, Hezhou, China

<sup>6</sup>Department of Urology, Hezhou City People's Hospital, Hezhou, China

<sup>7</sup>Department of Emergency Medicine, Hezhou City People's Hospital, Hezhou, China

## Corresponding author:

Shaofeng Liu, Department of Pharmacy, Hezhou City People's Hospital, 150 Babu District, Xiyue Street, Hezhou 542899, Guangxi Province, China.  
Email: [d-v-wade2007@163.com](mailto:d-v-wade2007@163.com)



## Keywords

Paediatrics, tracheobronchial foreign body, cystourethroscopy, rigid bronchoscopy, oedema, seed

Date received: 16 February 2018; accepted: 1 May 2018

## Background

Aspiration of tracheobronchial foreign bodies (TFBs) plays a large role in morbidity and accidental deaths of the paediatric population.<sup>1</sup> Aspiration of TFBs is responsible for 7% of deaths in children aged younger than years in the USA, and is the fourth leading cause for accidental mortality in paediatric patients.<sup>2,3</sup> Interestingly, 75.4% of TFB inhalation accidents occur in male children younger than 3 years.<sup>1</sup> Inhaled objects in choking cases mainly consist of organics, such as seeds and pieces of food, or inorganic objects, such as metals and plastics.<sup>3</sup> The main symptoms of TFB inhalation consist of persistent coughing, recurrent pneumonia, bronchiectasis, severe respiratory failure, and other complications, which can be serious enough to require a lobectomy because of irreversibility.<sup>4</sup>

Currently, rigid bronchoscopy (RB) is the standard treatment for paediatric patients with TFB inhalation.<sup>5,6</sup> RB is a safe method for removing TFBs in children because of its ability to control the airway and ventilation.<sup>7</sup> More importantly, RB is exclusively used for managing paediatric TFBs, particularly if extraction is attempted.<sup>8</sup> However, use of RB in paediatric patients is limited by the small size of the field of view during an operation. Therefore, surgeons sometimes need to exercise creativity in selecting other endoscopic tools for extracting a foreign body that is not amenable for removal by routine bronchoscopy. A flexible bronchoscope is an effective tool for removal of foreign

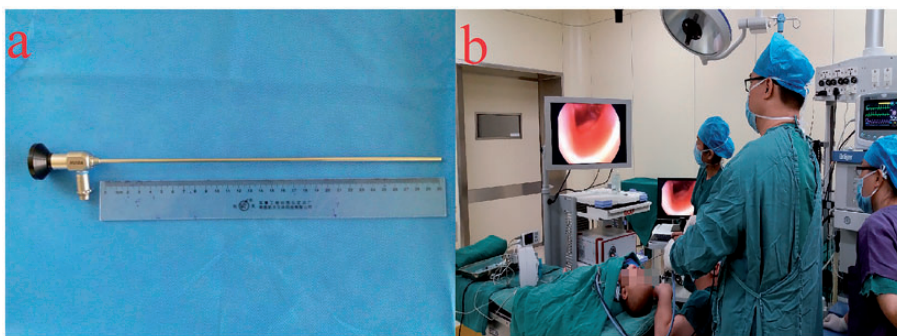
bodies, but it is usually used in older children or adults, and is hard to control.<sup>9</sup> We considered that a cystourethroscope could be useful for TFB removal. Cystourethroscopy (CU) has been used for removing aspirated TFBs in children since January 2009 in our department, and excellent results have been achieved. Although this operation is simple, no studies have reported its use.

In this study, we describe our preliminary experience with TFB removal using CU. This surgical method was designed based on the accumulated experience in our department.

## Materials and methods

All paediatric patients had TFB removal performed with a cystourethroscope (Hangzhou Huida Concord China Medical Instrument Co., Ltd., Zhejiang China). The cystourethroscope had an external diameter of 4.0 mm or 2.7mm, a length of 350 mm, a field angle of 70°, a television monitoring system that magnified objects 600-fold, and a strong 600-W xenon lamp with a cold light source that could be useful for TFB removal (Figure 1). The children were not allowed to eat or drink for 6 hours before the start of the operation.

To avoid large leakage of inhalational anaesthesia, intravenous anaesthetic agents were used to maintain a controlled level. Penhyclidine (0.5 mg), ondansetron (5 mg/m<sup>2</sup>), and dexamethasone sodium phosphate (2–5 mg) were administered by intravenous infusion to inhibit gland secretion, vomiting, and prevent the likelihood



**Figure 1.** Removal of a tracheobronchial foreign body by cystourethrosopy. (a) Cystourethrosopy. (b) An otolaryngologist used cystourethrosopy to remove a tracheobronchial foreign body.

of airway oedema, respectively. Pulse, oxygen saturation, and heart rate were monitored, while an appropriate concentration of oxygen was provided by mask. Sedation was accomplished by an initial intravenous infusion of midazolam (0.1 mg/kg) and ketamine (2 mg/kg), followed by sufentanil (0.5 µg/kg) and cis-atracurium (0.1 mg/kg) once the children breathed smoothly. After sedation, the glottis was topically anesthetized with a 2% lidocaine spray. Pulse oximetry was maintained above 99% by high-flow oxygen after tracheal secretions were rapidly exhausted under exposure of the glottis via laryngoscopy intubation. A cystourethroscope was then gently inserted into the pharynx and oesophagus, and sufficiently extended to look for TFBs. Forceps were moved forward under guidance of the cystourethroscope until they made contact with the foreign body. The forceps were gently withdrawn after the TFBs were clamped with an appropriate amount of strength, and the forceps and foreign body were removed. Patients had tracheal bronchoscopy performed again to exclude the existence of other TFBs or fragments of the removed TFB after removal of the TFB.

Descriptive statistics were conducted with distribution of frequencies. SPSS

version 12.0 (SPSS Inc., Chicago, IL, USA) was used for statistical analysis.

This study received ethical approval from the Ethics Committee of Hezhou City People's Hospital. The patients provided written or verbal informed consent for participation in the study.

## Results

A total of 127 paediatric patients with a diagnosis of TFBs were studied. Of these patients, 96 (75.59%) were boys and 31 (24.41%) were girls. The average age was 2.3 years and age ranged from 5 months to 14 years, with 105 (82.68%) patients aged younger than 3 years (Table 1). The duration of TFB retention ranged from 1 hour to 3.5 years, with a median of 2 weeks. TFB inhalation often caused signs and symptoms, including pneumonia in 24 (18.90%) patients, cough with dyspnoea in 22 (17.32%), cough in 19 (14.96%), dyspnoea in 13 (10.24%), emphysema in 12 (9.45%), pneumonia emphysema in five (3.94%), and obstructive emphysema in one (0.79%). Thirty-one (24.41%) patients presented with no obvious signs and symptoms.

The right bronchial tree was the most common location of TFBs. The second most common location of TFBs was the

**Table 1.** Data of the patients' age, symptoms, and duration of removal of tracheobronchial foreign bodies

Variable	Number	Percentage
<b>Patients' age (years)</b>		
<1	20	15.75
1-3	85	66.93
4-7	18	14.17
>7	4	3.15
<b>Symptoms</b>		
Emphysema	12	9.45
Pneumonia, emphysema	5	3.94
Obstructive emphysema	1	0.79
Pneumonia	24	18.90
Dyspnoea, cough	22	17.32
Dyspnoea	13	10.24
Cough	19	14.96
None	31	24.41
<b>Duration (days)</b>		
<1	48	37.80
1-7	33	25.98
7-30	21	16.54
>30	25	19.69

trachea, followed by the left bronchial tree. A total of 123 (97.63%) of the aspirated foreign bodies were organic and included melon seeds (n = 51), peanuts (n = 28), sunflower seeds (n = 17), peanut shells (n = 4), fragments of fish bones (n = 4), beans (n = 3), water chestnuts (n = 3), wampee seeds (n = 2), chestnuts (n = 2), sunflower seed shells (n = 2), a melon seed shell (n = 1), a nut (n = 1), a raisin (n = 1), an almond (n = 1), a grapefruit seed (n = 1), a tooth (n = 1), and a sputum scab (n = 1). Four of the foreign bodies were inorganic materials, such as plastic tubes (n = 2), fragments of a plastic horn (n = 1), and fragments of a plastic whistle (n = 1) (Table 2).

All TFBs were successfully removed by CU (including two cases of failure via RB and optical forceps) The mean (SD) time of this procedure in this series was 3.38 ± 2.86 minutes (range: 0.4-15 minutes). Otolaryngologists with varying years of

**Table 2.** Localization and nature of tracheobronchial foreign bodies

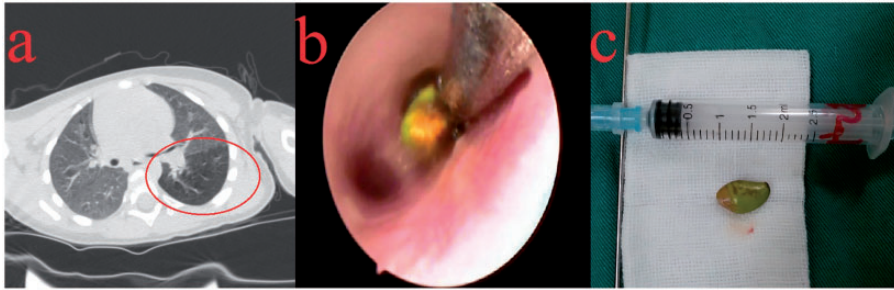
Variable	Number	Percentage
<b>Localization</b>		
Trachea	45	35.43
Right bronchial tree	55	43.31
Left bronchial tree	27	21.26
<b>Nature</b>		
Organic	123	96.85
Inorganic	4	3.15

experience in professional CU training appeared to show similar mean times of TFB removal (Table 3). Overall, 102 (80.31%) patients had successful removal of TFBs using CU during the initial trial, 19 (14.96%) patients were successfully treated in the second trial, and only six (4.72%) patients required a third trial. A Chinese wampee seed, which was inhaled in a child aged 2 years, could not be removed by RB. The seed was not able to be sufficiently gripped and easily slipped out during the removal process because of the limited field of view and smooth surface of the seed. Several additional attempts were made using RB, but all of them failed. A cystourethroscope with forceps (crocodile-jaw, double open, 2.0 × 360 mm) was used instead. Under the guidance of a CU magnification system on a TV display, the forceps could easily clamp the relatively flat sides of the seed. The Chinese wampee seed was able to be rapidly extracted from the right bronchus according to its structure (Figure 2).

In this study, oxygen saturation fell below 90% among patients at an average occurrence 0.39 times, but no patients showed a decrease below 85%. Only one patient experienced laryngeal oedema after the procedure.

## Discussion

Aspiration of TFBs is the most common cause of death from acute asphyxia among



**Figure 2.** A Chinese wampee seed in the right bronchus was removed by cystourethroscopy. (a) Chest computed tomography showing emphysema in the right bronchus that was induced by a Chinese wampee seed. (b) An otolaryngologist removed the Chinese wampee seed by cystourethroscopy. (c) The removed wampee seed.

**Table 3.** Mean time of doctors performing cystourethroscopy according to different years of surgical experience

Surgical experience	Number of cases	Operation time (min), mean $\pm$ SD
2 years	22	3.38 $\pm$ 2.13
5 years	37	3.40 $\pm$ 3.60
10 years	68	3.37 $\pm$ 2.86

children aged between 1 and 3 years. The seeds of sunflowers and watermelons, and peanuts are the most common TFBs found in children in China.<sup>5,10,11</sup> In this study, 82.68% of the TFB inhalation accidents occurred in children aged younger than 3 years among whom 75.59% were boys. RB remains the gold standard for managing many complex TFBs.<sup>12</sup> In recent years, an increasing amount of studies has supported the use of a flexible bronchoscope for TFB removal.<sup>12-14</sup> This use is based on the small and soft outer diameter of a flexible bronchoscope, which makes it easier to access a grade III or deeper bronchus. However, the situation where the location of TFB inhalation is a grade III or deeper bronchus is rare.<sup>15-17</sup> Additionally, a flexible bronchoscope is hard to control because of the soft outer diameter. However, we believe that

neither the flexible or rigid bronchoscope is mandatory in each case of TFB removal.

With a small outer diameter, a cystourethroscopy can easily access the tracheal bronchus of paediatric patients. Additionally, this instrument can be combined with a wide variety of forceps necessary for removing different types and shapes of TFBs. Most TFBs in this study were red melon seeds and peanuts, and forceps with a crocodile-jaw or a peanut-jaw were used. They were mutually separated from the cystourethroscopy, which increased flexibility of the cystourethroscopy and forceps in extraction of TFBs. Even though the forceps and cystourethroscopy could not continue to access a deeper position of the bronchus together, the forceps alone were able to keep extending until grasping the TFB under guidance of the cystourethroscopy. A cystourethroscopy (2.7-mm outside diameter) with forceps (crocodile-jaw, double open, 2.0  $\times$  360 mm) can be considered when a TFB is in a deeper position of the bronchus with limited space for access of optical forceps. In our study, otolaryngologists could clearly observe the structure of the tracheal bronchia and promptly adjust the posture of the TFB through the cystourethroscopy with a large field and high-definition view. This reduced the chance of TFBs slipping out of the capturing instrument during the removal



process, especially when passing through the glottis. Once this occurred, the otolaryngologist immediately pushed the TFB into one of the main bronchi for ventilation and oxygenation. TFB inhalation is usually a life-threatening emergency and rapid removal of the foreign body while maintaining adequate oxygenation helps to ensure the child's life and reduces complications. In our study, 102 (80.31%) patients had TFBs successfully removed by using CU in the initial trial. Less frequent insertions probably contributed to a reduction of the operation time and the incidence of complications. The average time of the procedure performed by CU was 3.38 minutes (range: 0.2–15 minutes), and only one patient showed laryngeal oedema. A pulmonologist was available during the procedure and open surgical procedures, such as tracheotomy, tracheostomy or thoracotomy, could be immediately carried out if removal of the TFB failed and airway obstruction occurred. Fortunately, no patients suffered from airway obstruction. Our experience in this study shows that the removal of TFBs with CU can be safely performed with few complications.

The skill of surgeons and the equipment used have a greater effect on the number of incidences of airway obstruction than the type of ventilation.<sup>18</sup> To maximize safety, these TFB removal operations should only be performed by those with experience and professional training. China is a large populous country with a relatively low proportion of doctors, which has led to a large amount of pressure on its medical environment. In our study, after more than 2 years of professional CU training, the experience of otolaryngologists had little effect on the outcome of TFB removal. Young doctors can quickly accumulate experience depending on the CU technique with an image enlargement system, which may relieve tension in the medical environment.

Although CU has achieved excellent outcomes in removal of TFBs, it still has some

disadvantages. Our institution has not used a rigid or flexible bronchoscope to remove TFBs since 2010. All inhalations of TFBs have been successfully treated with a cystourethroscope without a rigid bronchoscope. This means that young doctors have difficulty in finding the opportunity to become trained on extraction of TFBs with RB in paediatrics. Nevertheless, the best method for extracting TFBs in children is still in dispute.<sup>19</sup> If we encounter an emergency and needed a rigid or flexible bronchoscope to remove a TFB, an experienced doctor with training could be scheduled. One solution is to train young doctors for using flexible and rigid bronchoscopes so that they can assist in TFB removal.

In summary, our experience shows that CU is a useful method that minimizes complications and operational risks during the removal of paediatric TFBs. CU only costs USD 639. Not only is CU used for TFB removal, it is also used for urological surgery. Full use of all medical resources is required because of the lack of medical equipment and doctors, especially in developing countries with a large population.

### **Acknowledgements**

We acknowledge the nursing and technical assistance support from Min Liao and Yan Ma. We also thank the patients in this study.

### **Authors' contributions**

BFD and WGT conceived and designed the surgical approach; HL, BFD, and SFL contributed to the acquisition of data; FQS, RBX, QWC, and LXZ assisted in surgery; WQL and RQY contributed reagents/materials/analysis tools; BFD and SFL contributed to the analysis and interpretation of data; SFL wrote the manuscript. All authors read and approved the final manuscript.

### **Availability of data and materials**

The datasets used and/or analysed during the current study are available from the corresponding author on reasonable request.


## Declaration of conflicting interest

The authors declare that there is no conflict of interest.

## Funding

This work was supported by a Guangxi Scientific Research and Technology Development Project (Contract No. 14279006).

## ORCID iD

Shaofeng Liu  <http://orcid.org/0000-0002-0260-4495>

## References

- Roda J, Nobre S, Pires J, et al. Foreign bodies in the airway: a quarter of a century's experience. *Rev Port Pneumol* 2008; 14: 787–802.
- Mnejja M, Chakroun A, Bougacha L, et al. Bronchoscopy for foreign body inhalation in the pediatric population: lessons learned from 223 cases. *Arch Pediatr* 2012; 19: 670–674.
- Oğuzkaya F, Akçal Y, Kahraman C, et al. Tracheobronchial foreign body aspirations in childhood: a 10-year experience. *Eur J Cardiothorac Surg* 1998; 14: 388–392.
- Hasdiraz L, Oguzkaya F, Bilgin M, et al. Complications of bronchoscopy for foreign body removal: experience in 1,035 cases. *Ann Saudi Med* 2006; 26: 283–287.
- Tang LF, Xu YC, Wang YS, et al. Airway foreign body removal by flexible bronchoscopy: experience with 1027 children during 2000–2008. *World J Pediatr* 2009; 5: 191–195.
- Roh J L, Hong S J. Lung recovery after rigid bronchoscopic removal of tracheobronchial foreign bodies in children. *Int J Pediatr Otorhinolaryngol* 2008; 72: 635–641.
- Panda SS, Bajpai M, Singh A, et al. Foreign body in the bronchus in children: 22 years experience in a tertiary care paediatric centre. *Afr J Paediatr Surg* 2014; 11: 252.
- Swanson KL, Prakash UB, Midthun DE, et al. Flexible bronchoscopic management of airway foreign bodies in children. *Chest* 2002; 121: 1695–1700.
- Mehta AC and Rafanan AL. Extraction of airway foreign body in adults. *J Bronchol* 2001; 8: 123–132.
- Grillo HC. Development of tracheal surgery: a historical review. Part 1: Techniques of tracheal surgery. *Ann Thorac Surg* 2003; 75: 610–619.
- Tang FL, Chen MZ, Du ZL, et al. Fibrobronchoscopic treatment of foreign body aspiration in children: an experience of 5 years in Hangzhou City, China. *J Pediatr Surg* 2006; 41: 1–5.
- Swanson KL, Prakash UBS and Midthun DE. Flexible bronchoscopic management of airway foreign bodies in children. *Chest*, 2002; 121: 1695–1700.
- Shah MB, Bent JP, Vicencio AG, et al. Flexible bronchoscopy and interdisciplinary collaboration in pediatric large airway disease. *Int J Pediatr Otorhinolaryngol* 2008; 72: 1771–1776.
- Tang LF, Xu YC, Wang YS, et al. Airway foreign body removal by flexible bronchoscopy: experience with 1027 children during 2000–2008. *World J Pediatr* 2009; 5: 191–195.
- Ramírez-Figueroa JL, Gochicoa-Rangel LG, Juan RS, et al. Foreign body removal by flexible fiberoptic bronchoscopy in infants and children. *Pediatr Pulmonol* 2005; 40: 392–397.
- Karakoç F, Karadağ B, Akbenlioğlu C, et al. Foreign body aspiration: what is the outcome? *Pediatr Pulmonol* 2002; 34: 30–36.
- Chik KK, Miu TY and Chan CW. Foreign body aspiration in Hong Kong Chinese children. *Hong Kong Med J* 2009; 15: 6–11.
- Pawar DK. Dislodgement of bronchial foreign body during retrieval in children. *Paediatr Anaesth* 2000; 10: 333–335.
- Martinot A, Closset M, Marquette CH, et al. Indications for flexible versus rigid bronchoscopy in children with suspected foreign-body aspiration. *Am J Respir Crit Care Med* 1997; 155: 1676–1679.