

## Outcomes of preoperative bevacizumab in diabetics with nonclearing vitreous hemorrhage without tractional detachment – A quasi-randomized retrospective study

Debdul Chakraborty, Aniruddha Maiti<sup>1</sup>, Aditya Kelkar<sup>2</sup>, Sabyasachi Sengupta<sup>3</sup>, Sangeeta Roy<sup>1</sup>, Mounika Bolisetty<sup>2</sup>, Akshay Kothari<sup>2</sup>, Jaydeep Majumder<sup>1</sup>

**Purpose:** To assess whether preoperative bevacizumab (BVZ) in treatment-naïve eyes with proliferative diabetic retinopathy (PDR) and vitreous hemorrhage (VH) without tractional retinal detachment (TRD) leads to lesser macular edema and better visual outcome compared to eyes that do not receive BVZ. **Methods:** This quasi-randomized retrospective study included 217 treatment-naïve eyes with nonclearing VH without TRD that had vitrectomy with or without BVZ and had a minimum 6-months follow-up. Postoperative variables, including visual acuity (BCVA), central macular thickness (CMT) at 1 month, and need for additional anti-VEGF injections till 6 months follow-up, were recorded for analysis. **Results:** Of the 217 eyes, 107 eyes (49%) received preoperative BVZ and 110 (51%) did not. Groups were comparable in terms of preoperative characteristics. At 1 month, mean CMT was significantly higher in eyes without BVZ ( $310 \pm 33 \mu$  vs.  $246 \pm 34\mu$ ;  $P < 0.001$ ). The likelihood of developing center-involving DME at 1 month after vitrectomy was 67% lower if the eye received preoperative BVZ (OR = 0.33, 95%CI = 0.18–2.54,  $P = 0.56$ ). Though BCVA improved significantly in both groups at 1 month, it was 1/3<sup>rd</sup> of a line better in the BVZ group ( $\beta$  coefficient =  $-0.035 \log\text{MAR}$ , 95%CI =  $-0.04$  to  $-0.008 \log\text{MAR}$ ,  $P = 0.01$ ). **Conclusion:** Preoperative BVZ in treatment-naïve eyes with PDR and VH but without TRD lead to better macular status and marginally improved vision at 1 month, which was maintained at 6 months. In view of these results, patients may be offered BVZ only when it is readily affordable to them.

**Key words:** Bevacizumab, proliferative diabetic retinopathy, vitrectomy, vitreous hemorrhage

The surgical management of proliferative diabetic retinopathy (PDR) has seen significant advances over the last decade, including better vitrectomy cutter dynamics, smaller gauge instrumentation, and better visualization systems.<sup>[1]</sup> The surgical approach is governed by the clinical picture including the presence of vitreous hemorrhage (VH) and preoperative view of the fundus, presence of tractional elements and tractional retinal detachment (TRD), degree of separation of the posterior hyaloid face (PHF) as well as the degree of previous treatment received in the form of pan-retinal photocoagulation (PRP), and/or anti-vascular endothelial growth factor (VEGF) agents.

The preoperative use of anti-VEGF agents approximately 5–7 days before surgery has received a lot of attention in the past.<sup>[2–10]</sup> Based on previous studies, most vitreoretinal surgeons recommend this when they expect extensive membrane dissections during surgery, especially in very vascular membranes and coexistent diabetic TRD. Anti-VEGF agents have been shown to reduce the incidence of severe

intraoperative bleeding,<sup>[2,10–13]</sup> need for endodiathermy, and incidence of iatrogenic retinal tears in these complex surgeries.<sup>[3,14–16]</sup> There is also a moderate degree of evidence showing that per operative anti-VEGF agents may reduce the incidence of early postoperative vitreous cavity hemorrhage and help in earlier clearance of residual hemorrhage, thereby giving faster and better visual outcomes in the early postoperative period.<sup>[6,17]</sup>

However, the use of preoperative anti-VEGF in treatment-naïve eyes with nonresolving vitreous hemorrhage without coexistent TRD, where not much membrane dissection is expected, has not been studied well. Though previous studies looked at best-corrected vision (BCVA) as a major outcome measure, they evaluated this in terms of residual VH and not central macular thickness (CMT) in this subgroup of treatment-naïve eyes.<sup>[9,17–19]</sup> Even though the outcomes in these eyes are expected to be excellent with timely pars plana vitrectomy and endolaser, the CMT, incidence of center-involving diabetic macular edema (ciDME), and BCVA at

### Access this article online

Website:  
www.ijo.in

DOI:  
10.4103/ijo.IJO\_1264\_21

### Quick Response Code:



Department of Vitreo-Retina, Disha Eye Hospitals, 88 Ghosh Para Road Barrackpore, <sup>1</sup>Department of Vitreo-Retina, Susrut Eye Hospital, Salt Lake, Kolkata, <sup>2</sup>Department of Vitreo-Retina, National Institute of Ophthalmology, (NIO), Pune, <sup>3</sup>Department of Vitreo-Retina, Future Vision Eye Care and Research Centre, Mumbai, Maharashtra, India

**Correspondence to:** Dr. Debdul Chakraborty, Senior Consultant, Department of Vitreo-Retinal Services, Disha Eye Hospitals, 88 Ghosh Para Road Barrackpore, Kolkata - 700 120, West Bengal, India. E-mail: devdc@rediffmail.com

Received: 16-May-2021

Revision: 20-Aug-2021

Accepted: 01-Sep-2021

Published: 29-Oct-2021

This is an open access journal, and articles are distributed under the terms of the Creative Commons Attribution-NonCommercial-ShareAlike 4.0 License, which allows others to remix, tweak, and build upon the work non-commercially, as long as appropriate credit is given and the new creations are licensed under the identical terms.

**For reprints contact:** WKHLRPMedknow\_reprints@wolterskluwer.com

**Cite this article as:** Chakraborty D, Maiti A, Kelkar A, Sengupta S, Roy S, Bolisetty M, *et al.* Outcomes of preoperative bevacizumab in diabetics with nonclearing vitreous hemorrhage without tractional detachment – A quasi-randomized retrospective study. Indian J Ophthalmol 2021;69:3283-7.

the 1-month postoperative time point in relation to the anatomic macular features have not been elucidated well. Additionally, the need for adjuvant intravitreal pharmacotherapy up to 6 months follow-up after vitrectomy and influence of preoperative anti-VEGF on this has also not been studied well in this subgroup. Hence, we performed this study with the primary objective of identifying whether preoperative anti-VEGF in treatment-naïve eyes with PDR and VH without TRD leads to lesser macular edema and better visual outcome compared to eyes that do not receive anti-VEGF injections.

## Methods

This was a quasi-randomized retrospective multicenter study involving four tertiary eye care institutions across India; two located in eastern India and two in western India. The study was approved by the institutional ethics committees of all the participating institutions.

All consecutive patients that underwent pars plana vitrectomy for proliferative diabetic retinopathy between January 2018 and December 2019 were identified from computer databases of all four participating centers using the ICD-10 coding. Patient names were also cross-checked using operation room registers to ensure that all patients were identified. The case records were used to identify treatment-naïve (without prior PRP) patients who were operated for nonclearing VH (>4 weeks) without any significant tractional elements or tractional retinal detachment on ultrasound examination. Those with any mention of membrane dissection in surgical notes were excluded. Records of patients who had a minimum of 6 months follow-up were included in the analysis. Intravitreal bevacizumab (BVZ) was administered based on the surgeon's preference; two of the participating surgeons used BVZ in all eyes (DC, SS) whereas the other two (ASK, AM) did not use BVZ in any of the cases. All injections were administered in the operating room under strict aseptic conditions. During surgery, the four collaborating surgeons used 25-G vitrectomy systems, a noncontact visualization system (ReSight, Carl Zeiss, Germany), and standard vitrectomy maneuvers described previously. In summary, cone truncation was followed by peripheral vitreous shaving and then trimming of the PHF to the extent possible. Induction of a posterior vitreous detachment was attempted in situations when the risk of iatrogenic retinal tears was felt to be minimum, with total removal of the PHF. All eyes that had iatrogenic tears were filled with nonexpansile concentration of C<sub>3</sub>F<sub>8</sub> or SF<sub>6</sub> gas or air, as required, such that these were reabsorbed within the first month of surgery.

Patients' case files were used to record all relevant preoperative features, including demographic details, best-corrected visual acuity (BCVA), preoperative HbA1c levels, serum creatinine, lens status at the time of vitrectomy, and medications used for glycemic control (insulin or oral hypoglycemics (OHA)). Intraoperative complications such as excessive intraoperative bleeding (defined as serious bleeding requiring raised intraocular pressure of 50–60 mm Hg during surgery with or without fluid–air exchange and pausing surgery temporarily or abandoning surgery at the time) and occurrence of intraoperative iatrogenic retinal tears during vitrectomy were recorded from the intraoperative notes available in the files.

Postoperative follow-up at 1 month was used to record the BCVA and macular status, including measurements

of central macular thickness (CMT), external limiting membrane disruptions, and ellipsoid zone abnormalities, as described before. Participating centers used different optical coherence tomography machines to assess the macular status (Spectralis SD-OCT: Heidelberg, Germany at three centers and, Triton OCT: Topcon, Japan at the other center). Eyes were classified as macular edema involving the center of the macula if there were visible cystoid spaces involving the central 1 × 1 mm of the macular region in any of the scans passing through the center of the fovea. At 6 months follow-up, we recorded the BCVA, the HbA1c levels if available at follow-up, and need for additional intravitreal pharmacotherapy during the 6-month follow-up period, including any of the agents such as BVZ, triamcinolone, or dexamethasone implant. We also noted the incidence of recurrent VH over the 6-month follow-up period.

## Outcome measures

The primary outcome measure was the difference in the CMT and proportion of eyes having ciDME in eyes that received preoperative BVZ compared to eyes that did not receive it. Secondary outcome measures were to assess group differences in the incidence of serious intraoperative hemorrhage, iatrogenic tears, recurrent postoperative VH, and need for adjuvant intravitreal pharmacotherapy over the 6-month follow-up period.

## Statistical analysis

All continuous variables were expressed as mean with standard deviation and categorical variables were expressed as proportions (n, %). All BCVA values were converted into logarithm of minimal angle of resolution (logMAR) for statistical analysis. Group differences between continuous variables were assessed using the Student *t* test or the Wilcoxon rank-sum test for nonparametric variables while group differences between categorical variables were assessed using the Chi-squared test or the Fischer's exact test. Differences in BCVA before and at 1 month post op were assessed using the paired *t* test.

Univariate and multivariable linear regression was used to assess the association between CMT and use of anti-VEGF as well as between BCVA at 1 month, and anti-VEGF use and outcomes were expressed as beta coefficients with 95% confidence intervals (CI). Need for insulin therapy and baseline HbA1c were used as covariates in the multivariable models. Similarly, the factors associated with center-involving DME at the 1-month time points after surgery was assessed using univariate and multivariable logistic regression analysis where use of BVZ was the main influencer variable, whereas preoperative HbA1c, creatinine, baseline BCVA, and need for insulin were used as covariates.

All data were entered into Microsoft Excel and analyzed using STATA 12.1 I/c (STATA Corp, Fort Worth Texas, USA). *P* < 0.005 was considered statistically significant.

## Results

We included 217 eyes of 217 patients in the study that underwent pars plana vitrectomy for PDR and vitreous hemorrhage. Of these, 107 eyes (49%) received preoperative BVZ while the remaining 110 (51%) did not. The mean age of participants was 52.6 ± 6.9 years and 113 (52%) were men. Most patients had reasonably good systemic control of DM with the mean preoperative HbA1c of 6.48 ± 0.3; however, the creatinine

was elevated with a mean of  $1.37 \pm 0.5$  mg%. Sixty patients were on insulin while the remaining were on oral hypoglycemic agents for their diabetic control. The majority of patients were phakic ( $n = 163$ , 75%) at the time of vitrectomy whereas 53 (24%) were pseudophakic and 1 was aphakic.

A comparison of the baseline characteristics of the eyes that did and did not receive preoperative BVZ is shown in Table 1. Except for a greater proportion of patients requiring insulin in the BVZ group, there were no differences in the preoperative characteristics. Almost all eyes had a BCVA of worse than 20/200 before vitrectomy. Though the eyes that received preoperative BVZ had a slightly lower incidence of significant intraoperative bleeding as well as few iatrogenic retinal tears during surgery, these differences were not statistically significant between groups.

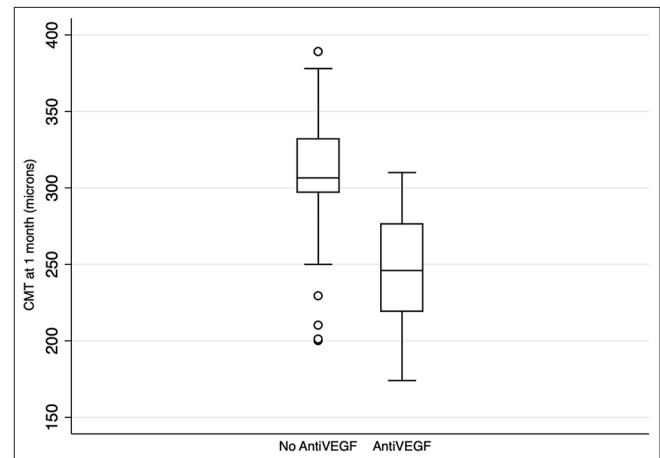
At 1 month follow-up, there was a significant improvement in BCVA of  $0.28 \pm 0.1$  compared to the preoperative levels ( $P < 0.001$ ). The mean CMT [Fig. 1] was significantly higher in eyes that had not received preoperative BVZ [Table 2]. Similarly, a significantly higher proportion of eyes that did not receive BVZ developed center-involving DME during the 6-month follow-up period after surgery [ $P = 0.002$ , Table 2]. The BCVA was also 1 line lower in the group that did not receive BVZ before surgery. There were no other differences in OCT characteristics between groups, including the proportion of eyes with epiretinal membrane, hyperreflective foci in the inner retina, and outer retinal abnormalities such as ellipsoid zone disruption and irregularity. At 6 months follow-up, the BCVA was maintained at the same level as that at 1 month, and though a greater proportion of eyes in the non-BVZ group required repeated intravitreal pharmacotherapy including repeat BVZ, triamcinolone, and Ozurdex, these differences were not statistically significant between the groups [Table 2].

Univariate analysis as well as multivariable linear regression analysis adjusting for age and preoperative insulin requirement, HbA1c, and creatinine showed that those who received preoperative BVZ had 1-month CMT of  $63\mu$  lower compared to those that did not receive BVZ [Table 3]; further, none of the other factors had a significant influence on CMT at 1 month. Similarly, the BCVA at 1 month was 1/3<sup>rd</sup> of a line (approximately 2–3 Snellen's letters) better in those that received preoperative BVZ ( $\beta$  coefficient =  $-0.035$  logMAR, 95%CI =  $-0.04$  to  $-0.008$  logMAR,  $P = 0.01$ ), even after adjusting for preoperative BCVA, insulin requirement, and preoperative BCVA. In the same multivariable

model, we found that eyes with ellipsoid zone abnormalities had a lower BCVA of more than 1 line compared to those with normal ellipsoid zone ( $\beta$  coefficient =  $0.13$  logMAR, 95%CI =  $0.03$ – $0.22$ ,  $P < 0.01$ ). The likelihood of developing center-involving DME at 1 month after vitrectomy was 67% lower if the eye received preoperative BVZ [Table 3]. None of the other covariates in the model, including insulin requirement, HbA1c, and creatinine, had any significant influence on the risk of center-involving DME at 1 month. A *post hoc* analysis indicated that the power of the study was 97% to detect differences in CMT between the two groups at the 1-month time point, with an alpha error of 0.01 and a beta error of 0.9.

## Discussion

In this retrospective study, eyes that received BVZ 3–5 days before pars plana vitrectomy for nonclearing VH in PDR without significant tractional elements had better anatomical and function outcomes in terms of CMT and BCVA compared to eyes with similar preoperative characteristics that did not receive BVZ. These eyes also required fewer intravitreal injections over the subsequent 6 months after surgery, though this difference was not statistically significant.



**Figure 1:** Box-and-whisker plot showing the distribution of central macular thickness (CMT) at 1 month after surgery in eyes with and without anti-VEGF injection

**Table 1: Comparison of baseline and intraoperative characteristics of eyes with and without preoperative bevacizumab**

Variable	No BVZ (n=110)	Preop BVZ (n=107)	P
Age	52.9±7.2	52.4±6.8	0.70
Gender (% men)	52 (47%)	61 (57%)	0.15
Preop BCVA (logMAR)	1.22±0.19	1.27±0.17	0.06
Preop HbA1c (gm %)	6.49±0.2	6.47±0.3	0.63
Preop Creatinine (mg%)	1.34±0.43	1.42±0.53	0.64
Preop % on insulin	24 (22%)	38 (36%)	0.03
Duration of vitreous hemorrhage (weeks)	6.72±2.6	6.41±2.3	0.65
Lens status: Phakic	80 (73%)	83 (78%)	
Pseudophakic	29 (26%)	24 (22%)	0.47
Aphakia	1 (1%)	0	
Intraop hemorrhage	9 (8%)	3 (3%)	0.13
Iatrogenic breaks	6 (5%)	2 (2%)	0.28

Though there have been numerous studies exploring the role of preoperative anti-VEGF before diabetic vitrectomy, most of them include advanced cases of TRD and are done in post-PRP eyes.<sup>[2,7,9,15]</sup> Based on results from many previous studies, as well as a few meta-analyses,<sup>[3,14]</sup> the use of BVZ is recommended when expecting extensive membrane dissection and resultant intraoperative bleeding. However, we studied its application in less severe cases and with a different primary outcome in mind. Treatment-naïve eyes with nonclearing VH or without TRD or extensive traction, where the operating surgeon does not expect extensive segmentation and delamination maneuvers, are usually not considered for preoperative anti-VEGF, as shown by two of our participating surgeons. Surprisingly, there have been very few studies on this unique scenario in the past to understand how preoperative anti-VEGF may influence the macular structure and function in the immediate postoperative period. We found a significant benefit in terms of lower mean CMT, significantly reduced likelihood of ciDME, and slightly better BCVA at 1 month following surgery in eyes that received BVZ. It is possible that the well-established benefit of BVZ on the macula persists till one month despite the removal of the vitreous depot and offers a benefit of more than 50 microns up to a 1-month time period. In a recent study with inclusion similar to ours, Haseeb *et al.*<sup>[20]</sup> showed improved BCVA in eyes that had combined BVZ with vitrectomy compared to eyes without BVZ ( $n = 30$  in each group). However, they did not mention the CMT in these eyes. In another large study from India done a decade ago, Gupta *et al.*<sup>[9]</sup> showed improved

vision in the BVZ group; however, half of these eyes had TRD and nearly 90% of eyes had received PRP in the past, a scenario very different from our baseline characteristics. Most studies are similar in their inclusion to the study by Gupta *et al.*<sup>[9]</sup> and hence are not directly comparable to our cohort of patients.

In addition to the absolute CMT benefit, we also found that a significantly lower proportion of eyes in the BVZ group developed ciDME, while almost a third of the control group without BVZ showed ciDME. Though the lack of comparison with preoperative CMT is problematic, this is a clinically meaningful difference at 1 month. It is important to prevent involvement of the center of the foveal in eyes PDR because this is associated with worse visual outcomes and repeated intravitreal injections. Yet, the functional benefit on BCVA was not very high, with only a few letters better vision in the BVZ group. As adding BVZ to the treatment regimen adds to the financial burden for patients in resource-poor settings, without offering a clinically meaningful visual benefit, we recommend that it may be offered to affording patients alone with baseline disease characteristics matching this study.

We also noted a trend toward a reduced number of anti-VEGF injections in the first 6 months after vitrectomy in eyes that received BVZ, though this was not statistically significant. However, the study was not adequately powered to analyze this outcome. Similarly, the overall incidence of serious intraoperative bleeding, iatrogenic retinal tears, and recurrent postoperative VH was very low, as expected, in view of the reduced complexity of the surgeries. Though we saw lower rates in the BVZ group, these were not statistically significant; thus, we are unable to comment on recommendations to use BVZ with these outcomes in mind. Further study may be required to find additional benefits of BVZ in this subgroup of eyes with less severe PDR.

The merits of our study are the relatively large sample from multiple centers in India, a minimum follow-up of 6 months to assess the risks and benefits of a single preoperative anti-VEGF on outcomes, and the quasi-randomized nature of the two groups. The *post hoc* power calculation also showed a high power to assess differences in CMT between groups. The drawbacks of the study are its retrospective nature, use of different OCT machines, and lack of cost-benefit analysis that can govern decisions in resource-poor settings. Additionally, the study was underpowered to assess the influence of BVZ on the other outcomes of interest such as intraoperative bleeding and iatrogenic breaks.

## Conclusion

In conclusion, we found that injecting preoperative BVZ in treatment-naïve eyes with PDR and VH but without TRD lead

**Table 2: Comparison of postoperative characteristics of eyes with and without preoperative bevacizumab**

Variable	No BVZ (n=110)	Preop BVZ (n=107)	P
At 1-month follow-up			
BCVA	0.37±0.11	0.26±0.08	0.03
CMT (in m)	310±33	246±34	<0.001
Center-involving DME (%)	34 (31%)	14 (13%)	0.002
ERM (%)	20 (18%)	14 (13%)	0.30
Inner retinal HRF (%)	15 (14%)	8 (7%)	0.14
ELM disruption (%)	24 (22%)	19 (18%)	0.45
EZ abnormality (%)	25 (23%)	20 (19%)	0.46
At 6-month follow-up			
HbA1c (gm %)	6.54±0.30	6.44±0.32	0.10
Recurrent VH (%)	6 (6%)	3 (3%)	0.50
Post op BVZ (%)	11 (10%)	4 (4%)	0.11
IVTA (%)	18 (16%)	12 (11%)	0.27
Ozurdex (%)	8 (7%)	6 (6%)	0.62

**Table 3: Factors associated with central macular thickness and center-involving diabetic macular edema at 1 month after vitrectomy**

Variable	Interval	Multivariable linear regression (CMT)		Multivariable logistic regression (ciDME)	
		B coefficient	95% CI, P	Odds Ratio	95% CI, P
Preop HbA1c	Every 1 g% increment	0.017	-0.03 to 0.07, 0.53	0.67	0.18-2.54, 0.56
Preop Creat	Every 0.1 mg% increment	0.02	-0.01 to 0.047, 0.15	1.12	0.55-2.26, 0.76
Preop BCVA	Every 1 line worsening	0.02	-0.05 to 0.09, 0.59	1.24	0.20-7.66, 0.82
Insulin	Vs. No insulin	0.002	-0.03 to 0.03, 0.85	0.92	0.43-1.97, 0.84
BVZ	Vs. no BVZ	-0.035	-0.06 to -0.008, 0.01	0.33	0.16-0.67, 0.002

to better macular status and marginally improved vision at 1 month follow-up, which was maintained at 6 months. In view of these results, patients may be offered BVZ in this scenario and the drug administered only when it is readily affordable to patients. Patients should also be explained the potential need for a greater number of anti-VEGF injections after surgery, which can be administered as and when required. Further studies with a larger sample size are needed to assess the benefit of adding anti-VEGF in these eyes without TRD to lessen intraoperative hemorrhage, iatrogenic retinal tears, and the incidence of postoperative recurrent VH in the early postoperative period.

#### Financial support and sponsorship

Nil.

#### Conflicts of interest

There are no conflicts of interest.

#### References

- Jackson TL, Nicod E, Angelis A, Grimaccia F, Pringle E, Kanavos P. Pars plana vitrectomy for diabetic macular edema: A systematic review, meta-analysis, and synthesis of safety literature. *Retina* 2017;37:886–95.
- Ahmadieh H, Shoeibi N, Entezari M, Monshizadeh R. Intravitreal bevacizumab for prevention of early postvitrectomy hemorrhage in diabetic patients: A randomized clinical trial. *Ophthalmology* 2009;116:1943–8.
- Zhao L-Q, Zhu H, Zhao P-Q, Hu Y-Q. A systematic review and meta-analysis of clinical outcomes of vitrectomy with or without intravitreal bevacizumab pretreatment for severe diabetic retinopathy. *Br J Ophthalmol* 2011;95:1216–22.
- Al-Kharashi A, Galbinur T, Mandelcorn ED, Muni RH, Nabavi M, Kertes PJ. The adjunctive use of pre-operative intravitreal bevacizumab in the setting of proliferative diabetic retinopathy. *Saudi J Ophthalmol* 2016;30:217–20.
- Berk Ergun S, Toklu Y, Cakmak HB, Raza S, Simsek S. The effect of intravitreal bevacizumab as a pretreatment of vitrectomy for diabetic vitreous hemorrhage on recurrent hemorrhage. *Semin Ophthalmol* 2015;30:177–80.
- Castillo Velazquez J, Aleman I, Rush SW, Rush RB. Bevacizumab before diabetic vitrectomy: A clinical trial assessing 3 dosing amounts. *Ophthalmol Retina* 2018;2:1010–20.
- El-Batarny AM. Intravitreal bevacizumab as an adjunctive therapy before diabetic vitrectomy. *Clin Ophthalmol* 2008;2:709–16.
- Farahvash M-S, Majidi AR, Roohipoor R, Ghassemi F. Preoperative injection of intravitreal bevacizumab in dense diabetic vitreous hemorrhage. *Retina* 2011;31:1254–60.
- Gupta A, Bansal R, Gupta V, Dogra MR. Six-month visual outcome after pars plana vitrectomy in proliferative diabetic retinopathy with or without a single preoperative injection of intravitreal bevacizumab. *Int Ophthalmol* 2012;32:135–44.
- Jorge DM, Tavares Neto JEDS, Poli-Neto OB, Scott IU, Jorge R. Intravitreal bevacizumab (IVB) versus IVB in combination with pars plana vitrectomy for vitreous hemorrhage secondary to proliferative diabetic retinopathy: A randomized clinical trial. *Int J Retina Vitreous* 2021;7:35.
- Ahn J, Woo SJ, Chung H, Park KH. The effect of adjunctive intravitreal bevacizumab for preventing postvitrectomy hemorrhage in proliferative diabetic retinopathy. *Ophthalmology* 2011;118:2218–26.
- Hu X, Pan Q, Zheng J, Song Z, Zhang Z. Reoperation following vitrectomy for diabetic vitreous hemorrhage with versus without preoperative intravitreal bevacizumab. *BMC Ophthalmol* 2019;19:200.
- Lo WR, Kim SJ, Aaberg TM, Bergstrom C, Srivastava SK, Yan J, *et al.* Visual outcomes and incidence of recurrent vitreous hemorrhage after vitrectomy in diabetic eyes pretreated with bevacizumab (avastin). *Retina* 2009;29:926–31.
- Simunovic MP, Maberley DAL. Anti-vascular endothelial growth factor therapy for proliferative diabetic retinopathy: A systematic review and meta-analysis. *Retina* 2015;35:1931–42.
- Arevalo JF, Lasave AF, Kozak I, Al Rashaed S, Al Kahtani E, Maia M, *et al.* Preoperative bevacizumab for tractional retinal detachment in proliferative diabetic retinopathy: A prospective randomized clinical trial. *Am J Ophthalmol* 2019;207:279–87.
- Papavasileiou E, Vasalaki M, Garnavou-Xirou C, Velissaris S, Zygora V, McHugh D, *et al.* Vitrectomy with fibrovascular membrane delamination for proliferative diabetic retinopathy with or without preoperative Avastin. *Hell J Nucl Med* 2017;20(Suppl):161.
- Smith JM, Steel DHW. Anti-vascular endothelial growth factor for prevention of postoperative vitreous cavity haemorrhage after vitrectomy for proliferative diabetic retinopathy. *Cochrane Database Syst Rev* 2015;2015:CD008214. doi: 10.1002/14651858.CD008214.pub3.
- Nagpal M, Mehrotra N, Vishnoi A. The role of perioperative anti-VEGF during vitrectomy for vitreous hemorrhage in relation to postoperative nonclearing vitreous hemorrhage and cystoid macular edema. *J Vitreoretin Dis* 2017;1:379–84.
- Sultan Z, Rizvi SF, Qureshi FM, Mahmood SA. Role of bevacizumab in the prevention of early postoperative haemorrhage after 25-gauge microincision vitrectomy surgery. *Pak J Med Sci* 2016;32:1184–7.
- Haseeb U, Aziz-Ur-Rehman, Haseeb M. Visual outcomes of pars plana vitrectomy alone or with intravitreal bevacizumab in patients of diabetic vitreous haemorrhage. *J Coll Physicians Surg Pak* 2019;29:728–31.