



Prolonged high-pressure balloon angioplasty of femoropopliteal lesions: Impact on stent implantation rate and mid-term outcome

Gianluca Rigatelli¹, Mariano Palena², Paolo Cardaioli¹, Fabio dell'Avvocata¹, Massimo Giordan¹, Dobrin Vassilev³, Marco Manzi²

¹Cardiovascular Diagnosis and Endoluminal Interventions, Rovigo General Hospital, Rovigo, Italy

²Interventional Radiology Unit, Abano Terme General Hospital, Padova, Italy

³Interventional Cardiology Department, National Heart Institute, Sofia, Bulgaria

Abstract

Objectives To assess the impact on stent implantation rate and mid-term outcomes of prolonged high pressure angioplasty of femoropopliteal lesions. **Methods** We retrospectively enrolled 620 consecutive patients from January 2011 to December 2011 (75.6 ± 12.3 years, 355 males, 76.5% in Rutherford class 5–6), referred for critical limb ischemia and submitted to prolonged high-pressure angioplasty of femoropopliteal lesions. The definition of prolonged high-pressure angioplasty includes dilation to at least 18 atm for at least 120 s. Procedural data, and clinical and instrumental follow-up were analyzed to assess stent implantation rate and mid-term outcomes. **Results** The preferred approach was ipsilateral femoral antegrade in 433/620 patients (69.7%) and contralateral cross-over in 164/620 (26.4%) and popliteal retrograde + femoral antegrade in 23/620 (3.7%). Techniques included subintimal angioplasty in 427/620 patients (68.8%) and endoluminal angioplasty in 193/620 patients (31.2%). The prolonged high pressure balloon angioplasty procedure was successful in 86.2% (minor intra-procedural complications rate 15.7 %), stent implantation was performed in 74 patients (11.9%), with a significant improvement of ankle-brachial index (0.29 ± 0.6 vs. 0.88 ± 0.3, $P < 00.1$) and Rutherford class (5.3 ± 0.8 vs. 0.7 ± 1.9, $P < 0.01$), a primary patency rate of 86.7%, restenosis of 18.6 % on Doppler ultrasound and a target lesion revascularization of 14.8% at a mean follow-up of 18.1 ± 6.4 months (range 1–24 months). Secondary patency rate was 87.7%. **Conclusions** Prolonged high pressure angioplasty of femoropopliteal lesions appears to be safe and effective allowing for an acceptable patency and restenosis rates on mid-term.

J Geriatr Cardiol 2014; 11: 126–130. doi: 10.3969/j.issn.1671-5411.2014.02.012

Keywords: Peripheral artery disease; Angioplasty; Balloon; Stent

1 Introduction

Despite the recent advances in stent bioengineering, stent treatment of femoropopliteal atherosclerotic lesions is still far from optimal because of the incidence of stent fractures and in-stent restenosis.^[1–3] Drug eluting stents (DES) and drug eluting balloons (DEB) have been advocated as the potential ideal tools to manage femoropopliteal disease,^[4–6] but definitive long-term results of these devices are still to be investigated. Balloon angioplasty alone is still currently used all over the world in the management of atherosclerotic occlusive disease in the femoropopliteal territory, but it is

troubled by a high incidence of restenosis and flow limiting dissections: the ideal protocol of inflation has not been established yet. Theoretically, increased pressure and duration of the inflation might improve the outcome in terms of recoil control, dissection frequency and patency rate. This retrospective study aimed to assess the safety and effectiveness of balloon angioplasty on midterm follow up with high pressure and prolonged inflation in the treatment of femoropopliteal disease.

2 Methods

We retrospectively enrolled 620 consecutive patients referred to the Interventional Radiology Unit of the Abano Terme Hospital and the Interventional Cardiology Unit of the Rovigo General Hospital from January 2011 to December 2011 (75.6 ± 12.3 years, 355 males, 76.5% in Rutherford class 5–6, Table 1), and undergoing prolonged high-pressure balloon angioplasty defined as balloon dila-

Correspondence to: Gianluca Rigatelli, MD, PhD, Cardiovascular Diagnosis and Endoluminal Interventions, Rovigo General Hospital, 45100 Rovigo, Italy.
E-mail: jackyheart71@yahoo.it

Telephone: +39-42-5394508

Fax: +39-34-71912016

Received: August 1, 2013

Revised: May 22, 2014

Accepted: May 25, 2014

Published online: June 10, 2014

tion at pressure of at least 18 atm for at least 120 s. Clinical indications to interventional revascularization included Rutherford class 3 to 6, whereas angiographic indications were > 50% stenosis or occlusion of the ipsilateral femoropopliteal artery with a target lesion length \geq 30 mm and at least one patent (< 50% stenosis) tibio-peroneal runoff vessel. Contraindications were included life expectancy < 6 months, acute renal failure, concurrent sepsis, international normalized ratio (INR) > 1.7, hemoglobin \leq 9 mg/dL, inability to assume antiplatelet therapy. The ankle-brachial index (ABI) using a handheld Doppler, Doppler ultrasonography (US), before and after the procedure were recorded as well as the complications and patency rate. Clinical examination and US were performed at 1, 3, and 6 months and every 12 months.

2.1 Procedural protocol

Lesion localization and severity was graded using the TASC II classification.^[7] Quantitative coronary angiography (QCA) was used to evaluate the angiographic reference diameter of the vessel and the lesion length. Preferred recanalization technique was endoluminal. In case of impossible endoluminal lesion crossing, the subintimal technique was used:^[8] a subintimal space was created looping a 0.035" Terumo (Terumo Europe, Leuven, Belgium) guidewire or torquing a 4F Bernstein catheter (Cordis, Johnson & Johnson Corp., USA) in the occluded femoral artery and re-entry by a coronary guidewire, such as the Pilot 150, Whisper MS or HS, or Crossit 100 or 200 (Abbot Vascular International, Diegem, Belgium). Femoropopliteal lesions were treated with balloon angioplasty inflating the semi-compliant Mustang (Boston Scientific Inc., USA) or PowerCross (Covidien, Maastricht, the Netherlands) balloon or a non-compliant Dorado balloon (Bard Inc, USA) at the discretion of the operator, depending on local availability and amount of calcium in the target lesion (Figures 1 and 2), at pressure of at least 18 atm for at least 120 s in one or

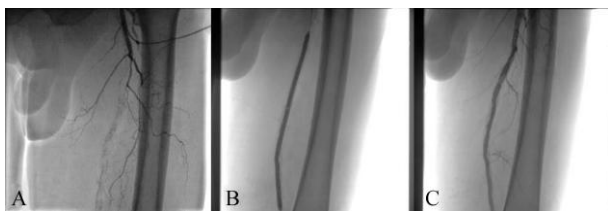


Figure 1. Prolonged high-pressure angioplasty in a non calcified lesion. (A): Baseline digital angiography in a 76-year old man with severe claudication demonstrating a long occlusion of the superficial femoral artery; (C): angiographic result after prolonged high pressure angioplasty with a Mustang balloon (B).

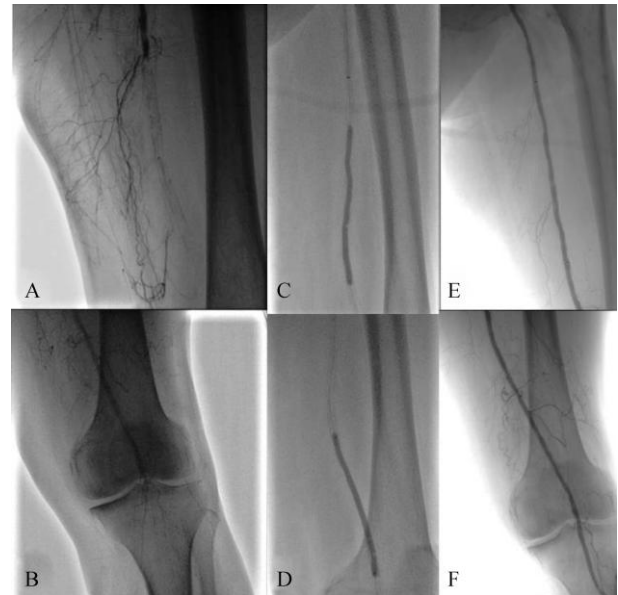

Figure 2 Prolonged high-pressure angioplasty in a severely calcified lesion. (A-B): Baseline digital angiography in a 73-year old woman with severe coronary disease and ischemic heart cardiomyopathy and severe claudication demonstrating a long calcified occlusion of the superficial femoral and popliteal arteries; (E-F): angiographic result after prolonged high pressure angioplasty with a Dorado balloon (C-D).

more dilations until the results were considered acceptable by the operator (< 30% residual stenosis on angiography).

All patients received acetylsalicylic acid 100 mg daily continuously and clopidogrel 75 mg daily for 3 months, if a stent was implanted.

2.2 Definition

Immediate success has been defined as the ability to restore an antegrade flow in the distal vessels with less than 30% of residual stenosis on QCA without acute thrombosis requiring aspiration, or thrombolytic treatment, or flow limiting dissection requiring stent implantation. Restenosis was defined as a reduction in the luminal diameter of more than 50%, as determined by follow-up duplex ultrasound peak velocity ratio. Peak velocity ratio was derived by dividing the peak systolic velocity in the stenotic segment by the peak systolic velocity in the preceding normal segment or, in patients with multiple stenoses, in the adjacent distal segment. A peak velocity ratio > 2.4 was predefined as > 50% stenosis. Target vessel revascularization (TLR) was defined as repeat revascularization of the same superficial femoropopliteal artery, proximal or distal to, or involving the index lesion, or surgical treatment of same superficial femoropopliteal artery.

Complications were divided in intra-procedural and

post-procedural and in major (intra-procedural death, acute renal failure or worsening of chronic renal failure requiring renal replacement therapy, retroperitoneal hemorrhage, vessel rupture requiring emergent surgery, acute limb ischemia requiring emergent thrombolysis or surgery) and minor incidents (distal embolization, self-limiting vessel rupture, no flow limiting dissection, inguinal hematomas not requiring transfusion, arterial pseudoaneurysm, and arteriovenous fistula).

2.3 Statistical analysis

Metric data are given as mean \pm SD and proportions were compared by χ^2 statistics using Yates' corrections. Statistical analysis was performed using a statistical software package (SAS for Windows, version 8.2; SAS Institute; Cary, NC).

3 Results

3.1 Immediate results

The preferred approach was ipsilateral femoral antegrade in 433/620 patients (69.7%) and contralateral cross-over in 164/620 (26.4%) and popliteal retrograde + femoral antegrade in 23/620 (3.7%). Techniques included subintimal angioplasty in 427/620 patients (68.8%) and endoluminal angioplasty in 193/620 patients (31.2%). The prolonged high pressure balloon angioplasty procedure was successful in 86.2% (Table 2) with an intra-procedural complications rate of 15.7 % (Table 3). Seventy-four patients required stent implantation (11.9%, mean diameter 6.5 ± 0.4 mm, mean length 100 ± 20 mm), in 54 cases the stents used were an Everflex stent (Ev3, USA); and in 20 cases a Smart stent (Cordis, Johnson & Johnson, USA), those patients were excluded from the follow-up analysis.

Table 1. Demographic and clinical data of the enrolled patients.

Age, yrs	78.5 \pm 15.8
Female/Male	255/365
Hypertension	415 (67.0%)
Smoke habit	140 (22.5%)
Hypercholesterolemia	301 (48.5%)
Diabetes	492 (79.3%)
Coronary artery disease	299 (48.2%)
Cardiac valve disease	133 (21.4%)
Dilated cardiomyopathy	89 (14.3%)
Chronic renal insufficiency	158 (25.4%)
Mean Rutherford class	5.3 \pm 0.8
Mean ABI	0.29 \pm 0.6

Data are presented as mean \pm SD or *n* (%). ABI: ankle-brachial index.

Table 2. Angiographic characteristics of the treated patients.

Stenosis	189 (33.7%)
Occlusion	411 (66.3%)
Mean vessel diameter, mm	5.8 \pm 1.9
Mean lesion length, mm	351 \pm 123
TASC II A	0 (0)
TASC II B	63 (10.1%)
TASC II C	419 (67.5%)
TASC II D	118 (19.4%)
Target lesion calcification	
None or mild	107 (17.2)
Moderate	392 (63.2)
Severe	211 (34)
Mean balloon diameter, mm	6.0 \pm 1.1
Mean balloon length, mm	195 \pm 46
Mean inflation pressure, atm	17.1 \pm 4.5
Mean inflation duration, min	5.9 \pm 1.9
Mean number of dilation	2.6 \pm 1.1

Data are presented as mean \pm SD or *n* (%). TASC: Inter-Society Consensus for the Management of Peripheral Arterial Disease.

Table 3. Intra-procedural and immediate post-procedural data.

Stent deployment	74/620 (13.5%)
Intra-procedural complications	86/546 (15.7%)
Major	
Acute thrombosis	15/546 (2.7%)
Minor	
No flow limiting dissection	
Recoiling	37/546 (6.7%)
Distal embolization	14/546 (2.5%)
Post-procedural complication	20/546 (3.6%)
Major	
Minor	0(0)
Groin hematoma	16/546 (2.9%)

3.2 Follow-up

56/546 patients (10.2%) died during the follow-up, but completed a follow-up of a mean of 10.1 ± 2.0 months, and thus were not considered lost at the follow-up and were included in the analysis; 41 patients died for cardiac causes; 13 patients for cancer; and no deaths related to the procedure were recorded. At a mean follow-up of 18.1 ± 6.4 months (range 1–24 months), a significant improvement of mean ABI (0.29 ± 0.6 to 0.88 ± 0.3 , $P < 0.01$) and mean Rutherford class (5.3 ± 0.8 vs. 0.7 ± 1.9 , $P < 0.01$) was observed: the primary patency rate was 86.7%. Restenosis was

18.6% (102 patients), whereas TLR was 14.8% (81 patients). Seventy-eight patients (14.2%) were treated with re-angioplasty alone or stent implantation (0.6%, Table 4) after a mean time from the first intervention of 8.2 ± 6.1 months, with a secondary patency rate of 87.7%.

Table 4. Follow-up data.

Mean Rutherford class	0.7 \pm 1.9
Mean ABI	0.88 \pm 0.3
Target lesion revascularization	81/546 (14.8%)
Re-intervention	
PTA alone	
Stent	78/546 (14.2%)
2° re-intervention	
3° re-intervention	8/546 (1.4%)
4° re-intervention	67/546 (12.3%)
	13/546 (2.3%)
	6/546 (1.1%)

ABI: ankle-brachial index; PTA: peripheral transluminal angioplasty.

4 Discussion

Our study suggested that prolonged high pressure balloon angioplasty has acceptable patency, restenosis and complication rates avoiding stent implantation in 87.4% of the cases on mid-term follow-up in a complex cohort of patients with the majority of lesions classified as TASC II C and D.

A recent series of femoropopliteal balloon angioplasty reported a restenosis rate of about 45.0% to 74.3%,^[9–11] whereas TLR has been reported favoring bare metal stent implantation over standard balloon angioplasty, about 13% vs. 55%.^[9–11] Interestingly in these studies, the duration of the inflation in patients randomized to balloon angioplasty was about 120 s and the pressure was reported 8 to 11 atm, far below the pressure used in our series.

Because of the quite high incidence of stent fracture recently reported at 17.8%,^[3] and the still problematic incidence of restenosis after stenting, alternative techniques have been proposed in the past years,^[9–12] such as the cryoplasty.^[13] The excimer laser ablation,^[14] and drug eluting stent,^[15] unfortunately all failed to result in a net benefit over standard angioplasty and stenting.

Recently, the application of drug eluting polymers to the angioplasty balloon has been investigated in randomized trials, suggesting a real improvement in the outcomes of this difficult arterial segment. Compared to standard angioplasty balloon, the paclitaxel-coated balloon has been shown to reduce both TLR (from 27.7% to 12.2 %) and the an-

giographic restenosis (from 45.5% to 18.7%) with no difference in mortality.^[16–19] When an adjunctive bare metal stent has been implanted after DEB, this strategy, compared to standard balloon plus stent, has been suggested to reduce restenosis and target lesion revascularization at 12-month follow-up.^[4] When directly compared to primary stenting with bare metal stent, DEB had similar anti-restenotic efficacy and safety,^[5] whereas when coupled with atherectomy resulted in an improved 1-year Kaplan-Meier freedom from restenosis 84.7% (70.9%–98.5%) vs. 43.8% (30.5%–57.1%) in patients treated with standard angioplasty alone.^[20]

Unfortunately, the economic price of DEB is still high, above 600 Euros in European countries compared to a standard price of 200 Euros for standard angioplasty balloons, whereas the use of standard nitinol stents increased the procedural cost by 57% when compared to standard angioplasty balloons regardless of treatment indication, and added 45% to the overall hospital cost of patients treated for claudication.^[9] Moreover, DEB are not yet produced in lengths over 150 mm and multiple balloons may be used to treat complex TASC II C and D lesions further increasing the costs.

Because a comprehensive, cost effectiveness, economic analysis is still as yet to be produced, and although DEB has clearly the potential to increase the outcomes of femoropopliteal revascularization, it appears evident that a strategy including prolonged high pressure angioplasty with semi-compliant or non-compliant balloons might result in a cost-saving and an effective option.

Our investigation suffers from clear limitations, including the retrospective nature with no randomization between conventional low pressure and high pressure prolonged angioplasty and between angioplasty and stenting implantation. Moreover, the technical characteristics of the three devices, the semi-compliant Mustang and PowerCross and the true non-compliant Dorado balloons might have confused the overall results, being the Dorado balloon is slightly technically different and was specifically studied for heavily calcified vessels. The irregular availability of this device in the two centers at different times has impacted the device selection strategy.

Nevertheless, our retrospective study suggested that prolonged high pressure angioplasty of femoropopliteal lesions appears to be safe and effective, allowing for an acceptable patency and restenosis rates on mid-term, and avoiding stent implantation in such vascular territory. Larger studies and longer follow-up are needed to evaluate this strategy as a cost-effective, alternative strategy to the DEB or/and stent implantation.

References

- 1 BASIL trial investigators. Bypass versus angioplasty in severe ischemia of the leg (BASIL): multicentre, randomised controlled trial. *Lancet* 2005; 366: 1925–1934.
- 2 Acin F, de Haro J, Bleda S, et al. Primary nitinol stenting in femoropopliteal occlusive disease: a meta-analysis of randomized controlled trials. *J Endovasc Ther* 2012; 19: 585–595.
- 3 Davaine JM, Qu érat J, Guyomarch B, et al. Incidence and the clinical impact of stent fractures after primary stenting for TASC C and D femoropopliteal lesions at 1 year. *Eur J Vasc Endovasc Surg* 2013; 46: 201–212.
- 4 Liistro F, Grotti S, Porto I, et al. Drug-eluting balloon in peripheral intervention for the superficial femoral artery: the DEBATE-SFA randomized trial (Drug Eluting Balloon in Peripheral Intervention for the Superficial Femoral Artery). *JACC Cardiovasc Interv* 2013; 6: 1295–1302.
- 5 Fusaro M, Cassese S, Ndrepepa G, et al. Paclitaxel-coated balloon or primary bare nitinol stent for revascularization of femoropopliteal artery: a meta-analysis of randomized trials versus uncoated balloon and an adjusted indirect comparison. *Int J Cardiol* 2013; 168: 4002–4009.
- 6 Cassese S, Byrne RA, Ott I, et al. Paclitaxel-coated versus uncoated balloon angioplasty reduces target lesion revascularization in patients with femoropopliteal arterial disease: a meta-analysis of randomized trials. *Circ Cardiovasc Interv* 2012; 5: 582–589.
- 7 Norgren L, Hiatt WR, Dormandy JA, et al. Inter-Society Consensus for the Management of Peripheral Arterial Disease (TASC II). *Eur J Vasc Endovasc Surg* 2007; 33: S1–S75.
- 8 Ingle H, Nasim A, Bolia A, et al. Subintimal angioplasty of isolated infragenicular vessels in lower limb ischemia: long-term results. *J Endovasc Ther* 2002; 9: 411–416.
- 9 Nguyen BN, Conrad MF, Guest JM, et al. Late outcomes of balloon angioplasty and angioplasty with selective stenting for superficial femoral-popliteal disease are equivalent. *J Vasc Surg* 2011; 54: 1051–1057.
- 10 Schillinger M, Sabeti S, Dick P, et al. Sustained benefit at 2 years of primary femoropopliteal stenting compared with balloon angioplasty with optional stenting. *Circulation* 2007; 115: 2745–2749.
- 11 Schillinger M, Sabeti S, Loewe C, et al. Balloon angioplasty versus implantation of nitinol stents in the superficial femoral artery. *N Engl J Med* 2006; 354: 1879–1888.
- 12 Laird JR, Katzen BT, Scheinert D, et al. Nitinol stent implantation vs. balloon angioplasty for lesions in the superficial femoral and proximal popliteal arteries of patients with claudication: three-year follow-up from the RESILIENT randomized trial. *J Endovasc Ther* 2012; 19: 1–9.
- 13 Shammas NW, Coiner D, Shammas G, et al. Percutaneous lower extremity arterial interventions using primary balloon angioplasty versus cryoplasty: a randomized pilot trial. *Cardiovasc Revasc Med* 2012; 13: 172–176.
- 14 Das TS. Excimer laser-assisted angioplasty for infrainguinal artery disease. *J Endovasc Ther* 2009; 16 (2 Suppl 2): II98–II 104.
- 15 Dake MD, Ansel GM, Jaff MR, et al. Paclitaxel-eluting stents show superiority to balloon angioplasty and bare metal stents in femoropopliteal disease: twelve-month Zilver PTX randomized study results. *Circ Cardiovasc Interv* 2011; 4: 495–504.
- 16 Tepe G, Zeller T, Albrecht T, et al. Local delivery of paclitaxel to inhibit restenosis during angioplasty of the leg. *N Engl J Med* 2008; 358: 689–699.
- 17 Werk M, Langner S, Reinkensmeier B, et al. Inhibition of restenosis in femoropopliteal arteries: paclitaxel-coated versus uncoated balloon: femoral paclitaxel randomized pilot trial. *Circulation* 2008; 118: 1358–1365.
- 18 Scheinert D, Duda S, Zeller T, et al. The LEVANT I (Lutonix paclitaxel-coated balloon for the prevention of femoropopliteal restenosis) trial for femoropopliteal revascularization: first-in-human randomized trial of low-dose drug-coated balloon versus uncoated balloon angioplasty. *JACC Cardiovasc Interv* 2014; 7: 10–19.
- 19 Werk M, Albrecht T, Meyer DR, et al. Paclitaxel-coated balloons reduce restenosis after femoro-popliteal angioplasty: evidence from the randomized PACIFIER trial. *Circ Cardiovasc Interv* 2012; 5: 831–840.
- 20 Sixt S, Carpio Cancino OG, Treszl A, et al. Drug-coated balloon angioplasty after directional atherectomy improves outcome in restenotic femoropopliteal arteries. *J Vasc Surg* 2013; 58: 682–686.