



## Case report

## Two cases of primary ocular adnexal lymphomas diagnosed after pre-biopsy corticosteroid treatment using polymerase chain reaction-based gene rearrangement analysis



Takahiro Kitahara<sup>a</sup>, Shin Imamura<sup>b</sup>, Makoto Ohta<sup>c</sup>, Tadakazu Okoshi<sup>c</sup>, Akira Kobori<sup>d</sup>, Akinori Miyakoshi<sup>a</sup>, Yuki Oichi<sup>a</sup>, Hiroki Toda<sup>a,\*</sup>

<sup>a</sup> Department of Neurosurgery, Fukui Red Cross Hospital, Fukui, Japan

<sup>b</sup> Department of Hematology, Fukui Red Cross Hospital, Fukui, Japan

<sup>c</sup> Department of Pathology, Fukui Red Cross Hospital, Fukui, Japan

<sup>d</sup> Department of Ophthalmology, Fukui Red Cross Hospital, Fukui, Japan

## ARTICLE INFO

## Keywords:

Ocular adnexal lymphomas  
Corticosteroids  
B-cell  
T-cell  
Polymerase chain reaction  
Gene rearrangement  
Immunoglobulin  
T-cell receptor

## ABSTRACT

**Purpose:** To report the limited usefulness of polymerase chain reaction (PCR)-based immunoglobulin (Ig) and T-cell receptor (TCR) gene rearrangement analysis in diagnosing primary ocular adnexal lymphomas (OAL) treated with corticosteroids before biopsy.

**Observations:** This was a case series of two patients: a 47-year-old woman and a 43-year-old man, who both presented with impaired visual acuity and ophthalmoplegia of the involved eyes. Both patients had previously received non-diagnostic biopsy and had been subsequently treated with corticosteroids. The visual acuity and ophthalmoplegia progressively worsened after a variable duration of remission. Ocular magnetic resonance imaging revealed gadolinium-enhancing intra- and extraconal lesions. Systemic evaluations did not reveal any other lesions outside of the orbit. Differential diagnoses were lymphoproliferative disorders, including undiagnosed primary OALs, and idiopathic ocular inflammation. Both patients were exposed to repeated biopsies. The biopsied tissue demonstrated marked lymphocytolysis due to corticosteroid usage; therefore, histology and immunophenotype were non-diagnostic. EuroClonality/BIOMED-2 PCR-based gene rearrangement analyses detected genetic clonalities of Ig and TCR and suggested diagnoses of primary OALs of B-cell and T-cell origins, respectively. An OAL of B-cell origin was treated with radiotherapy; an OAL of a rare T-cell origin was treated with high-dose methotrexate-based chemotherapy and adjuvant radiotherapy. Both patients remained progression free for more than 36 months.

**Conclusions and importance:** PCR-based gene rearrangement analysis can be of limited usefulness in suggesting a diagnosis of primary OAL in patients receiving pre-biopsy corticosteroid treatment. Identification of genetic clonality is of clinical importance to provide treatment options for undiagnosed OALs.

### 1. Introduction

Lymphoid tumors account for approximately 10–20% of orbital mass lesions.<sup>1,2</sup> Lymphomas are the most common tumors arising in the ocular adnexa.<sup>2</sup> The most common primary ocular adnexal lymphoma (OAL) is extranodal marginal zone B-cell lymphoma (EMZL) of the mucosa-associated lymphoid tissue (MALT) type, followed by follicular lymphoma (FL), diffuse large B-cell lymphoma (DLBCL), and mantle cell lymphoma (MCL).<sup>2–4</sup> Peripheral T-cell and natural killer (NK)/T-cell lymphomas are rare among primary OALs.<sup>2–4</sup> Treatment for various primary OALs should be based on accurate diagnosis and differentiation

from other lymphoproliferative disorders, thyroid-associated orbitopathy, and idiopathic orbital inflammation (IOI)<sup>2,5–9</sup>; however, an accurate diagnosis is not always possible. Several clinical conditions may induce non-diagnostic biopsies. Pre-biopsy corticosteroid administration can cause inaccurate diagnosis of lymphomas<sup>10–13</sup>; however, there is a lack of published literature reporting on the diagnostic strategy for steroid-treated primary OALs. Herein, the authors discuss the diagnostic usefulness and limitations of standardized BIOMED-2 multiplex polymerase chain reaction (PCR)-based gene rearrangement assays<sup>14,15</sup> in detecting clonal immunoglobulin (Ig) and T-cell receptor (TCR) gene rearrangements in steroid-treated hyalinized hypocellular

\* Corresponding author. Department of Neurosurgery, Fukui Red Cross Hospital, Tsukimi 2-4-1, Fukui, 918-8501, Japan.

E-mail address: [htoda-nstu@umin.ac.jp](mailto:htoda-nstu@umin.ac.jp) (H. Toda).

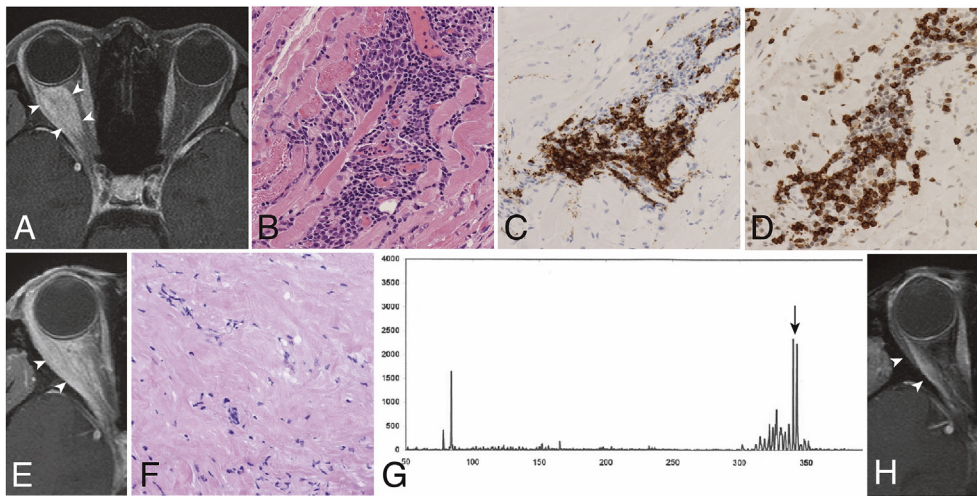
<https://doi.org/10.1016/j.ajoc.2019.100520>

Received 27 November 2018; Received in revised form 14 June 2019; Accepted 15 July 2019

Available online 16 July 2019

2451-9936/© 2019 The Authors. Published by Elsevier Inc. This is an open access article under the CC BY-NC-ND license

(<http://creativecommons.org/licenses/by-nc-nd/4.0/>).



**Fig. 1.** Case 1: Ocular adnexal B-cell lymphoma. A gadolinium-enhanced fat-saturated T1-weighted magnetic resonance (Gd-T1WI MR) image shows a homogeneously enhancing right orbital lesion involving the intraconal space medial to the lateral rectus muscle and lateral to the optic nerve (A, arrowheads). Hematoxylin-eosin (HE) staining of the initial biopsy samples shows proliferating and infiltrating lymphocytes (B, Original magnifications  $\times 200$ ). The lymphocytes contain CD20-positive (C) and CD3-positive (D) cells. Gd-T1WI MR image at recurrence after steroid treatment shows an enhancing lesion lateral to the right optic nerve involving the right lateral rectus muscle and the lacrimal gland (E, arrowheads). HE staining of the repeated biopsy sample shows hyalinized and hypocellular tissue (F). Polymerase chain reaction analysis for rearranged immunoglobulin heavy chain genes reveals clonal amplifications of 350-base pairs (G, arrow). Gd-T1WI MR image 3 years after radiation therapy shows no enhancing lesion (H).

lysis for rearranged immunoglobulin heavy chain genes reveals clonal amplifications of 350-base pairs (G, arrow). Gd-T1WI MR image 3 years after radiation therapy shows no enhancing lesion (H).

OAL tissues. We also highlight the clinical importance of detecting genetic clonality in undiagnosed OALs, including one of T-cell origin with a poor prognosis.

## 2. Case reports

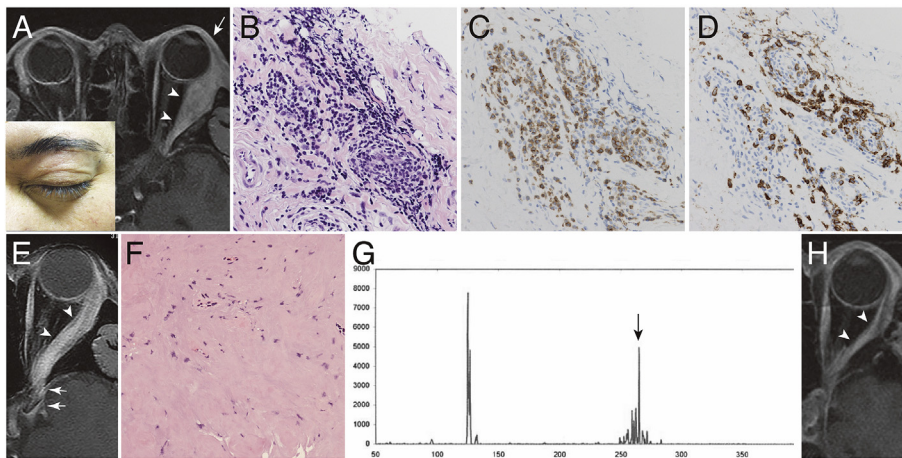
### 2.1. Case 1

A 47-year-old woman was referred to our hospital due to progressive visual loss in the right eye. This patient had also experienced a similar symptom five years ago. At that time, magnetic resonance (MR) imaging demonstrated a right orbital lesion (Fig. 1A). The patient was administered 300 mg of intravenous hydrocortisone for an allergic reaction to computed tomography (CT) contrast dye prior to receiving her initial biopsy. A week later, the patient had received the ocular biopsy, but it was not diagnostic for a lymphoma. The initial biopsy results suggested that the lesion was polyclonal lymphocyte proliferation (Fig. 1B–D) of a non-lymphomatous lymphoproliferative disorder. Therefore, the patient received high-dose intravenous corticosteroid pulse therapy (1 g of methylprednisolone for three days) twice. The patient was in remission until two months prior to the current presentation. On examination, visual acuity in the right eye was 20/400, and right exophthalmos, ptosis, and ophthalmoplegia were noted. Her eyelid and conjunctivae were normal. Orbital MRI revealed an intraconal mass involving the orbital fat. The lesion adjacent to the optic nerve was isointense on MR T1- and T2-weighted images (WIs) and was homogeneously enhanced (Fig. 1E). The lesion did not involve the globe and lacrimal gland. The contralateral orbit was normal. Results of laboratory tests, including serum levels of soluble interleukin-2 receptor, IgG4, and antinuclear antibody, those of systemic CT and positron emission tomography were also normal. The differential diagnoses were an undiagnosed primary OAL, reactive lymphoid hyperplasia, and IOI. The patient underwent a transcranial orbital biopsy. The tissue was markedly hyalinized, fibrous, and hypocellular (Fig. 1F). The immunohistochemistry and lymphocyte common antigen (CD45) gating flow cytometry (FCM) (SRL, Tokyo, Japan) did not identify the cellular clonality from the biopsied tissue. The standardized BIOMED-2 multiplex PCR assay (InVivoScribe Technologies, San Diego, CA, USA)<sup>14,15</sup> detected clonal peaks of Ig heavy chain gene  $V_H(FR1)/J_H$  rearrangements (Fig. 1G), suggesting the presence of clonal B-cells. Based on these pathological findings with the recurrent clinical course following corticosteroid treatment, and considering the imaging results and laboratory tests, the diagnosis of a primary OAL of B-cell origin was favored (T2cN0M0)<sup>16</sup> rather than reactive lymphoproliferative

hyperplasia or IOI. The patient underwent external beam radiotherapy of 40 Gy. Her visual acuity improved to 20/16, and extraocular movements were partially restored. As of July 2019, this patient has since been in remission for five years (Fig. 1H).

### 2.2. Case 2

A 43-year-old man was referred to our hospital after receiving a non-diagnostic biopsy of a left orbital tumor. The patient had a progressive left exophthalmos for two months and orbital MRI demonstrated a left extraconal mass (Fig. 2A). The initial biopsy results revealed polyclonal lymphocyte proliferation (Fig. 2B–D). The patient was treated with 10–40 mg of oral prednisolone for three months until his referral; during this period, he experienced progressive deterioration of his visual acuity. On examination, visual acuity in the left eye was *sensus luminis*, and left exophthalmos, complete ptosis, and ophthalmoplegia were noted. His right eyelid (Fig. 2A, inset), conjunctiva, and other neurological findings were normal. Orbital and brain MRI revealed a lesion that involved the left lacrimal gland (Fig. 2A). The lesion extended toward the left eyelid (Fig. 2A, E) and superior orbital fissure (Fig. 2E). The lesion was hypointense on T1- and T2-WI, homogeneously enhanced, and slightly hyperintense on diffusion weighted images (DWIs). Systemic evaluation did not reveal other lesions outside the orbit or within the orbital vicinity. The differential diagnoses were an undiagnosed primary OAL, reactive and atypical lymphoid hyperplasias, and IOI. Serologic evaluation did not suggest any autoimmune disorders. The patient underwent a transcranial orbital biopsy; however, the tissue was hypocellular (Fig. 2F), so immunohistochemistry and CD45-gating FCM were non-diagnostic. The standardized BIOMED-2 multiplex PCR assay<sup>14,15</sup> detected clonality of the T-cell receptor (TCR)  $\beta$  chain gene  $V\beta/J\beta 2$  rearrangement (Fig. 2G), suggesting the presence of clonal T-cells. Based on these pathological findings with the progressive and steroid-refractory clinical course, and considering the imaging results and laboratory tests a diagnosis of primary OAL of T-cell origin was favored (T4dN0M0)<sup>16</sup> rather than reactive or atypical lymphoproliferative hyperplasias or IOI. The patient underwent five cycles of chemotherapy (14 days per cycle) comprising of methotrexate (3.5 g/m<sup>2</sup> on day one), vincristine (1.4 mg/m<sup>2</sup> on day one), and procarbazine (100 mg/m<sup>2</sup> on days one to seven, odd cycles only; MPV), followed by whole-brain radiation treatment of 50 Gy and two cycles of cytarabine (ara-C) chemotherapy (28 days per cycle, 3 g/m<sup>2</sup> on days one to two). His left eye remained blind; however, as of July 2019, the patient has since been in remission for three years (Fig. 2H).



**Fig. 2.** Case 2: Ocular adnexal T-cell lymphoma. A gadolinium-enhanced fat-saturated T1-weighted magnetic resonance (Gd-T1WI MR) image shows a homogeneously enhancing left orbital lesion involving the lateral rectus muscle (A, arrowheads). The eyelid has no erythema or edema (A, inset). Hematoxylin-eosin (HE) staining of the initial biopsy sample shows lymphocyte proliferation. (B, Original magnifications  $\times 200$ ). The lymphocytes contain CD20-positive (C) and CD3-positive (D) cells. Steroid treatment decreases the lesion size (E); however, the lesion (arrowheads) extends posteriorly to the left cavernous sinus through the superior orbital fissure (arrows). HE staining of the repeated biopsy sample shows hyalinized fibrous tissue and paucity of cells (F). Polymerase chain reaction analysis for rearranged T-cell receptor  $\beta$  chain genes reveals a 260-base pair amplification (G, arrow). Gd-T1WI MR image 3 years after radiation and chemotherapy shows no enhancing lesion (H).

### 3. Discussion

Corticosteroids may be administered to patients with various clinical conditions prior to receiving their biopsy. Critically symptomatic illnesses, such as massive lymphoma, asthma, or autoimmune disease can justify pre-biopsy use of corticosteroids.<sup>11,12</sup> Corticosteroids may also be administered after a non-diagnostic biopsy to control progressive symptoms of lymphoid disorders, as seen in the cases presented herein. Corticosteroid treatment induces lymphocytolysis and alters the cytohistological structure.<sup>10–13</sup> Furthermore, corticosteroid treatment diminishes immunophenotype characteristics of each lymphoproliferative disorder.<sup>10–13</sup> Therefore, in corticosteroid-treated patients, differentiation of OAL from other lymphoproliferative disorders, such as reactive and atypical lymphoid hyperplasias, and the various etiologies of IOI may be more difficult.<sup>2,17</sup>

The standardized BIOMED-2 multiplex PCR assay<sup>14,15</sup> has been used to detect the molecular clonality of Ig/TCR gene rearrangements. The clonality detection rate of this PCR assay can reach 96% in mature B-cell neoplasms and 98% in mature T-cell neoplasms<sup>14,18</sup>; however, various technical and biological pitfalls may account for false positive and negative results in the Ig/TCR clonality testing.<sup>14,19,20</sup> The BIOMED-2 multiplex PCR assay should be performed appropriately according to the EuroClonality/BIOMED-2 guidelines.<sup>14</sup> The clonal detection results of the BIOMED-2 multiplex PCR assay must be interpreted together with the histology, immunophenotype, and cytogenetic data. In examination of corticosteroid-treated tissues, however, such a standard analysis would be difficult due to corticosteroid-induced lymphocytolysis. Therefore, the PCR assay results are examined with the accompanying clinical information, including the laboratory and radiological examinations.<sup>17</sup> For example, as corticosteroid treatment is effective against most lymphoid hyperplasias and IOI,<sup>2,5,6,8,9,17,21</sup> and the recurrence of reactive lymphoid hyperplasia is rare,<sup>5,6,8</sup> the patient's response to the previous corticosteroid treatment may help to identify the etiology. Additionally, positive serological results (such as thyroid function tests, angiotensin-converting enzymes, lysozymes, serum IgG4 levels, antineutrophil cytoplasmic antibodies, anti-SSA (Ro), and anti-SSB (La)) can be predictive of the respective etiology of the IOI.<sup>5,6,8,9,17</sup> MR imaging may also aid diagnostic differentiation by inspecting the exact tumor localization and tumor extent including the extraorbital structures, signal intensities, and patterns on T2-WI, enhanced T1-WI, and DWI.<sup>22–24</sup> Advanced MR-based radiomics analysis may successfully differentiate OAL from IOI.<sup>7</sup> Therefore, these composite diagnostic processes confirming the BIOMED-2 PCR assay results can be limitedly useful in diagnosing equivocal lymphomas that are caused by previous use of corticosteroids.<sup>13</sup> This diagnostic attempt is of clinical value because it may reduce the risk of under treatment of undiagnosed

### OAL.<sup>25</sup>

The clinical outcomes of undiagnosed OALs vary with their pathological types and grades.<sup>26,27</sup> EMZL/MALT, the most common type of OAL, which is reported in approximately 50% of OAL cases, may remit completely with surgery or prednisolone treatment alone.<sup>28</sup> FL, the second most common type of OAL reported in up to 20% of cases, are low-grade and indolent tumors; however, DLBCL, the third most common type of OAL, seen in 5–15% of cases, is aggressive and should be treated with rituximab and chemotherapy with or without external beam radiotherapy.<sup>29</sup> MCL, seen in less than 5% of OAL cases, also requires rituximab and chemotherapy to improve its survival rate up to 80%.<sup>30</sup> Therefore, inaccurate diagnosis and diagnostic delay might contribute to tumor dissemination and clinical stage progression, and may correlate with a worse prognosis in certain types of OALs.

Peripheral T-cell and NK/T-cell lymphomas are found in 0.6–3% of the primary OAL cases.<sup>2,3</sup> Lymphoma of the eyelid, constituting 5% of primary OAL cases, has an exceptionally high prevalence (up to 44%) of T-cell lymphoma.<sup>31</sup> Primary OALs of T-cell origin have a very poor prognosis,<sup>32</sup> especially if not appropriately diagnosed.<sup>25</sup> Meel et al. reviewed 16 reported cases of primary NK/T-cell OAL without nasal or paranasal sinus involvement that had been treated with various chemotherapies, such as the combination of cyclophosphamide, doxorubicin/epirubicin, vincristine, and prednisolone and adjuvant radiotherapy.<sup>32</sup> Twelve of the 16 cases (75%) died after an average of six months, ranging from 1 to 14 months.<sup>32</sup> The SMILE regimen (steroid, methotrexate, ifosfamide, L-asparaginase, and etoposide) has been reported to be associated with a better disease-free survival at 24 months.<sup>32</sup> The MPV- radiotherapy-ara-C regimen has provided progression-free survival for three years in the present case. Identification of TCR clonality can be a pivotal diagnostic component in diagnosing a steroid-treated OAL of T-cell origin, which can be fatal if it is undiagnosed and untreated.<sup>25</sup>

### 4. Conclusions

PCR-based Ig/TCR gene rearrangement analysis may have limited usefulness in suggesting a diagnosis of primary OAL in patients with pre-biopsy corticosteroid treatment. Identifying a genetic clonality may be crucial in suspecting undiagnosed OALs, including the rare and aggressive OAL of T-cell origin.

### Patient consent

The patient consented to publication of the case in writing.



## Funding

No funding or grant support.

## Conflicts of interest

The following authors have no financial disclosures: TK, SI, MO, TO, AK, AM, YO, HT.

## Authorship

All authors attest that they meet the current ICMJE criteria for Authorship.

## Acknowledgements

The authors wish to thank the language editors from the Editage and the Elsevier Language Editing service.

## References

- Ohtsuka K, Hashimoto M, Suzuki Y. A review of 244 orbital tumors in Japanese patients during a 21-year period: origins and locations. *Jpn J Ophthalmol*. 2005;49:49–55.
- Ferry JA, Fung CY, Zukerberg L, et al. Lymphoma of the ocular adnexa: a study of 353 cases. *Am J Surg Pathol*. 2007;31:170–184.
- McKelvie PA, McNab A, Francis IC, Fox R, O'Day J. Ocular adnexal lymphoproliferative disease: a series of 73 cases. *Clin Exp Ophthalmol*. 2001;29:387–393.
- Sniegowski MC, Roberts D, Bakhom M, et al. Ocular adnexal lymphoma: validation of American Joint Committee on Cancer seventh edition staging guidelines. *Br J Ophthalmol*. 2014;98:1255–1260.
- Al-Mujaini A, Wali U, Ganesh A, Al-Hadabi I, Burney I. Ocular adnexal reactive lymphoid hyperplasia in children. *Middle East Afr J Ophthalmol*. 2012;19:406–409.
- Andrew NH, Coupland SE, Pirbhai A, Selva D. Lymphoid hyperplasia of the orbit and ocular adnexa: a clinical pathologic review. *Surv Ophthalmol*. 2016;61:778–790.
- Guo J, Liu Z, Shen C, et al. MR-based radiomics signature in differentiating ocular adnexal lymphoma from idiopathic orbital inflammation. *Eur Radiol*. 2018;28:3872–3881.
- Kubota T, Moritani S. High incidence of autoimmune disease in Japanese patients with ocular adnexal reactive lymphoid hyperplasia. *Am J Ophthalmol*. 2007;144:148–149.
- McNab AA, McKelvie P. IgG4-Related ophthalmic disease. Part II: clinical aspects. *Ophthalmic Plast Reconstr Surg*. 2015;31:167–178.
- Barrantes-Freer A, Engel AS, Rodriguez-Villagra OA, et al. Diagnostic red flags: steroid-treated malignant CNS lymphoma mimicking autoimmune inflammatory demyelination. *Brain Pathol*. 2018;28:225–233.
- Borenstein SH, Gerstle T, Malkin D, Thorner P, Filler RM. The effects of prebiopsy corticosteroid treatment on the diagnosis of mediastinal lymphoma. *J Pediatr Surg*. 2000;35:973–976.
- Kan E, Levi I, Benharroch D. Alterations in the primary diagnosis of lymphomas pretreated with corticosteroid agents. *Leuk Lymphoma*. 2011;52:425–428.
- Shaw A, Iyer V, Rooney N, et al. Diagnosis of primary cerebral lymphomas: possible value of PCR testing in equivocal cases requiring rebiopsy. *Br J Neurosurg*. 2014;28:214–219.
- Langerak AW, Groenen PJ, Bruggemann M, et al. EuroClonality/BIMED-2 guidelines for interpretation and reporting of Ig/TCR clonality testing in suspected lymphoproliferations. *Leukemia*. 2012;26:2159–2171.
- van Dongen JJ, Langerak AW, Bruggemann M, et al. Design and standardization of PCR primers and protocols for detection of clonal immunoglobulin and T-cell receptor gene recombinations in suspect lymphoproliferations: report of the BIMED-2 Concerted Action BMH4-CT98-3936. *Leukemia*. 2003;17:2257–2317.
- Coupland SE, White VA, Rootman J, Damato B, Finger PT. A TNM-based clinical staging system of ocular adnexal lymphomas. *Arch Pathol Lab Med*. 2009;133:1262–1267.
- Mombaerts I, Rose GE, Garrity JA. Orbital inflammation: biopsy first. *Surv Ophthalmol*. 2016;61:664–669.
- Liu H, Bench AJ, Bacon CM, et al. A practical strategy for the routine use of BIMED-2 PCR assays for detection of B- and T-cell clonality in diagnostic haematopathology. *Br J Haematol*. 2007;138:31–43.
- Hummel M, Stein H. Clonality and malignancy. PCR assays for the diagnosis of clonal B- and T-cell proliferations: potentials and pitfalls. *Verhandlungen der Deutschen Gesellschaft für Pathologie*. 2003;87:102–108.
- Payne K, Wright P, Grant JW, et al. BIMED-2 PCR assays for IGK gene rearrangements are essential for B-cell clonality analysis in follicular lymphoma. *Br J Haematol*. 2011;155:84–92.
- Yu WK, Kao SC, Yang CF, Lee FL, Tsai CC. Ocular adnexal IgG4-related disease: clinical features, outcome, and factors associated with response to systemic steroids. *Jpn J Ophthalmol*. 2015;59:8–13.
- Kapur R, Sepahdari AR, Mafee MF, et al. MR imaging of orbital inflammatory syndrome, orbital cellulitis, and orbital lymphoid lesions: the role of diffusion-weighted imaging. *AJNR Am J Neuroradiol*. 2009;30:64–70.
- Politi LS, Forghani R, Godi C, et al. Ocular adnexal lymphoma: diffusion-weighted mr imaging for differential diagnosis and therapeutic monitoring. *Radiology*. 2010;256:565–574.
- Taylor TD, Gupta D, Dalley RW, Keene CD, Anzai Y. *Orbital Neoplasms in Adults: Clinical, Radiologic, and Pathologic Review*. vol. 33. Radiographics: a review publication of the Radiological Society of North America, Inc; 2013:1739–1758.
- Papalkar D, Sharma S, Francis IC, Downie JA, Thanakrishnan G, Hughes LJ. A rapidly fatal case of T-cell lymphoma presenting as idiopathic orbital inflammation. *Orbit*. 2005;24:131–133.
- Hatef E, Roberts D, McLaughlin P, Pro B, Esmaeli B. Prevalence and nature of systemic involvement and stage at initial examination in patients with orbital and ocular adnexal lymphoma. *Arch Ophthalmol*. 2007;125:1663–1667 (Chicago, Ill: 1960).
- Honavar SG, Manjandavida FP. Recent advances in orbital tumors—A review of publications from 2014–2016. *Asia Pac J Ophthalmol Phila. (PA)*. 2017;6:153–158.
- Sjo LD, Heegaard S, Prause JU, Petersen BL, Pedersen S, Ralfkiaer E. Extranodal marginal zone lymphoma in the ocular region: clinical, immunophenotypic, and cytogenetic characteristics. *Investig Ophthalmol Vis Sci*. 2009;50:516–522.
- Munch-Petersen HD, Rasmussen PK, Coupland SE, et al. Ocular adnexal diffuse large B-cell lymphoma: a multicenter international study. *JAMA Ophthalmol*. 2015;133:165–173.
- Rasmussen P, Sjo LD, Prause JU, Ralfkiaer E, Heegaard S. Mantle cell lymphoma in the orbital and adnexal region. *Br J Ophthalmol*. 2009;93:1047–1051.
- Svendsen FH, Heegaard S. Lymphoma of the eyelid. *Surv Ophthalmol*. 2017;62:312–331.
- Meel R, Dhiman R, Wadhvani M, Kashyap S, Sharma S, Gogia A. Isolated extranodal natural killer T-cell lymphoma of the orbit in a young patient: complete regression with the SMILE regimen. *Ocular Oncol Pathol*. 2017;3:45–48.