

# Treatment strategies for early neurological deficits related to malpositioned pedicle screws in the lumbosacral canal

A PILOT STUDY



**J-Y. Du,  
J-S. Wu,  
Z-Q. Wen,  
X-J. Lin**

*The First Affiliated Hospital, College of Medicine Zhejiang University, Hangzhou, China*

■ J-Y. Du, MD, Orthopaedic Surgeon, Co-first author, The First Affiliated Hospital, College of Medicine, Zhejiang University, No. 79 Oinchun Road, Hangzhou, China.

■ J-S. Wu, MD, Orthopaedic Surgeon, Co-first author, The First Affiliated Hospital, College of Medicine, Zhejiang University, No. 79 Oinchun Road, Hangzhou, China.

■ Z-Q. Wen, MD, Orthopaedic Surgeon, The First Affiliated Hospital, College of Medicine, Zhejiang University, No. 79 Oinchun Road, Hangzhou, China.

■ X-J. Lin, MD, PhD, Orthopaedic Surgeon, Professor, The First Affiliated Hospital, College of Medicine, Zhejiang University, No. 79 Oinchun Road, Hangzhou, China.

Correspondence should be sent to X-J. Lin; e-mail: [linxiangjin2014@126.com](mailto:linxiangjin2014@126.com)

doi:10.1302/2046-3758.52.2000477

*Bone Joint Res* 2016;5:46–51.  
Received: 22 June 2015;  
Accepted: 27 October 2015

## Objectives

To employ a simple and fast method to evaluate those patients with neurological deficits and misplaced screws in relatively safe lumbosacral spine, and to determine if it is necessary to undertake revision surgery.

## Methods

A total of 316 patients were treated by fixation of lumbar and lumbosacral transpedicle screws at our institution from January 2011 to December 2012. We designed the criteria for post-operative revision scores of pedicle screw malpositioning (PRSPSM) in the lumbosacral canal. We recommend the revision of the misplaced pedicle screw in patients with PRSPSM = 5' as early as possible. However, patients with PRSPSM < 5' need to follow the next consecutive assessment procedures. A total of 15 patients were included according to at least three-stage follow-up.

## Results

Five patients with neurological complications (PRSPSM = 5') underwent revision surgery at an early stage. The other ten patients with PRSPSM < 5' were treated by conservative methods for seven days. At three-month follow-up, only one patient showed delayed onset of neurological complications (PRSPSM 7') while refusing revision. Seven months later, PRSPSM decreased to 3' with complete rehabilitation.

## Conclusions

This study highlights the significance of consecutively dynamic assessments of PRSPSMs, which are unlike previous implementations based on purely anatomical assessment or early onset of neurological deficits, and also confirms our hypothesis that patients with early neurological complications may not need revision procedures in the relatively broad margin of the lumbosacral canal.

**Cite this article:** *Bone Joint Res* 2016;5:46–51.

**Keywords:** pedicle screws; mispositioning; lumbar spine; neurological deficits; treatment

## Article focus

- The study has developed a novel approach for assessing patient's recovery following misplaced pedicular screws.
- The study shows that patients with early neurological complications may not need revision procedures in relatively broad margin of lumbosacral canal.

## Key messages

- It is a simple and fast method to evaluate those patients with neurological deficits and misplaced screws.
- It has application in deciding whether to re-operate on a patient with neurological deficits and misplaced screws

## Strengths and limitations

- A strength of our study is the PRSPSM of surgical outcomes in an objective and dynamic way.
- The small number of patients and short follow-up are limitations of this study.

## Introduction

Pedicle screws have been effectively used to enhance spine arthrodesis. A significant advantage in using transpedicular screws is the rigidity that securely fixes the vertebral motion segments. Compared with cervical and thoracic spine, lumbar or lumbosacral spine can provide a safer margin for screw insertion due to morphometric and anatomical characteristics.<sup>1-3</sup>

However, the rate of screw misplacement, especially in the lumbosacral canal, is more than 8.7%.<sup>4</sup> Screw malpositioning may result in serious complications, including vascular and neurological deficits (radicular pain, motor and sensory dysfunction), dural tear, epidural haematoma, and pedicle fracture due to instruments loosening and pulling out.<sup>5-7</sup> Di Silvestre et al<sup>8</sup> reported a 4.3% rate of re-operation for misplaced pedicle screw in thoracic vertebrae, but most of those revision surgeries were for asymptomatic malpositioning, which may lead to tremendous waste of medical resources, and psychological and physical harm to those re-operative patients. Re-operation is often determined by surgeons' subjective perception and patients' clinical symptoms, but it is widely accepted that the appearance of post-operative neurological deficits is the benchmark for revision surgery. However, there is no standard assessment method for revision determination.

The purpose of our pilot study was to employ a simple and fast method to evaluate post-operative revision scores of pedicle screw malpositioning (PRSPSM) in those patients with neurological deficits and misplaced screws in relatively safe lumbar or lumbosacral spine, and to determine if it is necessary to undertake revision surgery. The theoretical basis and strategy of PRSPSM is deduced from enough tolerant margin of lumbar and lumbosacral central canal and nerve root canal compared with cervical and thoracic vertebrae canal. Moreover, adjacent neural structure may produce a certain degree of anatomical reconstruction and fit new anatomical space due to malpositioned screws, which was possibly caused by the flexibility and regeneration of nerve fibres. We hypothesised that many patients with misplaced pedicle screws in the lumbar and lumbosacral canal or superior/inferior pedicle wall perforation may have early neurological deficits, and often need no revision according to the results from several consecutive dynamic assessments by PRSPSM in a relatively long-term period (at least 12 months).

## Materials and Methods

A total of 316 patients were treated by laminectomy, decompression of spinal canal and posterior lumbar

interbody fusion with single oblique cage supplemented pedicle screw-rod fixation (PLIF) at our institution from January 2011 to December 2012. These patients suffered from degenerative disc herniation, lumbosacral stenosis, spondylolisthesis and lumbosacral vertebrae fracture, but not from serious idiopathic spinal deformity (scoliosis, kyphosis and lordosis) and secondary severe deformity (vertebral infection, tumour and other pathologic ruin). We only included pedicle screw encroachment in the vertebrae canal and medially/superior/inferior perforation of pedicle wall, but excluded lateral wall and anterior vertebrae body cortex breaches. Moreover, only patients with post-operative early neurological deficits were included. The neurological deficits were displayed as post-operative emerging motor weakness/sensory disturbance/bladder dysfunction.<sup>9</sup> All were assessed post-operatively by plain radiographs and/or CT (CT: GE CT/T 8800, General Electric, Milwaukee, Wisconsin) scan and/or MRI (MR: GE 1.5 Tesla Signa System, General Electric), and by consecutive PRSPSMs if neurological deficits emerged. Meanwhile, consensus was acquired by an independent radiologist (Y-J Z) and two spinal surgeons (J-Y D and J-S W), respectively. If screw malpositioning and early neurological deficits were observed within post-resuscitation period or 24 hours post-operatively, patients should receive PRSPSM assessment including the following five objectives (Table I).<sup>10,11</sup>

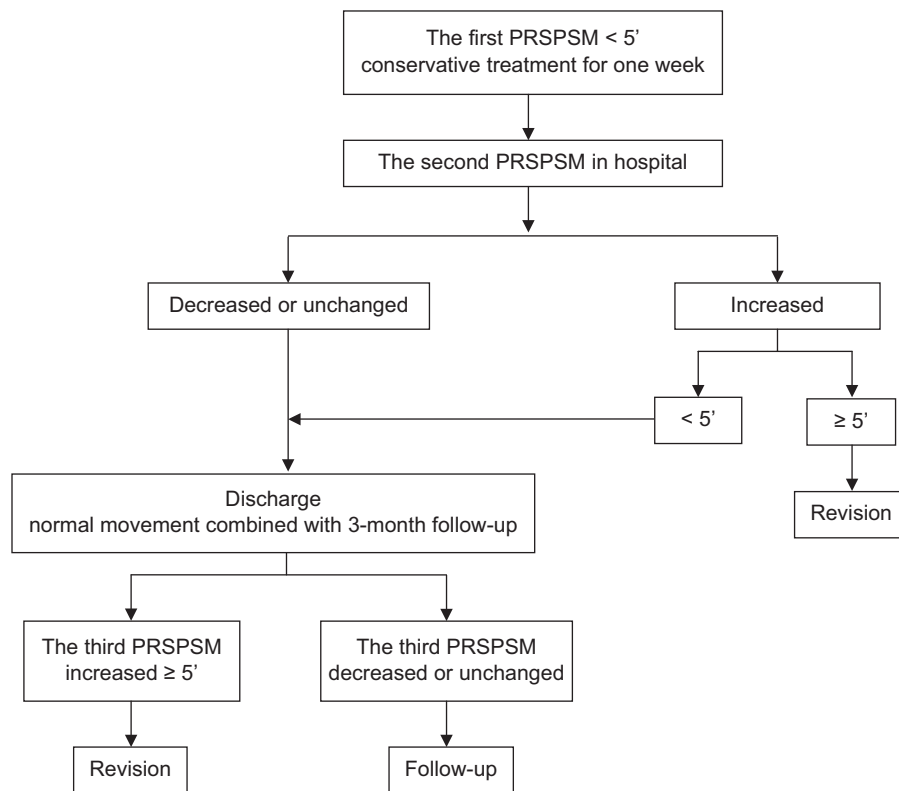
Patients with PRSPSM  $\geq 5$  were suggested to revise the misplaced pedicle screw as early as possible. However, patients with PRSPSM  $< 5$  need to undergo the next non-operating consecutive assessment procedures (Fig. 1).

The study was approved by the Ethics Committee of The First Affiliated Hospital, School of Medicine, Zhejiang University. We have obtained written informed consent from all participants. All of the study procedures were finished in accordance with the Declaration of Helsinki and relevant policies in China.

**Peri-operative procedure.** The operation was performed by one of three attending spinal specialists (X-JL; J-YD; J-SW) who specialised in the placement of pedicle screws. The same instrumentation system was used: Expedium (DePuy Synthes Spine, Inc., Paramount Drive, Raynham, Massachusetts) and Colorado 2" Spinal System (Medtronic Sofamor Danek, Warsaw Orthopedic, Inc., Memphis, Tennessee). Three investigators who were not involved in the surgery or post-operative care were required to judge the accuracy of screw position independently. Patients with early post-operative neurological deficits received the plain radiograph examination. If there was any doubt about a misplaced screw in the vertebrae canal or with superior/inferior pedicle wall breaches (anatomical location accounting for neurological symptoms must correspond to misplaced screw position), the patient should receive a CT scan and/or MR imaging. Screw position was scored in one of five ways: completely within the pedicle (excluded), penetration of

**Table 1.** Post-operative revision scores of pedicle screw malpositioning (PRSPSM) assessment.

Objective	Assessment	Score	Score
Medial pedicle wall breach: <sup>10</sup> degree of anatomical violation	< 2 mm	1'	
	2 mm to 4 mm	2'	
	> 4 mm	3'	
Inferior pedicle wall breach: degree of anatomical violation	Yes	1'	
	No	0'	
Post-operative Frankel scale changing degree (compared with pre-operative nerve function): <sup>11</sup> assessment of neurological deficit resulted in pedicle screw malpositioning	Unchanged Frankel scale	0'	
	1° increase	3'	
	More than 1° increase	5'	
Visual analogue scale (VAS): pain assessment resulted from irritation of nerve root and compression of spinal cord	No pain	0'	
	VAS < 3'	1'	
	VAS ≥ 3'	2'	
	Patients wish to undergo revision surgery	Yes	1'
	No	0'	

**Fig. 1**

Post-operative assessment procedures for patients with malpositioned pedicle screws in the lumbar/lumbosacral canal and with superior/inferior pedicle wall breaches. PRSPSM, pedicle screw malpositioning.

the medial pedicle wall (< 2 mm, 2 mm to 4 mm and > 4 mm) (included), superior or inferior pedicle wall breach (included), penetration of the lateral pedicle wall (excluded), or penetration of the anterior vertebral body cortex (excluded).

**Operative procedure.** All patients were treated by laminectomy, decompression of spinal canal and posterior lumbar interbody fusion with single oblique cage supplemented pedicle screw-rod fixation (PLIF). The patients were positioned prone on the operating table. To protect neural elements and the disc space at the arthrodesis

level, all pedicle screws were inserted under multi-planar fluoroscopic imaging with C-arm. A standard midline incision was made to expose the central posterior tissues over the instrumented level. An image at the superior endplate and central spinous process between the pedicles was made to ensure that the radiograph was parallel to the target pedicle in the sagittal plane. Adequate exposure of the facet joints at each level was needed for proper delineation of the anatomical topograph of the pedicles.<sup>12</sup> The entry point in the pedicle approach zone could be confirmed by decorticating procedure to expose

**Table II.** A total of 15 patients with pedicle screws misplaced in lumbar and lumbosacral vertebrae.

Patients/ revision	Gender	Age	Cause of admission	Segments of arthrodesis	Encroachment of screws	The first PRSPSM	The second PRSPSM	The third PRSPSM
1/ Yes	M	53	LS,DDH	L5/S1	S1(R)	6'	—	—
2/ No	F	64	LS,DDH	L4/ L5/S1	L4(R), L5(R)	4' L4(R) / 4' L5(R)	3'/ 3'	3'/ 3'
3/ No	F	56	LS,DDH	L4/ L5/S1	L5(R)	3'	2'	2'
4/ No	M	30	F/SJD,SF	L5/S1/S2/ I	S2(R)	4'	4'	3'
5/ Yes	M	40	S	L5/S1	L5(L), L5(R)	9' L5(L) / 9' L5(R)	—	—
6/ No	F	75	F/LCF	T11/T12/L2~L4	L3 (R)	3'	2'	3'
7/ No	F	64	LS,DDH	L3/ L4/L5	L3 (R)	4'	3'	7'
8/ Yes	M	65	LS,DDH	L4/ L5/S1	L5 (R), S1(R)	11' L5(R) / 9' S1 (R)	—	—
9/ No	F	51	S	L4/ L5	L4 (R), L5 (R)	4' L4(R) / 4' L5 (R)	3'/ 3'	3'/ 3'
10/ Yes	F	57	TB	L4/ L5/I	L5 (L)	12'	—	—
11/ No	M	58	DDH	L4/ L5	L4(R)	4'	4'	3'
12/ No	M	58	DDH, S	L5/S1	L5(R)	3'	2'	2'
13/ No	M	68	DDH	L4/ L5	L4(L)	2'	2'	1'
14/ Yes	M	57	F	T12/L2	L2(R)	10'	—	—
15/ No	F	52	S	L4/ L5	L5 (L)	4'	4'	3'

LS, lumbosacral stenosis; DDH, degenerative disc herniation; F, falling accident; SJD, sacroiliac joint dislocation; SF, sacral fracture; I, ilium; S, spondylolisthesis; LCF, lumbar compression fractures

the cancellous bone. The pedicle was cannulated with an awl and T-probe. Special care was needed to advance the awl or probe gradually. If there was resistance, the drilling angle and entry point should be adjusted with the aid of direct fluoroscopic vision. Once the pilot hole was drilled, and solid bone margins along the pedicle wall and a bony base in the bottom of the hole were confirmed, screws were then inserted into the pedicles that were linked with titanium rods. If laminectomy or wider exposure was implemented, the screws were also inserted by direct visualisation and palpation.<sup>10</sup> The intervertebral disc was extracted and interbody fusion was performed with a cage implanted.

## Results

All patients received plain radiographs, CT scans and/or MR images post-operatively. A total of 19 pedicle screws (1409 screws in total) in 15 patients (316 patients) medially/superiorly/inferiorly penetrated the pedicle wall. The mean follow-up of the 15 patients was 19.3 months (11 to 26). All had a different degree of post-operative neurological deficit associated with misplaced screws. According to PRSPSM strategy, five patients with neurological complications (misplaced screws) were found to have PRSPSM  $\geq$  5' and received revision procedures at an early stage (one to four days after the first operation). In the follow-up, the symptoms were improved in the patients after revision surgery. The other ten patients with PRSPSM < 5' were treated by conservative methods (absolute bed rest, methylprednisolone 80 mg intravenous injection twice a day, 20% mannitol 125 ml intravenous drip twice a day and mecobalamin 500 mg orally three times a day)<sup>13-16</sup> for seven days, and were discharged when PRSPSM was lower than 5' at the second assessment. At three-month follow-up, most patients, except case seven, were in gradual rehabilitation with normal motion post-operatively. In case seven, the first

PRSPSM was 4' (A1', B1', D2') and the second assessment was that of PRSPSM 3' (A 1', B1', D1'), but the third assessment was that of PRSPSM 7' (A1', B1', C3', D2'). The patient exhibited delayed appearance of decreasing muscle strength grade IV (Frankel score D), numbness and radicular pain in the right lower limb, and was recommended revision surgery. However, the 56-year-old female patient refused to undergo revision surgery but did attend further follow-up. At seven-month follow-up, the score of PRSPSM decreased to 3' (A 1', B1', D1') and the patient showed complete rehabilitation of lower leg muscle strength except for occasional mild numbness and pain (Table II).

## Discussion

This study was designed to provide a pilot clue for the necessity of post-operative revision surgery using a simple and fast assessment method.

Previous scoring systems regarding screw insertion accuracy had many limitations, especially in the analysis of screw anatomical position without the combination of quantitative measurements of clinical symptoms, such as the degree of post-operative neurological deficit and patients' subjective assessment of sensation including pain, and willingness to undergo revision surgery.<sup>17</sup> In addition, previous scoring methods mostly rely on statistical analysis, which is not a continuous dynamic procedure such as the consecutive standardised PRSPSMs described in our study. Neurological function can change along with post-operative treatment and rehabilitation procedure. Therefore, the decision-making procedure regarding revision surgery is not based on spinal surgeons' subjective perception, but on objective scores. PRSPSM provided five important objective assessments for the determination of spinal surgery, especially for changes in the dynamic Frankel scale and visual analogue scale.

The risk of neurological injury caused by cortical perforation is induced by the pedicle's proximity to the neural elements. The pedicle cortex is separated medially from the dural sac by a thin layer (2 mm in thickness) of epidural fat.<sup>18</sup> Nerve root irritation may be a very common phenomenon for medially misplaced screws. A study of 131 misplaced screws in 30 patients showed that the incidence rates of cortical penetration and medial wall penetration were 40% and 29%, respectively. Moreover, the deviation on 6 mm CT scans indicated a high risk of nerve root injury.<sup>19</sup> In another study,<sup>3</sup> researchers attempted to define the anatomical relationships quantitatively between the lumbar pedicle and the dural sac medially, and the lumbar pedicle and the nerve roots superiorly/inferiorly. The results demonstrated that from L1 to L5 levels, average pedicle-dural sac distance (PDSD) and pedicle–superior nerve root distance (PSRD) increased significantly from 1.29 mm to 1.56 mm and from 4.12 mm to 5.25 mm, respectively, while the mean pedicle–inferior nerve root distance (PIRD) was 1.1 mm at the L1 level and 1.06 mm at the L5 level.<sup>3</sup> Moreover, there was no statistical difference between lumbar levels in the same study.<sup>3</sup> Therefore, it is very important not to perforate the inferior cortex at all lumbar levels as far as possible.


In our study, however, case seven suggested that the symptomatic nerve root impingement resulting from misplaced pedicle screw could be early and partly attenuated (the first PRSPSM was 4', the second PRSPSM was 3'). The potential consequence could be explained by the dural sac, epidural fat and cerebrospinal fluid compensating the screw impingement due to stenotic space around the peripheral nerve root during the pre-operative period. Unfortunately, with the traction and impingement to neural root under normal conditions of movement, the patients had nerve root irritation again at three months post-operatively, even with lower limb muscle strength decreasing (muscle strength grade IV, PRSPSM was 7'). The patient didn't have revision surgery and received conservative treatment. At the seven-month post-operative follow-up, PRSPSM decreased to 3' (A 1', B 1', D 1') and the patient had complete rehabilitation of lower leg muscle strength except for occasional mild numbness and pain. The result could be partially explained by findings from Gertzbein and Robbins.<sup>17</sup> According to their study, 4 mm of canal encroachment in the straight spine could be tolerated without impinging the spinal cord. This 4 mm 'safe zone' was confirmed with 2 mm of epidural space and 2 mm of subarachnoid space by CT myelogram. In the present study, medial wall perforation of over 4 mm in the lumbar canal was observed in five cases and all patients received revision surgery. Moreover, less than 2 mm medial/inferior violation was identified in eight cases excluding the perforation over 6 mm in the sacral canal of case four. The case four results suggested that 6 mm of medial violation may

not be the absolute cut-off point for revision, and this finding had never been described in previous studies.<sup>10,17</sup> Compared with the lumbar canal, the adjacent neural tissues may acquire more buffering space in the sacral canal. All of the ten non-revised cases, including case seven or case two from the lumbar canal violation and case four from the sacral canal violation, might validate our initial hypothesis that adjacent neural injury could acquire long-term anatomical reconstruction and regeneration.

A recent study reported the neurological outcome and the management of misplaced pedicle screws within the spinal canal, in which nine patients with idiopathic scoliosis were observed to have delayed neurological complications at two years or more after surgery, and they strongly recommended removing any misplaced pedicle screw in the spinal canal.<sup>20</sup> However, unlike our criteria, the five-year follow-up in the above study only included the deformities of the thoracic vertebrae with exceedingly variable pedicles and severe screw malpositioning, while late screw loosening mainly accounted for loss of correction and neurological complications. Therefore, the results of our study were different from those in previous studies because of different criteria and levels of violation of the spine.

In conclusion, this study emphasised the significance of consecutive dynamic assessments of PRSPSM, preferably at three different periods: the first, immediately after surgery; the second, at the peak period of tissue oedema (one week post-operatively); the third, three months post-operatively during normal conditions of movement). Unlike previous implementations, this study was not based purely on anatomical assessment or early onset of neurological deficits.

### Supplementary material

 Procedure images for cases two and four are available alongside the online version of this article at [www.bjr.boneandjoint.org.uk](http://www.bjr.boneandjoint.org.uk)

### References

1. Ebraheim NA, Xu R, Darwich M, Yeasting RA, Yeasting RA. Anatomical relations between the lumbar pedicle and the adjacent neural structures. *Spine (Phila Pa 1976)* 1997;22:2338-2341.
2. Attar A, Ugur HC, Uz A, et al. Lumbar pedicle: surgical anatomical evaluation and relationships. *Eur Spine J* 2001;10:10-15.
3. Söyüncü Y, Yildirim FB, Sekban H, et al. Anatomical evaluation and relationship between the lumbar pedicle and adjacent neural structures: an anatomical study. *J Spinal Disord Tech* 2005;18:243-246.
4. Kosmopoulos V, Schizas C. Pedicle screw placement accuracy: a meta-analysis. *Spine (Phila Pa 1976)* 2007;32:E111-E120.
5. Hicks JM, Singla A, Shen FH, Arlet V. Complications of pedicle screw fixation in scoliosis surgery: a systematic review. *Spine (Phila Pa 1976)* 2010;35:E465-E470.
6. Merloz P, Tonetti J, Pittet L, et al. Computer-assisted spine surgery. *Comput Aided Surg* 1998;3:297-305.
7. Gautschi OP, Schatlo B, Schaller K, Tessitore E. Clinically relevant complications related to pedicle screw placement in thoracolumbar surgery and their management: a literature review of 35,630 pedicle screws. *Neurosurg Focus* 2011;31:E8.
8. Di Silvestre M, Parisini P, Lolli F, Bakaloudis G. Complications of thoracic pedicle screws in scoliosis treatment. *Spine (Phila Pa 1976)* 2007;32:1655-1661.

9. **Fujiwara A, Kobayashi N, Saiki K, et al.** Association of the Japanese Orthopaedic Association score with the Oswestry Disability Index, Roland-Morris Disability Questionnaire, and short-form 36. *Spine (Phila Pa 1976)* 2003;28:1601-1607.
10. **Amato V, Giannachi L, Irace C, Corona C.** Accuracy of pedicle screw placement in the lumbosacral spine using conventional technique: computed tomography postoperative assessment in 102 consecutive patients. *J Neurosurg Spine* 2010;12:306-313.
11. **Jiang T, Zhao J, He M, et al.** Outcomes and Treatment of Lumbosacral Spinal Tuberculosis: A Retrospective Study of 53 Patients. *PLoS One* 2015;10:e0130185.
12. **Louis R.** Fusion of the lumbar and sacral spine by internal fixation with screw plates. *Clin Orthop Relat Res* 1986;203:18-33.
13. **Amini-Saman J, Karbasrushman A, Ahmadi A, Bazargan-Hejazi S.** Intravenous mannitol for treatment of abducens nerve paralysis after spinal anesthesia. *Int J Obstet Anesth* 2011;20:271-272.
14. **Baysefer A, Erdogan E, Kahraman S, et al.** Effect of mannitol in experimental spinal cord injury: an ultrastructural and electrophysiological study. *Neurol India* 2003;51:350-354.
15. **Farsi L, Naghib Zadeh M, Afshari K, et al.** Effects of combining methylprednisolone with magnesium sulfate on neuropathic pain and functional recovery following spinal cord injury in male rats. *Acta Med Iran* 2015;53:149-157.
16. **Zhang YF, Ning G.** Mecobalamin. *Expert Opin Investig Drugs* 2008;17:953-964.
17. **Gertzbein SD, Robbins SE.** Accuracy of pedicular screw placement in vivo. *Spine (Phila Pa 1976)* 1990;15:11-14.
18. **Roy-Camille R, Saillant G, Mazel C.** Internal fixation of the lumbar spine with pedicle screw plating. *Clin Orthop Relat Res* 1986;203:7-17.
19. **Castro WH, Halm H, Jerosch J, et al.** Accuracy of pedicle screw placement in lumbar vertebrae. *Spine (Phila Pa 1976)* 1996;21:1320-1324.
20. **Mac-Thiong JM, Parent S, Poitras B, Joncas J, Hubert L.** Neurological outcome and management of pedicle screws misplaced totally within the spinal canal. *Spine (Phila Pa 1976)* 2013;38:229-237.

**Funding Statement**

- This work was supported by Zhe-Jiang province natural funds (LY13H150002) and Zhe-Jiang province medical science funds (201338379).

**Author Contribution**

- J-Y. Du, Writing the paper, Performed surgeries, Data analysis.
- J-S. Wu, Performed surgeries.
- Z-Q. Wen, Data collection.
- X-J. Lin, Guided the research.

**ICMJE conflict of interest**

- None declared.

© 2016 X-J Lin et al. This is an open-access article distributed under the terms of the Creative Commons Attribution licence (CC-BY-NC), which permits unrestricted use, distribution, and reproduction in any medium, but not for commercial gain, provided the original author and source are credited.