

Very late onset corneal haze in a photorefractive keratectomy patient associated with presumed viral keratoconjunctivitis

Karmiris Efthymios, Machairoudia Genovefa¹,
Armenis John², Magoulas Michael³

We report a rare case of very late-onset haze triggered by viral conjunctivitis, >20 years after treatment of moderate myopia with photorefractive keratectomy (PRK), and its successful management.

Key words: Photorefractive keratectomy complications, very late onset haze, viral conjunctivitis

Photorefractive keratectomy (PRK) is a safe and effective surgical procedure in correcting refractive errors. Corneal haze is a serious complication in PRK, clinically observed as subepithelial reticular opacities, consisting of a bright layer of subepithelial deposits that gradually develop at the epithelial-stromal junction. The most common type of haze occurring after PRK starts 1 week postoperatively, increases to a peak level between 1 and 3 months, and declines slowly thereafter, resolving within 1 year at maximum without causing clinical symptoms.^[1] It has been usually correlated with the depth of ablation and the smoothness of the stromal surface after the ablation.^[2] However, late onset haze, often noted between 2 and 5 months postoperatively, has been reported to occur in 1%–4% of eyes that have surface ablation procedures such as PRK without mitomycin-C prophylaxis and has been associated with moderate to high myopic ablations (more than –6.00 D).^[3] It can severely compromise vision, lead to refractive regression and can last up to 3 years.^[4]

Access this article online	
Quick Response Code:	Website: www.ijjo.in
	DOI: 10.4103/ijjo.IJO_1789_19

Consultant Ophthalmic Surgeon, Anterior Segment Specialist, Hellenic Air Force General Hospital, Affiliated Centers: Athens Refractive Laser Center, ¹Specialist Registrar, Hellenic Air Force General Hospital, ²Consultant Ophthalmic Surgeon, Hellenic Red Cross General Hospital, ³Consultant Ophthalmic Surgeon, Anterior Segment Specialist, Athens Refractive Laser Center, Athens, Greece

Correspondence to: Dr. Karmiris Efthymios, Department of Ophthalmology, Hellenic Air Force General Hospital, 3 P. Kanelloupolou Av, Athens, Greece. E-mail: tkarmiris@yahoo.com

Received: 13-Oct-2019

Revision: 26-Dec-2019

Accepted: 02-Jan-2020

Published: 25-May-2020

Case Report

A 43-year-old man with free medical history underwent an uneventful PRK without MMC in 1996. His preoperative refraction was –5.25 –0.50 × 180 in the right eye (OD) and –5.00 D in the left eye (OS). His 6-month postoperative vision was 20/20 in both eyes (BE) uncorrected.

During a routine eye check in 2016, his BCVA was recorded 20/20 in BE with –1.50 OD and –1.75 –0.50 × 150 OS. Patient had still free medical history, including history of diseases that may possibly impair his cornea such as rosacea or allergic/atopic diseases.

In April 2017, he suffered from an episode of adenoviral keratoconjunctivitis in BE. Diagnosis was based on clinical presentation that apart from follicular conjunctivitis included pharyngoconjunctival fever and periauricular lymphadenopathy and had highly contagious character involving also other members of his family and work colleagues.^[5] Herpetic involvement was also excluded with a negative PCR result. Following a 2-week course of treatment with lubricants and topical dexamethasone 0.1% qid, there was remission of symptoms and signs and BCVA was recorded 20/20 in BE without any change in his previous prescription.

He then presented in February 2018 complaining of blurred vision and decreased acuity in his left eye. He mentioned gradual deterioration of visual acuity over the past six months and symptoms of diplopia which interfered significantly with his job as a surgeon due to bad binocular and hence stereoscopic vision. The BCVA was 20/20 with –1.50 OD, and 20/32 with –6.00 –1.75 × 180 OS. Slit lamp examination revealed grade 3–4 stromal corneal haze over the papillary axis using the grading scale proposed by Hanna *et al.*^[6] and corneal epithelial hyperplasia overlying left eye [Fig. 1a and b]. No corneal infiltrate or injection of the conjunctival vessels was noted. Topical dexamethasone 0.1% qid was initiated, with haze being unresponsive after 1-month treatment. Dexamethasone was replaced by prednisolone sodium phosphate 1% on a tapering dosage scheme for another month. At the end of the 2-month treatment, no improvement was observed. There was no change of initial VA and refraction. Corneal topography (Oculus Pentacam Scheimpflug imager) was fairly normal, whereas wavefront analysis revealed considerable distortion, corresponding to the clinical appearance of the cornea [Fig. 1c and d].

At 3 months after the onset of haze, the patient underwent a manual superficial keratectomy, as he was reluctant to undergo

This is an open access journal, and articles are distributed under the terms of the Creative Commons Attribution-NonCommercial-ShareAlike 4.0 License, which allows others to remix, tweak, and build upon the work non-commercially, as long as appropriate credit is given and the new creations are licensed under the identical terms.

For reprints contact: reprints@medknow.com

Cite this article as: Efthymios K, Genovefa M, John A, Michael M. Very late onset corneal haze in a photorefractive keratectomy patient associated with presumed viral keratoconjunctivitis. *Indian J Ophthalmol* 2020;68:1186-8.

an additional laser treatment. Following appropriate consent, epithelium was removed manually avoiding the use of ethanol

solution to spare its proinflammatory properties and apoptotic effect on fibroblasts. Mechanical debridement was performed to the underlined stromal haziness until complete smoothness and clearness of the underlying stroma were achieved, followed by topical application of 0.02% mitomycin-C (MMC) for 1 min. At the end of the procedure, a bandage soft contact lens was placed, and apart from topical moxifloxacin, prednisone acetate 1% was applied on a tapering basis.

One month later, BCVA was 20/20 with -1.50 OD, and 20/25 with -1.25 -0.50 ×160 OS and visual disturbances disappeared. Slit-lamp examination showed only a minimal peripheral haze remaining [Fig. 2a and b]. An excellent outcome was remained 6 months postoperatively with an improvement in corneal wavefront values [Fig. 2c-e].

Discussion

A number of factors unrelated to surgery such as oral contraceptives, mechanical trauma, ultraviolet exposure, atopy, autoimmune conditions, and allergic conjunctivitis have been described as risk factors for haze after PRK.^[1] Viral conjunctivitis as a trigger for haze has been reported as a late onset complication, however one year post surgery.^[7] The appearance of haze a year after the infection represents a delayed hypersensitivity immune response to viral antigens deposited in the corneal stroma during infection,^[8] which causes activation of keratocytes in the anterior corneal stroma, upregulation of mediators such as chemokines, and as a result activation of fibroblasts.^[9,10]

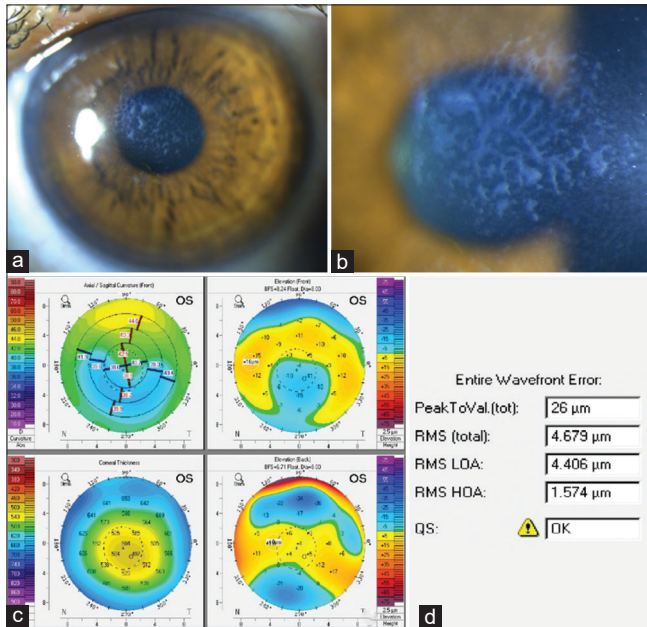


Figure 1: (a and b) Left eye stromal corneal haze and corneal epithelial hyperplasia overlying the papillary axis. (c) Fairly normal left eye corneal topography (Oculus Pentacam, Scheimpflug imager). (d) Left eye corneal wavefront analysis

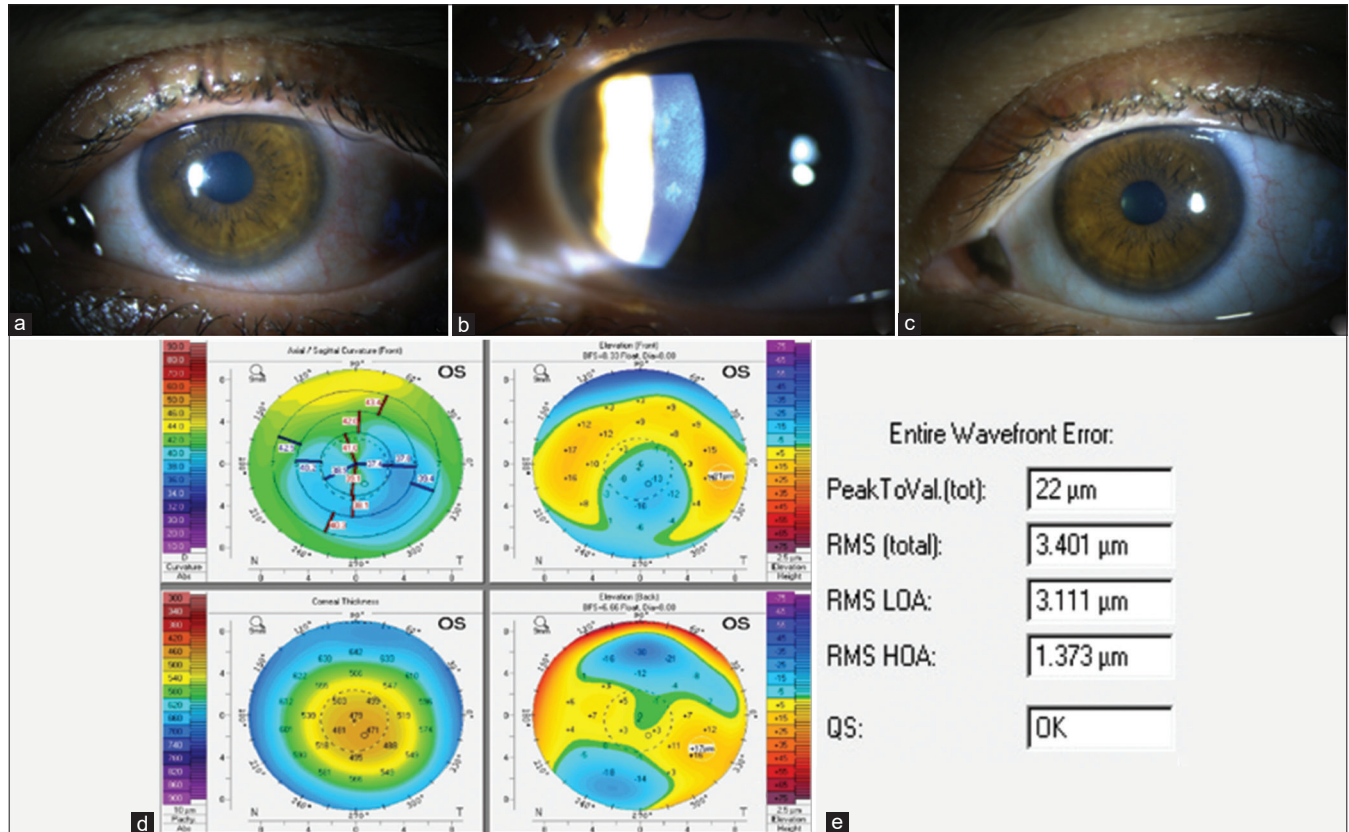


Figure 2: (a and b) One month following manual superficial keratectomy only a minimal peripheral haze remaining. (c) Excellent outcome 6 months postoperatively. (d) No significant changes in corneal topography. (e) Improvement in corneal wavefront analysis

To the best of our knowledge very late onset haze is an extremely rare complication and has never been reported as a result of viral keratoconjunctivitis. Our case indicates that myofibroblasts can be generated years after the original PRK surgery. Hyperactive keratocytes or loss of Bowman's layer may explain the unusual response to the inflammatory molecules released from tear film, leading to epithelial hyperplasia, myofibroblast generation, and abnormal stromal repair.

Conclusion

The case described here illustrates the potential risk for severe corneal haze even decades postoperatively triggered by a common eye infection. However, with prompt medical treatment, a successful visual outcome and restoring of vision can be achieved.

Declaration of patient consent

The authors certify that they have obtained all appropriate patient consent forms. In the form the patient(s) has/have given his/her/their consent for his/her/their images and other clinical information to be reported in the journal. The patients understand that their names and initials will not be published and due efforts will be made to conceal their identity, but anonymity cannot be guaranteed.

Financial support and sponsorship

Nil.

Conflicts of interest

There are no conflicts of interest.

References

1. Corbett MC, O'Brart DP, Warburton FG, Marshall J. Biologic and environmental risk factors for regression after photorefractive keratectomy. *Ophthalmology* 1996;103:1381-91.
2. Salomao MQ, Wilson SE. Corneal molecular and cellular biology update for the refractive surgeon. *J Refract Surg* 2009;25:459-66.
3. Netto MV, Mohan RR, Sinha S, Sharma A, Dupps W, Wilson SE. Stromal haze, myofibroblasts, and surface irregularity after PRK. *Exp Eye Res* 2006;82:788-97.
4. Lipshitz I, Loewenstein A, Varssano D, Lazar M. Late onset corneal haze after photorefractive keratectomy for moderate and high myopia. *Ophthalmology* 1997;104:369-73. discussion 373-4.
5. Jhanji V, Chan TCY, Li EYM, Agarwal K, Vajpayee RB. Adenoviral keratoconjunctivitis. *Surv Ophthalmol* 2015;60:435-43.
6. Hanna KD, Pouliquen YM, Waring GO 3rd, Savoldelli M, Fantes F, Thompson KP. Corneal wound healing in monkeys after repeated excimer laser photorefractive keratectomy. *Arch Ophthalmol* 1992;110:1286-91.
7. Pineda R, Talamo JH. Late onset of haze associated with viral keratoconjunctivitis following photorefractive keratectomy. *J Refract Surg* 1998;14:147-51.
8. Jones BR. The clinical features of viral keratitis and a concept of their pathogenesis. *Proc Royal Soc Med* 1958;51:13-20.
9. Chodosh J. Human adenovirus type 37 and the BALB/c mouse: Progress toward a restricted adenovirus keratitis model (an American Ophthalmological Society thesis). *Trans Am Ophthalmol Soc* 2006;104:346-65.
10. Xiao J, Chodosh J. JNK regulates MCP-1 expression in adenovirus type 19-infected human corneal fibroblasts. *Invest Ophthalmol Vis Sci* 2005;46:3777-82.