

Lymphoscintigraphy with single-photon emission computed tomography/computed tomography is useful for determining the site of chyle leakage after esophagectomy

Kohei Kotani, Joji Kawabe, Shigeaki Higashiyama, Susumu Shiomi

Department of Nuclear Medicine, Graduate School of Medicine, Osaka City University, Osaka, Japan

ABSTRACT

We describe the case of chylothorax after esophagectomy for esophageal carcinoma. Lymphoscintigraphy with Tc-99m-human serum albumin-diethylenetriaminepentaacetic acid showed an abnormal radioisotope accumulation on the left side of the thoracic duct. Single-photon emission computed tomography (SPECT) combined with computed tomography (CT) revealed a hot spot directly on the site at which the thoracic duct was ligated during surgery, which was the suggested site of chyle leakage. We emphasize that lymphoscintigraphy with SPECT/CT is very useful tool for accurately identifying the site of the chyle leakage.

Keywords: Chylothorax, esophagectomy, lymphoscintigraphy, single-photon emission computed tomography/computed tomography

INTRODUCTION

Single-photon emission computed tomography (SPECT) combined with computed tomography (CT) is the latest technique in, which a gamma camera and a CT are juxtaposed. Recently, different types of scintigraphies with SPECT/CT have been reported to be performed.^[1,2] Unlike conventional fusion technique of SPECT and CT, it enables us to obtain fusion images with little displacement of both images of SPECT and CT for accurate identification of lesions.^[2] We show lymphoscintigraphy with SPECT/CT imaging for chylothorax.

CASE REPORT

A 59-year-old woman was diagnosed with esophageal carcinoma of the lower intrathoracic esophagus and radical esophagectomy was performed. After surgery, more than 1 L of chylous fluid

was drained via a chest tube daily for more than a week. It was expected that the patient's nutritional condition would become worse if chyle, which contains lipids, proteins, electrolytes, lymphocytes, and various other elements, leaks continuously for a long period. Therefore, we performed lymphoscintigraphy with Tc-99m-human serum albumin-diethylenetriaminepentaacetic acid (HSA-D) to identify chyle leakage site. The imaging protocol for the lymphoscintigraphy was following that after 185 MBq of Tc-99m-HSA-D was subcutaneously injected between the first and second toes of each foot, we began temporal imaging from 0 to 60 min and SPECT/CT at the time when an abnormal accumulation of the radioisotope (RI) appeared. In this case, by 10 min after the injections, lymphatic fluid in each foot flows through the lymphatic vessel of the lower limb to the lumbar lymphatic trunk. At 10 min after the injections, planar imaging revealed cisterna chyli joined by right and left lumbar lymphatic trunks and the thoracic duct above. An abnormal accumulation of the RI was observed on the left side of the thoracic duct at 10 min and it appeared to be distributed over the left thoracic cavity as time passed, which suggested chyle leakage into the left thoracic cavity [Figure 1]. SPECT/CT was performed to identify the accurate site of chyle leakage into the left thoracic cavity at 30 min after the injections. SPECT/CT revealed a hot spot directly on the site at which the thoracic duct was ligated during surgery, which was the suggested site of chyle leakage [Figure 2]. Although we considered surgical treatment for chyle leakage,

Access this article online

Quick Response Code:



Website:
www.ijnm.in

DOI:
10.4103/0972-3919.112749

Address for correspondence:

Dr. Joji Kawabe, Department of Nuclear Medicine, Graduate School of Medicine, Osaka City University, 1-4-3 Asahimachi, Abenoku, Osaka 545-8585, Japan. E-mail: kawabe@med.osaka-cu.ac.jp

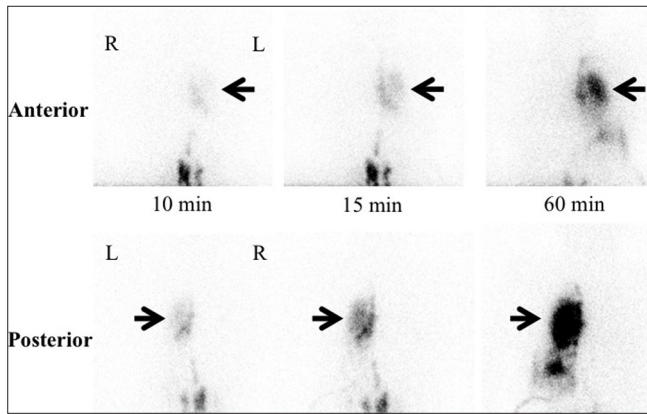


Figure 1: Planar imaging of lymphoscintigraphy with Tc-99m-human serum albumin-diethylenetriaminepentaacetic acid at 10, 15 and 60 min. The image at 10 min after the radioisotope (RI) injections revealed abnormal accumulation of the RI on the left side of the thoracic duct and the RI appeared to be distributed over the left thoracic cavity as time passed

it gradually decreased following conservative treatment with octreotide, a somatostatin analog,^[3] and did not increase again after restarting meals.

DISCUSSION

Chylothorax is a condition where chyle leaks into the thoracic cavity because of injury to the thoracic duct. The incidence of chylothorax after esophagectomy is approximately 2.0%.^[4] Mild chylothorax can be relieved by fasting, parenteral nutrition, or octreotide, a somatostatin analog,^[3] but surgery should be considered when conservative treatment fails to improve the patient's condition. The site of chyle leakage can be accurately needed if the thoracic duct is ligated or clipped.

Conventionally, chylothorax is diagnosed by CT, lymphangiography or lymphoscintigraphy. CT has limited use in localizing a site of chyle leakage although it is simpler than others. Lymphangiography enables direct visualization of lymphatic collection system, but this technique involves complex and invasive manipulation. Lymphoscintigraphy that can visualize lymph ducts up to the thoracic duct shortly after subcutaneous RI injection is a simple and non-invasive modality, and it have been used to detect a site of chyle leakage by planar and SPECT imaging only.^[5,6] The site of chyle leakage can be partially diagnosed by these techniques, but accurate determination of the chyle leakage sites is sometimes difficult. SPECT/CT, the latest technique in which a gamma camera and a CT are juxtaposed, enables us to obtain fusion images with little displacement of both images for accurate identification of lesions.^[2] Lymphoscintigraphy with SPECT/CT enabled accurate determination of the chyle leakage site in the thoracic cavity of our patient, which facilitated understanding of the local anatomical relationships. Lymphoscintigraphy cannot detect a point of chyle leakage in all cases, but lymphoscintigraphy

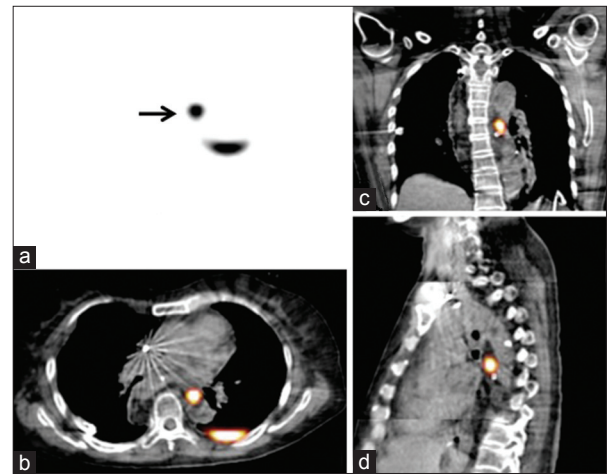


Figure 2: SPECT (a) axial slice, SPECT/CT (b) axial slice, (c) coronal slice and (d) sagittal slice. The SPECT/CT images revealed a hot spot at the level of the tracheal bifurcation, which showed that the hot spot was located at retromediastinum anterior to the descending thoracic aorta and directly above the ligated site of the thoracic duct in comparison with the surgical findings

with SPECT/CT technically has a potential role to illustrate a point of chyle leakage, and we should consider performing this SPECT/CT technique if conservative treatment for chylothorax fails to improve the patient's condition.

In conclusion, we experienced a case of chylothorax after esophagectomy for esophageal carcinoma. Planar imaging of lymphoscintigraphy showed an abnormal accumulation on the left side of the thoracic duct and SPECT/CT suggested the site of chyle leakage. Lymphoscintigraphy with SPECT/CT can be a useful diagnostic tool of chyle leakage.

REFERENCES

1. Lerman H, Metser U, Lievshitz G, Sperber F, Shneebaum S, Even-Sapir E. Lymphoscintigraphic sentinel node identification in patients with breast cancer: The role of SPECT-CT. *Eur J Nucl Med Mol Imaging* 2006;33:329-37.
2. Mariani G, Bruselli L, Kuwert T, Kim EE, Flotats A, Israel O, *et al.* A review on the clinical uses of SPECT/CT. *Eur J Nucl Med Mol Imaging* 2010;37:1959-85.
3. Al-Zubairy SA, Al-Jazairi AS. Octreotide as a therapeutic option for management of chylothorax. *Ann Pharmacother* 2003;37:679-82.
4. Bolger C, Walsh TN, Tanner WA, Keeling P, Hennessy TP. Chylothorax after oesophagectomy. *Br J Surg* 1991;78:587-8.
5. Inoue Y, Otake T, Nishikawa J, Sasaki Y. Lymphoscintigraphy using Tc-99m human serum albumin in chylothorax. *Clin Nucl Med* 1997;22:60.
6. Ogi S, Fukumitsu N, Uchiyama M, Mori Y. A case of chylothorax diagnosed by lymphoscintigraphy using Tc-99m HSA-DTPA. *Clin Nucl Med* 2002;27:455-6.

How to cite this article: Kotani K, Kawabe J, Higashiyama S, Shiomi S. Lymphoscintigraphy with single-photon emission computed tomography/computed tomography is useful for determining the site of chyle leakage after esophagectomy. *Indian J Nucl Med* 2012;27:208-9.

Source of Support: Nil. **Conflict of Interest:** None declared.