

## CASE REPORT

### Protein S deficiency present in a pregnant woman with dyspnea, abdominal pains, restlessness, agitation and hypofibrinogenemia

Takeshi Umazume, Mamoru Morikawa, Takahiro Yamada, Rina Akaishi, Takahiro Koyama & Hisanori Minakami

Department of Obstetrics, Hokkaido University Graduate School of Medicine, Sapporo 060-8638, Japan

#### Correspondence

Takahiro Yamada, Department of Obstetrics, Hokkaido University Graduate School of Medicine, N15W7, Kita-ku, Sapporo 060-8638, Japan. Tel: +81 11 706 5941; Fax: +81 11 706 7711; E-mail: taka0197@med.hokudai.ac.jp

#### Funding Information

This study was supported by a Grant-in-Aid for Scientific Research from the Ministry of Education, Science, Sports, and Culture of Japan (No. 2646246804).

Received: 8 October 2014; Revised: 4 November 2014; Accepted: 7 December 2014

*Clinical Case Reports* 2015; 3(4): 213–216

doi: 10.1002/ccr3.200

## Introduction

Blood fibrinogen level increases during pregnancy from a nonpregnant level of  $2.5 \pm 0.7$  g/L to  $4.5 \pm 0.9$  g/L at gestational week (GW) 30–33 [1], partly explaining the hypercoagulable state of pregnancy. As fibrinogen is a soluble precursor of fibrin and D-dimer is a specific degradation product of cross-linked fibrin monomers, a decrease in fibrinogen level can occur in clinical situations with acute and aggressive increases in the D-dimer level [2]. With increasing pulmonary occlusion rate, fibrinogen level decreases and D-dimer level increases in pulmonary thromboembolism (PTE) [2]. However, hypofibrinogenemia defined as  $<0.5$  g/L is seldom seen in patients with PTE [2, 3].

Although amniotic fluid embolism (AFE) is a leading cause of maternal mortality in developed countries, occurring in approximately 1 in 20,000–30,000 pregnancies, its pathogenesis remains unclear [4, 5]. Some blood parameters, such as elevated levels of STN and IL-8, were

#### Key Clinical Message

Hypofibrinogenemia is rare in pulmonary thromboembolism. A pregnant woman with dyspnea, abdominal pain, restlessness, agitation and protein S deficiency exhibited normal blood oxygenation and high D-dimer (370  $\mu$ g/mL) and undetectable fibrinogen levels in the blood. The pathogenesis responsible for present findings may have some features similar to amniotic fluid embolism.

#### Keywords

Amniotic fluid embolism, coagulopathy, maternal complication, protein S deficiency, pulmonary thromboembolism, twin pregnancy.

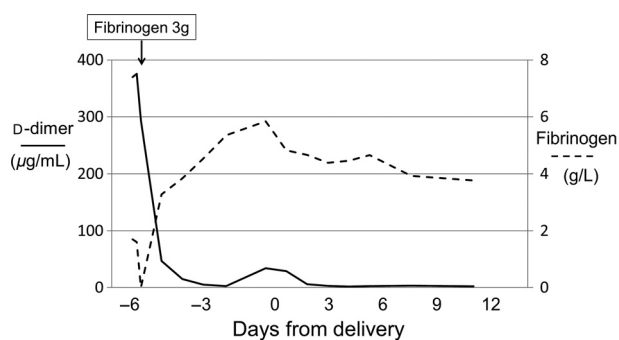
suggested to be associated with the occurrence of AFE [6, 7]. However, as no reliable blood parameters are available for diagnosis, AFE is almost a diagnosis of exclusion and is clinically based on one or more of four key signs/symptoms: cardiovascular collapse, respiratory distress, coagulopathy, and/or coma/seizures [5].

Here, we report a pregnant woman in whom a marked D-dimer increase concomitant with a very acute decrease in fibrinogen to an undetectable level occurred. This presentation was conducted after receiving approval by the patient and the Ethics Committee of Hokkaido University Hospital.

## Case Description

A 35-year-old Japanese woman with monochorionic diamniotic twin pregnancy and pre-pregnancy body mass index of  $19.6$  kg/m<sup>2</sup> presented with stabbing pain in the lower abdomen at gestational week (GW) 30<sup>-5/7</sup>. Her medical history was unremarkable except for asthma with

prior birth of a healthy girl 5 years ago. She was unstable and apparently ill with difficulty in breathing, agitation, and restlessness despite body temperature of 36.8°C, blood pressure of 119/69 mmHg, pulse rate of 105 bpm, no proteinuria on dipstick test, and unremarkable test results on SPO<sub>2</sub> monitoring (99%), ultrasound/Doppler study in the abdomen and lower extremities, echocardiography. Although these studies suggested increased uterine activity, but not placental abruption, cardiac stroke, deep vein thrombosis (DVT), pulmonary thromboembolism (PTE), or AFE, marked elevation of D-dimer (370 and 376 µg/mL again on reexamination) concomitant with reduced fibrinogen level (1.7 and 1.6 g/L again on reexamination) (Fig. 1) in the presence of normal liver function (AST/ALT, 20 and 12 IU/L, respectively) prompted us to initiate intravenous continuous administration of unfractionated heparin at a rate of 833 units/h and



**Figure 1.** Changes in blood levels of fibrinogen and D-dimer. The reduced blood fibrinogen level of 170 mg/dL on admission decreased to an undetectable level (<50 mg/dL) within 4 h after admission to our hospital. However, administration of 3000 mg of fibrinogen (FibrinogenHT-BENESIS<sup>®</sup>, TanabeMitsubishi Pharmaceutical Co. Ltd., Osaka, Japan) unexpectedly resulted in a high fibrinogen level (274 mg/dL) determined 1 h after administration, suggesting that hyperproduction of fibrinogen was occurring in the liver of this critically ill patient.

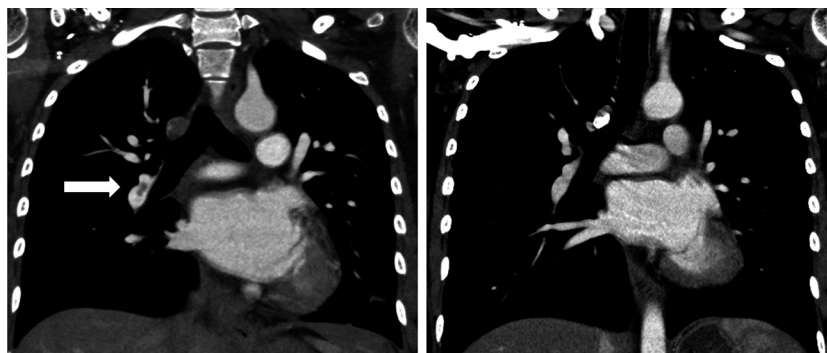
intravenous ritodrine hydrochloride for suppression of uterine activity; subsequent tests indicated undetectable fibrinogen level (<0.5 g/L) 3 h later in this patient. She received 3.0 g of fibrinogen, resulting in an unexpected rise in fibrinogen level to 2.7 g/L. She became stable with regard to subjective symptoms, such as dyspnea, abdominal pain, restlessness, and agitation, within 12 h, exhibited no bleeding diathesis, and showed an uneventful course thereafter. However, she experienced premature rupture of the fetal membranes 6 days later at GW 31<sup>-4/7</sup> and underwent cesarean section, giving birth to two healthy boys weighing 1396 and 1334 g (Apgar scores of 8 and 9 at 1 and 5 min, respectively, for both infants). Computed tomography (CT) was performed after delivery to avoid fetal exposure to radiation, although she was entirely asymptomatic. Right PTE detected on CT on postpartum day (PPD) 1 had disappeared on repeat CT on PPD 10 (Fig. 2).

The patient was given warfarin and left hospital on PPD 17. The patient was screened for thrombophilia (Table 1). Protein S activity was consistently low even after delivery, and congenital protein S deficiency was diagnosed in this patient.

## Discussion

We speculated that an extraordinary acute and massive thrombus formation associated with protein S deficiency occurred in the deep veins of this patient in a short time based on marked elevation of D-dimer to 376 µg/mL concomitant with depletion of fibrinogen to an undetectable level (<0.5 g/L).

Although the D-dimer level is significantly higher in pregnant than nonpregnant women [8, 9] and in women with twin than singleton pregnancies [10], its rarely exceeds 10 µg/mL at this stage (GW 31) of pregnancy [9, 10], at which time fibrinogen level is around 4.5 g/L in otherwise healthy pregnant women [1]. According to



**Figure 2.** Lung CT images on postpartum day 1 (left) and 10 (right). An arrow indicates thrombus in a lower lobe branch of the right pulmonary artery. The thrombus was not detected with CT on postpartum day 10.

**Table 1.** Results of laboratory work-up for thrombophilia and coagulopathy.

Platelet count ( $\times 10^9/L$ )	126 [–6], 149 [–3], 189 [0], 236 [3], 349 [7]
APTT (sec)	32 [–6], 34 <sup>1</sup> [–5], 37 <sup>1</sup> [–3], 31 [0], 59 <sup>1</sup> [2], 57 <sup>1</sup> [7]
PT-INR	1.2 [–6], 1.2 <sup>1</sup> [–5], 1.1 <sup>1</sup> [–3], 1.1 [0], 1.2 <sup>1</sup> [2], 1.1 <sup>1</sup> [7]
Antithrombin activity (%)	80 [–6], 61 [0], 77 [5]
Protein C (%)	93 [–4]
Free protein S antigen (% <sup>2</sup> )	38 [–4], 67 [3]
Protein S activity (%)	<10 [–4], 34 [3], 28 [29], 38 [78]
Lupus anticoagulant	Negative [–4]
Anticardiolipin antibodies (U/mL)	Negative [–4]
Antinuclear antibodies	$\times 160$ [–4]

Days from delivery are indicated in square brackets. APTT, activated partial thromboplastin time; PT-INR, prothrombin time-international normalized ratio.

<sup>1</sup>Data on heparin.

<sup>2</sup>% of normal antigen concentration level.

Kucher *et al.* [2], such profound hypofibrinogenemia <0.5 g/L may not occur in PTE cases unless more than 80% pulmonary occlusion occurs. The D-dimer level did not exceed 30  $\mu\text{g/mL}$  even in pregnant patients with DVT/PTE [9]. DVT, PTE, or abnormalities in cardiac function were not detected on ultrasound or Doppler studies in our patient, while she was unstable and showed dyspnea despite sufficient oxygenation as determined by SPO<sub>2</sub> monitoring.

Placental abruption is a common complication (occurring in approximately 1 in 100 women [11]) in which abdominal pain and fibrinogen depletion are likely to occur [12] and the fetal condition monitored by fetal heart rate pattern progressively worsens. However, fetal well-being was maintained throughout the clinical course in this patient.

As pathogenesis of AFE remains unclear, AFE is ill defined and diagnosed based on clinical symptoms [4, 5]. Patients with AFE exhibit one or more of the following four clinical symptoms: cardiovascular collapse, respiratory distress, coagulopathy, and/or coma/seizures [4, 13]. However, premonitory neurological symptoms, including restlessness, agitation, numbness, and tingling, are seen in 30–65% of AFE cases [13], as in the present case. With regard to coagulopathy and the diagnosis of AFE, fibrinogen level was <2.0 g/L in 32 (94%), <1.0 g/dL in 17 (50%), and undetectable in 8 (24%) of 34 AFE patients

with laboratory assessment of coagulopathy [14]. In addition, coagulopathy alone was described as the sole clinical sign/symptom of AFE in at least five AFE cases [15–19]. Our patient had laboratory coagulopathy and would have developed bleeding diathesis unless fibrinogen was replaced in a timely manner because there is a strong association between fibrinogen activity level and clinical severity of bleeding [20].

The fibrinogen level was undetectable (<0.5 g/L) in this patient before replacement of fibrinogen. As the estimated circulating blood volume was 5000 mL in this patient, the exogenous 3.0 g of fibrinogen would have contributed to a net increase in fibrinogen level by 0.50 g/L. However, the patient showed a fibrinogen level of  $\geq 2.7$  g/L after a single replacement of fibrinogen. This suggested the occurrence of hyperproduction of fibrinogen to respond to acute and massive consumption of fibrinogen in this critically ill patient.

Transient shortness of breath, palpitations, and laboratory evidence for coagulopathy were documented in a patient with possible “mild” AFE [21], as seen in our patient. Although our patient was finally diagnosed as having PTE with CT on PPD 1 in the absence of decreased oxygenation in the blood, the clinical course was very unusual for PTE. The pathogenesis leading to the present symptoms and findings may have some features similar to AFE. However, a route of amniotic fluid entrance to the general circulation was unclear if AFE was assumed to have occurred in this patient.

## Disclosure

All authors declare that they have no financial relationships with biotechnology manufacturers, pharmaceutical companies, or other commercial entities with an interest in the subject matter or materials discussed in this manuscript.

## Acknowledgements

This study was supported by a Grant-in-Aid for Scientific Research from the Ministry of Education, Science, Sports, and Culture of Japan (No. 2646246804).

## Conflict of Interest

None declared.

## References

- Hui, C., M. Lili, C. Libin, Z. Rui, G. Fang, G. Ling, *et al.* 2012. Changes in coagulation and hemodynamics during pregnancy: a prospective longitudinal study of 58 cases. *Arch. Gynecol. Obstet.* 285:1231–1236.

2. Kucher, N., H. P. Kohler, T. Dornhofer, D. Wallmann, and B. Lammle. 2002. Accuracy of D-dimer/fibrinogen ratio to predict pulmonary embolism: a prospective diagnostic study. *J. Thromb. Haemost.* 1:708–713.
3. Hajsadeghi, S., S. R. Kerman, M. Khojandi, H. Vaferi, R. Ramezani, N. M. Jourshari, et al. 2012. Accuracy of D-dimer:fibrinogen ratio to diagnose pulmonary thromboembolism in patients admitted to intensive care units. *Cardiovasc. J. Afr.* 23:446–456.
4. Roberts, C. L., C. S. Algert, M. Knight, and J. M. Morris. 2010. Amniotic fluid embolism in an Australian population-based cohort. *BJOG* 117:1417–1421.
5. Benson, M. D. 2012. Current concepts of immunology and diagnosis of amniotic fluid embolism. *Clin. Dev. Immunol.* 2012:7, Article ID 946576.
6. Kobayashi, H., H. Ohi, and T. Terao. 1993. A simple, non-invasive, sensitive method for diagnosis of amniotic fluid embolism by monoclonal antibody TKH-2 that recognizes NeuAc 2alfa- 6GalNac. *Am. J. Obstet. Gynecol.* 168:848–853.
7. Oi, H., K. Naruse, N. Koike, T. Tsunemi, H. Shigetomi, N. Kanayama, et al. 2014. Predictor of mortality in patients with amniotic fluid embolism. *J. Obstet. Gynaecol. Res.* 40:941–945.
8. Chan, W. S., A. Lee, F. A. Spencer, S. Chunilal, M. Crowther, W. Wu, et al. 2010. D-dimer testing in pregnant patients: toward determining the next level in the diagnosis of deep vein thrombosis. *J. Thomb. Haemost.* 8:1004–1011.
9. Kawaguchi, S., T. Yamada, M. Takeda, R. Nishida, T. Yamada, M. Morikawa, et al. 2013. Changes in D-dimer levels in pregnant women according to gestational week. *Pregnancy Hypertens.* 3:172–177.
10. Yamada, T., S. Kawaguchi, N. Araki, M. Takeda, R. Nishida, T. Yamada, et al. 2013. Difference in the D-dimer rise between women with singleton and multifetal pregnancies. *Thromb. Res.* 131:493–496.
11. Morikawa, M., T. Takahiro Yamada, K. Cho, T. Yamada, S. Sato, and H. Minakami. 2014. Prospective risk of abruptio placentae. *J. Obstet. Gynaecol. Res.* 40:369–374.
12. Nelson, D. B., N. P. Yost, and F. G. Cunningham. 2014. Hemostatic dysfunction with acute fatty liver of pregnancy. *Obstet. Gynecol.* 124:40–46.
13. Tuffnell, D., M. Knight, and F. Plaat. 2011. Amniotic fluid embolism – an update. *Anaesthesia* 66:3–6.
14. Clark, S. L., G. D. V. Hankins, D. A. Dudley, G. A. Dildy, and T. F. Porter. 1995. Amniotic fluid embolism: analysis of the national registry. *Am. J. Obstet. Gynecol.* 172:1158–1169.
15. Yang, J. I., H. S. Kim, K. H. Chang, H. S. Ryu, and H. J. Joo. 2006. Amniotic fluid embolism with isolated coagulopathy: a case report. *J. Reprod. Med.* 51:64–66.
16. Laforga, J. B. 1997. Amniotic fluid embolism. Report of two cases with coagulation disorder. *Acta Obstet. Gynecol. Scand.* 76:805–806.
17. Davies, S. 1999. Amniotic fluid embolism and isolated disseminated intravascular coagulation. *Can. J. Anaesth.* 46 (5 Pt 1):456–459.
18. Awad, I. T., and G. D. Shorten. 2001. Amniotic fluid embolism and isolated coagulopathy: atypical presentation of amniotic fluid embolism. *Eur. J. Anaesthesiol.* 18:410–413.
19. Bastien, J. L., J. R. Graves, and S. Balley. 1998. Atypical presentation of amniotic fluid embolism. *Anesth. Analg.* 87:124–126.
20. Peyvandi, F. 2012. Epidemiology and treatment of congenital fibrinogen deficiency. *Thromb. Res.* 130:S7–S11.
21. Benson, M. D., and H. Oi. 2007. A mild case of amniotic fluid embolism? *J. Matern. Fetal Neonatal Med.* 20:261–262.