

Early Results of Coronary Endarterectomy Combined with Coronary Artery Bypass Grafting in Patients with Diffused Coronary Artery Disease

Li-Qun Chi, Jian-Qun Zhang, Qing-Yu Kong, Wei Xiao, Lin Liang, Xin-Liang Chen

Department of Cardiac Surgery, Beijing Anzhen Hospital, Capital Medical University, Beijing 100029, China

Abstract

Background: It is still a challenge for the cardiac surgeons to achieve adequate revascularization for diffused coronary artery disease (CAD). Coronary endarterectomy (CE) offers an alternative choice of coronary artery reconstruction and revascularization. In this study, short-term result of CE combined with coronary artery bypass graft (CABG) was discussed in the treatment for the diffused CAD.

Methods: From January 2012 to April 2014, 221 cases of CABG were performed by the same surgeon in our unit. Among these cases, 38 cases of CE + CABG were performed, which was about 17.2% (38/221) of the cohort. All these patients were divided into two groups: CE + CABG group (Group A) and CABG alone group (Group B). All clinical data were compared between the two groups, and postoperative complications and in-hospital mortality were analyzed. The categorical and continuous variables were analyzed by Chi-square test and Student's *t*-test respectively.

Results: Diabetes mellitus, hypertension, hyperlipidemia, and peripheral vascular disease were more common in group A. In this cohort, a total of 50 vessels were endarterectomized. Among them, CE was performed on left anterior descending artery in 11 cases, on right coronary artery in 29 cases, on diagonal artery in 3 cases, on intermediate artery in 2 cases, on obtuse marginal artery in 5 cases. There was no hospital mortality in both groups. The intro-aortic balloon pump was required in 3 cases in Group A (3/38), which was more often than that in Group B (3/183). At the time of follow-up, coronary computed tomography angiogram showed all the grafts with CE were patent (50/50). There is no cardio-related mortality in both groups. All these patients were free from coronary re-intervention.

Conclusions: Coronary endarterectomy + CABG can offer satisfactory result for patients with diffused CAD in a short-term after the operation.

Key words: Coronary Artery Bypass Grafting; Coronary Endarterectomy; Diffused Coronary Artery Disease

INTRODUCTION

A number of significant improvements have been made in the diagnosis and treatment of coronary artery disease (CAD) in China. The recent decades have witnessed a dramatic rise in the number of the percutaneous coronary intervention (PCI) and coronary artery bypass graft (CABG) surgeries. Because of the improvements in PCI, patients with complex and diffused CAD are increasingly being referred for surgical revascularization. For these patients, it is difficult to achieve adequate revascularization via CABG surgery alone, and coronary endarterectomy (CE) offers an alternative choice of coronary artery reconstruction and revascularization. In this study, we reviewed the clinical data of 38 patients who underwent CE + CABG and compared them with those of patients who underwent CABG surgery alone over the

same period by a single surgeon to explore the approach, methodology, and efficacy of CE + CABG.

METHODS

Clinical data

Data of 221 patients who underwent CABG from January 2012 to April 2014 under the same surgeon were retrospectively reviewed. Of these, 38 (17.2%) underwent CE + CABG (Group A), and the remaining patients underwent CABG alone (Group B). The clinical data of the patients are shown in Table 1. Diabetes, hypertension, hyperlipidemia, and peripheral vascular disease were more common in Group A than in Group B.

Surgical procedure

A routine median sternotomy was performed on patients from Group A. Of the 38 patients, 35 underwent off-pump CABG surgery while 3 underwent on-pump CABG surgery. The

Access this article online

Quick Response Code:



Website:
www.cmj.org

DOI:
10.4103/0366-6999.157652

Address for correspondence: Dr. Li-Qun Chi,
Department of Cardiac Surgery, Beijing Anzhen Hospital,
Capital Medical University, Beijing 100029, China
E-Mail: chiliquan2002@sohu.com

Table 1: Preoperative and intraoperative characteristics of patients with diffused CAD in the two groups

Characteristics	Group A (n = 38)	Group B (n = 183)	P
Age (years, mean ± SD)	65.4 ± 12.1	69.6 ± 5.2	0.215
Gender (male:female)	23:15	115:68	0.933
Diabetes mellitus (n (%))	26 (68.4)	69 (37.7)	<0.01
Hypertension (n (%))	38 (100)	157 (85.8)	0.028
Hyperlipidemia (n (%))	33 (86.8)	106 (57.9)	<0.001
Peripheral vascular disease (n (%))	35 (92.1)	74 (40.4)	<0.001
Ejection fraction (%)	47 ± 11	49 ± 12	0.340
Failed PCI (n (%))	11 (28.9)	41 (22.4)	0.387
Emergency (n (%))	1 (2.6)	5 (2.7)	1.000
Number of grafts	3.2 ± 1.1	3.5 ± 0.8	0.510
Usage of LIMA (n (%))	37 (97.4)	176 (96.2)	1.000
Off-pump CABG (n (%))	35 (92.1)	172 (94.0)	0.950

SD: Standard deviation; PCI: Percutaneous coronary intervention; LIMA: Left internal mammary artery; CABG: Coronary artery bypass graft; CAD: Coronary artery disease.

decision to perform CE was mainly based on the results of preoperative coronary angiography and intraoperative findings of the target coronary artery. Diffuse lesions with severe calcifications and totally or subtotally occluded distal segment of the target vessels were observed in all 38 patients [Figure 1]. The coronary artery was longitudinally incised 10–15 mm, and the sclerotic intima was stripped with fine forceps. The calcified intima was clamped using a mosquito clamp and gently pulled out, in line with the rhythm of the heartbeats from the distal end of the coronary artery. Meanwhile, the coronary artery adventitia was pushed by the forceps in the opposite direction until all the thickened calcified intima cords were removed [Figure 2-4]. Further, the intima was stripped in the same manner as described above from the proximal end of the coronary artery. Some bleeding was observed at the distal and proximal ends of the incision after CE. After washing any residual intima fragments, the CABG surgery was performed by anastomosing the left internal mammary artery graft or vein graft on the endarterectomized artery directly. Before neutralization of heparin by protamine, the Medistim VeriQ system was routinely used to assess the blood flow of the bypass graft [Figure 5]. Of the 183 patients in Group B, 9 underwent off-pump CABG surgery from the minimally invasive left 4th intercostal incision, whereas the remaining 174 underwent routine median sternotomy. Of these, 163 underwent off-pump CABG surgery while 11 underwent on-pump CABG surgery.

Postoperatively, all patients were maintained on dual antiplatelet therapy with 75 mg clopidogrel and 100 mg aspirin daily for at least 1-year, and were later moved to single antiplatelet therapy with 100 mg aspirin daily.

Follow-up was obtained at regular intervals in the outpatient clinic 3–6 months post the operation. Data collected at that time included echocardiography, electrocardiogram, chest X-ray, and blood laboratory test. Coronary computed tomography (CT) angiogram [Figure 6] was performed for

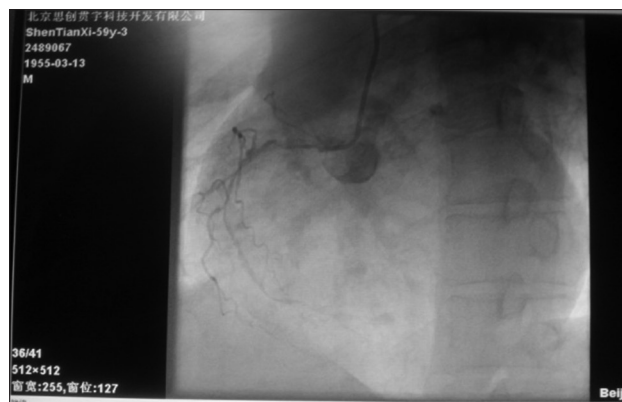


Figure 1: Preoperative angiograms showing diffuse disease of the right coronary artery.

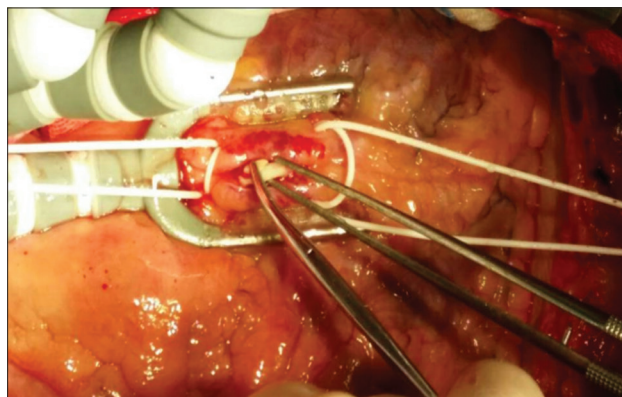


Figure 2: Coronary endarterectomy was performed in the beating heart before off-pump coronary artery bypass graft.

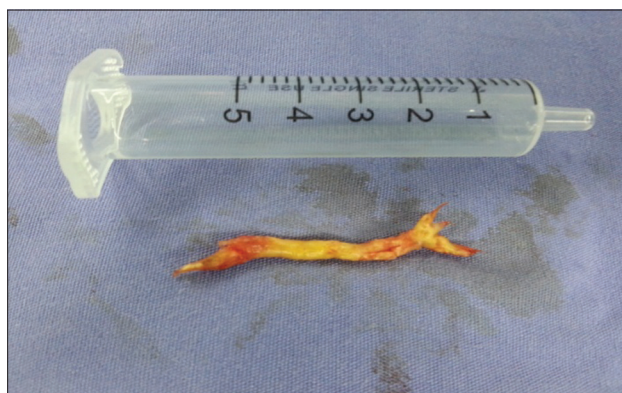

Figure 3: A piece of intima contracted from the right coronary artery, 3 branches can be found at the end of the calcified intima.

all patients in Group A and 59 selected voluntary patients on a voluntary basis from Group B (32.2%). The latest follow-up was obtained by telephone interview. Data collected at follow-up included current symptom, hospital readmission, and re-do PCI. Follow-up was 100% completed, and the mean follow-up time is 14.3 months, ranged from 3 to 30 months.

Statistical analysis

Data were analyzed using the SPSS software version 11.0 (SPSS Inc., Chicago, IL, USA). Results of the continuous

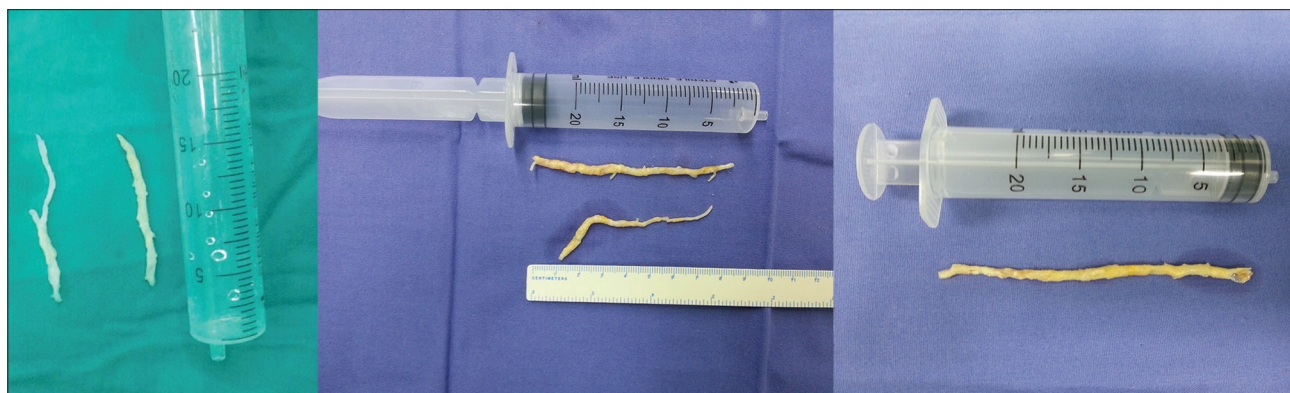

Figure 4: Several cases of endarterectomy specimen, the longest one was about 10 cm, all these specimen can be found with a nearly normal intima at the distal end of the atheromatous plaque.

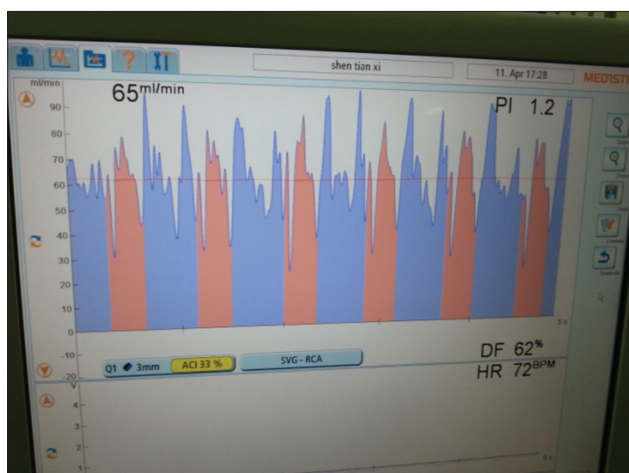


Figure 5: Blood flow of the bypass graft was detected with Medistim VeriQ.

variables were expressed as mean \pm standard derivation (SD), whereas those of the categorical variables were expressed by the frequencies. The categorical and continuous variables were analyzed by Chi-square test and Student's *t*-test, respectively. $P < 0.05$ was considered statistically significant.

RESULTS

In Group A ($n = 38$), endarterectomy was performed in 50 vessels, with 3 vessels in 1 patient, 2 vessels in 10 patients, and 1 vessel in 27 patients. CE was performed on the left anterior descending artery in 11 of these cases, on the right coronary artery (RCA) in 29 cases, on the diagonal artery in 3 cases, and on the intermediate artery in 2 cases. No hospital mortality was observed in any of the groups, and there was no significant difference between Group A and Group B in terms of the postoperative blood drainage, atrial fibrillation rate, Intensive Care Unit stay time, and postoperative stay time. The intro-aortic balloon pump was required in 3 cases in Group A (3/38; 7.89%), which was more often than that in Group B (3/183; 1.64%), as shown in Table 2.

At the time of follow-up, coronary CT angiography of Group A patients showed that all the grafts with CE were

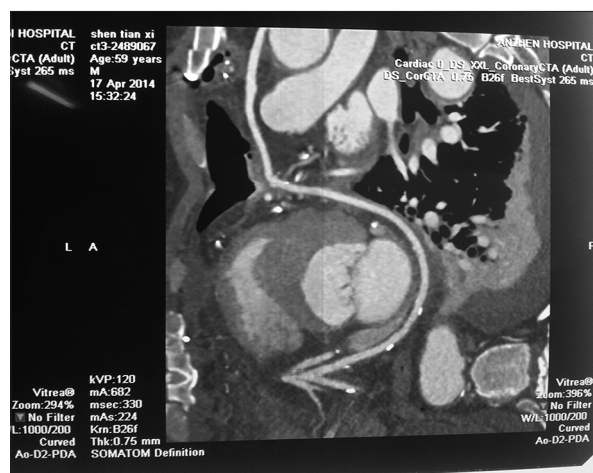

Figure 6: Postoperative computed tomography angiogram showing a patent vein graft anastomosed to the right coronary artery, the three branches are well revealed.

patent (50/50) while 1 vein graft without CE was occluded. Coronary CT angiography of Group B patients showed that 2 vein grafts were occluded. One patient from Group B died from lung cancer 19 months postoperation. No cardiac-related mortality was observed in any of the groups. All patients were free from coronary re-intervention.

DISCUSSION

Considerable progress has been made in the diagnosis and treatment of CAD since the first successful completion of CE by Bailey *et al.* in the late 1950s.^[1] Since CE is associated with a high risk of death and other complications, many surgeons do not recommend it.^[2,3] However, given the significant improvements in PCI, patients with more complicated diffuse lesions are being referred for CABG surgery. However, the short-term and long-term effects of CABG surgery alone for these patients are not favorable, because it is difficult to establish a thorough revascularized bypass since the blood flow of the barely established graft is low and highly resistant because of the severe target vascular sclerosis and calcification, especially in those with total

Table 2: Postoperative outcomes of patients with diffused CAD in the two groups

Outcomes	Group A (n = 38)	Group B (n = 183)	P
In-hospital mortality (n)	0	0	-
Blood drainage in 24 h (ml)	520 ± 230	510 ± 260	0.750
Atrial fibrillation rate (n (%))	5 (13.1)	23 (12.6)	1.000
ICU stay (days)	1.6 ± 0.5	1.5 ± 0.3	0.100
Postoperative stay (days)	7.4 ± 2.2	6.8 ± 2.3	0.140
Usage of IABP (n (%))	3 (7.9)	3 (1.6)	0.031
Postoperative cTnI > 10 ng/ml (n (%))	4 (10.5)	16 (8.7)	0.970

ICU: Intensive care unit; cTnI: Cardiac troponin I; IABP: Intra-aortic balloon pump; CAD: Coronary artery disease.

or subtotal long-segment occlusions. To ensure adequate revascularization in such patients, surgeons are increasingly recommending the CE + CABG surgery.^[4-9]

There are two main approaches to CE: closed endarterectomy and open endarterectomy.^[2,5-7,10-12] In this study, closed endarterectomy was performed since it requires a shorter operation time than an open endarterectomy. The hyperplastic intima mainly consists of a firm and hard internal elastic membrane,^[13] which facilitates intimal denudation. Typically, most of the hyperplastic and thickened intimal tissues can be fully stripped. The main purpose of endarterectomy is to extract the complete intima distal to the incision and ensure adequate revascularization. For endarterectomy proximal to the incision, thorough extraction of the intima is not necessary. Distal intimal extraction is considered adequate if obvious bleeding of the distal vascular segment and a patent vessel with a normal distal intima (with thin and soft tissues) on the top is observed after endarterectomy. In our experience, an adequate distally intimal extraction is necessary in CE surgery. The incisions in patients with inadequate endarterectomy because of fractured intima should be extended to enable thorough extraction of the distal calcified intima. In certain patients, another distal incision may be required to facilitate endarterectomy; in such cases, one of the two incisions should be repaired by the vein patch, and the other should be used for CABG.

During endarterectomy for vessels with large branches in the distal segment, the intimal cord can break at the bifurcations, resulting in poor revascularization of the distal segment. Therefore, the incision should be made as close to the large branches as possible (particularly in closed endarterectomy for the RCA, the incision should be made near the bifurcation of the posterior descending artery and the posterior branch of the left ventricle, where the most severe calcification and stenosis often lies), and intimal extraction should be performed along the passages of the branches, which leads to excellent surgery outcomes.

If possible, the blood flow and resistance should be measured to ensure satisfactory blood flow of the bypass graft. In this study, one patient from Group B experienced inadequate blood flow after the operation; therefore, another incision was made at the distal bifurcation. After endarterectomy, the

incision was repaired with a saphenous vein patch. Repeat measurements indicated that blood flow inside the graft was satisfactory, and the patient successfully recovered postoperatively. A stricter surgical hemostasis is required in CE + CABG surgery, and earlier use of heparin, aspirin, and Plavix (clopidogrel) postoperatively is also recommended to prevent the early triggering of the coagulation cascade reported in CE.^[14] Further, more aggressive statin therapy may improve the long-term patency of the vessels.

Due to the right method of CE + CABG, measurement of blood flow of the bypass graft, and the earlier use of anticoagulant, fully revascularization could be assured for patient with diffused CAD. A fully revascularization is the assurance to avoid peri-operative myocardial infarction. In this study, there was no operative mortality in CE + CABG group, and at the same time, no difference was found in cardiac troponin I level between CE + CABG group and routine CABG group, we can conclude that CE + CABG can offer satisfactory result for patients with diffused CAD in short-term after the operation.

This study still has some limitations. Although it has been reported that CE + CABG has good long-term prospects,^[5-7,15,16] the analyzed clinical data only dates back to 2 years before in this study. Therefore, a further long-term follow-up is required to confirm our results. Meanwhile, we have only reviewed the operations performed by the same surgeon, which may have minimized the variation or bias during patient selection. However, the small sample size is a major limitation. Further studies with longer follow-ups in a larger sample of patients with more extensive research in terms of the surgical approach, methodology, and efficacy of CE + CABG are warranted.

REFERENCES

1. Bailey CP, May A, Lemmon WM. Survival after coronary endarterectomy in man. *J Am Med Assoc* 1957;164:641-6.
2. Tiruvoipati R, Loubani M, Lencioni M, Ghosh S, Jones PW, Patel RL. Coronary endarterectomy: Impact on morbidity and mortality when combined with coronary artery bypass surgery. *Ann Thorac Surg* 2005;79:1999-2003.
3. Ferraris VA, Harrah JD, Moritz DM, Striz M, Striz D, Ferraris SP. Long-term angiographic results of coronary endarterectomy. *Ann Thorac Surg* 2000;69:1737-43.
4. Binsalamah ZM, Al-Sarraf N, Chaturvedi RK, Alam A, Thalib L, Belley G, *et al.* Mid-term outcome and angiographic follow-up of endarterectomy of the left anterior descending artery in patients undergoing coronary artery bypass surgery. *J Card Surg* 2014;29:1-7.
5. Takahashi M, Gohil S, Tong B, Lento P, Filsoufi F, Reddy RC. Early and mid-term results of off-pump endarterectomy of the left anterior descending artery. *Interact Cardiovasc Thorac Surg* 2013;16:301-5.
6. Ariyaratnam P, Javangula K, Papaspyros S, McCrum-Gardner E, Nair RU. Long-term survival from 801 adjunctive coronary endarterectomies in diffuse coronary artery disease. *Eur J Cardiothorac Surg* 2012;42:e140-5.
7. Khalifa AA, Cornily JC, David CH, Choplain JN, Le Gal G, Barra JA, *et al.* Medium-term survival of diffuse coronary artery disease patients following coronary artery reconstruction with the internal thoracic artery. *Cardiology* 2011;120:192-9.
8. LaPar DJ, Anvari F, Irvine JN Jr, Kern JA, Swenson BR, Kron IL, *et al.* The impact of coronary artery endarterectomy on outcomes during coronary artery bypass grafting. *J Card Surg* 2011;26:247-53.

9. Schmitto JD, Kolat P, Ortmann P, Popov AF, Coskun KO, Sohns C, *et al.* CABG surgery with long coronary endarterectomy of the LAD. *Ann Thorac Cardiovasc Surg* 2010;16:445-7.
10. Giordano V, Grandjean JG. There is always hope after PCI and stenting. *J Cardiovasc Med (Hagerstown)* 2012;13:766-8.
11. Osswald B, Tochtermann U, Badowski-Zyla D, Thomas G, Hagl S. Coronary reconstructive surgery versus coronary artery bypass grafting – A documentation gap. *Thorac Cardiovasc Surg* 2006;54:239-43.
12. Erdil N, Cetin L, Kucuker S, Demirkilic U, Sener E, Tatar H. Closed endarterectomy for diffuse right coronary artery disease: Early results with angiographic controls. *J Card Surg* 2002;17:261-6.
13. Roberts WC, Turnage TA 2nd, Whiddon LL. Quantitative comparison of amounts of cross-sectional area narrowing in coronary endarterectomy specimens in patients having coronary artery bypass grafting to amounts of narrowing in the same artery in patients with fatal coronary artery disease studied at necropsy. *Am J Cardiol* 2007;99:588-92.
14. Walley VM, Byard RW, Keon WJ. A study of the sequential morphologic changes after manual coronary endarterectomy. *J Thorac Cardiovasc Surg* 1991;102:890-4.
15. Gegouskov V, Tochtermann U, Badowski-Zyla D, Thomas G, Hagl S, Osswald B. Long-term results after coronary artery reconstructive surgery. *Thorac Cardiovasc Surg* 2007;55:293-7.
16. Sachweh JS, Messmer BJ, Groetzner J, Vom Dahl J, Fausten B, Daebritz SH. Left anterior descending coronary artery: Long-term angiographic results of CABG with endarterectomy. *J Cardiovasc Surg (Torino)* 2007;48:633-40.

Received: 12-02-2015 **Edited by:** Yuan-Yuan Ji
How to cite this article: Chi LQ, Zhang JQ, Kong QY, Xiao W, Liang L, Chen XL. Early Results of Coronary Endarterectomy Combined with Coronary Artery Bypass Grafting in Patients with Diffused Coronary Artery Disease. *Chin Med J* 2015;128:1460-4.
Source of Support: Nil. **Conflict of Interest:** None declared.