


Intravenous thrombolysis for stroke in pregnancy should be administered if the benefit outweighs the risk: A case report and recommended diagnostic workup

Women's Health
Volume 17: 1–3
© The Author(s) 2021
Article reuse guidelines:
sagepub.com/journals-permissions
DOI: 10.1177/1745506521999495
journals.sagepub.com/home/whe


Marek Bojda¹, Andrea Cimprichová¹, Bibiana Vavříková¹,
Alena Filipková¹ and Zuzana Gdovinová² 

Abstract

Introduction: There is an ongoing debate about the use of recombinant tissue plasminogen activator in acute stroke during pregnancy. The aim of our case report is to present that even in a small stroke centre intravenous thrombolysis can be used on a pregnant woman if the benefit outweighs the risk and to summarize the diagnostic workup in a pregnant woman with stroke.

Case report: Our case describes a 31-year-old woman presenting in her third trimester with a sudden onset of slurred speech, severe right hemiparesis, facial nerve central palsy, eyes deviation to the left, right side hemianopia, hemisensory loss, psychomotor agitation and pain in the right lower limb. She was successfully treated with recombinant tissue plasminogen activator with almost complete recovery (NIHSS 1 after 10 days), and 23 days after intravenous thrombolysis, she delivered in the 37th week a healthy male infant. The first documented successful outcome from thrombolysis for this condition in Slovakia supports the notion of giving intravenous recombinant tissue plasminogen activator to pregnant patients with disabling ischaemic stroke who meet the criteria for thrombolysis.

Discussion: At the end of case study, a recommended diagnostic workup for acute treatment of stroke in pregnant women is presented.

Keywords

intravenous thrombolysis, pregnancy, stroke

Date received: 20 November 2020; revised: 20 November 2020; accepted: 4 February 2021

Introduction

There is an ongoing debate about the use of recombinant tissue plasminogen activator (rt-PA) in acute stroke during pregnancy.^{1,2} Pregnancy has long been an exclusion criterion from all randomized controlled trials (RCTs) conducted to validate thrombolytic therapy in stroke. Even today, our knowledge stems from individual case reports, and last year, the Canadian Stroke Best Practice Consensus Statement was published on the management of acute stroke in pregnancy.³ However, in clinical practice physicians refrain from thrombolytic therapy during pregnancy, since they fear causing harm to the mother or the foetus.

The aim of our case report is to present that even in a small stroke centre pregnant women can be treated with intravenous rt-PA and to summarize a diagnostic workup in pregnant women with stroke.

¹Department of Neurology, Faculty Hospital Trenčín, Trenčín, Slovakia

²Department of Neurology, Faculty of Medicine, P.J. Šafarik University and University Hospital L. Pasteur, Košice, Slovakia

Corresponding author:

Zuzana Gdovinová, Department of Neurology, Faculty of Medicine, P.J. Šafarik University and University Hospital L. Pasteur, Trieda SNP 1, 04011 Košice, Slovakia.
Email: z.gdovin@gmail.com



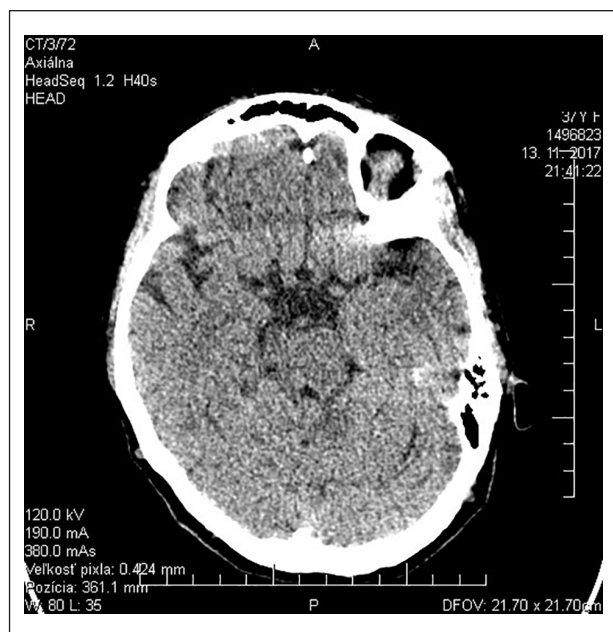


Figure 1. Negative brain computed tomography at admission.

Case report

A 31-year-old woman (weight 58 kg) with a history of coeliac disease and sideropenic anaemia for several years, 34 weeks pregnant, was presented to a local emergency room with sudden onset of slurred speech, severe right hemiparesis, facial nerve central palsy, eyes deviation to the left, psychomotor agitation resulting in an NIHSS of 16 points, pain in the right lower limb, normal blood pressure and tachycardia at 124/min. Standard 12-lead electrocardiogram was normal; laboratory studies showed haemoglobin of 86g/L, D-dimer of 4.27mg/L; other parameters, were normal. Brain computed tomography (CT) was negative (Figure 1); CT angiography was not performed, as there was no sign of hyperdense artery, and due to psychomotor agitation, the patient was not suitable for transport to a secondary stroke centre.

Obstetric ultrasound was normal, without signs of placental alterations; therefore, 65 min after admission and 120 min after symptoms onset, intravenous rt-PA was administered by the standard protocol. We assumed that rt-PA does not pass into the placenta, so we calculated a weight of 48kg before delivery and thus a dose of 40mg was administered. The patient recovered within a few hours to mild hemiparesis and slight aphasia, resulting in an NIHSS of 4 points after 7h and 1 point after 10 days. Nine hours after the intravenous thrombolysis (IVT), brain magnetic resonance imaging (MRI) and magnetic resonance angiography (MRA) showed acute ischaemia in the territory of the left middle cerebral artery (MCA), severe stenosis of the M1 segment of left MCA (Figure 2a and b) and two small ischaemic lesions in the right hemisphere. Twenty-four hours after rt-PA, dual antiplatelet treatment with acetylsalicylic acid (100mg/day) and clopidogrel (75 mg/day) started because of MCA stenosis. Hypomagnesaemia and decreased calcium were

surrogated. Two days after rt-PA, deep vein thrombosis of the right lower limb was confirmed; enoxaparin 50 mg twice daily was added and clopidogrel was dropped.

Transthoracic echocardiogram and prolonged Holter monitoring were negative. Transoesophageal echocardiography planned in view of the deep vein thrombosis to evaluate the right-left shunt was contraindicated by the cardiologist during pregnancy; after delivery, patent foramen ovale, or atrial septal defect was not confirmed.

In consideration of recurrent miscarriages, the patient was tested before the current pregnancy for antiphospholipid syndrome, lupus anticoagulant antibodies, anti β_2 -glycoprotein-I antibodies and anti-cardiolipin antibodies, with negative results.

Twenty-three days after IVT, the patient delivered in the 37th week, labour started spontaneously; the patient delivered a healthy term male infant 3350 g/50 cm, Apgar score 10/10, without complications; the puerperium was normal. The aetiology of stroke was not revealed even after delivery.

Discussion

Thrombolytic therapy with rt-PA is an approved therapy for ischaemic stroke, myocardial infarction, pulmonary embolism and thrombosis of cardiac valve prosthesis. However, there are no data from controlled randomized trials in pregnant patients. So far, the largest number of patients was included in the US Stroke Registry, Get With The Guidelines (GWTG), where pregnant or postpartum (<6 weeks) and non-pregnant women were also compared. There were no cases of major systemic bleeding or in-hospital mortality in this cohort and no increase in adverse events compared to the non-pregnant cohort.⁴ The risk of using thrombolytics in pregnancy seems reasonable taking into account the risk of death in a life-threatening event. However, some reviews describe major bleeding events when thrombolytics agents were used for another purpose.

In addition to these results, only case reports have been published: to the best of our knowledge, 17 case studies of patients treated with IV rt-PA and four case studies about endovascular treatment alone or in combination with IV rt-PA.⁵⁻¹⁰ In the clinical routine, physicians refrain from using thrombolytic therapy on pregnant patients, since they fear they will cause harm to the mother or the foetus because information about the safety of thrombolytics in pregnancy is lacking. The most serious possible complication for both mother and foetus is the bleeding.

The recommended diagnostic workup in pregnant women with stroke based on the available literature is as follows:

Rapid presentation at a stroke centre. Neuroimaging immediately to confirm the diagnosis. Given the severe maternal risk caused by potential delay in diagnosis of stroke and the small risk to the foetus, neuroimaging with CT is acceptable, including CT angiography to detect large vessel occlusion (LVO).^{3,5-8} There is a lack of evidence on, but no known harm from, CT contrast. In selected cases (e.g. the presence of hyperdense MCA on non-contrast CT

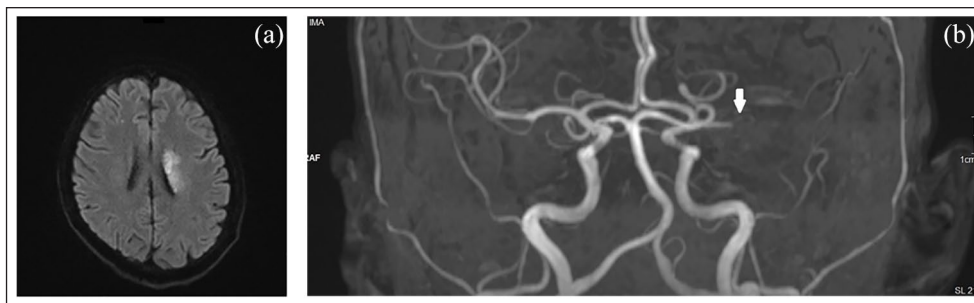


Figure 2. Brain magnetic resonance imaging (MRI) 9h after rt-PA: (a) diffusion-weighted axial images showed the area of restricted diffusion in the territory of left lenticulostriate branches of the middle cerebral artery (MCA) and (b) severe stenosis of the M1 segment of the left MCA.

angiography) CTA may be deferred in favour of moving directly to digital subtraction angiography for potential treatment of LVO. MRI of the brain, even in the first trimester, is not associated with increased foetal risks. The use of gadolinium contrast should be avoided. Diffusion weighted images (DWIs) are important in assessing the timing of the ischaemia. Management of acute stroke in pregnant women should reflect collaboration between stroke teams and obstetrics teams,^{3,5–8} this also includes the treatment of severe hypertension (i.e. sBP > 160 mmHg or dBP > 110 mmHg). In pregnant women who present to the hospital with acute stroke, gestational age should be established where possible.

The outcome of our patient support IVT is an effective treatment for pregnant women with stroke after consideration of the risk/benefit ratio. Both mechanical thrombectomy and IVT should be considered in patients with LVO.^{4,9,10} The risk of recurrent ischemic stroke during subsequent pregnancies is low.¹¹

Author contributions

Treatment decision – M.B., A.C., B.V., A.F.; concept of the work and writing of the first draft – M.B. and Z.G.; review and critique and approval of the final version – M.B., A.C., B.V., A.F., and Z.G.

Declaration of conflicting interests

The author(s) declared the following potential conflicts of interest with respect to the research, authorship, and/or publication of this article: Z.G. received honoraria for lectures from Boehringer-Ingelheim and serves as the member of the European Academy of Neurology Stroke Management Panel, there is no conflict of the interest in relation to this article, M.B., A.C., A.F., B.V. have nothing to declare.

Funding

The author(s) received no financial support for the research, authorship, and/or publication of this article.

Informed consent

As we know, there is no requirement for the case report to be approved by the ethics committee, the patient has agreed to the

treatment, the patient has signed the informed consent in accordance with the laws of our country.

ORCID iD

Zuzana Gdovinová  <https://orcid.org/0000-0002-7396-5052>

References

- Selim MH and Molina CA. The use of tissue plasminogen activator in pregnancy. *Stroke* 2013; 44: 868–869.
- Demchuk AM. Yes, intravenous thrombolysis should be administered in pregnancy when other clinical and imaging factors are favorable. *Stroke* 2013; 44(3): 864–865.
- Ladhani NNN, Swartz RH, Foley N, et al. Canadian stroke best practice consensus statement: acute stroke management during pregnancy. *Int J Stroke* 2018; 13(7): 743–758.
- Leffert LR, Clancy CR, Bateman BT, et al. Treatment patterns and short-term outcomes in ischemic stroke in pregnancy or postpartum period. *Am J Obstet Gynecol* 2016; 214: 723.e1–723.e11.
- Reining-Festa A, Foldy D, Coulibaly-Wimmer M, et al. Intravenous thrombolysis of stroke in early pregnancy: a case report and review of the literature. *J Neurol* 2017; 264(2): 397–400.
- Ritchie J, Lokman M and Panikkar J. Thrombolysis for stroke in pregnancy at 39 weeks gestation with a subsequent normal delivery. *BMJ Case Rep*. Epub ahead of print 11 August 2015. DOI: 10.1136/bcr-2015-209563.
- Tassi R, Acampa M, Marotta G, et al. Systemic thrombolysis for stroke in pregnancy. *Am J Emerg Med* 2013; 31(2): 448.e1–448.e3.
- Wiese KM, Talkad A, Mathews M, et al. Intravenous recombinant tissue plasminogen activator in a pregnant woman with cardioembolic stroke. *Stroke* 2006; 37(8): 2168–2169.
- Bhokal P, Aguilar M, AlMatter M, et al. Mechanical thrombectomy in pregnancy: report of 2 cases and review of the literature. *Interv Neurol* 2017; 6(1–2): 49–56.
- Aaron S, Shyamkumar NK, Alexander S, et al. Mechanical thrombectomy for acute ischemic stroke in pregnancy using penumbra system. *Ann Indian Acad Neurol* 2016; 19: 261–263.
- Lamy C, Hamon JB, Coste J, et al. Ischemic stroke in young women: risk of recurrence during subsequent pregnancies. French Study Group on Stroke in Pregnancy. *Neurology* 2000; 55: 269–274.