

## Pediatric calcaneal fractures

Hobie Summers, Patricia Ann Kramer,  
Stephen K. Benirschke

Department of Orthopaedics and Sports  
Medicine, Harborview Medical Center,  
University of Washington, Seattle, WA,  
USA

### Abstract

Although operative treatment of displaced, intra-articular fractures of the calcaneus in adults is generally accepted as standard practice, operative treatment for the same fractures in the skeletally immature remains controversial, potentially because the outcome for fracture types (intra- vs. extra-articular) and severity (displaced vs. nondisplaced) have been confounded in studies of children. We review herein the results of 21 displaced, intra-articular fractures in 18 skeletally immature patients, who were treated with open reduction and internal fixation using a standard surgical approach and protocol developed for adults. The average pre-operative Böhler's angle on the injured side was  $-5^\circ$  (range:  $-35$  -  $+35$ ) compared to  $31^\circ$  (range:  $+22$  -  $+47$ ) on the uninjured side, indicating substantial displacement. There were no post-operative infections or wound healing problems, and all but one patient was followed to union (average follow-up: 1.5 years; range: 0.30-4.3 years). Maintenance of reduction was confirmed on follow-up radiographs with an average Böhler's angle of  $31^\circ$  (range:  $+22$  -  $+49$ ). We demonstrate that results for operative fixation of displaced, intra-articular calcaneal fractures in the skeletally immature are comparable to those in adults when the treatment protocol is the same.

### Introduction

Although operative intervention for adults with displaced, intra-articular calcaneal fractures has become the generally accepted standard practice<sup>1,2</sup> and, recently, Petit and colleagues<sup>3</sup> described good operative outcome in 13 children with 14 displaced intra-articular fractures, it remains unclear to some whether or not skeletally immature patients experience the same benefits from operative intervention to obtain anatomic reduction as adults. One problem has been the lack of stratification based on injury pattern, displacement, age, or skeletal maturity. Displaced, intra-articular fractures of the calcaneus are rare in the skeletally immature<sup>4</sup> and reports of "pediatric" cal-

canal fractures generally include both intra- and extra-articular fractures with varying degrees of displacement across broad chronological age ranges.<sup>5-10</sup> As a result of confounding fracture severity, a lingering impression that children will remodel displaced fractures with little or no functional loss remains. No evidence, however, that supports this contention for displaced, intra-articular calcaneal fractures exists in the literature. Thomas<sup>11</sup> suggested that the unfused talus could remodel, providing some subtalar joint congruity, but this hypothesis has not been tested with serial radiographs or CT images. Further, while it is possible that the talus may remodel to conform to a deformed calcaneus, subtalar joint congruity does not address the interface of the calcaneus with the other tarsals or with the ground. Thus, given that children will experience the result of their fracture treatment for decades and that the standard treatment for adults is operative reduction to restore anatomic configuration, the only reason to not surgically address displaced, intra-articular fractures in children is if there are difficulties in obtaining or maintaining reduction or if other pre-surgical contraindications or post-surgical complications are present. Because few studies have specifically addressed intra-articular fractures with substantial displacement in the skeletally immature<sup>3,6,9</sup> and none have compared children to adults, we sought to answer the question: are skeletally immature patients with displaced, intra-articular calcaneal fractures different in their injury characteristics or outcome from adults?

### Patients and Methods

Institutional Review Board approval was obtained to retrospectively review the charts of all calcaneus fractures treated at our institution from April 1989 to October 2006. All patients with a displaced, intra-articular calcaneal fracture and open calcaneal physes were included. Our prospectively collected trauma database identified 2,031 calcaneus fractures. Forty of these patients had open physes at the time of injury. Of these skeletally immature patients, 6 received an amputation due to a mangled extremity and 13 were treated non-operatively due to lack of displacement or an extra-articular fracture. In addition, 2 patients sustained their injuries from a lawn mower and another one from a jet ski propeller. All 3 of these resulted in massive soft tissue and skeletal injuries that limited the reconstructive alternatives. This left 18 skeletally immature patients with 21 displaced, intra-articular fractures. The data of these children were compared to those of a group of adults from the same institution and approximate time frame.<sup>12</sup>

Correspondence: Hobie Summers,  
Department of Orthopaedics and Sports Medicine,  
Harborview Medical Center, University of  
Washington, Seattle, WA, USA  
E-mail: hobieds@yahoo.com

Key words: calcaneus, intra-articular, pediatric.

Received for publication: 28 March 2009.  
Revision received: 10 June 2009.  
Accepted for publication: 15 June 2009.

This work is licensed under a Creative Commons  
Attribution 3.0 License (by-nc 3.0)

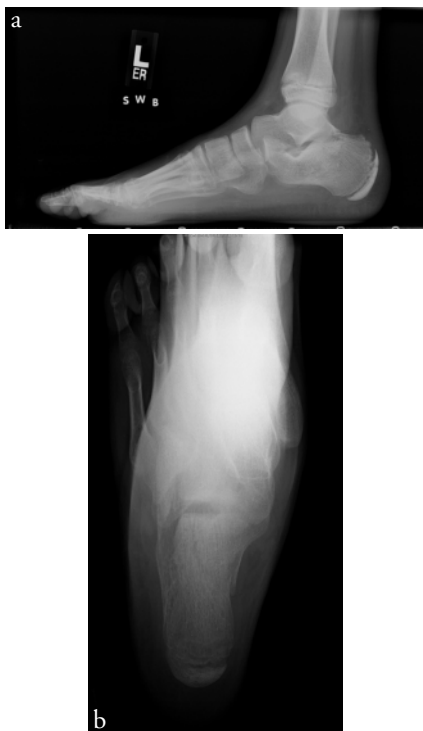©Copyright H. Summers et al., 2009  
Licensee PAGEPress, Italy  
Orthopedic Reviews 2009; 1:e9  
doi:10.4081/or.2009.e9

The adults in the comparison group were selected to match the fracture pattern (displaced, intra-articular) and treatment protocol (open reduction internal fixation (ORIF) via a lateral incision, described below) of the children and represent a sub-sample (n=368) of those patients described elsewhere.<sup>12</sup> All patients received the following standard protocol. After pre-operative antibiotics were administered, a standard L or J shaped lateral incision was used, and the calcaneus was exposed as has previously been described for adults.<sup>12,13</sup> Anatomic reconstruction of the height, width, length, and articular surfaces was the goal. For the children, small and mini-fragment implants were used for fixation. No locking plates were used in the children and no fixation crossed the calcaneal apophysis. Implants used for the adults included standard calcaneal reconstruction plates. Post-operative prophylactic antibiotics were administered both to children and adults whose incisions were not sealed at the time of discharge and continued until the wounds had sealed. Patients were allowed to begin range of motion exercises of the foot and ankle as soon as the surgical wound was healed and sutures were removed, typically at 2-3 weeks post-operatively. A removable resting splint was used to prevent equinus contracture. All patients were instructed to remain non-weight bearing for 12 weeks and were then gradually progressed to weight bearing as tolerated. While we recognize that children heal more quickly than adults, we prescribe 12 weeks of non-weightbearing because the consequences of early weightbearing (broken implants, poor healing and additional surgery) are substantially worse than the cost (inconvenience to parent and child). Further, children will mediate their compliance with this prescription. Hardware removal is offered after fracture consolidation (usually more than one year after injury) to those patients with irritation over the implant. Patient, injury and treat-

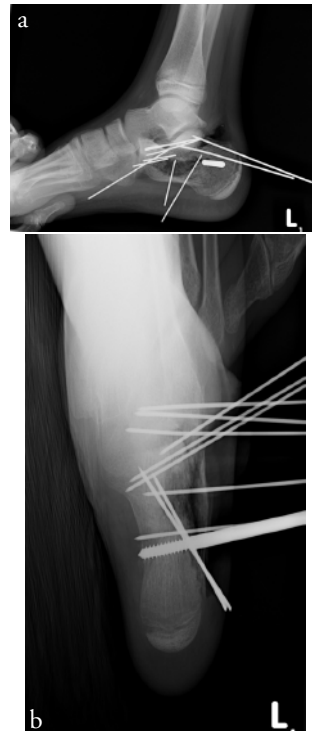
**Table 1. Characteristics and outcome of skeletally immature patients (children) compared to adults.**

| Variable   | Children       | Adults <sup>1</sup> |
|--|----------------|---------------------|
| <b>Patient characteristics</b>                             |                |                     |
| N. fractures   | 21             | 368                 |
| N. patients  | 18             | 288                 |
| N. males (%)   | 15 (83%)       | 256 (89%)           |
| Average age in years (range)                               | 12 (3-16)      | 40 (16-77)          |
| <b>Injury characteristics</b>                              |                |                     |
| N. left calcanei (%)                                       | 9 (43%)        | 179 (49%)           |
| N. patients with bilateral                                 | 3 (17%)        | 40 (14%)            |
| N. tongue-type (%) <sup>2</sup>                            | 5 (24%)        | 148 (40%)           |
| N. open (%)  | 2 (9%)         | 37 (10%)            |
| N. injuries caused by falls                                | 14 (67%)       | 295 (80%)           |
| N. injuries caused by motor vehicle accident               | 6 (29%)        | 79 (21%)            |
| <b>Treatment</b>   |                |                     |
| Average time to surgery in days (range)                    | 10 (4-17)      | 13 (1-94)           |
| N. feet with allograft (%)                                 | 11 (52%)       | 109 (70%)           |
| N. patients who received oral antibiotics at discharge (%) | 4 (22%)        | 130 (45%)           |
| <b>Post-surgical outcome</b>                               |                |                     |
| Average follow-up in years (range)                         | 1.5 (0.3-4.29) | 2.0 (1-10.03)       |
| N. feet with hardware removal (%)                          | 15 (71%)       | 223 (61%)           |
| N. patients with wound healing complications (%)           | 0              | 7 (2%)              |
| <b>Böhler's angle</b>                                      |                |                     |
| Injury in degrees  | -5 (-35 - +35) | 1 (-45 - +45)       |
| Post-operative in degrees                                  | 30 (20-50)     | 33 (22-46)          |
| Follow-up in degrees                                       | 31 (22-49)     | 32 (20-44)          |
| Contralateral in degrees                                   | 31 (22-47)     | 32 (18-44)          |
| Change between injury and post-operative in degrees        | 35 (14-65)     | 32 (7-85)           |

<sup>1</sup>The data for adults is a subsample that includes only displaced, intra-articular fractures in adults from the group documented by ref. 12. Böhler's angles were assessed on all individuals for whom injury, post-operative, follow-up and contralateral radiographic views were available (n=70). <sup>2</sup>As defined by Letoumel's method.



**Figure 1.** Injury to left calcaneus is shown in a) lateral and b) axial view. This boy was 12.75 years old at the time he was injured by falling from monkey bars at a school playground. The calcaneal apophysis is clearly evident.

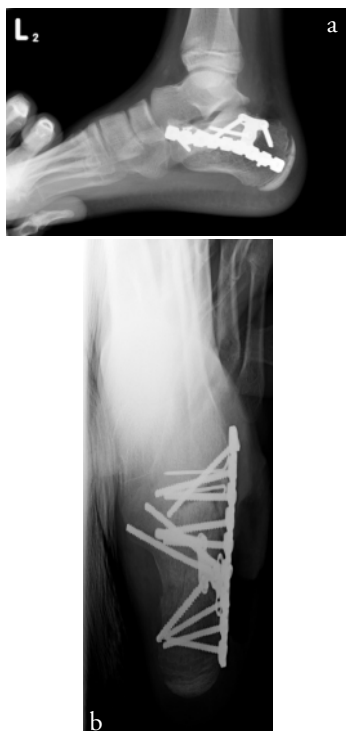


**Figure 2.** Intra-operative reduction shown in a) lateral and b) axial view. Kirschner wires temporarily hold the posterior facet in place. Note the osseous defect that will be filled with allograft to facilitate tightening the screws across the injured calcaneus.

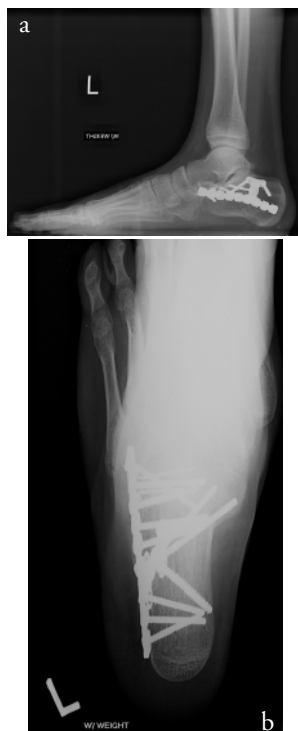ment characteristics were gathered from retrospective review of the medical records of both children and adults. Böhler's angle was measured by one of us using radiographs taken of the initial injury (Figure 1), of the operative reduction, (Figure 2,3) and of the reduction status after weight bearing at final clinical follow-up (Figure 4) and these values were compared to angles measured on the radiographs of the contralateral side (Figure 5) in the cases with unilateral injury. All radiographs were re-measured to assess intrarater reliability and an intraclass correlation coefficient 0.94 was obtained with all angular discrepancies within 5°. Continuous variables were compared using Student's t-test, while for categorical variables we used the Wilcoxon non-parametric test. Statistical significance was set at  $p < 0.05$ . All statistical analyses were carried out using STATA (STATA Corp., College Station, TX, USA).

## Results

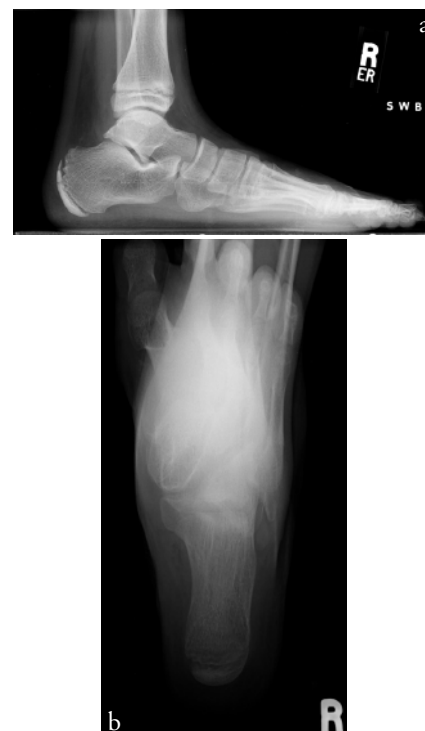Details of the patient, injury and treatment characteristics and outcome for the skeletally immature group are presented in Table 1 along with those of the comparison adult group. In general, the characteristics and outcome of the two groups are similar. Children were followed on average for 1.5 (range: 0.3-4.29) years while adult follow-up was 2.0 (1-10.03) years. No skeletally immature patient had problems related to wound healing, similar to the 2% seen in the adult group. In general, the characteristics and outcome of the two groups are similar, although there were fewer tongue-type<sup>14</sup> fractures in children. There were 2 open injuries in the skeletally immature group. One occurred in a 5-year old patient who sustained a crush injury by a garage door. He had a Type IIIA open medial wound that was treated with two debridements and delayed primary closure prior to fixation of his calcaneus. He had no infectious complications. The other was in a 13-year old patient who had jumped 4 stories off a building and sustained bilateral fractures. The right calcaneus was classified as a Type II open injury on the medial side, and was treated uneventfully with irrigation and debridement and primary closure of the wound. Several patients experienced notable sequelae to their injury, though all of these are also known in the adults.<sup>12</sup> There was one varus malunion in the 5-year old male with an open fracture who subsequently underwent calcaneal osteotomy six months after injury. One patient with bilateral calcaneal fractures and a pelvic ring injury developed a sacral decubitus that was managed with local wound care. Two patients developed claw toes, one of which required Girdlestone transfers for toes two through five. One patient underwent subtalar cheilectomy at the time of



**Figure 3.** Final reduction after implants are secured shown in a) lateral and b) axial view.



**Figure 4.** Healed fracture with implants in place after 1.5 years shown in a) lateral and b) axial view. Note that the apophysis is now fused.



**Figure 5.** Uninjured right calcaneus shown in a) lateral and b) axial view. Note the unfused apophysis.

hardware removal one years after the injury. Böhler's angle for the injury, post-operative, follow-up and contralateral conditions, and the change in Böhler's angle between injury and post-operative exams, was not significantly different between children and adults ( $p>0.05$ ). The degree of posterior facet displacement that was seen in the skeletally immature group was as substantial as that seen in adults. Even the child with an injury Böhler's angle of  $35^\circ$  was substantially displaced, because his contralateral angle was  $49^\circ$ . Maintenance of reduction was confirmed on follow-up radiographs in both groups. Notably, none of the skeletally immature patients have experienced a collapse of the posterior facet and failure of the buttressing hardware. Although this event is rare in adults, it does occasionally occur and, when it does, is difficult to treat. Six adults in this group experienced a change between post-operative (average:  $24.8^\circ$ ) and follow-up (average:  $-1^\circ$ ) Böhler's angles. These patients had substantial injuries but they were not unusual in any of their injury or other characteristics. In retrospect, we believe that their bone quality was poor, although we do not have the studies to confirm this assumption. We recommend fixed angle (locking) implants and a longer period of protected weightbearing for patients presenting with poor bone quality.

## Discussion

Treatment of displaced, intra-articular calcaneal fractures in the skeletally immature has received little attention in the literature until recently. Perhaps one reason for this is that Thomas<sup>11</sup> hypothesized that the subtalar joint may remodel in skeletally immature patients after calcaneal fracture. He imagined that the articular surface of the talus could remodel to accommodate the deformity of the calcaneus as the child grows. These developmental changes in the talus potentially allow the formation of a relatively congruent joint which preserves hindfoot motion and potentially allows for a low rate of the development of arthrosis. This hypothesis has not, however, been demonstrated with serial CT scans or post-mortem examinations. Further, even in this scenario, the entire calcaneus does not remodel, as is evidenced by the persistent axial deformity and loss of Böhler's angle after non-operative treatment in the growing child.<sup>5</sup> Although there is the possibility that talar remodeling provides some protection to the subtalar joint in minimally displaced intra-articular injuries, the persistent hindfoot deformity in substantially displaced fractures may lead to long-term foot and ankle disability. This is a particularly egregious possibility

because, while adults will live with the outcome of their fracture treatment for approximately 40 years, children will experience this disability for over 70 years of their life, potentially impacting everything from their body habitus to their selection of occupation. Brunet<sup>5</sup> described conservatively treated intra- and extra-articular calcaneal fractures with a follow-up rate of 50%. The average age at injury was 6.2 years with a mean follow-up of 16.8 years. Among 19 fractures, 14 were intra-articular, but only 6 had "gross" displacement. The inclusion criteria for "gross" displacement was 5 mm displacement or a loss of Böhler's angle of  $8^\circ$  or more. By their criteria, all of our children experienced gross displacement. Brunet reported AOFAS scores that averaged 96.2 for all fractures, but all patients with a score of less than 100 also had displaced, intra-articular fractures that had been conservatively treated. In other words, displaced, intra-articular fractures in children can heal and cause few problems in young adulthood, but those patients who do have reduction of function when in their 20s are those whose initial injuries were intra-articular and displaced. This finding is particularly dismaying because children are ideal candidates for surgical intervention to obtain anatomic reduction because they heal rapidly with few complications. For those patients described by Brunet who have

AOFAS scores of 100 in their 20s, it remains to be determined whether or not they will experience functional loss due to their childhood fracture as they enter middle or old age. A mounting body of evidence<sup>3,9,15</sup> indicates that the appropriate treatment of displaced, intra-articular fractures in skeletally immature patients is the same as that for adults: open reduction and internal fixation with anatomic reduction of the entire calcaneus. Our operative results are similar to those presented by Petit and colleagues,<sup>3</sup> who found that most children had good clinical outcome after surgical intervention. Few differences exist between skeletally immature and mature patients in their injury characteristics or outcomes. Indeed, the pediatric population is an ideal patient population to perform open reduction and internal fixation of displaced fractures, because anatomic reduction is possible in children and they have excellent healing capabilities with low complication rates using the standard surgical dissection and commonly used implants. Additionally, these children are (usually) non-smokers, not involved in litigation or workmen's compensation claims, and not generally disobedient of medical orders, all possible contraindications in adults. The potential foot problems stemming from hind-foot varus malalignment or other morphological discrepancies over a lifetime of 70 or more years is concerning, especially because restoration of normal hindfoot anatomy may prevent such long-term functional loss. A strength of this paper is that we have contralateral (uninjured) radiographs for all of our unilaterally injured patients, which allows us to assess quantitatively the extent of displacement caused by the trauma. We obtain these pre-operatively to facilitate anatomic reduction of the injured side. Although Böhler's angle varies among people by more than 30°<sup>16,17</sup> within a person the variation is within the 5° measurement error of the angle. In addition, we are also able to compare directly the outcome of skeletally mature and immature patients who

were treated using the same techniques and protocols. Although our study would have been scientifically improved with a control group of conservatively treated children, our standard of care is to offer open reduction and internal fixation for all displaced, intra-articular fractures regardless of the age of the patient. We found that displaced, intra-articular injuries in children are similar in injury characteristics and outcome to those of adults, at least within the first few years after surgical intervention. The children in our study healed with few complications after their surgery, and anatomic reduction was obtained and maintained in them much as in our adult patients. Consequently, we feel that, in the absence of other contraindications, all displaced, intra-articular fractures of the calcaneus warrant surgical intervention regardless of the age of the patient.

## References

- Howard JL, Buckley R, McCormack R, et al. Complications following management of displaced intraarticular calcaneal fractures: a prospective randomized trial comparing open reduction internal fixation with nonoperative management. *J Orthop Trauma* 2003;17: 241-9.
- Rammelt S, Zwipp H. Calcaneus fractures: facts, controversies and recent developments. *Injury* 2004;35:443-61.
- Petit CJ, Lee BM, Kasser JR, Kocher MS. Operative treatment of intraarticular calcaneal fractures in the pediatric population. *J Pediatr Orthop* 2007;27:856-62.
- Schneidmueller D, Dietz HG, Kraus R, Marzi I. Calcaneal fractures in childhood: a retrospective survey and literature review. *Unfallchirurg* 2007;110:939-45.
- Brunet JA. Calcaneal fractures in children. Long-term results of treatment. *J Bone Joint Surg Br* 2000;82: 211-6.
- Ceccarelli F, Faldini C, Piras F, Giannini S. Surgical versus nonsurgical treatment of calcaneal fractures in children: a long-term results comparative study. *Foot Ankle Int* 2000;21:825-32.
- Inokuchi S, Usami N, Hiraishi E, Hashimoto T. Calcaneal fractures in children. *J Pediatr Orthop* 1998;18:469-74.
- Mora S, Thordarson DB, Zions LE, Reynolds RA. Pediatric calcaneal fractures. *Foot Ankle Int* 2001;22:471-7.
- Pickle A, Benaroch TE, Guy P, Harvey EJ. Clinical outcome of pediatric calcaneal fractures treated with open reduction and internal fixation. *J Pediatr Orthop* 2004;24: 178-80.
- Schmidt TL, Weiner DS. Calcaneal fractures in children. An evaluation of the nature of the injury in 56 children. *Clin Orthop Relat Res* 1982;171:150-5.
- Thomas HM. Calcaneal fracture in childhood. *Br J Surg* 1969;56:664-6.
- Benirschke SK, Kramer PA. Wound healing complications in closed and open calcaneal fractures. *J Orthop Trauma* 2004; 18:1-6.
- Benirschke SK, Sangeorzan BJ. Extensive intraarticular fractures of the foot. Surgical management of calcaneal fractures. *Clin Orthop Relat Res* 1993;292:128-34.
- Letournel E. Open reduction and internal fixation of calcaneus fractures. In *Topics in Orthopedic Trauma* 173-192. Edited by Spiegel, P., 173-192., Baltimore, University Park Press, 1984.
- Knorr P, Dietz H, Kruger P. Bilateral calcaneus fracture in childhood. A report of experiences. *Unfallchirurg* 1992;95:106-8.
- Igbigbi PS, Mutesasira AN. Calcaneal angle in Ugandans. *Clin Anat* 2003;164: 328-30.
- Khoshhal KI, Ibrahim A F, Al-Nakshabandi NA, et al. Bohler's and Gissane's angles of the calcaneus in the Saudi population. *Saudi Med J* 2004;25:1967-70.