

# Allergic Dermatitis Following Bilateral Oxidized Zirconium Total Knee Replacements

Marlon M Mencia<sup>1</sup>, Shamir O Cawich<sup>1</sup>

## Learning Point of the Article:

Informed consent should include the possibility of allergic skin reactions occurring even when hypo-allergenic oxinium implants are used in total knee arthroplasty.

## Abstract

**Introduction:** Total knee replacement (TKR) utilization is expected to increase by 673% in 2030, with patients between the ages of 45 to and 64 years representing the fastest-growing fastest growing age group requiring joint replacement. This group not only demands a higher-performing higher performing, durable prosthesis but are also the most likely to be dissatisfied if their expectations are not met. Hypo-allergenic implants have been developed by some implant manufacturers to fill this need, so the occurrence of allergic skin reactions after surgery is unanticipated and can have unwanted consequences if not recognized and managed appropriately.

**Case Report:** We present the case of a 55-year-old woman who underwent bilateral staged TKR using oxidized zirconium implants and subsequently developed eczematous skin reactions. In both instances, she presented with a peri-incisional erythematous blistering skin reaction that was successfully treated with topical corticosteroids. Investigations revealed no evidence of infection or allergic-type allergic type reactions to the metals contained in the knee replacements.

**Conclusion:** Allergic skin reactions following TKR are very rare, and are not necessarily due to a metal hypersensitivity. Infection must be excluded in all cases and a trial of topical corticosteroids is useful before prior to more aggressive treatment, with the removal of the implant reserved as a last resort. To the best of our knowledge, this is the first case in the literature that reports the occurrence of allergic skin reactions following oxidized zirconium TKRs, and highlights the fact that allergic skin reactions can occur when using hypo-allergenic implants. Surgeons should be aware of this possibility and counsel their patients appropriately during the informed consent process.

**Keywords:** Metal allergy, hypo-allergenic implants, oxidized zirconium, hypersensitivity.

## Introduction

The knee is commonly affected by osteoarthritis and it is estimated that eleven million adults in the United States have symptomatic arthritis. At present about four million patients have had a total knee replacement (TKR) and utilization is projected to grow by 673% in 2030. [1, 2]

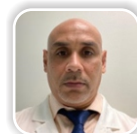
Young patients between the ages of 45 to 64 years represent the fastest growing age group requiring TKR. [3] This group is usually very active, demanding more out of their joint replacement. The survivorship for conventional TKR in young active patients is considerably less than in the older, more sedentary patient, paving the way for the development of more

robust implants [4].

Aseptic loosening due to the development of allergic reactions to the metallic implants has been implicated as a reason for revision surgery. In an attempt to reduce this complication, we have seen the evolution of newer, high-performance hypoallergenic knee replacement systems. These new materials promise better durability and function with a lower risk of allergic reactions.

There is a notable relationship between metal sensitivity and allergic reactions to implants. Approximately 10% of the general population is patch test positive for metal sensitivity. It is noted that the incidence of metal sensitivity doubles in patients with

## Author's Photo Gallery



Dr. Marlon M Mencia



Dr. Shamir O Cawich

Access this article online

Website:  
www.jocr.co.in

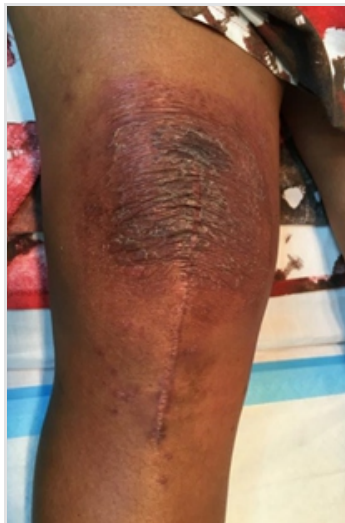DOI:  
10.13107/jocr.2021.v11.i02.2030

<sup>1</sup>Department of Orthopaedics, Westshore Medical Private Hospital, Cocorite, Trinidad, West Indies.

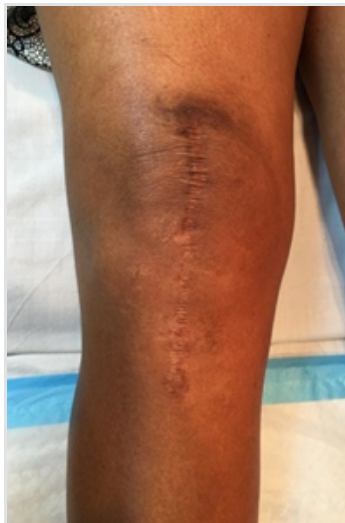### Address of Correspondence:

Dr. Marlon M. Mencia,  
Department of Orthopaedics, DM, FACS. Westshore Medical Private Hospital, 239 Western Main Road, Cocorite, Trinidad, West Indies.  
E-mail: socawich@hotmail.com





**Figure 1:** Eczematous skin reaction after the right total knee replacement.



**Figure 2:** Improvement in the skin following application of a topical corticosteroid.

well-functioning joint replacements, despite the absence of clinical allergic reactions to their implants. Therefore, one can appreciate that the relationship remains relatively obscure.

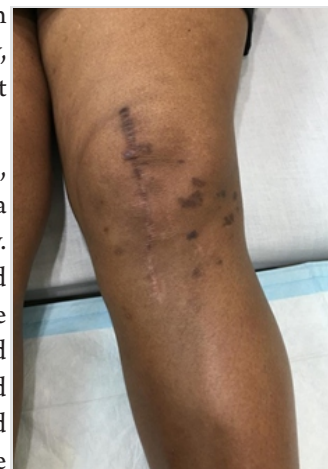We report a case of a patient with idiopathic allergic dermatitis following hypoallergenic knee replacements. To the best of our knowledge this is the first case of dermatitis occurring after an oxidized zirconium TKR. This case highlights the difficulties in diagnosing metal hypersensitivity reactions and also reinforces the need for further research to better elucidate the relationship between metal hypersensitivity, allergic reactions and implant survivorship.

### Case Report

A 55-year-old woman presented with bilateral knee pain for several years secondary to advanced tri-compartmental osteoarthritis, marginally worse on the right side.

The patient enjoyed an active social life, had no known allergies, and exercised regularly. Following a discussion of the surgical options, it was decided that the genesis II total knee replacement (TKR) with Oxinium (Smith and Nephew, Memphis, TN) would be most appropriate for her activity levels.

We performed the right TKR first, using a midline skin incision and a medial parapatellar arthrotomy. Intramedullary alignment jigs and a measured resection technique were used to prepare the bone and achieve balance in flexion and extension. The bone was cleaned with pulsatile lavage and the components cemented in place,



**Figure 3:** Skin changes at annual clinic follow-up.

with the tourniquet used only during cementation. The knee was closed in layers and the patient was given three post-operative doses of intravenous cefuroxime.

Following an uncomplicated post-operative period at 10 weeks after surgery, the proximal extent of the incision became erythematous, discharging a serous fluid. This was treated expectantly with local dressings, however, the erythematous area became larger and began to spread distally (Fig. 1).

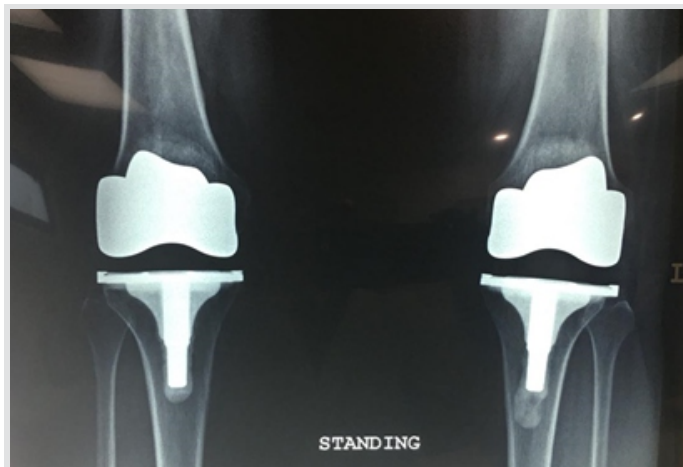Inflammatory markers were within normal limits (C-reactive protein 1.1 mg/L and erythrocyte sedimentation rate 18 mm/h) and clinically the patient demonstrated an excellent range of pain-free knee movement. A consultation with the dermatology unit suggested that this may be allergic dermatitis and recommended a trial of topical corticosteroids. Dermovate (clobetasol propionate 0.05% w/w) was applied to the affected area and within 48 h there was a marked improvement in the appearance of her skin (Fig. 2).

Six months later, the patient underwent a left genesis II TKR with oxidized zirconium implants using a similar technique as previously described. Twelve weeks after surgery, the proximal aspect of the incision became inflamed with local blistering. On this occasion, dermovate cream was used as first-line treatment, leading to resolution within 24 h.

At the annual clinic visit, we observed hyperpigmented spots on the skin surrounding both knees and on her feet and hands (Fig. 3).

The patient has remained asymptomatic, with excellent knee function and radiographs show no signs of loosening (Fig. 4). Skin patch testing with a commercially available kit for the metals used in the knee replacement was negative and at 18 months from her first TKR, the patient remains satisfied with the clinical outcome. We continue to follow her up with annual clinical and radiological assessments.

### Discussion



**Figure 4:** Anterior-posterior radiograph at 1 year post-operative.

Nickel allergy caused by the implantation of a stainless steel plate was first reported in the medical literature in 1966 by Fousereau and Laugier [5]. Nickel is most commonly implicated in metal allergies, but other metals used in reconstructive surgery have also been associated with allergic reactions, including cobalt, chromium, and titanium.

Although many authors have noted an association between metal hypersensitivity and the development of allergies to implanted metallic devices, a causal relationship has not been definitively proven [6]. Metal hypersensitivity is fairly common, with a reported incidence of 10–15% in the general population. It increases to 25% in patients with well-functioning implants and up to 60% when there is evidence of aseptic loosening [7,8].

Aseptic loosening is a major cause of implant failure leading to revision, and there is concern that patients with metal hypersensitivity will have a higher rate of aseptic loosening. With revision surgery costing 2–3 times the primary operation, this can lead to a significant financial burden on the health system [9].

The immune system is responsible for the development of allergies to implanted metallic devices. Therefore, it is important to understand the underlying pathophysiology. Essentially, any metallic implant that is in contact with body fluids will undergo corrosion and release metal ions, which are not allergenic in themselves, but may combine with tissue proteins and then act as antigens. The reaction is a delayed hypersensitivity Type IV allergic reaction which involves the initial phase of sensitization and then the effector phase with the activation of T-cells and macrophages [6]. The primary antigen-presenting cell in the dermis is the Langerhans cell which produces a dermatitis-type reaction. It must be borne in mind that materials other than those commonly implicated in allergic-type reactions can also cause contact dermatitis. Polymethylmethacrylate used in fixing the implants to bone, gentamycin embedded in the cement and even sutures have all been reported to cause contact dermatitis [10, 11, 12].

Histological examination of tissues around failed metal-on-metal hip arthroplasties has revealed perivascular and diffuse lymphocyte infiltration, both of which are associated with delayed-type hypersensitivity reactions. These findings support the theory that delayed-type hypersensitivity to metals plays an important role in implant failure [13].

Skin patch testing remains the most common method used to test for delayed hypersensitivity. It is a relatively inexpensive method that can be readily performed in the office with commercially available kits. Some drawbacks include false-positive results due to contact irritation and false-negative results due to the lack of ions produced from corrosion or

dissolution.

In this case, the patient presented on two occasions following oxidized zirconium TKRs with a temporally related eczematous dermatitis reaction on the skin surrounding the incision. The clinical features were in keeping with the description by Verma et al. in their report of the typical allergic dermatitis-type reactions [14]. Determining whether the allergic reaction is due to an implanted metal is difficult. Some authors have proposed management algorithms to diagnose and treat clinically suspected implant-related allergies, although none are universally accepted [15].

Common among the many reports is the need to first exclude infection as the cause of a skin reaction following TKR [16]. Using the 2018 definition of periprosthetic hip and knee infection as proposed by the musculoskeletal infection society, our patient's aggregate score did not meet the threshold for periprosthetic infection [17].

Patch testing using the implant manufacturer-derived testing kit revealed no evidence of skin allergy to the implanted metals. Based on the clinical features and there being no evidence of infection or metal allergy, we suspected that the skin reaction was due to contact dermatitis caused by an unknown allergen. Verma et al. reported on 30 patients who developed post-operative contact dermatitis following TKR, in 23 patients, no allergen was found with only 7 cases showing any signs of metal hypersensitivity but all patients were treated successfully with topical corticosteroids [14]. In keeping with the report by Verma et al., our patient responded well to topical corticosteroids.

The well-publicized failure of metal-on-metal hip replacement has no doubt heightened public awareness of the potential problems related to metal implants. Manufacturers have been quick to capitalize on this and several companies now produce hypoallergenic implants. Oxidized zirconium (Oxinium®, Smith and Nephew) has been proven efficacious at preventing post-operative allergic reactions while being less expensive than the alumina ceramic implant [18]. In our patient, we chose an oxidized zirconium implant, because of its reported durability in active patients, an added benefit was its hypoallergenicity. Although we have excluded a metal allergy as the cause of the skin reaction, we were unable to identify the allergen in this patient.

## Conclusion

To the best of our knowledge, this is the first case of dermatitis occurring after an oxidized zirconium TKR. This highlights the possibility than in susceptible individuals undergoing joint replacement, allergic skin reactions may occur even with the use of hypoallergenic implants. This is important since many



patients choose to use hypoallergenic implants with the expectation that allergic reactions will not occur. Satisfaction is directly related to surgical expectations, and the occurrence of an allergic skin reaction in this group of patients is likely to lead to increased dissatisfaction rates.

### Clinical Message

Allergic skin reactions can occur in patients following hypoallergenic knee implants. A trial of topical corticosteroids may be considered but early peri-prosthetic infection must be excluded because this will likely worsen the infection.

### References

1. Kurtz S, Ong K, Lau E, et al. Projections of primary and revision hip and knee arthroplasty in the United States from 2005 to 2030. *J Bone Joint Surg Am* (2007); 89: 780-785.
2. Weinstein AM, Rome BN, Reichmann WM, et al. Estimating the burden of total knee replacement in the United States. *J Bone Joint Surg Am* (2013); 95: 385-392.
3. Jain NB, Higgins LD, Ozumba D, et al. Trends in epidemiology of knee arthroplasty in the United States, 1990-2000. *Arthritis and rheumatism* (2005); 52: 3928-3933.
4. Julin J, Jansen E, Puolakka T, et al. Younger age increases the risk of early prosthesis failure following primary total knee replacement for osteoarthritis. A follow-up study of 32,019 total knee replacements in the Finnish Arthroplasty Register. *Acta orthopaedica* (2010); 81: 413-419.
5. Fousereau J, Laugier P. Allergic eczemas from metallic foreign bodies. *Trans St Johns Hosp Dermatol Soc* 1966;52:220-5.
6. Hallab N, Merritt K, Jacobs JJ. Metal sensitivity in patients with orthopaedic implants. *J Bone Joint Surg Am* 2001;83:428-36.
7. Elves MW, Wilson JN, Scales JT, Kemp HB. Incidence of metal sensitivity in patients with total joint replacements. *Br Med J* 1975;4:376-8.
8. Granchi D, Cenni E, Giunti A, Baldini A. Metal hypersensitivity testing in patients undergoing joint replacement: A systematic review. *J Bone Joint Surg Br* 2012;94:1126-34.
9. Kurtz S, Ong K, Lau E, Mowat F, Halpern M. Projections of primary and revision hip and knee arthroplasty in the United States from 2005 to 2030. *J Bone Joint Surg Am* 2007;89:780-5.
10. Wittmann D, Summer B, Thomas B, Halder A, Thomas P. Gentamicin allergy as an unexpected 'hidden' cause of complications in knee arthroplasty. *Contact Dermatitis* 2018;78:293-4.
11. Bali R, Kankam HK, Agrawal A. A rare reaction to synthetic mono-filament sutures: A report of two cases. *J Perioper Pract* 2018;28:27-30.
12. Megaloikonomos PD, Mitsiokapa E, Flevas DA, Kakouratos G, Kyrou G, Koulouvaris P, et al. PMMA cement allergy misleading total knee arthroplasty infection. *J Long Term Eff Med Implants* 2017;27:13-20.
13. Willert HG, Buchhorn GH, Fayyazi A, Flury R, Windler M, Köster G, et al. Metal-on-metal bearings and hypersensitivity in patients with artificial hip joints. A clinical and histomorphological study. *J Bone Joint Surg Am* 2005;87:28-36.
14. Verma SB, Mody B, Gawkrödger DJ. Dermatitis on the knee following knee replacement: A minority of cases show contact allergy to chromate, cobalt or nickel but a causal association is unproven. *Contact Dermatitis* 2006;54:228-9.
15. Gao X, He RX, Yan SG, Wu LD. Dermatitis associated with chromium following total knee arthroplasty. *J Arthroplasty* 2011;26:665.e13-6.
16. Anand A, McGlynn F, Jiranek W. Metal hypersensitivity: Can it mimic infection? *J Arthroplasty* 2009;24:826.e25-8.
17. Parvizi J, Tan TL, Goswami K, Higuera C, Valle CD, Chen AF, et al. The 2018 definition of periprosthetic hip and knee infection: An evidence-based and validated criteria. *J Arthroplasty* 2018;33:1309-14.e2.
18. Sam N. A prospective comparison of alumina ceramic and oxinium® total knee replacement femoral components in patients with cobalt-chrome hypersensitivity. *Orthop Proc* 2008;90-B:178.

**Conflict of Interest:** Nil

**Source of Support:** Nil

**Consent:** The authors confirm that informed consent was obtained from the patient for publication of this case report

### How to Cite this Article

Mencia MM, Cawich SO. Allergic dermatitis following bilateral oxidized zirconium total knee replacements. *Journal of Orthopaedic Case Reports* 2021 February;11(2):67-70.

