

## ORIGINAL ARTICLE

# *Ehrlichia canis* rapid spread and possible enzooty in northern South Australia and distribution of its vector *Rhipicephalus linnaei*

A-L Chaber,<sup>a\*</sup> R Easther,<sup>a</sup> B Cumming,<sup>b</sup> R Irving,<sup>b,c</sup> AL Keyburn,<sup>d</sup> C Smart,<sup>b</sup> R O'Handley<sup>a</sup> and L Lignereux<sup>a</sup>

Recent concerns have arisen in Australia regarding detections of the exotic bacterium *Ehrlichia canis* which has resulted in ehrlichiosis outbreaks. In Australia, it is spread by the tropical brown dog tick *Rhipicephalus linnaei*, formerly *Rhipicephalus sanguineus* sensu lato tropical lineage. Previously, the tick has been recorded in South Australia in the Coober Pedy and the Oodnadatta areas. This study, which includes historical specimens data held in historical Australian arthropod collections, along with 10 sampled remote communities, confirms the wide distribution range of this species within the State. *E. canis* was detected by PCR in the ticks. The percentage of dogs hosting PCR-positive ticks increased from 2.8% (95% confidence interval [CI]: 0.3 to 9.7) in November–December 2020 to 62.9% (95% CI: 44.9 to 78.5) end of February 2021, initially in two then in seven Anangu Pitjantjatjara Yankunytjatjara lands communities in the far northern regions of South Australia. Our results suggest a rapid spread of the pathogen. No evidence of *E. canis* was found in nine regional communities. The extended tropical brown dog tick distribution indicates a greater area where *E. canis* may occur and may require management to minimise the impacts of ehrlichiosis outbreaks. Without the implementation of effective detection and control programs, this extended distribution of *R. linnaei* is likely to result in the spread of the bacterium to other regions.

**Keywords** Australia; *Ehrlichia canis*; ehrlichiosis; remote communities; *Rhipicephalus linnaei*; ticks

**Abbreviations** APY, Anangu Pitjantjatjara Yankunytjatjara; CI, confidence intervals; CME, canine monocytic ehrlichiosis

*Aust Vet J* 2022;100:533–538

doi: 10.1111/avj.13201

Ticks are obligatory haematophagous ectoparasites found worldwide.<sup>1</sup> Ticks belonging to the *Rhipicephalus sanguineus* complex have a global distribution. They are endophilic, meaning they reside in homes, dog kennels, and domestic animals' vicinity.<sup>2</sup> They tend to prefer low-density housing with access to

gardens or open areas rather than high-density urban areas.<sup>3</sup> Although commonly found inside houses, they can be observed outside, crawling on walls and between rocks.<sup>3</sup> They are monotropic, three-host tick species, with the domestic dog, *Canis lupus familiaris*, being the main host. However, they have been reported feeding on other mammal species including humans.<sup>4</sup>

Formerly referred to as the *R. sanguineus* tropical lineage, *Rhipicephalus linnaei* has been a distinct taxonomic entity since 2021.<sup>5</sup> It is the only species belonging to this group reported in Australia. This tick prefers tropical and semi-arid habitats, but it was found in many different climates, including temperate parts of New South Wales, arid areas of the Northern Territory and Western Australia, and tropical Queensland.<sup>6</sup> Houses and kennels protect the tick against extreme environmental conditions, and *R. linnaei* is likely to withstand a larger variety of environments.<sup>4,7</sup>

A 1965 Australian distribution map<sup>7</sup> showed the enzootic presence of the tick throughout the northern regions of Western Australia, the majority of the Northern Territory and Queensland, and the very northeastern tip of New South Wales. In 2020, this range was expanded to include the entire western coast of Western Australia and an increased range of northern inland New South Wales.<sup>6</sup> The southward spread is thought to be facilitated by increases in the average number of warmer days and by human-assisted movements, allowing further migration of brown dog ticks to new areas which were previously inhospitable.<sup>6,7</sup> *R. linnaei* has been recorded in Oodnadatta and Coober Pedy<sup>8</sup> but otherwise published records of the tick in South Australia are limited.<sup>4,9</sup>

The tick is a vector for *Ehrlichia canis*, a Gram-negative obligatory intracellular bacterium of the order Rickettsiales, first described in 1935<sup>10</sup> and which has emerged in Australia very recently.<sup>11</sup> The dog constitutes the reservoir for this pathogen, which parasitises circulating monocytes causing a syndrome called canine monocytic ehrlichiosis (CME).<sup>1</sup> The bacterium circulates in macrophages and replicates mainly in the liver and spleen. Incubation in the dog is 8–20 days.<sup>12</sup> It may be followed by an acute disease presenting with various clinical signs, but certain cases may remain asymptomatic.<sup>1,13</sup> The clinical signs during the acute phase include petechiae, ecchymoses, splenomegaly, epistaxis and lymphadenomegaly.<sup>1,12</sup> They are caused by autoimmune pancytopenia and lead to pale mucous membranes, peripheral oedema, lethargy, depression, anorexia and tachypnoea.<sup>1,10</sup> Other associated clinical signs include pyrexia, oculonasal discharge, vomiting and weight loss.<sup>1,10</sup> Rarely, neurological signs such as cranial nerve dysfunction, seizures, ataxia and paresis will occur if the

\*Corresponding author.

<sup>a</sup>School of Animal and Veterinary Sciences, Roseworthy Campus, The University of Adelaide, Adelaide, South Australia, Australia; [anne-lise.chaber@adelaide.edu.au](mailto:anne-lise.chaber@adelaide.edu.au)

<sup>b</sup>Animal Management in Rural and Remote Indigenous Communities (AMRRIC), 4/41 Sadgroves Crescent, Winnellie, Larrakia Country, Northern Territory, 0820, Australia

<sup>c</sup>Adelaide Northern Veterinary Group, 854 North East Road, Modbury, South Australia, 5092, Australia

<sup>d</sup>Bioassay Research and Development Team, Commonwealth Scientific and Industrial Research Organisation, Australian Centre for Disease Preparedness, Private Bag 24, Geelong, Victoria, 3220, Australia

A-L Chaber and R Easther contributed equally to this manuscript.

bacterium enters the cerebrospinal fluid.<sup>1</sup> Subclinical and chronic forms might then follow, lasting for months or years. The chronic phase is invariably terminal.<sup>10</sup> Death may occur due to haemorrhage and secondary infection<sup>1</sup> before the chronic phase. A daily oral administration of doxycycline at 10 mg/kg for one month is the usual recommended antibiotic treatment for acute CME, although treatment instituted after the acute phase may be ineffective.<sup>14</sup>

The three-host lifecycle of *R. linnaei* requires the larval, nymphal and adult stages each to ingest blood from different dogs, and each stage is susceptible to *E. canis* infection. This provides the tick with opportunities to both become infected when feeding on infected dogs, and to transmit the bacterium to multiple susceptible dogs.<sup>13</sup> In the absence of transovarian transmission, only nymphs and adult ticks transmit the bacterium. The adult ticks, especially males, can have more than one blood meal on multiple different hosts, further increasing the number of dogs that can be infected.<sup>10</sup> Adult ticks can transmit *E. canis* up to 155 days after becoming infected, allowing survival of the bacterium for extended periods while the tick is less active.<sup>10</sup> Dogs can remain infectious with recurring bouts of ehrlichiosis long after the initial phases of infection, which aids the maintenance of *E. canis* in the tick population.<sup>10</sup>

Ehrlichiosis is a notifiable disease in dogs in Australia. Until 2020, it was considered an exotic disease but it has since been reported in the towns of Halls Creek and Kununurra in the Kimberley region of Western Australia in May 2020.<sup>15</sup> In June 2020 it was diagnosed in

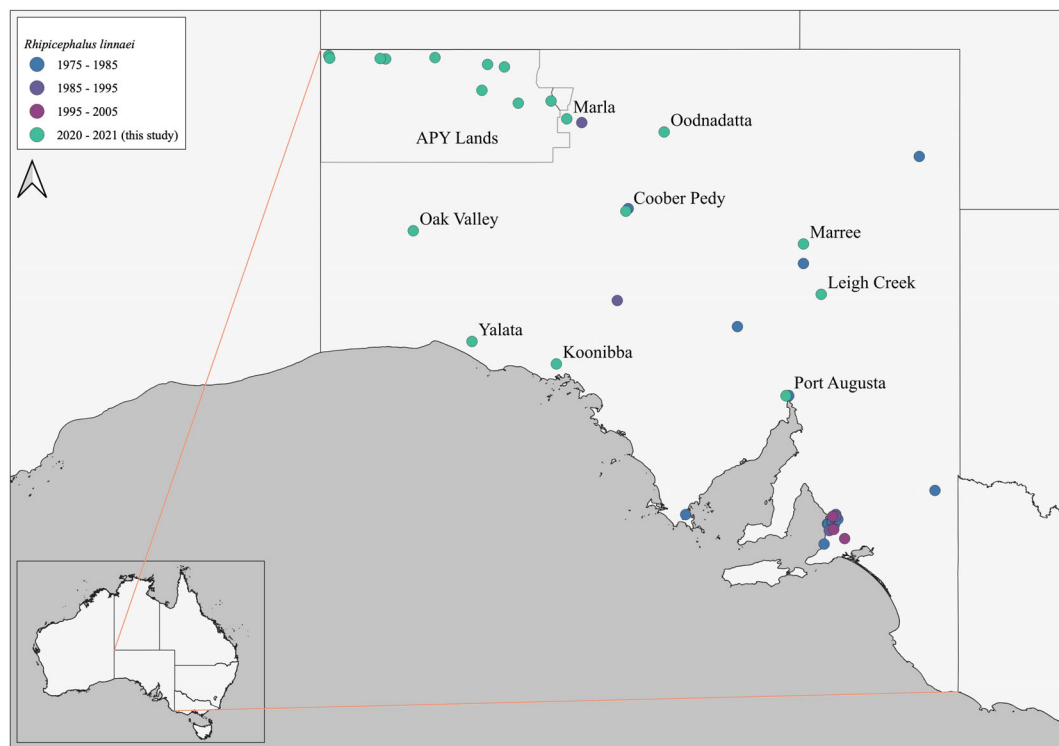
the town of Katherine and near Alice Springs in the Northern Territory,<sup>16</sup> in the far northern regions of South Australia in March 2021,<sup>17</sup> and then in the town of Mount Isa in northwest Queensland in January 2022.<sup>18</sup>

In Australia, in addition to *E. canis*, *R. linnaei* is capable of transmitting other pathogens to dogs, such as *Anaplasma platys* and *Babesia canis vogeli*,<sup>19</sup> both causing syndromes mimicking CME.

## Materials and methods

The tick sampling happened in three campaigns during dog desexing and preventative health initiatives. The domestic dogs that were owned in 10 remote Indigenous and nine regional communities in South Australia (see Figure 1) were screened for ticks. The screening consisted of manually checking the coat and ears of the dogs for evidence of attached adult ticks. The ticks were removed and placed in small plastic vials filled with 70% ethanol and kept at ambient temperature.

The first campaign happened in August 2020 in seven regional communities (Coober Pedy, Koonibba, Marla, Port Augusta, Oak Valley, Oodnadatta and Yalata), and the second campaign was done in October and November 2020 in two regional communities (Leigh Creek and Maree) and nine Anangu Pitjantjatjara Yankunytjatjara (APY) lands communities. The third and last campaign happened




**Figure 1.** Distribution of the tick *Rhipicephalus linnaei* in South Australia. The name of the regional communities where the specimens have been collected during this study is indicated. A polygon represents the Anangu Pitjantjatjara Yankunytjatjara (APY) Lands. The date of collection and location of the historical specimens are mentioned. Map made with QGIS 3.24 (QGIS Development Team, 2021 QGIS Geographic Information System. Open-Source Geospatial Foundation Project, <http://www.qgis.org>), with free data sets for country boundaries and land borders from 'Natural Earth'. Source: <http://www.naturalearthdata.com/>.

during the last week of February 2021 in 10 APY lands communities, including the nine communities already sampled.

At the University of Adelaide, the ticks from the first two campaigns were identified under a dissecting microscope according to the morphological criteria (Figure 2) outlined by Roberts<sup>7</sup> and Barker and Walker.<sup>4</sup>

Ticks from the three campaigns were sent to the Commonwealth Scientific and Industrial Research Organisation (Australian Centre for Disease Preparedness, Victoria) where they were screened for *E. canis* by PCR. One tick per dog from the first and the second campaigns was tested, but whenever a tick elicited a positive reaction, the test was repeated on the other ticks found on the same dog. During the third campaign, the ticks collected from three dogs were pooled



**Figure 2.** Unengorged adult female tropical brown dog tick *Rhipicephalus linnaei* and morphological features. (A) Dorsal view of the whole specimen. The eyes are indicated. (B) Ventral view of the same specimen. Note the hexagonal shape of the basis capituli, the bifid coxae 1 (ovals), and the anal groove posterior to the anus (arc). (C) Detail of the basis capituli and coxae 1, (D) detail of the anal area and adanal plates. The size for each bar is mentioned. Photographs taken with reversed Componon 28 mm enlarger lens (Schneider Kreuznach, Germany) and Nikon 4×/0.1 E Plan infinity-corrected microscope objective (Japan), mounted on Nikon D7200 DSLR. Assembled using focus stacking technique in Zerene stacker (Zerene Systems, Richland, WA, USA). Edited in GIMP 2.10 (the GIMP Development Team <http://gimp.org>).



in the specimen vials, and the PCR was done on one tick from each vial.

The *E. canis* PCR was performed as follows: the DNA was extracted for testing by placing a tick in a 2 mL bead beating tube (FastPrep-24, MP Biomedicals, Santa Ana, CA, USA) containing 180 µL ATL lysis buffer (Qiagen, Germany) and two stainless steel 5 mm beads (Qiagen, Germany). The tick was homogenised at 6 m/s for 1 min, and the tubes were then spun at 12,000 rcf (relative centrifugal force) for 1 min, adding 20 µL of proteinase K, before being incubated at 56°C for at least 3 h. The homogenate was spun at 12,000 rcf for 1 min to pellet debris, the supernatant was carefully poured into a new 1.5 mL tube. Equal volumes (200 µL) of AL lysis buffer (Qiagen, Germany) and 100% ethanol was added, the tubes were vortexed and the supernatant was transferred to a spin column before continuing with the standard Qiagen protocol (DNeasy Blood & Tissue Kit, Qiagen, Germany). The resultant DNA was used in an *E. canis* specific probe-based qPCR assay as described by Baneth et al.<sup>20</sup>

Historical tick collections were accessed through the Atlas of Living Australia (<https://www.ala.org.au>),<sup>21</sup> the Online Zoological Collections of Australian Museums (<https://ozcam.org.au/>), and the Australian National Insect Collection (<https://data.csiro.au/collection/csiro:4641>). Both queries '*Rhipicephalus linnaei*' and '*Rhipicephalus sanguineus*' were entered. After downloading the records, the data were cleaned in Excel (Microsoft, Redmond, WA, USA) and only the data regarding the specimens collected in South Australia were retained.

The statistical difference between groups was evaluated with a Chi-squared test. Differences were considered significant with P value <0.05. 95% confidence intervals (95% CI) were calculated with the binomial method.

Voucher specimens of *R. linnaei* collected during this study were deposited at the South Australian Museum (Catalogue numbers J 25503–J 25507).

## Results

A total of 153 ticks were collected during the first two campaigns from all sampling sites: nine regional communities and ten APY lands communities (see Figure 1). They were all *R. linnaei*.

Among the 23 ticks collected on 23 dogs in the nine different regional communities during the first and second campaigns, none (0%) elicited a positive *E. canis*-PCR result (see Table 1).

In the ten APY lands communities sampled during the second campaign, 82 ticks were collected on 72 dogs. Seventy ticks from 70 dogs in seven communities elicited a negative PCR reaction, but ten ticks collected on one dog and two ticks collected on another dog in a different community were *E. canis* PCR-positive.

From the 35 ticks collected on 35 dogs out of the 95 dogs handled during the third campaign in February 2021, 22 were PCR-positive. No evidence of *E. canis* was found in three communities among the 10 communities sampled, but only one or two ticks were tested in each of those three communities.

The percentage of dogs hosting PCR-positive ticks in the APY lands was 2.8% (95% CI: 0.3 to 9.7) and 62.9% (95% CI: 44.9 to 78.5) during the second and the third campaigns, respectively. This difference was significant  $X^2(1, n = 107) = 45.47, P < 0.0001$ .

Different online resources led to the same list of specimens collected in South Australia. These specimens are part of the South Australian Museum Arachnology collection, held at the South Australian

**Table 1.** Number of dogs with ticks and number of dogs with ticks PCR-positive to *Ehrlichia canis*

Locations	Number of dogs with <i>E. canis</i> -positive ticks/number of dogs with ticks		
	August 2020	October–November 2021	February 2021
Regional communities			
Yalata	0/4		
Oak Valley	0/1		
Koonibba	0/1		
Oodnadatta <sup>a</sup>	0/9		
Marla	0/1		
Cooper Pedy <sup>a</sup>	0/1		
Maree		0/3	
Leigh Creek		0/1	
Port Augusta	0/2		
Remote Aboriginal communities			
APY lands		2/72	22/35
Total	0/19	2/76	22/35

<sup>a</sup> *Rhipicephalus linnaei* has been previously recorded at these locations. All ticks identified were *R. linnaei*. APY, Anangu Pitjantjatjara Yankunytjatjara.

Museum. The query '*Rhipicephalus linnaei*' did not return any result, but the query '*Rhipicephalus sanguineus*' provided the records for 114 historical specimens collected in South Australia. They were downloaded. Their collection date was kindly provided by the terrestrial invertebrates' collection manager at the South Australian Museum and ranged from 1975 to 2005. Geospatial information, with accuracy down to the suburb, the livestock station or the country town level was indicated for 108 specimens. Two specimens were collected from 'the Adelaide suburbs'. The location of four specimens was lacking. A total of 54 specimens were collected in metropolitan Adelaide by at least 14 different persons between 1975 and 1997. The other 54 specimens were collected from different rural areas across the state between 1976 and 2005 (see Figure 1).

### Discussion

*R. linnaei* was found in all sampled locations in the state, nine of which (eight regional communities and the APY lands) were not previously recorded. This result indicates that *R. linnaei* is more extensively distributed in South Australia than previously published. It also suggests the enzooty of this tick in South Australian regional and Aboriginal communities. It was the only tick species identified.

This might only be a re-discovery as *R. linnaei* has indeed been collected across the state and voucher specimens were deposited in arachnid historical collections since the 1970s. This finding emphasises the importance of such collections and calls for updated vectors' surveys.

This study does not constitute a formal survey. It is difficult to measure more accurately both the tick and the *E. canis* prevalences based on our data. Nevertheless, no evidence of *E. canis* was found in the regional communities in 2020. The situation was different in the APY lands communities, with more communities being affected over time, going from two communities affected out of nine, to seven communities affected out of 10. The prevalence of dogs hosting *E. canis*-positive ticks rose from 2.8% in October 2020 to 62.9% in February 2021. Our results suggest an important *E. canis* incidence increase in owned dogs within this four-month period. This finding is not in agreement with an already established enzooty but it is in favour of the rapid spread of the bacterium. Both hypotheses were already suggested in an Australian *E. canis* phylogenetic study<sup>11</sup> without a clear conclusion. In the light of these findings and in the context of the emergence of this pathogen in Halls Creek, less than 9 months before our study and over 900 km away, we recommend an epidemiological enquiry to investigate both the movements of dogs within communities and the chains of transmission.

Our observation indicates that *E. canis* was limited in South Australia to the APY lands, but its apparent rapid spread, associated with the distribution of the vector across the state suggests that the CME might become enzootic throughout South Australia. This is a concern for canine health. Factors influencing the reservoir for *E. canis*, such as the possibility for dogs to roam free, or to move between locations, and factors influencing the vector such as the sub-optimal ectoparasite control, in particular *R. linnaei*, on dogs and in the environment, as well as favourable climatic conditions, are all likely to amplify the spread of the pathogen. Those factors are

present in remote Aboriginal communities where dogs are valued companions, and they often serve important cultural and/or spiritual roles.

Unfortunately, the animal welfare authorities and veterinary services are scarce and infrequent in those communities which prevent rapid response to both acute and chronic cases of CME. As such, a high proportion of dogs that develop ehrlichiosis in remote communities are likely to go untreated. Due to the recent introduction of *E. canis* in the country, dog populations are likely still naïve to this infection, and an important negative impact on dogs' health and welfare as well as on their owners' welfare can therefore be forecast.

Furthermore, the current funding deficits prohibit the implementation of efficient anti-parasitic programs in dogs and the control of environmental infestations. A repellent acaricide as well as a systemic acaricide is recommended in order to prevent *Ehrlichia* transmission, which may occur within hours of an initial tick bite.<sup>22,23</sup> A systemic acaricide will assist in environmental tick control and reduce the risk of infected ticks remaining in the environment.

The role other canids present in Australia, such as dingoes (*Canis lupus dingo*) and foxes (*Vulpes vulpes*) might play as *E. canis* reservoir is not well documented nor understood, and requires scientific investigation. The detection of *E. canis* calls for more vigilance and screening of dogs with suggestive clinical signs, especially in remote areas. Ehrlichiosis should be included in the differential diagnosis whenever compatible clinical signs are observed in dogs in, or from, South Australia. Whenever confirmed, the disease should be notified. Lastly, relevant information should be provided to pet dog owners visiting those areas.

### Conclusion

The triad relationship '*canid* – *R. linnaei* – *E. canis*' is central in managing ehrlichiosis in Australia. More research is needed to understand this disease and its impacts in Australia, including *R. linnaei* surveys and further *E. canis* prevalence studies in areas where *R. linnaei* is enzootic, both in domestic dogs and dingoes, within a 'One-Health' framework.

Improved resources for remote community animal health programs are essential.

### Acknowledgments

We would like to acknowledge the traditional owners of the lands where this study took place, and in particular acknowledge the community residents and their dogs in the Anangu Pitjantjatjara Yankunytjatjara (APY) Lands, Koonibba community, Oak Valley community and Yalata community. We would also like to thank all veterinarians and staff involved in tick collection, in particular Dr Allison Crawley, Dr Kate Litchfield, Dr Roger Absalom and Dr Nat Wakeham. Furthermore, the authors sincerely appreciate and thank Yalata Anangu Aboriginal Corporation (YAAC), Tullawon Health Services (THS), Anangu Pitjantjatjara Yankunytjatjara and Nganampa Health Council for assistance from and permission to visit the communities involved. Open access publishing facilitated by

The University of Adelaide, as part of the Wiley - The University of Adelaide agreement via the Council of Australian University Librarians.

#### Conflicts of interest and sources of funding

The authors declare no conflicts of interest or sources of funding for the work presented here.

#### References

1. Taylor MA. *Veterinary parasitology*. 4th edition. Chichester, Wiley Blackwell, 2016.
2. Dantas-Torres F. The brown dog tick, *Rhipicephalus sanguineus* (Latreille, 1806) (Acari: Ixodidae): from taxonomy to control. *Vet Parasitol* 2008;152:173–185.
3. Dantas-Torres F. Biology and ecology of the brown dog tick, *Rhipicephalus sanguineus*. *Parasit Vectors* 2010;3:26.
4. Barker SC, Walker AR. *Ticks of Australia. The species that infest domestic animals and humans*. 1st edition. Auckland, Zootaxa, 2014.
5. Šlapeta J, Chandra S, Halliday B. The “tropical lineage” of the brown dog tick *Rhipicephalus sanguineus* sensu lato identified as *Rhipicephalus linnæi* (Audouin, 1826). *Int J Parasitol* 2021;51:431–436.
6. Chandra S, Ma GC, Burleigh A et al. The brown dog tick *Rhipicephalus sanguineus* sensu Roberts, 1965 across Australia: morphological and molecular identification of *R. sanguineus* s.l. tropical lineage. *Ticks Tick Borne Dis* 2020;11:101305.
7. Roberts FHS. The taxonomic status of the species of the genera *Rhipicephalus* Koch and *Boophilus* Curtice (Acarina: Ixodidae) occurring in Australia. *Aust J Zool* 1965;13:491–524.
8. Greay T. An investigation of *Coxiella burnetii* and *Coxiella*-like bacteria in the brown dog tick (*Rhipicephalus sanguineus*). 2014. Available at: <https://researchrepository.murdoch.edu.au/id/eprint/25301>. Accessed 22 May 2022.
9. Greay TL, Oskam CL, Gofton AW et al. A survey of ticks (Acari: Ixodidae) of companion animals in Australia. *Parasit Vectors* 2016;9:207.
10. Donatien A, Lestoquard F. Existence en Algérie d'une Rickettsia du chien. *Bull Soc Pathol Exot* 1935;28:418–419.
11. Neave MJ, Mileto P, Joseph A et al. Comparative genomic analysis of the first *Ehrlichia canis* detections in Australia. *Ticks Tick Borne Dis* 2022;13:101909.
12. Mylonakis ME, Theodorou KN. Canine monocytic ehrlichiosis: an update on diagnosis and treatment. *Acta Vet Brno* 2017;67:299–317.
13. Stich RW, Schaefer JJ, Bremer WG et al. Host surveys, ixodid tick biology and transmission scenarios as related to the tick-borne pathogen, *Ehrlichia canis*. *Vet Parasitol* 2008;158:256–273.
14. Sainz Á, Roura X, Miró G et al. Guideline for veterinary practitioners on canine ehrlichiosis and anaplasmosis in Europe. *Parasit Vectors* 2015;8:75.
15. Fowler C. Exotic tick-borne disease detected in dogs for the first time in Australia. *ABC News*, 2020. Available at: <https://www.abc.net.au/news/2020-06-03/ehrlichiosis-detected-in-kimberley-dogs/12313052>. Accessed 19 May 2022.
16. Daly J. Northern Territory vets suspect tropical dog disease has gone undetected “for years”. *ABC News*, 2020. Available at: <https://www.abc.net.au/news/rural/2020-06-25/ehrlichiosis-undetected-nt-vets-suspect-new-dog-disease/12388500>. Accessed 19 May 2022.
17. Ehrlichiosis in dogs. Available at: <https://www.outbreak.gov.au/current-responses-to-outbreaks/ehrlichiosis-dogs>. Accessed 17 May 2022.
18. Margolis Z. Deadly dog disease spreads to north-west Queensland putting pet owners on alert. *ABC News*, 2022. Available at: <https://www.abc.net.au/news/2022-02-01/tick-borne-disease-ehrlichiosis-arrives-in-mount-isa-queensland/100787066>. Accessed 17 May 2022.
19. Brown G, Canfield P, Dunstant R et al. Detection of *Anaplasma platys* and *Babesia canis vogeli* and their impact on platelet numbers in free-roaming dogs associated with remote Aboriginal communities in Australia. *Aust Vet J* 2006;84:321–325.
20. Baneth G, Harrus S, Ohnona FS et al. Longitudinal quantification of *Ehrlichia canis* in experimental infection with comparison to natural infection. *Vet Microbiol* 2009;136:321–325.
21. Atlas of Living Australia. Available at: [https://biocache.ala.org.au/occurrences/search?q=taxa%3A%22Rhipicephalus%20\(Rhipicephalus\)%20sanguineus%22&qualityProfile=ALA](https://biocache.ala.org.au/occurrences/search?q=taxa%3A%22Rhipicephalus%20(Rhipicephalus)%20sanguineus%22&qualityProfile=ALA). Accessed 19 May 2022.
22. Stanneck D, Fourie JJ. Imidacloprid 10%/Flumethrin 4.5% collars (Seresto®, Bayer) successfully prevent long-term transmission of *Ehrlichia canis* by infected *Rhipicephalus sanguineus* ticks to dogs. *Parasitol Res* 2013;112:21–32.
23. Jongejan F, Crafford D, Erasmus H et al. Comparative efficacy of oral administered afoxolaner (NexGard™) and fluralaner (Bravecto™) with topically applied permethrin/imidacloprid (Advantix®) against transmission of *Ehrlichia canis* by infected *Rhipicephalus sanguineus* ticks to dogs. *Parasit Vectors* 2016;9:348.

(Accepted for publication 31 July 2022)