



# Rotator cable and rotator interval: anatomy, biomechanics and clinical importance

Gazi Huri<sup>1</sup>

Mehmet Kaymakoglu<sup>1</sup>

Nickolas Garbis<sup>2</sup>

- The rotator cable and rotator interval are among the most recent topics of interest in current shoulder literature. Most of the research has been published in the last two decades and our understanding about the importance of these anatomical structures has improved with biomechanical studies, which changed the pre- and intra-operative approaches of shoulder surgeons to rotator cuff tears in symptomatic patients.
- The rotator cable is a thick fibrous bundle that carries the applied forces to the rotator cuff like a ‘suspension bridge’. Tears including this weight-bearing bridge result in more symptoms. On the other hand, the rotator interval is more like a protective cover consisting of multiple layers of ligaments and the capsule rather than a single anatomical formation like the rotator cable.
- Advances in our knowledge about the rotator interval demonstrate that even basic anatomical structures often have greater importance than we may have understood. Misdiagnosis of these two important structures may lead to persistent symptoms.
- Furthermore, some distinct rotator cuff tear patterns can be associated with concomitant rotator interval injuries because of the anatomical proximity of these two anatomical regions. We summarize these two important structures from the aspect of anatomy, biomechanics, radiology and clinical importance in a review of the literature.

**Keywords:** rotator cable; rotator interval; rotator cuff; review; ligamentum semicirculare humeri

Cite this article: *EFORT Open Rev* 2019;4:56-62.

DOI: 10.1302/2058-5241.4.170071

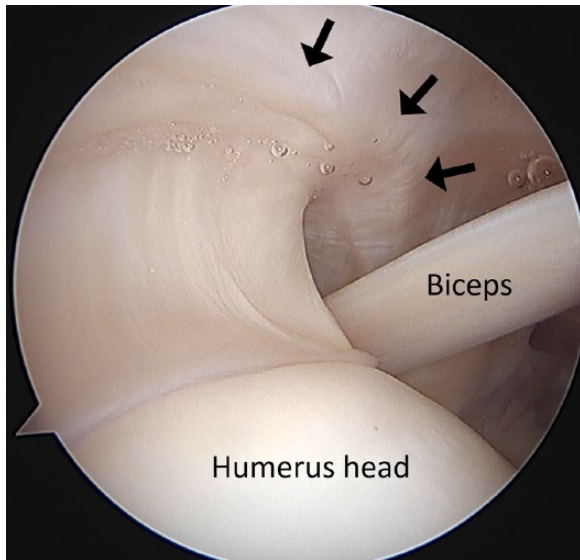
## Introduction

Rotator cuff problems are a common cause of shoulder pain and represent a significant expense and burden on the healthcare system. Despite the high rate of radiological

prevalence of rotator cuff tears in elderly patients, many patients continue their lives with minimal symptoms. Several studies investigated asymptomatic shoulders in the general population and found that rotator cuff tears are relatively common, in the range of 6% to 34% in all age groups.<sup>1,2</sup> A recent study by Yamamoto et al reported that nearly 20% of the general population have rotator cuff tears, with an increasing prevalence in elderly patients. They found that 50% of patients who are in their 80s have rotator cuff tears regardless of whether they are symptomatic or asymptomatic. Even patients without any shoulder symptoms accounted for 13.5% of the rotator cuff tears in the general population.<sup>3</sup> Understanding the contribution of the rotator cable (RC) or rotator interval (RI) could be the answer to those.

In his first publication about supraspinatus tears in 1934, Codman presented two cases of surgical repair and defined an avascular crescentic area at the insertion site of the supra and infraspinatus.<sup>4</sup> He identified this insertion site in rotator cuff tear patients. Nearly 60 years later, Clark and Harryman published a detailed anatomical study of the rotator cuff and described a fibrous tissue which originates from the deep layer of coracohumeral ligament and moves along the perpendicular axis of supraspinatus and infraspinatus tendon fibres.<sup>5</sup> Later, Burkhart et al named this anatomical structure the ‘rotator cable’ and described the biomechanical role of this ligament as a stress shield of the rotator crescent, which is an avascular crescentic area at the insertion site of the supra and infraspinatus.<sup>6</sup> They compared the RC to a ‘suspension bridge’ that works to keep load stress out of the rotator crescent, which tends to be more vulnerable to tears. More studies of the gross anatomic and arthroscopic appearance of the RC were published after the abovementioned publications.<sup>7,8</sup>

The RI is more like a protective cover consisting of multiple layers of ligaments and the capsule rather than a single anatomical formation like the RC. This close relationship with the joint capsule and nearby anatomical structures, such as the long head of biceps tendon and coracohumeral



**Fig. 1** Arthroscopic view of the rotator cable (black arrows) (courtesy of Nickolas Garbis).

ligament, etc., increases its importance. Ignoring the RI causes many misdiagnoses in clinical routine and can explain some 'refractory' shoulder pains. The RI's role in biceps tendinopathy, SLAP lesions and glenohumeral instability has been recently popularized in shoulder literature.<sup>9</sup>

The aim of this paper is to recall the importance of the RC and RI and summarize their anatomical, biomechanical and radiological features. Awareness of these important structures should be raised among shoulder surgeons in the interest of proper diagnosis and treatment of shoulder pathologies.

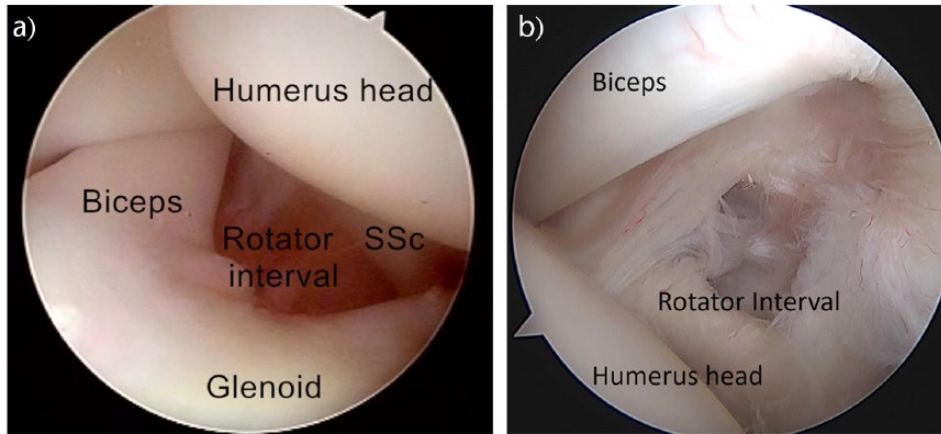
## Anatomy and function

Understanding the anatomy of the rotator cuff is essential for a shoulder surgeon in order to apply the appropriate surgical repair. Recent research has helped to advance our understanding of the complexity of the shoulder anatomy. The coracohumeral ligament (CHL) arises from the lateral side of the coracoid process and orientates obliquely to the humeral head. It divides into two layers (superficial and deep), surrounds the rotator cuff and inserts into lesser and greater tuberosities. The superficial layer of the CHL covers the articular surface of the supraspinatus and infraspinatus tendons. The deeper part of the CHL is thicker and inserts into the greater tuberosity. Here, the deep layer forms a crescent-shaped structure, running posteriorly from the anterior insertion site of the supraspinatus to the inferior border of the infraspinatus, perpendicular to the axis of tendon fibres (Fig. 1). Kolts et al contributed to the anatomy literature and named this

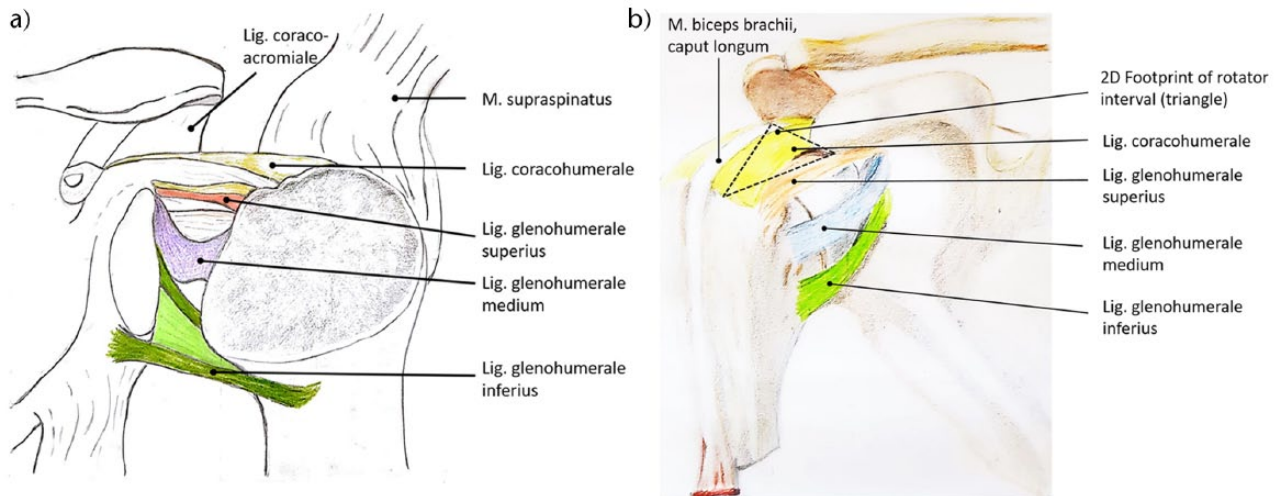
structure the *ligamentum semicirculare humeri*.<sup>10</sup> This arch showed variable thickness in ultrasonographic and cadaveric studies.<sup>11</sup> It is approximately 2.59 times thicker than the rotator crescent. Burkhart et al found that younger cadaveric specimens have a thicker rotator crescent compared to the cable. They proposed that two categories can be defined.<sup>6</sup> One of these categories is *cable-dominant*, which is seen in older specimens, and the other is *crescent-dominant*. Their data suggested that as a person gets older, his/her RC becomes thicker and the rotator crescent thinner. Therefore, it can be said that the cable/crescent ratio is bigger in older shoulders and the crescent area becomes thinner. This implies that the integrity of the superior rotator cuff is more dependent on RC integrity in older patients. Despite these findings, some researchers found that the RC is more detectable with ultrasound (US) in younger patients.<sup>10,12</sup>

Understanding which muscles are suspended by the RC is crucial to making a proper diagnosis and surgical repair. The supraspinatus tendon has two parts: a superficial part which reaches more anteriorly and attaches to the lesser tuberosity, whereas the deeper and major part fuses into the RC in conjunction with the CHL. The anterior insertion area of the RC mainly consists of supraspinatus tendon fibres. The posterior insertion area is shared by the supraspinatus, infraspinatus and partly the teres minor tendons.<sup>9</sup>

In addition to rotator cuff insertion, there has been some recent interest in studying the anatomy and function of the RI. The RI was presumed to be a semi-functional and relatively empty area in the rotator cuff. There are two different RIs in shoulder anatomy: the anterior and posterior RIs.<sup>13</sup> Here, we will discuss only the anterior RI. In 2002, Kolts et al identified the borders of the RI in a cadaver study on 19 shoulder joints.<sup>7</sup> It is described as a triangular-shaped space instead of a two-dimensional 'area', whose borders are drawn superiorly by the supraspinatus, inferiorly by the subscapularis tendon and by the joint capsule as a ceiling. The floor of this space is the articular surface of the humeral head (Fig. 2). It is strengthened by the CHL laterally and by the superior glenohumeral ligament (SGHL) medially (Fig. 3a).<sup>14</sup> The long head of the biceps tendon lies on the base of the RI space and is covered by a fibrous sheet of capsule.<sup>15</sup> The coracoid process constitutes the medial edge of this triangular space (Fig. 3b). Microscopically, the RI consists of four layers, as described by Jost et al.<sup>16</sup> The first layer consists of superficial CHL fibres which originate from the coracoid process and insert into the greater and lesser tuberosities following the supraspinatus and subscapularis tendons, respectively. The second layer is a blend of the CHL and rotator cuff tendons. The third layer consists of deep CHL fibres and the fourth layer is a mesh of the SGHL and capsule.<sup>17</sup> Another important structure in the RI is the coracoglenoid



**Fig. 2** a) Arthroscopic view of the rotator interval (courtesy of Gazi Huri). b) Arthroscopic view of the rotator interval (courtesy of Nickolas Garbis).



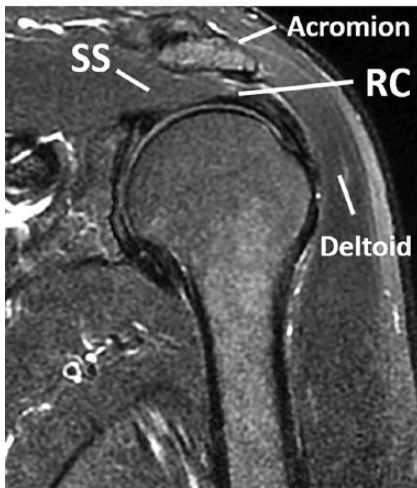
**Fig. 3** a) Important ligamentous structures around the glenohumeral joint. b) Schematic drawing of anatomic location of the rotator interval.

ligament (CGL) which forms the anterosuperior ligament complex with the CHL and SGHL. It runs from the coracoid process to the supraglenoid tubercle, extra-articularly. Its function is still not fully understood, but a few studies suggest the contribution of stability to the shoulder.<sup>18</sup>

Wilson et al described how the capsular anatomy in the RI can be variable. They stated that most of the patients (59%) have a RI capsular opening (RICO) that is superolateral to the middle glenohumeral ligament (MGHL).<sup>19</sup> A shoulder surgeon should also be aware of how close the RI and anterior portion of the RC (or supraspinatus tendon) are. This variability and proximity can give us a clue about why the RI and its associated structures (ligaments and biceps tendon, etc.) are involved in some cuff tears.<sup>20</sup>

### Radiological manifestation

The RC and RI structures are not visible on plain radiographs. MRI or US is widely used in the screening of these anatomical structures. The RC can be observed in routine shoulder MRI screening in patients with rotator cuff symptoms in all planes. Some authors state that the abduction, external rotation (ABER) is the best position for viewing the rotator cuff and cable pathologies. This is attributed to the decreased tension of ruptured rotator cuff fibres and avoidance of adherence to adjacent intact cuff tissue.<sup>21</sup> However, evaluation of this imaging technique requires experience and can be complicated for some radiologists and orthopaedic surgeons. A routine oblique coronal plane MRI often offers a good view of the RC (Fig. 4). On

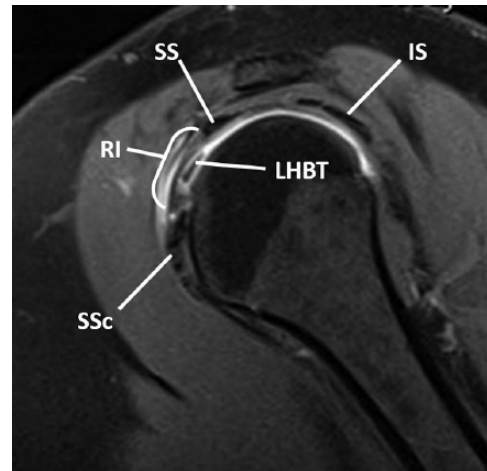


**Fig. 4** MRI, coronal section, T2-weighted image of rotator cable. SS, supraspinatus; RC, rotator cable.

the fat-suppressed T2 view, the RC can be visualized as a hypo-intense region 2 mm to 5 mm wide on the articular side of the supraspinatus tendon. Even in the best-case scenario, visualization of the RC is limited up to nearly 75% in asymptomatic patients on MRI due to its small diameter and the difficulty in distinguishing it in *crescent-dominant* younger patients.<sup>6,22</sup> In addition, it is hard to distinguish the RC from a small anterior supraspinatus tear. Using axial images may help identify the RC for the clinician. On the axial plane, hypo-intensity of the RC runs from the greater tuberosity to its posterior attachment next to the infraspinatus tendon, the same as its anatomical shape. Coronal and axial images provide sufficient visibility in most cases, whereas ABER and sagittal planes may also be used to confirm the previous commonly used planes.<sup>23</sup>

Ultrasound is another screening technique used to assess the RC. Some studies report improved identification of RI structures compared to MRI screening, in the range of 77% to 99%.<sup>24,25</sup> Sconfienza et al reported more frequent detection of the RC in elderly patients. This finding is consistent with the findings by Burkhart, in which elderly patients have *cable-dominant* anatomy. Another explanation for this relationship is the concomitant sub-clinical tendinosis in elderly patients, which makes the cable more visible.<sup>26</sup>

Because the RI is an intra-articular structure, it can only be seen on MRI if synovial fluid is prominent (Fig. 5).<sup>27</sup> For this reason, a MR arthrogram is suggested in the presence of any injury of RI structures. The oblique sagittal MRI plane is the most useful sequence in evaluating the RI. On the sagittal plane, the RI capsule lies over the biceps pulley as a hypo-intense band. More medially, the CHL is visualized running from the coracoid process to the humeral



**Fig. 5** MRI, coronal section, T2-weighted image of the rotator interval. SS, supraspinatus tendon; IS, infraspinatus tendon; LHBT, long head of the biceps tendon; RI, rotator interval.

head covering the long head of biceps tendon. Conversely, the SGHL is harder to visualize than the other structures of the RI. In an MRI study by Chung et al, the SGHL is not seen at all in all routine MRI views, and the CHL is observed only in 60% of cases.<sup>28</sup> The CGL can also be observed by experienced radiologists as a part of the anterosuperior capsuloligamentous complex.<sup>29</sup>

Tamborrini et al reported that musculoskeletal US is another superior technique used to visualize the RI. Many pathologies of the anatomic structures within the RI (including tendinosis, tears and capsulitis) can be imaged using US with a better resolution than any other techniques. The only limiting factor is the decreased visualization while observing the soft tissue beneath any bony structure such as the acromion.<sup>30</sup> Also, US is dependent on the ability of radiologists' diagnostic experience; decisions on appropriate imaging techniques should be made taking this into consideration.

### Biomechanical and clinical importance of the rotator cable and rotator interval

The relationship of cuff tear type and size with patients' clinical presentation has been discussed for a long time. Early studies suggested a correlation between the tear size and symptomatic disease with decreased muscle strength, pre- and post-operatively;<sup>30</sup> however, some researchers contradicted this idea, stating that post-operative outcomes and tear size have no relationship.<sup>17</sup> After the RC concept was introduced, there have been studies specifically evaluating the biomechanics. In 2013, Mesiha et al published the biomechanical properties of the RC in a cadaveric shoulder model.<sup>31</sup> They compared crescent- and cable-involving tears and proved that the cable-involved

tears which are located at the anterior insertion site of the supraspinatus tendon are more relevant with bigger tear size, reduced tendon stiffness and increased tendon stress. These findings may explain increased fatty degeneration in anterior supraspinatus tendon ruptures and give us a clue about why some rotator cuff tears are more likely to be symptomatic. Using this concept, the treatment strategy for full thickness rotator cuff ruptures involving the anterior portion of the supraspinatus tendon is more often surgical.

Our knowledge continued to evolve with the findings of Pinkowski et al about partial thickness ruptures involving the RC. Using five frozen cadavers, they demonstrated partial thickness cable rupture and found out that even partial thickness rupture would be enough to change the glenohumeral kinematics. The simulated tear in the anterior cable increases the anterior translation of humeral head by 38.6% in 30° external rotation. They concluded that these results can explain why orthopaedic surgeons sometimes fail to treat overhead athletes with partial thickness cuff rupture and their shoulder pain if they only perform debridement without repair in surgery.<sup>32</sup>

Besides the more complex pattern and inherent risk for fatty degeneration and disrupted glenohumeral kinematics, re-tears occur more frequently in the setting of the rotator cuff ruptures involving the RC.<sup>33</sup> Additionally, Denard et al laid emphasis upon the relation of the cable integrity and pseudoparalysis. They compared the integrity of the RC in two different patient groups that underwent arthroscopic repair with massive rotator cuff tear, retrospectively. The first group, in which all patients had pseudoparalysis pre-operatively, had more disrupted RC attachment than the other group, in which patients had more active forward flexion > 90°. <sup>34</sup> This shows us the importance of the cable integrity in shoulder biomechanics.

The RI plays an important role in stabilizing the glenohumeral joint. Harryman et al proved this relationship in a cadaveric study, in which they measured the motion of glenohumeral joint in three conditions: in the normal state; after capsule dissection; and imbrication. The capsular and ligamentous components of the RI limit the inferior translation of the glenohumeral joint in an adducted position. Sectioning increases the range of passive flexion, external rotation and adduction. Imbrication causes a decrease in these motions.<sup>35</sup> A second function of the RI is the stabilization of the long head of the biceps tendon via the CHL and SGHL. Both of these ligaments form a U-shaped cover around the biceps tendon, named the 'biceps pulley'. The superior part of the subscapularis tendon also contributes to this stabilization with a buttress effect.<sup>36</sup> Many studies reveal the biomechanical and clinical effects of RI closure. Daly et al suggested that an additional RI closure improves the biomechanical strength of the repaired subscapularis tendon.<sup>37</sup> Furthermore, Mologne et al put forward the idea

that anterior shoulder stability increases with the same closure.<sup>38</sup> A study by Tsai et al showed good clinical results with arthroscopic release of the RI in adhesive capsulitis patients. They declared that the technique does not increase the risk of instability and avoids injury of the axillary nerve and fluid extravasation.<sup>39</sup>

Adhesive capsulitis (frozen shoulder) is another pathological condition that the RI plays a fundamental role in. It was first described by Nevasier et al in 1945 and is seen in patients aged > 40 years.<sup>40</sup> To put it all in simple terms, we can describe it as a thickening or rigidification of the glenohumeral capsule around the RI, as we mentioned above that the deepest layer of the RI consists of the capsule. Histological studies revealed that higher cytokine levels and lack of metalloproteinases could be the cause of the pathology.<sup>41</sup> Although CHL thickening and autoimmune response are also accused of being the cause, we still do not know the exact mechanism. Synovitis in adhesive capsulitis involves all of the anatomical parts of the RI, such as the sheath of long head of the biceps, the CHL and the capsule. Thus, these findings prove to us that whatever the exact mechanism adhesive capsulitis has, it can be said that adhesive capsulitis is a disease of the RI, specifically. The diagnosis is based mainly on clinical findings: pain and loss of range of the motion around the shoulder circle. MRI findings such as obliteration of the RI fat pad and increased signal density of the inferior glenohumeral ligament are diagnostic.<sup>42</sup> Imaging is helpful to exclude other pathologies such as rotator cuff tears, etc. Ultrasound can also be used for diagnosis but it is more difficult to view than in MRI. Treatment is mainly conservative, as most of the cases resolve by themselves. If physiotherapy fails to succeed, manipulation under general anaesthesia or arthroscopic release of the capsule is indicated.

Anatomical proximity of the anterior RC and RI lead to a new definition: 'anterior superior lesions'. This distinct type of rotator cuff tear involves the subscapularis and anterior portion of the supraspinatus tendon and adjacent RI structures: SGHL, CHL and biceps tendon.<sup>43</sup> Case-control clinical studies and further investigation are needed to better define the clinical importance of this new concept.

## Conclusion

The RC is one of the most important contributors to glenohumeral biomechanics. Even in cases of partial thickness rotator cuff tear involving the RC, there are significant changes in joint translation. This knowledge may help shoulder surgeons to clarify the indication for repairing *versus* debridement based on the involvement of the RC rather than the traditional percentage of medial to lateral thickness involvement. Biomechanical studies have been transforming into clinical prospective trials; the benefits of repairing the RC will be studied further as we develop

longer-term results.<sup>32</sup> Our understanding of the RI can help us treat the shoulder during arthroscopic intervention in conditions such as adhesive capsulitis or shoulder instability.<sup>39,44</sup> The relatively new finding of an anatomical structure in the RI like the CGL may continue to change our knowledge about shoulder biomechanics and further clarify identification and clinical management of pathologic processes. Additional studies are needed to clarify the role of the RI and RC and its associated structures in the setting of shoulder instability to better define indications and improve surgical techniques.

#### AUTHOR INFORMATION

<sup>1</sup>Department of Orthopaedics and Traumatology, Hacettepe University, Ankara, Turkey.

<sup>2</sup>Department of Orthopaedics and Traumatology, Loyola University, Chicago, USA.

#### ACKNOWLEDGEMENTS

Special thanks to Aysen Dincer for drawings.

Correspondence should be sent to: G. Huri, Hacettepe Universitesi Eriskin Hastanesi Ortopedi ve Travmatoloji, Sıhhiye, 06100 Ankara, Turkey.  
Email: gazihuri@yahoo.com

#### FUNDING STATEMENT

The author or authors choose not to respond.

#### ICMJE CONFLICT OF INTEREST STATEMENT

N. Garbis declares payment for lectures from DJO and Wright Medical, activity outside the submitted work.

#### LICENCE

© 2019 The author(s)

This article is distributed under the terms of the Creative Commons Attribution-Non Commercial 4.0 International (CC BY-NC 4.0) licence (<https://creativecommons.org/licenses/by-nc/4.0/>) which permits non-commercial use, reproduction and distribution of the work without further permission provided the original work is attributed.

#### REFERENCES

- Schibany N, Zehetgruber H, Kainberger F, et al. Rotator cuff tears in asymptomatic individuals: a clinical and ultrasonographic screening study. *Eur J Radiol* 2004;51:263-268.
- Sher JS, Uribe JW, Posada A, Murphy BJ, Zlatkin MB. Abnormal findings on magnetic resonance images of asymptomatic shoulders. *J Bone Joint Surg [Am]* 1995;77-A:10-15.
- Yamamoto A, Takagishi K, Osawa T, et al. Prevalence and risk factors of a rotator cuff tear in the general population. *J Shoulder Elbow Surg* 2010;19(1):116-120.
- Codman EA. *The Shoulder: Rupture of the supraspinatus tendon and other lesions in or about the subacromial bursa*. Boston, MA: Thomas Todd, 1934.
- Clark JM, Harryman DT. Tendons, ligaments, and capsule of the rotator cuff. Gross and microscopic anatomy. *J Bone Joint Surg [Am]* 2012;74-A:713-725.
- Burkhart SS, Esch JC, Jolson RS. The rotator crescent and rotator cable: an anatomic description of the shoulder's "suspension bridge". *Arthroscopy* 1993;9(6):611-616.
- Fallon J, Blevins FT, Vogel K, Trotter J. Functional morphology of the supraspinatus tendon. *J Orthop Res* 2002;20:920-926.
- Rahu M, Kolts I, Poldoja E, Kask K. Rotator cuff tendon connections with the rotator cable. *Knee Surg Sports Traumatol Arthrosc* 2017;25(7):2047-2050.
- Kolts I, Busch LC, Tomusk H, et al. Macroscopical anatomy of the so-called "rotator interval". A cadaver study on 19 shoulder joints. *Ann Anat* 2002;184:9-14.
- Kolts I, Busch LC, Tomusk H, et al. Anatomy of the coracohumeral and coracoglenoidal ligaments. *Ann Anat* 2000;182(6):563-566.
- Morag Y, Jacobson JA, Lucas D, et al. US appearance of the rotator cable with histologic correlation: preliminary results. *Radiology* 2006;241:485-491.
- Orlandi D, Sconfienza LM, Fabbro E, et al. Preliminary ultrasound evaluation of the rotator cable in asymptomatic volunteers. *J Ultrasound* 2012;15(1):16-19.
- Miller SL, Gladstone JN, Cleeman E, et al. Anatomy of the posterior rotator interval: implications for cuff mobilization. *Clin Orthop Relat Res* 2003;(408):152-156.
- Tamborrini G, Möller I, Bong D, et al. The rotator interval – A link between anatomy and ultrasound. *Ultrasound Int Open* 2017;3(3):E107-E116.
- Woertler K. Rotator interval. *Semin Musculoskelet Radiol* 2015;19:243-253.
- Jost B, Koch PP, Gerber C. Anatomy and functional aspects of the rotator interval. *J Shoulder Elbow Surg* 2000;9:336-341.
- Essman JA, Bell RH, Askew M. Full-thickness rotator-cuff tear. An analysis of results. *Clin Orthop Relat Res* 1991;(265):170-177.
- Pouliart N, Somers K, Eid S, Gagey O. Variations in the superior capsuloligamentous complex and description of a new ligament. *J Shoulder Elbow Surg* 2007;16(6):821-836.
- Wilson WR, Magnussen RA, Irribarra LA, Taylor DC. Variability of the capsular anatomy in the rotator interval region of the shoulder. *J Shoulder Elbow Surg* 2013;22(6):856-861.
- Muto T, Ninomiya H, Inui H, Komai M, Nobuhara K. Rotator interval lesion and damaged subscapularis tendon repair in a high school baseball player. *Case Rep Orthop* 2015;2015:890721.
- Iyengar JJ, Burnett KR, Nottage WM. The abduction external rotation (ABER) view for MRI of the shoulder. *Orthopaedics (Glendale Calif)* 2010;33(8):562-565.
- Gyftopoulos S, Bencardino J, Nevsky G, et al. Rotator cable: MRI study of its appearance in the intact rotator cuff with anatomic and histologic correlation. *AJR Am J Roentgenol* 2013;200(5):1101-1105.
- Gyftopoulos S, Bencardino J, Immerman I, Zuckerman JD. The rotator cable: magnetic resonance evaluation and clinical correlation. *Magn Reson Imaging Clin N Am* 2012;20(2):173-185.
- Morag Y, Jamadar DA, Boon TA, et al. Ultrasound of the rotator cable: prevalence and morphology in asymptomatic shoulders. *AJR Am J Roentgenol* 2012;198:W27-W30.
- Bureau NJ, Blain-Paré E, Tétreault P, Rouleau DM, Hagemeister N. Sonographic visualization of the rotator cable in patients with symptomatic full-thickness rotator cuff tears. *J Ultrasound Med* 2016;35(9):1899-1905.

- 26. Sconfienza LM, Orlandi D, Fabbro E, et al.** Ultrasound assessment of the rotator cable: comparison between young and elderly asymptomatic volunteers and interobserver reproducibility. *Ultrasound Med Biol* 2012;38(1):35-41.
- 27. Bigoni BJ, Chung CB.** MR imaging of the rotator cuff interval. *Magn Reson Imaging Clin N Am* 2004;12(1):61-73. vi.
- 28. Chung CB, Dwek JR, Cho GJ, et al.** Rotator cuff interval: evaluation with MR imaging and MR arthrography of the shoulder in 32 cadavers. *J Comput Assist Tomogr* 2000;24:738e43.
- 29. Zappia M, Castagna A, Barile A, et al.** Imaging of the coracoglenoid ligament: a third ligament in the rotator interval of the shoulder. *Skeletal Radiol* 2017;46(8):1101-1111.
- 30. Gore DR, Murray MP, Sepic SB, Gardner GM.** Shoulder-muscle strength and range of motion following surgical repair of full-thickness rotator-cuff tears. *J Bone Joint Surg [Am]* 1986;68-A:266-272.
- 31. Mesiha MM, Derwin KA, Sibole SC, Erdemir A, McCarron JA.** The biomechanical relevance of anterior rotator cuff cable tears in a cadaveric shoulder model. *J Bone Joint Surg [Am]* 2013;95-A(20):1817-1824.
- 32. Pinkowsky GJ, ElAttrache NS, Peterson AB, et al.** Partial thickness tears involving the rotator cable lead to abnormal glenohumeral kinematics. *J Shoulder Elbow Surg* 2017;26(7):1152-1158.
- 33. Cho NS, Moon SC, Hong SJ, Bae SH, Rhee YG.** Comparison of clinical and radiological results in the arthroscopic repair of full-thickness rotator cuff tears with and without the anterior attachment of the rotator cable. *Am J Sports Med* 2017;45(11):2532-2539.
- 34. Denard P, Koo S, Murena L, Burkhart S.** Pseudoparalysis: the importance of rotator cable integrity. *Orthopedics* 2012;35:1353-1357.
- 35. Harryman DT, Sidles JA, Harris SL, Matsen FA.** The role of the rotator interval capsule in passive motion and stability of the shoulder. *J Bone Joint Surg [Am]* 1992;74-A:53-66.
- 36. Arai R, Mochizuki T, Yamaguchi K, et al.** Functional anatomy of the superior glenohumeral and coracohumeral ligaments and the subscapularis tendon in view of stabilization of the long head of the biceps tendon. *J Shoulder Elbow Surg* 2010;19:58-64.
- 37. Daly CA, Hutton WC, Jarrett CD.** Biomechanical effects of rotator interval closure in shoulder arthroplasty. *J Shoulder Elbow Surg* 2016;25:1094-1099.
- 38. Mologne TS, Zhao K, Hongo M, et al.** The addition of rotator interval closure after arthroscopic repair of either anterior or posterior shoulder instability: effect on glenohumeral translation and range of motion. *Am J Sports Med* 2008;36:1123-1131.
- 39. Tsai MJ, Ho WP, Chen CH, Leu TH, Chuang TY.** Arthroscopic extended rotator interval release for treating refractory adhesive capsulitis. *J Orthop Surg (Hong Kong)* 2017;25(1):2309499017692717.
- 40. Harris G, Bou-Haidar P, Harris C.** Adhesive capsulitis: review of imaging and treatment. *J Med Imaging Radiat Oncol* 2013;57(6):633-643.
- 41. Bunker TD, Reilly J, Baird KS, Hamblen DL.** Expression of growth factors, cytokines and matrix metalloproteinases in frozen shoulder. *J Bone Joint Surg [Am]* 2000;82-A(5):768-773.
- 42. Zappia M, Di Pietto F, Aliprandi A, et al.** Multi-modal imaging of adhesive capsulitis of the shoulder. *Insights Imaging* 2016;7(3):365-371.
- 43. Edwards TB, Walch G, Nove-Josserand L, Gerber C.** *Complex and revision problems in shoulder surgery*. 2nd ed. Philadelphia, PA: Lippincott Williams & Wilkins, 2005.
- 44. Frank RM, Taylor D, Verma NN, et al.** The rotator interval of the shoulder: implications in the treatment of shoulder instability. *Orthop J Sports Med* 2015;3(12):2325967115621494.