

Inflammation and infection

Embolization-sclerotherapy of a refractory large volume post-operative pelvic lymphocele

Eric Addo^a, Min J. Kong^b, Ghassan El-Haddad^{c,*}^a Department of Diagnostic Radiology, University of South Florida, 2 Tampa General Circle, STC 7026, Tampa, FL, 33606, USA^b Morsani College of Medicine, University of South Florida, 12901 Bruce B. Downs Blvd., Tampa, FL, 33612, USA^c Department of Diagnostic Imaging and Interventional Radiology, Moffitt Cancer Center and Research Institute, 12902 Magnolia Dr., Tampa, FL, 33612, USA

ARTICLE INFO

Keywords:

Pelvic lymphocele
Transcollection embolization
Sclerotherapy
Retrograde lymphatic embolization
Lymphatic intervention

Introduction

Interventional radiologists play an integral part in the treatment of post-operative lymphoceles. Our case report describes a modified therapy combining transcollection glue embolization of the major leaking lymphatic channel followed by sclerotherapy of a persistent high-output post-operative lymphocele. There is only one previous report on transcollection embolization of an abdominal lymphocele.⁵ This is the first report of a combined embolization-sclerotherapy of persistent high output pelvic lymphocele with long-term follow up. This case report is exempt from Institutional Review Board by meeting exemption criteria by the Moffitt Cancer Center IRB.

Case presentation

A 68-year-old man with a history of prostate adenocarcinoma Gleason 8 score presented two weeks after laparoscopic robotic assisted radical prostatectomy and bilateral pelvic lymph node dissection (PLND) with pelvic pain and fever. A computed tomography (CT) of the pelvis demonstrated a large pelvic fluid collection. Fluid analysis was consistent with an infected lymphocele, which was drained percutaneously with a 10.2 Fr pigtail catheter.

After antibiotic therapy and 10 weeks of drainage, CT of the pelvis revealed resolution of the collection, and the catheter was removed. However, the patient returned six days later for excessive fluid draining from the prior drainage site, and a new drain was placed in a recurrent pelvic collection (Fig. 1). Due to persistent high output drainage of

1300 ml/day, a drainage catheter check demonstrated opacification of left iliac lymphatic channels consistent with a lymphatic leak (Fig. 2). The drainage catheter was then exchanged for a 10 F sheath and 4 Fr Kumpe catheter was used to select the leaking left iliac lymphatic channel. Through the Kumpe catheter, a 1.9 Fr Prowler microcatheter (Codman Neurovascular, Raynham, Mass., USA) was advanced over a 0.014-in Charter guidewire (Angiodynamics, Latham, NY, USA) into the leaking channel that was then embolized with *n*-butyl cyanoacrylate (nBCA) (Trufill; Cordis Neurovascular, Miami, FL, USA) mixed in a 1:1 ratio with Lipiodol (Guerbet, Aulnay-sous-bois, France) (Fig. 3). A new 10.2 French drainage catheter was placed in the collection and sclerotherapy was performed using 60 ml of Doxycycline sclerosing mixture (Doxycycline 500 mg diluted in 50 ml of normal saline and mixed with 10 ml of Lidocaine 2%). Lymphatic drainage decreased by 70% in 12 days, and tube check two weeks after embolization, demonstrated significant decrease in the size of the lymphocele. Seventeen days after initial embolization, another round of transcatheter sclerotherapy was performed using ethanol mixture (16 ml of dehydrated alcohol mixed with 5 ml of Lidocaine 2%) leading to continued decrease in drainage. The final round of sclerotherapy with ethanol mixture was performed 8 days later, leading to complete resolution of the lymphocele. The drainage catheter was removed, and the patient had no lymphocele recurrence after a 4-year follow up.

Discussion

Most postoperative lymphoceles resolve without requiring

* Corresponding author. Department of Diagnostic Imaging and Interventional Radiology, H. Lee Moffitt Cancer Center and Research Institute, 12902 Magnolia Dr., Tampa, FL, 33612, USA

E-mail addresses: eaddo@health.usf.edu (E. Addo), mkong@health.usf.edu (M.J. Kong), Ghassan.elhaddad@moffitt.org (G. El-Haddad).

<https://doi.org/10.1016/j.eucr.2018.06.010>

Received 10 May 2018; Accepted 19 June 2018

Available online 21 June 2018

2214-4420/© 2018 The Authors. Published by Elsevier Inc. This is an open access article under the CC BY-NC-ND license

(<http://creativecommons.org/licenses/by-nc-nd/4.0/>).

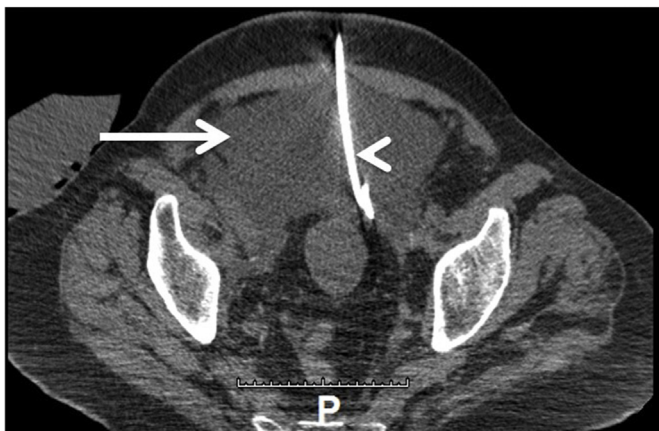


Fig. 1. Pelvic lymphocele (arrow) with interval placement of a pigtail drainage catheter (arrowhead).

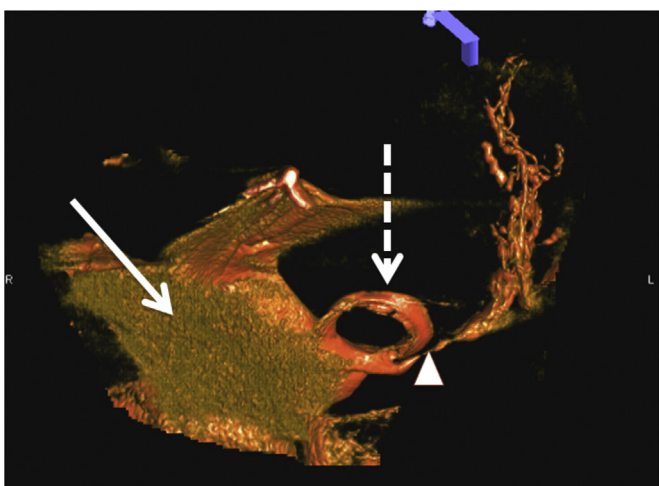


Fig. 2. Three dimensional reconstruction of a Cone beam CT of the pelvis after injection of contrast through the pigtail drainage catheter (dashed arrow) demonstrating a large collection (arrow) and a left iliac lymphatic leak (arrowhead).

treatment. The rate of symptomatic lymphocele following robotic PLND is about 5%.¹ There are a constellation of treatment options for postoperative lymphocele, including percutaneous drainage, sclerotherapy, percutaneous image guided lymphatic ligation, marsupialization, and fibrin glue injection.^{2,3} Therapies are directed to aid in resolving pain, infection, or compression of adjacent structures. Unfortunately, sclerotherapy of refractory large-volume lymphoceles has a high recurrence rate.³ Percutaneous drainage requires a long-term indwelling catheter that carries the increased risk of infection. Pedal lymphangiography is time-consuming and has limited therapeutic success when performed alone. Intranodal lymphangiography has emerged as an alternative to pedal lymphangiography, but is also limited when performed alone due to the inability for Lipiodol to incite granulation reaction or inflammatory response within the leaking duct.⁴ Combining lymphangiography to percutaneous fluoroscopy or CT-guided embolization of the leaking lymphatic duct is somewhat limited in the pelvis due to the anatomical limitation from pelvic bones, arteries, and organs. In the presence of a large volume lymphocele, embolization of the leaking ducts is challenging due to the usual presence of multiple small leaking channels. A transcatheter embolization of leaking lymphatic channel has been documented in one prior case report, where the authors had to repeat transcatheter glue embolization due to persistent leakage. In that case, the patient was followed for a short period of time since he died 3 months after last embolization from reported chemotherapy-related

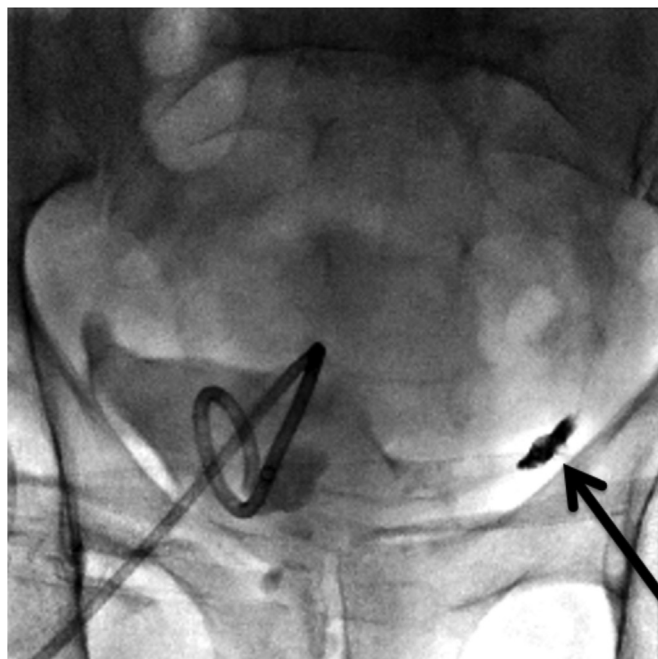


Fig. 3. Pelvic radiograph following the deposition of nBCA glue/Lipiodol in the left iliac lymphatic leaking channel (arrow) through the lymphocele.

complications.⁵

Conclusion

In our case, there was no recurrence of the lymphocele following the procedure with a follow up of 4 years. Our case report highlights a new innovative technique that provides an alternative option for treatment of refractory pelvic lymphoceles. It is, however, only possible if the leaking lymphatic duct can be opacified and catheterized in a retrograde fashion from within the lymphocele. Combined translymphocele retrograde embolization with sclerotherapy is a safe and effective means of treating recurrent pelvic lymphoceles.

Informed consent

Written consent was obtained by the authors from the legal guardian of the patient prior to submission.

Conflicts of interest

The authors declare no conflict of interest.

Acknowledgements

None.

References

1. Liss MA, Palazzi K, Stroup SP, Jabaji R, Raheem OA, Kane CJ. Outcomes and complications of pelvic lymph node dissection during robotic-assisted radical prostatectomy. *World J Urol.* 2013;31:481–488.
2. Mahrer A, Ramchandani P, Trerotola SO, Shlansky-Goldberg RD, Itkin M. Sclerotherapy in the management of postoperative lymphocele. *J Vasc Intervent Radiol.* 2010;21:1050–1053.
3. Karcaaltincaba M, Akhan O. Radiologic imaging and percutaneous treatment of pelvic lymphocele. *Eur J Radiol.* 2005;55:340–354.
4. Kos S, Hauelsen H, Lachmund U, Roeren T. Lymphangiography: forgotten tool or rising star in the diagnosis and therapy of postoperative lymphatic vessel leakage. *Cardiovasc Intervent Radiol.* 2007;30:968–973.
5. Dinc H, Oguz S, Sari A. A novel technique in the treatment of retroperitoneal lymphatic leakage: direct percutaneous embolization through the leakage pouch. *Diagn Interv Radiol.* 2015;21:419–422.