

Increased expression of urotensin II is associated with poor prognosis in hepatocellular carcinoma

DIAN-GANG LIU^{1,2*}, JING CHEN^{3*}, HONG-XIA WANG⁴ and BAO-XIN LI²

¹Department of General Surgery, Xuanwu Hospital, Capital Medical University, Beijing 100053;

²Department of Pharmacology, Harbin Medical University, Harbin, Heilongjiang 150086; ³Department of Gastroenterology, The Second Affiliated Hospital, Harbin Medical University, Harbin, Heilongjiang 150000; ⁴Department of Physiology and Pathophysiology, School of Basic Medical Sciences, Capital Medical University, Beijing 100069, P.R. China

Received July 16, 2015; Accepted September 1, 2016

DOI: 10.3892/ol.2016.5344

Abstract. Urotensin II (UII) and the urotensin II receptor (UT) exhibit mitogenic effects on tumor growth. Our previous study demonstrated that the UII/UT system is upregulated in hepatocellular carcinoma (HCC) and may enhance the proliferation of human hepatoma cells. However, the clinical significance of UII/UT expression in HCC remains unclear. The present study assessed UII messenger RNA (mRNA) expression in 129 surgical specimens obtained from HCC patients using reverse transcription quantitative-polymerase chain reaction. The association between UII mRNA expression and clinicopathological parameters and overall survival rates was also investigated. The results revealed that UII and UT mRNA expression was significantly increased in HCC tissue compared with adjacent non-cancerous liver tissue ($P < 0.001$). Furthermore, a significant correlation was identified between UII expression and histological differentiation ($P < 0.01$), tumor size ($P < 0.01$) and tumor stage ($P = 0.026$). Kaplan-Meier survival analysis indicated that overall survival time was significantly shorter in patients with high UII expression, compared with those with low UII expression ($P < 0.001$). Multivariate analyses indicated that UII expression was an independent predictor of overall survival (odds ratio, 1.12; $P < 0.001$). In addition, UII mRNA was correlated with vascular endothelial growth factor mRNA expression. Therefore, UII expression is an independent biomarker for the prognosis of patients with HCC and thus, the UII/UT system may present a novel therapeutic target for the treatment of HCC.

Introduction

Hepatocellular carcinoma (HCC) is the sixth common malignancy worldwide, and is the second cause of cancer-associated mortality (1). At present, the incidence of HCC is increasing, and the disease is expected to become the third leading cause of cancer-associated mortality in the USA by 2030 (2-4). Recently, the survival rates of HCC patients have improved due to advances in early diagnosis and surgical treatments, including hepatic resection and liver transplantation (5). However, patients with HCC exhibit high postoperative recurrence and mortality rates, and thus, prognosis remains unsatisfactory (6,7). Molecular-targeted therapy has been used to treat HCC; however, only limited improvements in patient survival rates have been achieved (8,9). Therefore, the identification of novel prognostic markers and therapeutic targets for HCC treatment is required.

Urotensin II (UII) is an endogenous peptide that is considered a 'non-classical' pro-angiogenic cytokine (10,11). Previous studies have indicated that UII is involved in the pathogenesis of a number of human malignancies, including breast, bladder, colon and prostate cancer (11-14). Additionally, following the identification of human UII as the cognate ligand for the urotensin II receptor (UT), the function of the UII/UT system in human diseases was extensively investigated (15). Increased expression of UII and UT has been identified in a number of tumor cell lines (16,17), including HeLa cervical cancer cells, BeWo choriocarcinoma cells, IMR-32 neuroblastoma cells, VMRC-RCW human renal cell carcinoma cells, SW-13 adrenocortical carcinoma cells, T98G glioblastoma cells, DLD-1 colorectal adenocarcinoma cells and NB69 neuroblastoma cells. Furthermore, the proliferation of certain tumor cells, including VMRC-RCW cells, SW-13 cells and human pheochromocytoma cells, is stimulated by UII (16). A previous study demonstrated that the motility and invasion of bladder cancer cells was significantly decreased following UT knockdown using a specific small hairpin RNA (12). Furthermore, our previous study revealed that the UII/UT system is upregulated in dithyinitrosamine-induced rat precancerous liver lesions (18), liver cirrhosis (19) and human liver cancer (20). Additionally, the UII/UT system has been demonstrated to stimulate cell proliferation in a human hepatoma cell

Correspondence to: Professor Bao-Xin Li, Department of Pharmacology, Harbin Medical University, 246 Xuefu Road, Harbin, Heilongjiang 150086, P.R. China
E-mail: libaoxinyaoli@126.com

*Contributed equally

Key words: hepatocellular carcinoma, urotensin II, poor prognosis, overall survival

line (BEL-7402 cells) via extracellular signal-regulated kinase (ERK) 1/2, protein kinase C (PKC) and p38 mitogen-activated protein kinase (MAPK) signaling pathways (20). These results indicate that the UII/UT system may be involved in the development of HCC. However, at present the clinical significance of UII expression in HCC remains unclear.

The aim of the present study was to assess UII and UT messenger RNA (mRNA) expression in surgical specimens obtained from HCC patients, and to investigate the association between UII mRNA expression and patient clinicopathological parameters and overall survival rates.

Patients and methods

Patients and tissue collection. A total of 129 HCC patients that underwent surgical resection between September 2007 and January 2014 at Xuanwu Hospital, Capital Medical University (Beijing, China) were included in the present study. None of the patients had received chemotherapy or radiotherapy prior to surgery. HCC diagnosis was based on the World Health Organization criteria (21). Tumor staging was determined according to the sixth edition of the tumor-node-metastasis classification of the International Union Against Cancer (22). The histological types were assigned according to the grading system of Edmondson and Steiner (23). All patients received a single intrahepatic arterial injection dose of 40 mg/m² epirubicin 1 month after surgery. Preoperative clinical data, including patient age, gender, pathological diagnosis, serum α -fetoprotein (AFP) levels, time after surgery to last follow-up and overall survival, were collected prospectively (Table I). The current study was approved by the ethics committee of Xuanwu Hospital, Capital Medical University (Beijing, China), and written informed consent was obtained from all patients.

HCC tissues and adjacent healthy liver tissues were resected, and the resected tissues obtained during surgery were divided into two sections: The first section was immediately snap frozen and stored in liquid nitrogen prior to RNA and protein extraction, and the second section was fixed in 10% neutral buffered formalin (OriGene Technologies, Inc., Beijing, China) for 24 h at room temperature and embedded in paraffin for subsequent immunohistochemical analysis. Liver function was assessed using the Child-Pugh scoring system (24). Only those patients who were classified as Child-Pugh class A were included in the study. Patients with portal vein thrombosis, metastasis, systemic hypertension, chronic kidney disease (creatinine >177 mmol/l and blood urea nitrogen >9 mmol/l), diabetes mellitus or aortic valve diseases were excluded from the present study.

Reverse transcription-quantitative polymerase chain reaction (RT-qPCR). RNA extraction and complementary DNA (cDNA) synthesis were performed as previously described (19). Total RNA was extracted from snap-frozen liver biopsy specimens using TRIzol (Invitrogen; Thermo Fisher Scientific, Inc., Waltham, MA, USA). The cDNA was reverse transcribed using the High-Capacity cDNA Reverse Transcription kit (Applied Biosystems; Thermo Fisher Scientific, Inc.), according to the manufacturer's protocol. UII, UT and vascular endothelial growth factor (VEGF) gene expression were quantified by qPCR. The housekeeping gene

GAPDH was used as the internal control for target genes. Primer sequences (Invitrogen; Thermo Fisher Scientific, Inc.) are presented in Table II. mRNA expression was measured using SYBR[®] Green Real-Time PCR Master Mix (Applied Biosystems; Thermo Fisher Scientific, Inc.) and a 7500 Fast Real-Time PCR system (Applied Biosystems; Thermo Fisher Scientific, Inc.), according to the manufacturer's protocol. PCR was performed in a 20- μ l reaction mixture containing 2 μ g cDNA, 1 μ l of each primer and 10 μ l SYBR Green PCR Master Mix. The conditions for PCR amplification were as follows: 94°C pre-denaturation for 5 min, 94°C denaturation for 30 sec, 60°C annealing for 30 sec, and 72°C extension for 2 min, for a total of 40 cycles. qPCR analysis was performed as previously described (19,25). Comparative quantification cycle (Cq) calculations were all relative to the control group. GAPDH Cq values were subtracted from gene Cq values to give a final Cq value. $\Delta\Delta$ Cq values were achieved by subtracting the average control Δ Cq value, and the expression of UII and UT relative to the control was derived by using the equation $2^{-\Delta\Delta Cq}$ (26). All experiments were performed in triplicate.

Immunohistochemistry. Immunohistochemical analysis was performed as previously described (19). The paraffin-embedded samples were cut into 4- μ m sections and subjected to immunohistochemical staining using the EliVision[™] Plus kit (Maxim Biotechnology Development, Co., Ltd., Fuzhou, China), according to the manufacturer's protocol. Tissue sections were incubated with rabbit anti-human UT antibody (1:200; catalog no. LS-A372; LifeSpan BioSciences, Inc., Seattle, WA, USA) for 18 h in a humidified chamber at 4°C and washed three times with PBS. An enhancer was added for 30 min, followed by three washes in PBS. The sections were then incubated with horseradish peroxidase (HRP)-conjugated goat anti-rabbit antibody (1:1,500; catalog no. ZDR-5306; Beijing Zhongshan Biotechnology Co., Ltd., Beijing, China) for 20 min at 37°C, followed by three washes with PBS. Finally, immunoreactivity was visualized following incubation with 3,3'-diaminobenzidine (Maxim Biotechnology Development, Co., Ltd.) for 10 min. Samples were then counterstained with Mayer's hematoxylin and eosin. As a negative control, PBS was used instead of primary antibodies.

Western blot analysis. Western blot analysis was performed as previously described (18). Briefly, proteins were extracted from liver samples using the RIPA-IV type Mammalian Cell Extraction kit (catalog no. DBI-1017; Bendabio, Shanghai, China), homogenized at 7,104 x g for 15 min at 4°C and assayed using the Pierce BCA Protein Assay kit (Thermo Fisher Scientific, Inc.). Protein samples (40 μ g) were subjected to SDS-PAGE (80 V for 40 min on a 5% acrylamide stacking gel and 120 V for 70 min on a 10% running gel) and subsequently transferred to a nitrocellulose membrane (Hybond-C Extra; GE Healthcare Bio-Sciences, Uppsala, Sweden). The membranes were blocked with TBS (10 mmol/l Tris-HCl and 250 mol/l NaCl), 5% non-fat powdered milk and 0.1% Tween-20 for 2 h, followed by incubation with primary rabbit anti-human UT antibody (1:1,000; catalog no. sc-20940; Santa Cruz Biotechnology, Inc., Dallas, Texas, USA) overnight at 4°C. The blots were washed with TBS containing 0.1% Tween-20 for 10 min (three times),

Table I. Associations between UII expression and clinicopathological parameters in 129 hepatocellular carcinoma patients.

| Parameter | Patients, (n=129) | UII mRNA expression | | P-value |
|------------------------------|-------------------|---------------------|-------------|---------|
| | | Low (n=53) | High (n=76) | |
| Age, years | | | | 0.421 |
| <60 | 59 | 22 | 37 | |
| ≥60 | 70 | 31 | 39 | |
| Gender | | | | 0.398 |
| Male | 80 | 35 | 45 | |
| Female | 49 | 18 | 31 | |
| HBsAg | | | | 0.139 |
| Positive | 78 | 28 | 50 | |
| Negative | 51 | 25 | 26 | |
| AFP, ng/ml | | | | 0.854 |
| ≤400 | 55 | 24 | 31 | |
| >400 | 74 | 29 | 45 | |
| Liver cirrhosis | | | | 0.295 |
| Present | 87 | 33 | 54 | |
| Absent | 42 | 20 | 22 | |
| Esophageal varices | | | | 0.388 |
| Present | 77 | 34 | 43 | |
| Absent | 52 | 19 | 33 | |
| Histological differentiation | | | | <0.001 |
| Well/moderate | 58 | 38 | 20 | |
| Poor | 71 | 15 | 56 | |
| Tumor size, cm | | | | <0.001 |
| ≤5 | 62 | 42 | 20 | |
| >5 | 67 | 11 | 56 | |
| Pathological stage | | | | 0.026 |
| I-II | 58 | 30 | 28 | |
| III-IV | 71 | 23 | 48 | |

AFP, α -fetoprotein; HBsAg, hepatitis B surface antigen; UII, urotensin II; UT, urotensin II receptor; VEGF, vascular endothelial growth factor; mRNA, messenger RNA.

followed by incubation with anti- β -actin antibody (1:1,000; catalog no. ab8226; Abcam, Shanghai, China) or HRP-linked goat anti-rabbit immunoglobulin G secondary antibody (1:1,500; catalog no. GGHL-15PXSP; Immunology Consultants Laboratory, Inc., Portland, OR, USA) for 2 h at room temperature. Films were scanned using a Gel Doc imaging system (Bio-Rad Laboratories, Inc., Hercules, CA, USA). Proteins were visualized using the SuperSignal™ West Pico Chemiluminescent Substrate kit (catalog no. 34079; Thermo Fisher Scientific, Inc.), and bands were quantified via scanning densitometry using the Image Lab™ software version 5.1 (Bio-Rad Laboratories, Inc.). UT protein expression was normalized to β -actin expression.

Statistical analysis. Data are presented as the mean \pm standard deviation. Statistical analysis was performed using one way analysis of variance and the Student's *t* test. The χ^2 test was used to analyze the associations between UII

expression and patient clinicopathological characteristics. The Kaplan-Meier method was used for survival analysis, and differences in survival were estimated using the log-rank test. Prognostic factors were examined by univariate and multivariate analyses using the Cox proportional hazards regression model. Correlations between different mRNA expression levels were analyzed using the Pearson rank sum test. $P < 0.05$ was considered to indicate a statistically significant difference. All statistical analyses were performed using SPSS 20.0 statistical software (IBM SPSS, Armonk, NY, USA).

Results

Clinical data. Patient characteristics and data are presented in Table I. The patient cohort included 80 males and 49 females, with a median age of 58.37 years (age range, 21-73 years). The median follow-up time was 84 months. Histologically,

Table II. Primer sequences.

| Gene | Primer sequence | Product size (bp) | NCBI accession number |
|-------|--|-------------------|-----------------------|
| UII | (F) 5'-TCTCCTTGACTCCAGGGAAATA-3' (R) 5'-GCAGTATCTGTAGAAGGGAAGC-3' | 104 | NM-006786.2 |
| UT | (F) 5'-CCCAACGCAACCCTCAA-3' (R) 5'-CGACAGCAGAGTCCCAATG-3' | 96 | NM-018949.1 |
| VEGF | (F) 5'-CACTGAGGAGTCCAACATCAC-3' (R) 5'-AGGAAGCTCATCTCTCCTATGT-3' | 97 | NC-000006.12 |
| GADPH | (F) 5'-AGCCACATCGCTCAGACAC-3' (R) 5'-GCCCAATACGACCAAATCC-3' | 67 | NM-002046.3 |

NCBI, National Center for Biotechnology Information; F, forward; R, reverse; UII, urotensin II; UT, urotensin II receptor; VEGF, vascular endothelial growth factor.

all patients exhibited evidence of HCC with clear surgical margins. None of the patients had been administered somatostatin or vasoactive drugs for 1 week prior to surgery.

UII and UT gene expression is significantly higher in HCC tissues than in adjacent non-cancerous tissues. UII and UT mRNA expression was evaluated in 129 HCC samples and adjacent non-cancerous hepatic tissues by RT-qPCR. The results revealed a 6-fold increase in UII mRNA levels in HCC tissues compared with adjacent non-cancerous tissues ($P < 0.01$; Fig. 1A). Similarly, in HCC tissues, UT expression levels were increased by ~10-fold compared with adjacent non-cancerous tissues ($P < 0.01$; Fig. 1B). These results revealed that UII and UT mRNA levels were significantly higher in HCC tissues compared with adjacent non-cancerous tissues ($P < 0.01$).

VEGF expression is significantly higher in HCC than in adjacent non-cancerous tissues. The expression of VEGF mRNA was also examined by RT-qPCR. A 7-fold increase in VEGF mRNA was observed in HCC tissues when compared with adjacent non-cancerous tissues ($P < 0.01$; Fig. 1C). Furthermore, a significant positive correlation was identified between VEGF mRNA expression and UII expression in HCC ($P < 0.001$; $r = 0.78$; Fig. 1D).

Immunohistochemical analysis of UT expression in HCC tissues. Immunohistochemistry revealed that non-cancerous tissues exhibited low UT protein expression levels (Fig. 2A, lower left panel). By contrast, abundant UT protein expression was identified in HCC tissues (Fig. 2A, lower right panel). Furthermore, UT staining was observed in the cytoplasm of tumor stromal cells (Fig. 2B). Western blot analysis of six representative HCC tissues identified a significant increase in the levels of UT protein in cancerous tissues when compared with non-cancerous tissues (Fig. 2C and D). These findings are consistent with the relative UT mRNA expression levels detected by RT-qPCR (Fig. 1B).

High UII mRNA expression is associated with tumor size, histological differentiation and pathological stage in HCC patients. Associations between UII expression and

clinicopathological parameters in HCC patients were analyzed using the χ^2 test. The median mRNA expression level of UII in HCC tissues, 6.56-fold, was used as the cut-off value to divide the 129 patients into two groups: A low-expression group (UII mRNA expression level < 6.56 ; $n = 53$) and a high-expression group (UII mRNA expression level > 6.56 ; $n = 76$). As presented in Table I, a correlation was identified between UII expression and tumor size ($P < 0.001$), histological differentiation ($P < 0.001$) and pathological stage ($P = 0.026$). However, no significant associations were observed between UII mRNA expression and gender ($P = 0.398$), age ($P = 0.421$), liver cirrhosis ($P = 0.295$), expression of hepatitis B surface antigen (HBsAg) ($P = 0.139$) or serum AFP levels ($P = 0.854$). Furthermore, the association between UT expression and clinicopathological parameters was analyzed (Table III). The mean UT relative mRNA expression level of HCC tissues was 10.04, which was used as the cut-off value to divide the 129 patients into two groups. Higher UT expression was significantly associated with tumor size ($P < 0.001$) and pathological stage ($P = 0.016$); however, no significant association was identified between UT mRNA expression and gender ($P = 0.197$), age ($P = 0.543$), liver cirrhosis ($P = 0.193$), HBsAg expression ($P = 0.183$), serum AFP levels ($P = 0.724$) or histological differentiation ($P = 0.252$) (Table III).

High UII mRNA expression is associated with poor prognosis in HCC patients. Overall survival was analyzed using the Kaplan-Meier method, which demonstrated that the survival rates of HCC patients with high UII expression were significantly lower than those of patients with low UII expression ($P < 0.001$; Fig. 3). Univariate analysis demonstrated a significant association between overall patient survival rates and tumor size ($P = 0.031$), histological differentiation grade ($P = 0.017$), pathological stage ($P = 0.017$) and UII mRNA expression ($P = 0.017$) (Table IV). However, no significant associations were identified between UT mRNA expression ($P = 0.058$), patient age ($P = 0.432$), gender ($P = 0.781$), HBsAg expression ($P = 0.908$), serum AFP levels ($P = 0.407$) or patient outcomes. Multivariate analysis using the Cox proportional hazards model for all the variables included in the univariate analysis indicated that histological differentiation grade

Table III. Associations between UT expression and clinicopathological parameters in 129 hepatocellular carcinoma patients.

| Parameter | Patients, (n=129) | UT mRNA expression | | P-value |
|------------------------------|-------------------|--------------------|-------------|---------|
| | | Low (n=54) | High (n=75) | |
| Age, years | | | | 0.543 |
| <60 | 59 | 23 | 31 | |
| ≥60 | 70 | 31 | 39 | |
| Gender | | | | 0.197 |
| Male | 80 | 37 | 43 | |
| Female | 49 | 17 | 32 | |
| HBsAg | | | | 0.183 |
| Positive | 78 | 29 | 49 | |
| Negative | 51 | 25 | 26 | |
| AFP, ng/ml | | | | 0.724 |
| ≤400 | 55 | 24 | 31 | |
| >400 | 74 | 30 | 44 | |
| Liver cirrhosis | | | | 0.193 |
| Present | 87 | 33 | 54 | |
| Absent | 42 | 21 | 21 | |
| Esophageal varices | | | | 0.520 |
| Present | 77 | 34 | 43 | |
| Absent | 52 | 20 | 32 | |
| Histological differentiation | | | | 0.252 |
| Well/moderate | 58 | 39 | 19 | |
| Poor | 71 | 15 | 56 | |
| Tumor size, cm | | | | <0.001 |
| ≤5 | 62 | 42 | 20 | |
| >5 | 67 | 12 | 55 | |
| Pathological stage | | | | 0.016 |
| I-II | 58 | 31 | 27 | |
| III-IV | 71 | 23 | 48 | |

UT, urotensin II receptor; AFP, α -fetoprotein; HBsAg, hepatitis B surface antigen.

Table IV. Univariate and multivariate analysis of overall survival for 129 patients with hepatocellular carcinoma.

| Variable | Univariate analysis | | | Multivariate analysis | | |
|--------------------|---------------------|-------------|---------|-----------------------|-------------|---------|
| | HR | 95% CI | P-value | HR | 95% CI | P-value |
| UII expression | 2.05 | 0.176-1.035 | 0.017 | 1.12 | 0.072-0.811 | <0.001 |
| UT expression | 0.58 | 0.302-1.071 | 0.058 | 0.55 | 0.331-1.075 | 0.080 |
| Age | 1.71 | 1.238-2.794 | 0.432 | 1.53 | 0.275-4.346 | 0.867 |
| Gender | 0.54 | 0.134-1.967 | 0.781 | 0.87 | 0.207-3.675 | 0.450 |
| HBsAg | 1.22 | 0.475-1.557 | 0.908 | 1.26 | 0.296-4.541 | 0.800 |
| AFP | 0.68 | 0.472-2.034 | 0.407 | 1.23 | 0.170-3.043 | 0.877 |
| Liver cirrhosis | 0.73 | 0.443-2.907 | 0.951 | 1.47 | 0.074-2.693 | 0.203 |
| Histological | 1.33 | 0.479-3.871 | 0.017 | 1.76 | 0.037-0.394 | 0.031 |
| Tumor size | 1.37 | 0.537-3.880 | 0.031 | 2.41 | 0.045-2.364 | 0.440 |
| Pathological stage | 0.97 | 0.097-3.554 | 0.017 | 1.45 | 1.011-2.093 | 0.006 |

UII, urotensin II; UT, urotensin II receptor; HR, hazard ratio; CI, confidence interval; HBsAg, hepatitis B surface antigen; AFP, α -fetoprotein.

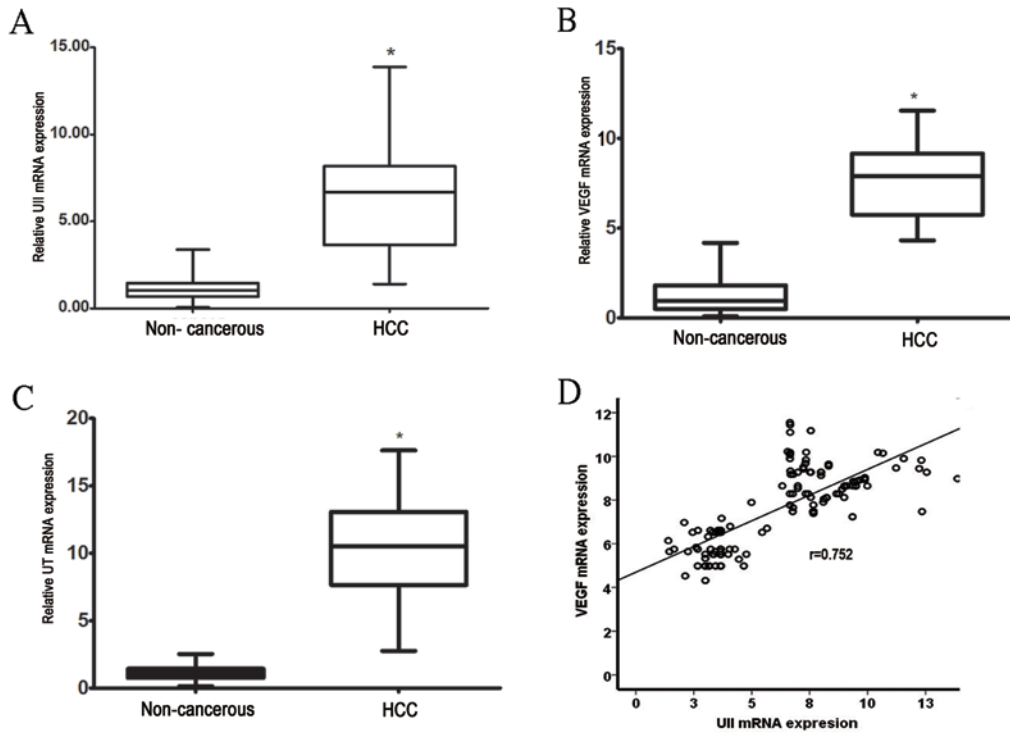


Figure 1. mRNA expression in human liver tissue. The levels of (A) UII, (B) UT and (C) VEGF mRNA were measured in HCC and adjacent non-cancerous tissue by reverse transcription-quantitative polymerase chain reaction. The results are expressed as the Cq for the target gene standardized to the Cq of the GAPDH housekeeping gene. Values are expressed as the mean (95% confidence interval) relative to the controls (adjacent non-cancerous tissues), which were arbitrarily assigned a value of 1. * $P<0.01$ vs. control. (D) UII mRNA expression and VEGF mRNA expression were positively correlated in HCC tissue ($r=0.752$; $P<0.01$; Pearson correlation test). UII, urotensin II; UT, urotensin II receptor; VEGF, vascular endothelial growth factor; HCC, hepatocellular carcinoma; mRNA, messenger RNA; Cq, quantification cycle.

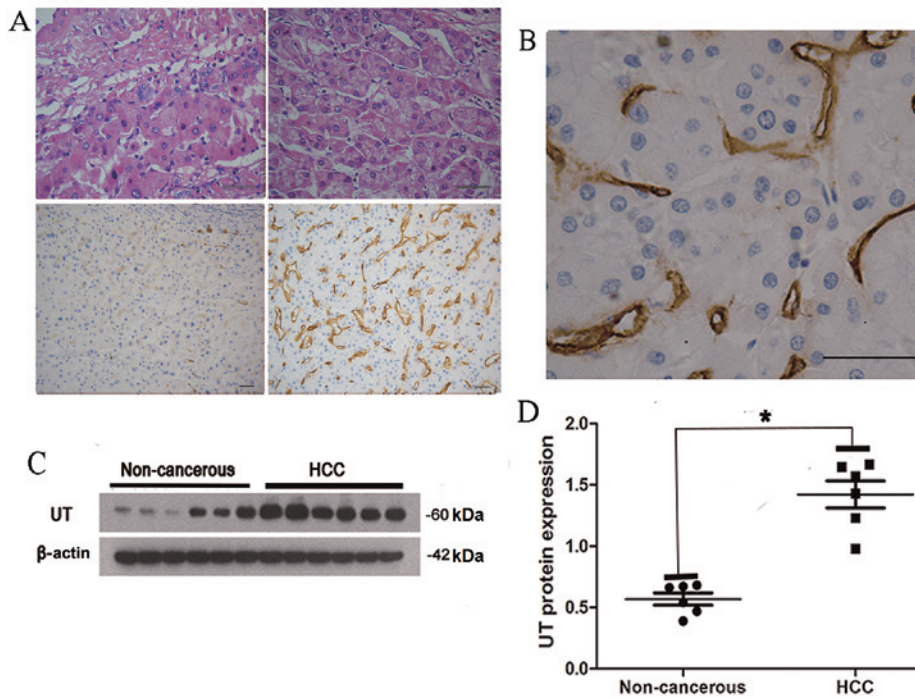


Figure 2. IHC staining of UT protein in HCC and adjacent non-cancerous tissues. (A) Upper left panel, adjacent non-cancerous tissue (HE staining); upper right panel, HCC tissue (HE staining); lower left panel, adjacent non-cancerous tissue (IHC staining); and lower right panel, HCC tissue (IHC staining). IHC staining revealed low levels of UT expression in adjacent non-cancerous tissue; however, increased UT expression was observed in HCC tissue. Scale bars, 50 μ m. (B) Positive UT expression was identified in the cytoplasm of tumor stromal cells. Scale bar, 50 μ m. (C) UT protein expression was analyzed by western blotting in six representative HCC tissues and the matched adjacent non-cancerous tissues. A 60-kDa band, indicative of UT expression, was observed in the liver of 6 patients. (D) Quantification of western blotting revealed that UT protein expression was significantly higher in HCC tissues compared with adjacent non-cancerous tissues. UT protein expression was normalized to β -actin and expressed as the mean \pm standard deviation. * $P<0.01$, HCC vs. adjacent non-cancerous tissue. HCC, hepatocellular carcinoma; UT, urotensin II receptor; IHC, immunohistochemical; HE, hematoxylin and eosin.

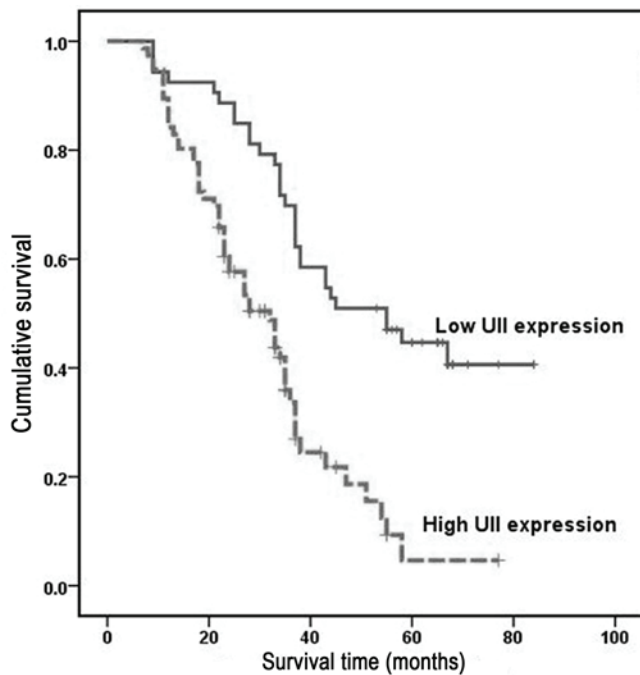


Figure 3. Kaplan-Meier survival analysis of all primary hepatocellular carcinoma patients (n=129) with high UII expression (n=53) and low UII expression (n=69) following surgical resection. The survival time of patients in the high UII expression group was significantly lower than that of patients in the low UII expression group ($P < 0.001$). UII, urotensin II.

($P = 0.031$), pathological stage ($P = 0.006$) and UII expression ($P = 0.0001$) were all independent prognostic factors for overall survival in HCC patients (Table IV).

Discussion

Tumor cells produce and secrete a number of vasoactive peptides such as endothelin-1 and adrenomedullin, which act as paracrine growth stimulators (27). UII is a somatostatin-like cyclic undecapeptide that has been identified as a potent mammalian vasoconstrictor (15). As well as affecting vascular tone, UII stimulates cell proliferation, and previous studies have indicated that it is involved in the pathogenesis of certain tumors, including breast, bladder, colon and prostate cancer (12-14,28). Our previous study demonstrated that the expression of the UII/UT system was increased in HCC tissues and cell lines, and that exogenous administration of UII regulated the proliferation of cancer cells and increased the expression of various transcription factors, including ERK, PKC and p38 MAPK (18,20). However, the association between the UII/UT system and the clinicopathological behavior of HCC remains unclear.

For a more comprehensive insight into the clinical value of the UII/UT system in HCC, in the current study, RT-qPCR was performed to measure UII/UT mRNA expression, and the association between UII/UT mRNA expression and patient clinicopathological features was analyzed. The results revealed that UII mRNA expression was significantly upregulated in HCC tissues, and that its expression was correlated with tumor stage, size and differentiation. Furthermore, it was determined that UII mRNA expression was an independent prognostic factor for overall patient survival. In addition, UT mRNA

expression was analyzed by RT-qPCR, and it was demonstrated that UT mRNA was significantly overexpressed in HCC tumor tissue samples when compared with adjacent non-tumor tissue samples. Western blot analysis confirmed these results, demonstrating elevated UT protein expression in six representative HCC tissues. Taken together, these results support the hypothesis that UII may function as an oncogene in HCC, and thus may exhibit an important function in the tumorigenesis of HCC.

Univariate and multivariate analyses demonstrated that UII expression and prognostic factors, including tumor size, histological differentiation and pathological stage, are independent prognostic factors for HCC patients. Univariate analyses demonstrated a significant association between increased UII mRNA expression in HCC tissues and decreased overall survival rates. Kaplan-Meier survival analysis indicated that the overall survival rate of HCC patients with high UII expression was significantly lower than that of patients with low UII expression. These results indicate that UII expression may represent a novel prognostic marker for HCC patients.

VEGF is one of the most potent angiogenic factors and an essential mediator of both angiogenesis and endochondral ossification (29). Previous studies have demonstrated that it serves a critical function in HCC tumor angiogenesis (30-32). Furthermore, it has been reported that the pro-angiogenic cytokine UII directly stimulates an angiogenic phenotype in endothelial cells following exposure to UII, and enhances the process indirectly by delaying the production of other pro-angiogenic factors such as VEGF (10). It is also hypothesized that different genetic backgrounds of patients and etiological factors may affect the development of HCC, and thus, different mechanisms of transformation may occur (29,33). As a single-agent therapy, the multi-kinase inhibitor sorafenib appears to have limited efficacy in HCC (9). However, using sorafenib in combination with other agents that control HCC-derived symptoms may be clinically beneficial for patients with HCC (34). UII is a non-classical angiogenic factor (10,11), and may therefore regulate the endothelial expression of VEGF in HCC. Notably, in the present study, a significant positive correlation was identified between UII and VEGF expression. Therefore, UII may be involved in tumor angiogenesis by stimulating the production of VEGF and by enhancing tumor growth and progression in HCC. Furthermore, UT staining was observed in tumor stromal cells. UII is a vasoactive cyclic neuropeptide that activates UT and exhibits various effects; therefore, it has been postulated that UII may stimulate the proliferation of tumor stromal cells (35). However, further studies are required to confirm this hypothesis.

In conclusion, the results of the present study indicated that the UII/UT system is overexpressed in HCC, and that high UII mRNA expression is associated with poor overall survival rates. These findings suggest that the UII/UT system may represent a potential therapeutic target for HCC treatment in the future.

Acknowledgements

The present study was supported by The National Natural Science Foundation of China (Beijing, China; grant no. 81170408), The China Postdoctoral Science Special Foundation (Beijing, China; grant no. 2013T60386) and The China Postdoctoral Science Foundation (Beijing, China; grant no. 2012M510094).

References

- Chow PK, Choo SP, Ng DC, Lo RH, Wang ML, Toh HC, Tai DW, Goh BK, Wong JS, Tay KH, *et al*: National cancer centre singapore consensus guidelines for hepatocellular carcinoma. *Liver Cancer* 5: 97-106, 2016.
- Yang JD and Roberts LR: Hepatocellular carcinoma: A global view. *Nat Rev Gastroenterol Hepatol* 7: 448-458, 2010.
- Maluccio M and Covey A: Recent progress in understanding, diagnosing, and treating hepatocellular carcinoma. *CA Cancer J Clin* 62: 394-399, 2012.
- Rahib L, Smith BD, Aizenberg R, Rosenzweig AB, Fleshman JM and Matrisian LM: Projecting cancer incidence and deaths to 2030: The unexpected burden of thyroid, liver, and pancreas cancers in the United States. *Cancer Res* 74: 2913-2921, 2014.
- Bodzin AS and Busuttill RW: Hepatocellular carcinoma: Advances in diagnosis, management, and long term outcome. *World J Hepatol* 7: 1157-1167, 2015.
- Forner A, Llovet JM and Bruix J: Hepatocellular carcinoma. *Lancet* 379: 1245-1255, 2012.
- Bruix J and Sherman M; American Association for the Study of Liver Diseases: Management of hepatocellular carcinoma: An update. *Hepatology* 53: 1020-1022, 2011.
- Llovet JM and Bruix J: Molecular targeted therapies in hepatocellular carcinoma. *Hepatology* 48: 1312-1327, 2008.
- Peck-Radosavljevic M: Drug therapy for advanced-stage liver cancer. *Liver cancer* 3: 125-131, 2014.
- Albertin G, Guidolin D, Sorato E, Oselladore B, Tortorella C and Ribatti D: Urotensin-II-stimulated expression of pro-angiogenic factors in human vascular endothelial cells. *Regul Pept* 172: 16-22, 2011.
- Yumrutas O, Oztuzcu S, Büyükhatipoglu H, Bozgeyik I, Bozgeyik E, Ipci YZ, Bagis H, Cevik MO, Kalender ME, Eslik Z and Arslan A: The role of the UTS2 gene polymorphisms and plasma Urotensin-II levels in breast cancer. *Tumor Bio* 36: 4427-4432, 2015.
- Franco R, Zappavigna S, Gigantino V, Luce A, Cantile M, Cerrone M, Facchini G, Perdonà S, Pignata S, Di Lorenzo G, *et al*: Urotensin II receptor determines prognosis of bladder cancer regulating cell motility/invasion. *J Exp Clin Cancer Res* 33: 48, 2014.
- Federico A, Zappavigna S, Romano M, Grieco P, Luce A, Marra M, Gravina AG, Stiuso P, D'Armiento FP, Vitale G, *et al*: Urotensin-II receptor is over-expressed in colon cancer cell lines and in colon carcinoma in humans. *Eur J Clin Invest* 44: 285-294, 2014.
- Grieco P, Franco R, Bozzuto G, Toccaceli L, Sgambato A, Marra M, Zappavigna S, Migaldi M, Rossi G, Striano S, *et al*: Urotensin II receptor predicts the clinical outcome of prostate cancer patients and is involved in the regulation of motility of prostate adenocarcinoma cells. *J Cell Biochem* 112: 341-353, 2011.
- Ames RS, Sarau HM, Chambers JK, Willette RN, Aiyar NV, Romanic AM, Loudon CS, Foley JJ, Sauermelech CF, Coatney RW, *et al*: Human urotensin-II is a potent vasoconstrictor and agonist for the orphan receptor GPR14. *Nature* 401: 282-286, 1999.
- Takahashi K, Totsune K, Murakami O, Arihara Z, Noshiro T, Hayashi Y and Shibahara S: Expression of urotensin II and its receptor in adrenal tumors and stimulation of proliferation of cultured tumor cells by urotensin II. *Peptides* 24: 301-306, 2003.
- Takahashi K, Totsune K, Murakami O and Shibahara S: Expression of urotensin II and urotensin II receptor mRNAs in various human tumor cell lines and secretion of urotensin II-like immunoreactivity by SW-13 adrenocortical carcinoma cells. *Peptides* 22: 1175-1179, 2001.
- Wang H, Dong K, Xue X, Feng P and Wang X: Elevated expression of urotensin II and its receptor in diethylnitrosamine-mediated precancerous lesions in rat liver. *Peptides* 32: 382-387, 2011.
- Liu D, Chen J, Wang J, Zhang Z, Ma X, Jia J and Wang Y: Increased expression of urotensin II and GPR14 in patients with cirrhosis and portal hypertension. *Int J Mol Med* 25: 845-851, 2010.
- Yu XT, Wang PY, Shi ZM, Dong K, Feng P, Wang HX and Wang XJ: Up-regulation of urotensin ii and its receptor contributes to human hepatocellular carcinoma growth via activation of the PKC, ERK1/2, and p38 MAPK signaling pathways. *Molecules* 19: 20768-20779, 2014.
- Shariff MI, Cox IJ, Gomaa AI, Khan SA, Gedroyc W and Taylor-Robinson SD: Hepatocellular carcinoma: Current trends in worldwide epidemiology, risk factors, diagnosis and therapeutics. *Expert Rev Gastroenterol Hepatol* 3: 353-367, 2009.
- Lei HJ, Chau GY, Lui WY, Tsay SH, King KL, Loong CC and Wu CW: Prognostic value and clinical relevance of the 6th Edition 2002 American joint committee on cancer staging system in patients with resectable hepatocellular carcinoma. *J Am Coll Surg* 203: 426-435, 2006.
- Pirisi M, Leutner M, Pinato DJ, Avellini C, Carsana L, Toniutto P, Fabris C and Boldorini R: Reliability and reproducibility of the edmondson grading of hepatocellular carcinoma using paired core biopsy and surgical resection specimens. *Arch Pathol Lab Med* 134: 1818-1822, 2010.
- Wang SB, Wang JH, Chen J, Giri RK and Chen MH: Natural history of liver cirrhosis in south China based on a large cohort study in one center: A follow-up study for up to 5 years in 920 patients. *Chin Med J (Engl)* 125: 2157-2162, 2012.
- Schmittgen TD and Livak KJ: Analyzing real-time PCR data by the comparative C(T) method. *Nat Protoc* 3: 1101-1108, 2008.
- Livak KJ and Schmittgen TD: Analysis of relative gene expression data using real-time quantitative PCR and the 2(-Delta Delta C(T)) Method. *Methods* 25: 402-408, 2001.
- Bagnato A and Catt KJ: Endothelins as autocrine regulators of tumor cell growth. *Trends Endocrinol Metab* 9: 378-383, 1998.
- Zhou CH, Wan YY, Chu XH, Song Z, Xing SH, Wu YQ and Yin XX: Urotensin II contributes to the formation of lung adenocarcinoma inflammatory microenvironment through the NF- κ B pathway in tumor-bearing nude mice. *Oncol Lett* 4: 1259-1263, 2012.
- Dai J and Rabie AB: VEGF: An essential mediator of both angiogenesis and endochondral ossification. *J Dent Res* 86: 937-950, 2007.
- Shibuya M: Vascular endothelial growth factor and its receptor system: Physiological functions in angiogenesis and pathological roles in various diseases. *J Biochem* 153: 13-19, 2013.
- Mukoizu T, Nagai H, Matsui D, Kanekawa T and Sumino Y: Serum VEGF as a tumor marker in patients with HCV-related liver cirrhosis and hepatocellular carcinoma. *Anticancer Res* 33: 1013-1021, 2013.
- Marra M, Sordelli IM, Lombardi A, Lamberti M, Tarantino L, Giudice A, Stiuso P, Abbruzzese A, Sperlongano R, Accardo M, *et al*: Molecular targets and oxidative stress biomarkers in hepatocellular carcinoma: An overview. *J Transl Med* 9: 171, 2011.
- Colombino M, Sperlongano P, Izzo F, Tatangelo F, Botti G, Lombardi A, Accardo M, Tarantino L, Sordelli I, Agresti M, *et al*: BRAF and PIK3CA genes are somatically mutated in hepatocellular carcinoma among patients from South Italy. *Cell Death Dis* 3: e259, 2012.
- Caraglia M, Giuberti G, Marra M, Addeo R, Montella L, Murolo M, Sperlongano P, Vincenzi B, Naviglio S, Prete SD, *et al*: Oxidative stress and ERK1/2 phosphorylation as predictors of outcome in hepatocellular carcinoma patients treated with sorafenib plus octreotide LAR. *Cell Death Dis* 2: e150, 2011.
- Scognamiglio PL, Di Natale C, Perretta G and Marasco D: From peptides to small molecules: An intriguing but intricate way to new drugs. *Curr Med Chem* 20: 3803-3817, 2013.