

## Surgical management in patient with uveitis

Somasheila I Murthy, Rajeev Reddy Pappuru, K Madhavi Latha<sup>1</sup>, Sripathi Kamat<sup>1</sup>, Virender S Sangwan

Surgery in the management of uveitis can be divided based on indication: either for therapeutic or can be for diagnostic purposes or to manage complications. The commonest indications include: Visual rehabilitation: surgery for removal of cataract, band keratopathy, corneal scars, pupillary membranes, removal of dense vitreous membranes, management of complications: anti-glaucoma surgery, vitreous hemorrhage, retinal detachment and chronic hypotony and diagnostic: aqueous tap, vitreous biopsy, tissue biopsy (iris, choroid). In this review, we shall describe the surgical technique for visual rehabilitation and for management of complications.

**Key words:** Cataract surgery in uveitis, glaucoma surgery in uveitis, vitrectomy in uveitis

## Access this article online

Website:

www.ijo.in

DOI:

10.4103/0301-4738.114103

## Quick Response Code:



The indications for surgery in the management of uveitis can be divided as:

1. Visual rehabilitation: Surgery for removal of cataract, band keratopathy, corneal scars, pupillary membranes, removal of dense vitreous membranes.
2. Management of complications: Anti-glaucoma surgery, vitreous hemorrhage, retinal detachment and chronic hypotony.
3. Diagnostic: Aqueous tap, vitreous biopsy, tissue biopsy (iris, choroid).

Table 1 lists the various surgical techniques and the indications in uveitis.

In uveitis, the dictum is to operate in a quiet eye, especially, if it is for an elective surgery as for visual rehabilitation. It is mandatory to wait for at least 3 months after the last episode of active disease. While complete absence of anterior chamber and vitreous cells is highly desirable to improve outcomes, in certain uveitis (like Fuch's uveitis syndrome) this may not be necessary or possible. Based on the type of uveitis, pre-operative and peri-operative stepping up of corticosteroids is often required, especially in more severe forms.

## Cataract Surgery in Uveitis

### Pre-operative assessment

A complete ophthalmic examination should help determine the cause of visual loss, i.e., whether cataract is the primary cause or the visual disability is due to other factors. Based on this assessment, the goal of surgery-visual rehabilitation or

improved visualization of the posterior segment-should be explained to the patient.

### Indications for cataract surgery

Foster and Rashid have described four indications for cataract surgery,<sup>[1]</sup>

1. Phaco-antigenic uveitis: Active inflammation as a result of leakage of lens proteins, in which case cataract surgery is mandatory
2. Visually significant cataract: With well controlled inflammation and potential for visual improvement exists
3. Cataract impairing visualization of the posterior segment, especially in cases of suspected retinal or disc neovascularization and other retino-choroidal pathology
4. Cataract impairing visualization of the posterior segment in a patient undergoing vitreo-retinal surgery.

Successful visual outcome depends not only on successful surgery, but also on pre-existing irreversible structural damage. Factors adversely affect the visual outcome include presence of concurrent glaucoma or hypotony, band shaped keratopathy, extensive posterior synechia, retinal detachment, optic atrophy, cystoid macular edema (CME), macular atrophy or hole, epiretinal membranes (ERM), and vitreous opacities.<sup>[1]</sup>

### Pre-operative control of inflammation

The most important step in cataract surgery in uveitis is adequate pre-operative control of inflammation. Elimination of inflammation for at least 3 months (preferably longer) before surgery is desirable. Several authors have reiterated this and the rule of thumb is to operate only when cells are absent (0-5) in the anterior chamber as assessed on slit lamp examination. In cases with vitritis, reduction of vitreous cells is desirable, but these persist even in the inactive stage and cannot be completely eliminated.

Various authors have recommended the addition of supplementary peri-operative anti-inflammatory therapy in the form of oral and systemic steroids, but it is not clearly established whether this improves the outcomes in well-controlled disease.

Department of Cornea and Anterior Segment Service, <sup>1</sup>Smt Kannuri Santamma Vitreo- Retinal Service, L.V. Prasad Eye Institute, Kallam Anji Reddy Campus, Hyderabad, India

**Correspondence to:** Dr. Somasheila I Murthy, L. V. Prasad Eye Institute, L. V. Prasad Marg, Banjara Hills, Hyderabad - 500 034, India. E-mail: smurthy@lvpei.org

Manuscript received: 12.12.2012; Revision accepted: 26.03.2013

**Table 1: Surgical indication, etiology and choice of surgery**

Indication	Etiology	Surgical procedure	Prognosis
Band-shaped keratopathy	JIA	Chelation, superficial keratectomy, phototherapeutic excimer laser keratotomy	Tends to recur and may need repeat treatment
Cataract	Seen in upto 70% of uveitis	Phacoemulsification±IOL, lensectomy and vitrectomy	Ranges from good to poor, depending on the type or uveitis and age of the patient
Corneal scar	Post-herpetic keratitis and peripheral ulcerative keratitis	Lamellar or penetrating keratoplasty	Guarded prognosis in view of high risk of rejection or recurrence
IOL precipitates	Chronic anterior uveitis	YAG laser "pigment sweeping"	Often recurs, repeat YAG laser and topical corticosteroids are required
Pupillary membranes	Anterior uveitis in JIA	Nd-YAG laser or pars plana vitrectomy	Guarded prognosis, may require removal of the IOL in some cases
Glaucoma, pupillary block, 2° angle closure	Chronic anterior uveitis, herpetic uveitis, Fuchs uveitic syndrome	Laser iridectomy, filtering surgery with mitomycin vs aqueous drainage tube	Consider performing laser peripheral iridectomy when 270° or more of posterior synechiae
Cystoid macular edema	Seen in upto 75% of uveitis	Intravitreal steroid injection, intravitreal implants (Retisert, Ozurdex), pars plana vitrectomy	Often recurs, poor visual outcome if long standing

JIA: Juvenile idiopathic arthritis, IOL: Intraocular lens, Nd-YAG: neodymium doped yttrium aluminium garnet

## Surgical Technique

Phacoemulsification is the preferred technique for its many advantages; however, in some cases where there are extensive synechiae [Fig. 1], extra capsular cataract extraction and posterior chamber intraocular lens (IOL) implantation can be safely performed. With careful patient selection, diligent surgery and appropriate perioperative care, phacoemulsification with IOL implantation is safe and effective in a majority of patients with uveitis [Fig. 2 a and b]. In a study at our institute,<sup>[2]</sup> of the 89 patients who underwent cataract extraction, 67% underwent Extra capsular cataract surgery (ECCE) with posterior chamber intra-ocular lens implantation (PCIOL) implantation. Only 10.4%, in whom adequate papillary dilatation was present, underwent phacoemulsification (PE). There was no significant difference in the post-operative visual acuity 6 months post-operatively in either group. However, other studies have reported better outcomes with phacoemulsification compared to ECCE. In our experience as long as the surgical time and iris manipulations are kept to a minimum, the final outcome does not seem to differ in either technique. The choice of technique is perhaps best left to the surgeon.

IOL implantation in uveitis: A PCIOL can be safely implanted in cases of idiopathic non-granulomatous anterior uveitis, Human leucocyte antigen (HLA-B27) associated uveitis and Fuchs heterochromic iridocyclitis,<sup>[3,4]</sup> [Fig. 3 a and b]. Moderate success is expected in diseases such as Vogt Koyanagi Harada syndrome, sympathetic ophthalmia, Behcet's disease, pars planitis,<sup>[5]</sup> and any burnt out or inactive uveitis. Most specialists consider IOL implantation contraindicated in children with Juvenile idiopathic arthritis (JIA)-associated uveitis, since the IOL is presumed to act as a scaffold for the formation of intra-ocular membranes,<sup>[6]</sup> further leading to cyclitic membranes, hypotony, and eventual phthisis bulbi. More experience and longer periods of follow-up is needed before IOL implantation can be recommended as a safe procedure in these cases.

## Complications of cataract surgery in uveitis

- Posterior capsular rent, zonular dehiscence
- Retained lens matter or nuclear fragment
- Hyphema
- Immediate post-operative: Severe post-operative inflammation
- CME
- Secondary glaucoma
- Uveitis flare-up
- Persistent inflammation
- Optic capture and pupillary membranes [Fig. 4]
- Posterior capsular opacification
- Hypotony.

## Surgery in Band Shaped Keratopathy

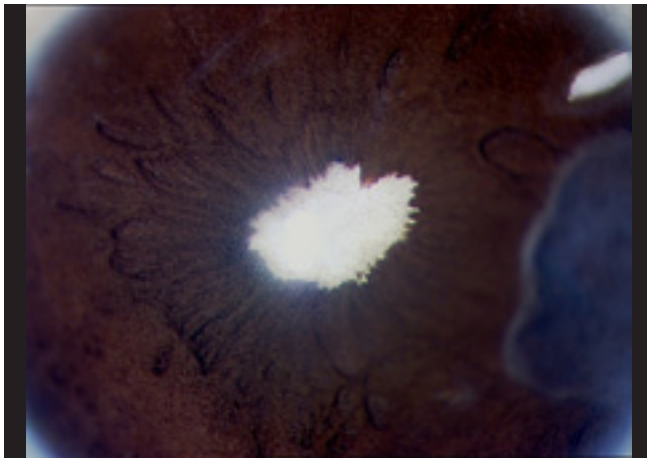
Patients with chronic uveitis may develop deposition of calcium at the level of corneal epithelial basement membrane and Bowman's membrane. This deposition usually starts in the periphery slowly encroach the central area obscuring fundus view and surgeons view during various surgical procedures. Band shaped keratopathy (BSK) is commonly encountered in JIA and can occur at an amblyogenic age; thus, requiring its removal.

Current modalities in approaching this problem are:

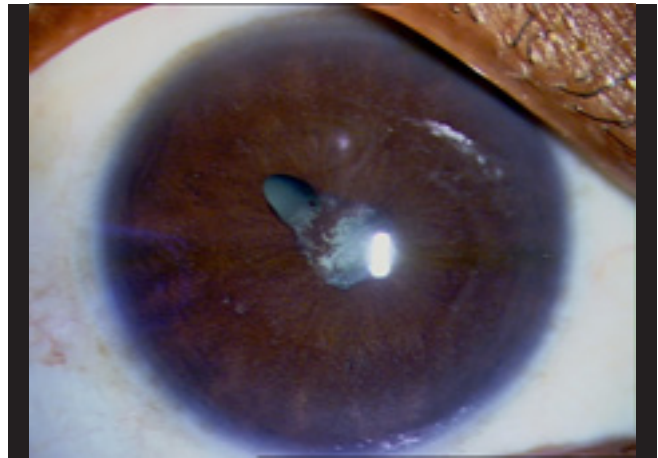
1. Phototherapeutic keratectomy (PTK)
2. Chemical chelation with ethylenediminetetracetic acid (EDTA)
3. Superficial keratectomy with or without adjuvant amniotic membrane transplant (AMT).

## PTK

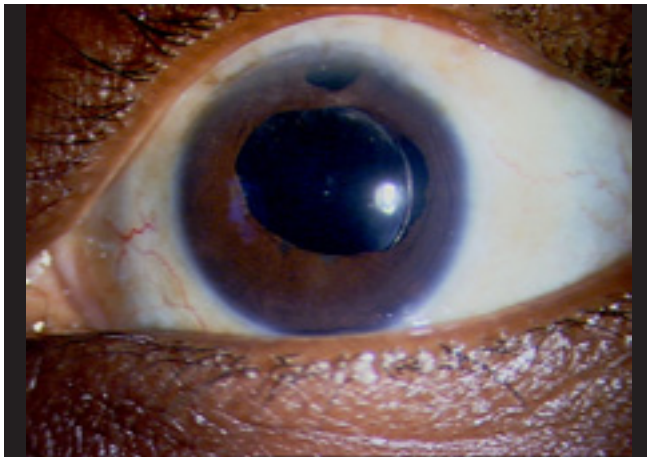
Under topical anesthesia, the epithelium is debrided manually and the laser energy is directed over the central 6 mm zone. This works very well to create a central uniformly smooth bed leading to excellent visual recovery as there is removal of the anterior stromal opacification. Its only disadvantage is that there is loss of corneal tissue during the procedure and hence cannot be repeated very often.<sup>[7]</sup>



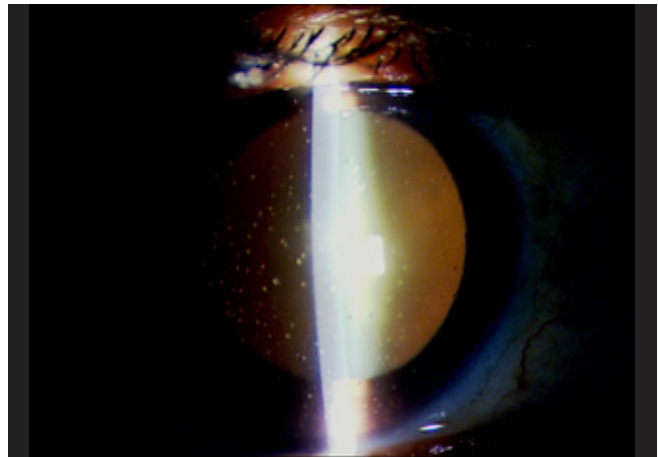
**Figure 1:** Slit lamp photograph shows a patient with chronic idiopathic panuveitis with a white cataract and extensive posterior synechiae and neo-vascularization on the anterior lens capsule



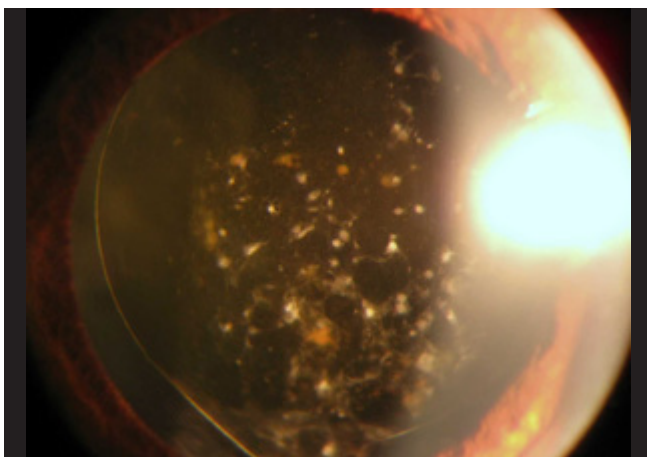
**Figure 2a:** Complicated cataract in a patient with idiopathic anterior uveitis with posterior synechia and a quiet eye at the time of surgery



**Figure 2b:** Post-operative outcome after phacoemulsification



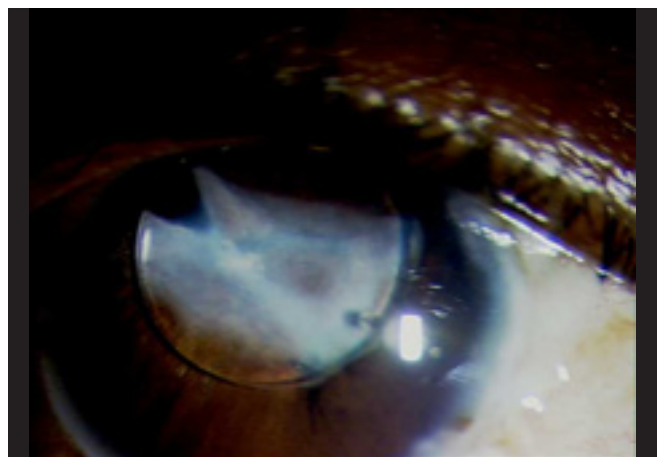
**Figure 3a:** Pre-operative (a) photograph of a patient with Fuch's uveitic syndrome, showing diffuse, large keratic precipitates



**Figure 3b:** Post-operative photograph shows recurrence of these precipitates as stellate deposits on the intraocular lens

#### EDTA chelation

This popular time-tested technique involves superficial removal of overlying calcium deposits by gentle scraping the epithelium



**Figure 4:** Optic capture of the intraocular lens, which was implanted in the sulcus and pupillary membranes in a 35-year-old female patient with intermediate uveitis who underwent surgery 5 years ago

manually and soaking the corneal epithelium in 0.05 mol, 1.5% EDTA for 3-5 min. This can be carried out using a cellulose sponge soaked in solution. It is later followed by copious irrigation with

normal saline and removal of loosened epithelium and calcium debris manually with a number 15 surgical blade. A bandage contact lens is then applied finally and eye patched.

#### Superficial keratectomy with or without adjuvant AMT

Superficial keratectomy involving the calcium deposition and underlying diseased epithelium is done using No: 15 blades or a creating a tunnel in the anterior stroma to dissect a plane of affected stroma. This is followed by placing amniotic membrane using fibrin glue on the exposed bed. This procedure yields good results in terms of smoothening of the corneal surface and improved optical clarity.

### Glaucoma Surgery

Glaucoma in the setting of uveitis presents a clinical challenge, both in diagnosis and management.<sup>[8]</sup> It is estimated that around 20% of patients with uveitis will eventually develop secondary glaucoma. Medical therapy is important but insufficient and in such high-risk patients glaucoma surgery needs to be considered as a vision salvageable procedure and not an end stage procedure. There are several mechanisms of secondary glaucoma:

1. Severe anterior segment inflammation resulting in decreased trabecular filtration
2. Pupillary block glaucoma (posterior synechia)
3. Angle closure due to peripheral anterior synechia
4. Steroid response.

Pupillary block glaucoma is difficult to identify in the presence of chronic inflammation and posterior synechia in which cases the iris bombe is very shallow and peripheral. In such cases laser iridotomy acts both as confirmatory and therapeutic procedure.

Studies have proven the declining success rates of filtering surgery from 80% at 2 years to 30% at 5 years,<sup>[9,10]</sup> and it is mainly because of younger age of the patient, inflammation mediated fibrous tissue growth and closure of the bleb. Recent retrospective analysis by Chawla *et al.* demonstrated good long-term survival rates of 5FU enhanced trabeculectomy in patients with uveitic glaucoma and concluded that for patients above 30 years of age, 5 FU enhanced trabeculectomy is appropriate as first line surgery, whereas glaucoma drainage implant should be used as primary procedure in those below 30 years.<sup>[11]</sup>

The current surgical approach is the use of aqueous drainage devices like Ahmed glaucoma valve (AGV).<sup>[10]</sup> These devices present alternate aqueous pathways by channeling aqueous from anterior chamber through a long tube to an equatorial plate that promotes bleb formation [Fig. 5 a and b].

#### Technique

The surgery is taken up under either general or local anesthesia depending upon the age of the patient. A fornix-based conjunctival flap is fashioned and a subconjunctival pocket is created between the recti usually in the superotemporal quadrant. This is achieved by blunt dissection of tenons from the episclera. Later, after priming the AGV the valve body is placed in the pocket and sutured in place with 10-0 vicryl suture, 10 mm away from limbus. The drainage tube is trimmed and 2-3 mm length of it is placed in the anterior chamber parallel to iris plane with the help of anchoring sutures to the sclera, making sure both iris and corneal endothelial surfaces do not come in contact with the tube. Scleral patch graft is applied over the exposed tube using 10-0 nylon interrupted sutures and conjunctiva closed with 8-0 vicryl suture.

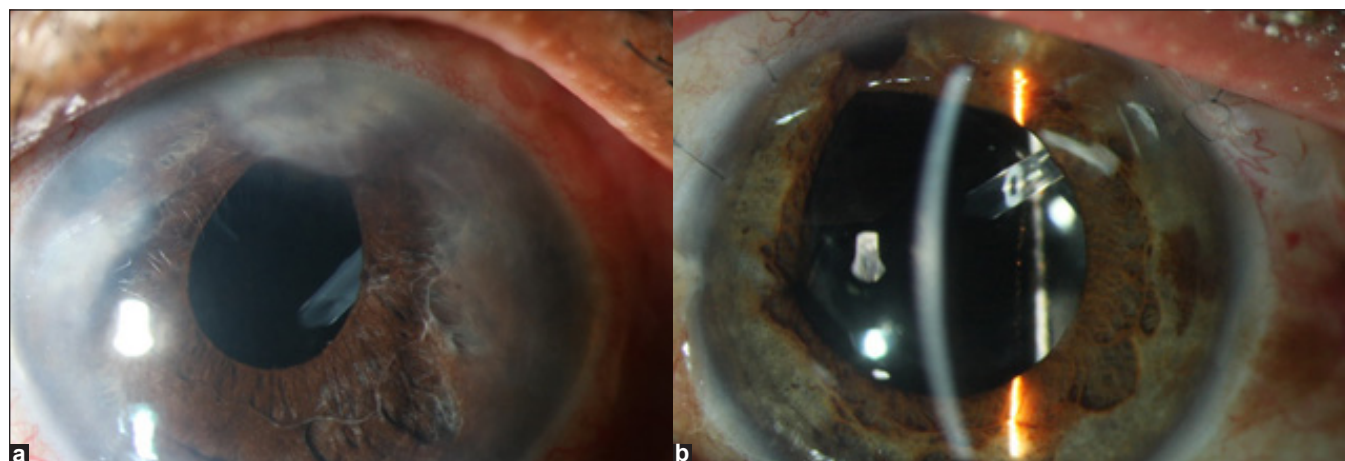
The success rates range from 94% to 74% at the end of 1 year,<sup>[12,13]</sup> requiring one or two medications at the end of 4 years for control of intra-ocular pressure (IOP).

If all the above approaches fail, aqueous suppression can be achieved by transcleral cyclo-photocoagulation or cryotherapy aimed at destructing the ciliary body and thus, reducing the intraocular pressure. Recent case report by Dastiridou *et al.* demonstrated the success rate of transcleral diode cyclophotocoagulation for refractory secondary glaucoma in pediatric patient with juvenile idiopathic arthritis.<sup>[14]</sup>

### Vitreo-retinal Surgery in Uveitis

Pars plana vitrectomy (PPV) has been increasingly performed both for diagnostic and therapeutic purposes in management of patients with uveitis. The indications can be broadly classified as,<sup>[15]</sup>

1. Diagnostic PPV
2. Therapeutic PPV
3. Both indications.



**Figure 5:** (a and b) Slit lamp photograph of a patient with chronic uveitis and secondary glaucoma who underwent Ahmed glaucoma valve implant, showing the valve well positioned in the anterior chamber, diffuse (a) and slit illumination (b)

### Timing of surgery

Whereas cataract surgery in uveitis is ordinarily performed only after complete quiescence of the uveitis for 3-6 months, PPV is often required in active disease.<sup>[13]</sup> For non-urgent elective procedures, quiescence of anterior segment inflammation is advisable. Inflammatory choroidal effusion or exudative retinal detachments are commonly considered contraindications.<sup>[16]</sup> Active pars plana exudation may increase the risk of retinal injury from the pars plana sclerotomy sites.

### Diagnostic vitrectomy

#### Indications

1. Atypical clinical presentations
2. Non-responsive to empirical treatment with corticosteroids/immunosuppressants
3. Rapidly progressive disease with inconclusive non-invasive work-up
4. Strong suspicion of malignancy.

#### Techniques

1. Vitreous tap/aspiration
2. Vitreous biopsy
3. Chorioretinal biopsy.

In general, undiluted vitreous is preferred for cytology, viral culture, polymerase chain reaction (PCR), and antibody determinations. Diluted vitreous wash can be used for flow cytometry and deoxyribonucleic acid (DNA) gene rearrangement studies and filtered for bacterial and fungal cultures. Vitreous cells and bacterial or fungal cultures are transported at room temperature. Viral cultures, PCR samples and antibodies are refrigerated or frozen, depending upon the time until the assay can be performed. Coordination with the laboratory prior to PPV is desirable to avoid damage to the specimen.

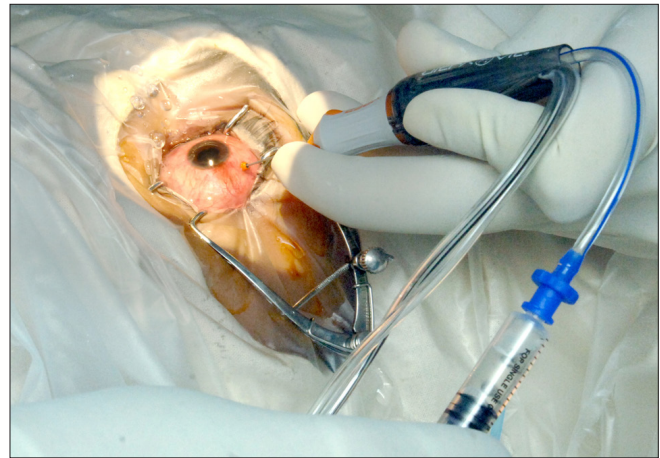### Technique of diagnostic vitrectomy

#### Vitreous tap/aspiration

This technique is performed using 23/26 G needle directly attached to 2 ml syringe via flexible tube containing balanced salt solution under topical anesthesia. Approximate amount drawn is around 0.2-0.5 ml. this procedure is easy to perform, but can cause retinal traction at the vitreous base and retinal detachment. This is not the preferred technique of obtaining vitreous sample.

#### Vitreous biopsy

This technique can be performed under peribulbar or topical anesthesia. Standard two-port vitrectomy is the preferred technique. However, this can be performed using single port technique. Infusion can be through the pars plana canula or anterior chamber maintainer. The infusion is kept off until the sample is withdrawn. Infusion cannula helps to maintain the intraocular pressure following biopsy thereby preventing sudden hypotony. Approximately, 1 ml of vitreous is obtained directly from the vitrectomy hand piece (20, 23 or 25 gauge cutter) with a cutting rate of 1200-1500 cuts/min, through an inline stopcock and tubing attached to syringe, which is held by the assistant providing passive suction [Fig. 6]. Standard three-port vitrectomy is preferable while performing combined diagnostic and therapeutic vitrectomy. Apart from allowing



**Figure 6:** Intra-operative photograph showing single port diagnostic vitrectomy using 23 G vitrectomy cutter with 2 ml disposable syringe connected to suction tubing

the visualization of the fundus and allowing better diffusion of intraocular medications, it also has the advantage of yielding more samples with enough material available for multiple tests.

The vitreous sample can be studied in the laboratory for the following tests tailored to patient's clinical profile.

1. Microbiological tests: Smears have their limitation with gram positivity for only 66% of culture proven cases.<sup>[16,17]</sup> Results of the smear are available faster and help in rapid institution of specific therapy. Undiluted samples are inoculated in culture media. Two solid media (blood agar, chocolate agar), two liquid media (thioglycolate broth, brain heart infusion broth) and Saborauds and potato dextrose agar for fungal cultures are inoculated. Diluted samples are passed through a Millipore filter and the filter, which contains the microorganisms and cellular elements on the surface, is then cut and used for culture. Culture plates should be kept for 4-6 weeks before declaring the sample to be negative for infective etiology.
2. PCR: PCR is a rapid sensitive molecular biological technique performed using small quantity of sample obtained from the eye, which amplifies specific region of the DNA in order to produce multiple copies of DNA. The test DNA can be patient's own DNA as in intraocular lymphoma or microbial DNA.
3. Cytopathology: Helps to differentiate infective, non-infective, and malignant etiologies. Diagnosis of malignancy is based on cell morphology and therefore, it is important to take measures to prevent cell morphology and prevent the cells from degenerating. Infective etiology is diagnosed based on isolation of microbe or fungal hyphae. Non-infective etiological diagnosis is based on the presence of nonspecific inflammatory cells
4. Flow cytometry and immunohistochemistry: Detects cell or tissue bound antigens by using fluorescence activated cell sorters in flow cytometry and fluorescence or enzyme labeled antibodies in immunohistochemistry.
5. Antibody detection: Detects local antibody detection using various techniques like Enzyme linked immune-sorbent assay (ELISA). Goldmann-Witmer coefficient relates vitreous to serum antibodies (> 3 significant).

6. Cytokine assay: Indicates polymorphonuclear cellular activity. IL1.2, 6 in infection and uveitis. IL10 concentrations (ratio of IL10:IL6) have been found to be elevated in intraocular lymphoma.

#### *Chorioretinal biopsy*

Highly invasive procedure usually carried out when other invasive procedures fail to provide useful information and disease is rapidly progressive and non-responding to standard therapy. This can be performed using external approach (trans-scleral) or internal approach (endoretinal). Endoretinal is preferred technique. The site of the biopsy is lasered to prevent future retinal detachment. Retinochoroidal tissue is taken after dissecting using intraocular scissors and forceps. The tissue is sent for standard histological, immunopathological, and culture tests. The complications of this procedure are retinal detachment (RD), choroidal hemorrhage, proliferative vitreo-retinopathy (PVR) changes and infection.

#### **Therapeutic vitrectomy**

##### *Indications*

1. Media opacities obscuring the visual axis
2. Tractional or combined retinal detachment
3. Non-resolving CME
4. ERM as consequence of inflammation
5. Cyclitic membrane removal for the treatment of non-responding hypotony.

In general, therapeutic vitrectomy aims at improving vision by clearing the visual axis, reducing inflammation in active disease and thereby treating non-resolving CME if any. PPV facilitates post-operative control of inflammation by immune-suppressive drugs, perhaps by removing a depot of activated lymphocytes, and cytokines, making it easier for the drugs to work or by increasing penetration of the drugs into the eye.

PPV is gaining popularity in the management of intermediate uveitis and CME, thereby clearing the visual axis and promoting the regression of CME in patients with recurrent intermediate uveitis resulting in visual improvement.<sup>[18,19]</sup> However, ERM, RD and macular hole that develop as a consequence of uveitis may need vitreo-retinal surgery as per the requirement. It is important to promptly recognize cyclitic membranes either pre-operatively using ultrasound biomicroscopy or early removal of these membranes followed by appropriate intraocular tamponade can prevent recalcitrant hypotony in some of the patients.

This procedure is performed using the standard 20/23/25G system using the standard three-port vitrectomy following standard principles of vitreoretinal surgery.

#### **Implants for the treatment of uveitis**

A sustained drug-delivery device has many purported advantages for these uveitis patients. Maintaining a low, but constant drug level should, theoretically, reduce the number of recurrences of uveitis and subsequent ocular damage as well as reduce steroidal side-effects.

#### **Retisert**

This is a 0.59 mg fluocinolone acetonide device (manufacturer: Bausch and Lomb Inc., Rochester, NY, USA) controls uveitis with minimal recurrences and is the first FDA-approved

treatment for posterior uveitis. The non-biodegradable drug-delivery device is surgically sutured to the sclera and releases fluocinolone acetonide at a controlled rate for 2.5 years. For patients with posterior uveitis requiring steroid treatment, the Retisert implant provides better vision and lower rates of recurrence compared to periocular steroid injections or systemic steroid therapy.<sup>[20,21]</sup> The control of uveitis with the Retisert comes at a price: A 90% rate of cataract formation and a 40% rate of glaucoma requiring surgery. The long-term complications are similar to those seen with a sutured IOL, including suture failure, dislocated implant, suture exposure, and endophthalmitis.

#### **Ozurdex**

In September 2010, the Ozurdex (dexamethasone steroid implant; Allergan, Inc.) was FDA approved for the treatment of uveitis. The Ozurdex device is implanted transconjunctivally through a 23-gauge needle in the office. The drug is contained in a polymer of lactic and glycolic acid that biodegrades into carbon dioxide and water over the course of 6 months. Dexamethasone controls inflammation for 4-6 months.<sup>[22,23]</sup>

#### **Implants in trials**

The newer implants include calcineurin inhibitor voclosporin (Luveniq), antitumor necrosis factor monoclonal humanized antibody (Humira), fluocinolone acetonide (Iluvien implant). The past 5 years have brought patients the first therapies specifically for the treatment of uveitis. With new drugs in the pipeline, uveitis specialists can expect better treatments and less blindness from uveitis in the future.

#### **Post-operative complications of vitrectomy in uveitis**

1. Hypotony: Hypotony following surgery in uveitic eyes is felt to relate to shutdown of the aqueous humor production from acute, severe inflammation. Wound leakage and retinal detachment are other possibilities that need to be excluded. Hypotony generally responds to topical, systemic or periocular/intraocular corticosteroids.
2. Retinal detachment: It is a severe complication in uveitic eyes since the intraocular inflammation would be predicted to produce more ERM formation and a poor prognosis. Causes of retinal detachment that are specific to uveitis patients include instrument passage through pars plana exudates, contracture of pars plana exudates and tractional detachment, and retinal breaks at the edge of chorioretinitis.
3. Vitreous hemorrhage: It is relatively common following PPV of all types, presumably from oozing from the sclerotomies. Blood generally clears from a vitrectomized eye within 1 month. Neovascularization or retinal tear formation should be kept in mind as possible complications leading to vitreous hemorrhage that require treatment.
4. Uveitis recurrence: Recurrence of uveitis following PPV can occur. Transient increases in inflammation immediately after surgery are generally, easily treated with oral corticosteroids. Because the vitreous gel is absent, vitreous cells are sparser and affect vision less. In the absence of vitreous cellular reaction, there may be a false sense that the inflammation is entirely under control.

#### **Summary**

It is possible, in fact even expected, to achieve successful visual outcomes following various surgeries in uveitis. The predictability has improved primarily because of a higher

level of understanding of the uveitic disease among clinicians.

Pre-operative factors include proper patient selection and counseling and pre-operative control of inflammation. It is now well-recognized that chronic inflammation, even low grade, can irreversibly damage the retina and optic nerve and therefore inflammatory control both pre- and post-operatively is vital. The use of immunosuppressive agents other than steroids also helps control inflammation and has enabled long-term use of these agents especially as steroids sparing medication. Management of post-operative complications, especially inflammation and glaucoma, earlier rather than later, has also contributed to improved outcomes. Still several questions are left unanswered, especially in the area of pediatric uveitis with cataract, which continues to challenge the ophthalmologist to further refine the surgical technique and search for new treatment.

## References

1. Foster CS, Rashid S. Management of coincident cataract and uveitis. *Curr Opin Ophthalmol* 2003;14:1-6.
2. Hazari A, Sangwan VS. Cataract surgery in uveitis. *Indian J Ophthalmol* 2002;50:103-7.
3. Javadi MA, Jafarinasab MR, Araghi AA, Mohammadpour M, Yazdani S. Outcomes of phacoemulsification and in-the-bag intraocular lens implantation in Fuchs' heterochromic iridocyclitis. *J Cataract Refract Surg* 2005;31:997-1001.
4. Harper SL, Foster CS. Intraocular lens explantation in uveitis. *Int Ophthalmol Clin* 2000;40:107-16.
5. Ganesh SK, Babu K, Biswas J. Phacoemulsification with intraocular lens implantation in cases of pars planitis. *J Cataract Refract Surg* 2004;30:2072-6.
6. BenEzra D, Cohen E. Cataract surgery in children with chronic uveitis. *Ophthalmology* 2000;107:1255-60.
7. Rathi VM, Vyas SP, Vaddavalli PK, Sangwan VS, Murthy SI. Phototherapeutic keratectomy in pediatric patients in India. *Cornea* 2010;29:1109-12.
8. Takahashi T, Ohtani S, Miyata K, Miyata N, Shirato S, Mochizuki M. A clinical evaluation of uveitis-associated secondary glaucoma. *Jpn J Ophthalmol* 2002;46:556-62.
9. Towler HM, McCluskey P, Shaer B, Lightman S. Primary trabeculectomy with 5FU for glaucoma secondary to uveitis. *Ocul Immunol Inflamm* 1995;3:163-70.
10. Rachmiel R, Trope GE, Buys YM, Flanagan JG, Chipman ML. Ahmed glaucoma valve implantation in uveitic glaucoma versus open-angle glaucoma patients. *Can J Ophthalmol* 2008;43:462-7.
11. Chawla A, Mercieca K, Fenerty C, Jones NP. Outcomes and complications of trabeculectomy enhanced with 5-fluorouracil in adults with glaucoma secondary to Uveitis. *J Glaucoma* 2012. [In press].
12. Papadaki TG, Zacharopoulos IP, Pasquale LR, Christen WB, Netland PA, Foster CS. Long-term results of Ahmed glaucoma valve implantation for uveitic glaucoma. *Am J Ophthalmol* 2007;144:62-9.
13. Da Mata A, Burk SE, Netland PA, Baltatzis S, Christen W, Foster CS. Management of uveitic glaucoma with Ahmed glaucoma valve implantation. *Ophthalmology* 1999;106:2168-72.
14. Dastiridou AI, Androudi S, Praidou A, Brazitikos P, Brozou CG, Tsironi EE. Transscleral diode laser cyclophotocoagulation for refractory glaucoma secondary to juvenile idiopathic arthritis: A short term follow-up. *Int Ophthalmol* 2012. [In press]
15. Gupta V, Gupta A, Nihawan R. Vitreoretinal surgery in uveitis. Eds: Gupta A, Gupta V, Herbolt C P. Jaypee Brothers Medical Pub; 2<sup>nd</sup> edition; 2009. p. 779.
16. Bovey EH, Herbolt CP. Vitrectomy in the management of uveitis. *Ocul Immunol Inflamm* 2000;8:285-91.
17. Forster RK, Abbott RL, Gelender H. Management of infectious endophthalmitis. *Ophthalmology* 1980;87:313-9.
18. Stavrou P, Baltatzis S, Letko E, Samson CM, Christen W, Foster CS. Pars plana vitrectomy in patients with intermediate uveitis. *Ocul Immunol Inflamm* 2001;9:141-51.
19. Wiechens B, Nölle B, Reichelt JA. Pars-plana vitrectomy in cystoid macular edema associated with intermediate uveitis. *Graefes Arch Clin Exp Ophthalmol* 2001;239:474-81.
20. Jaffe GJ, Martin D, Callanan D, Pearson PA, Levy B, Comstock T. Fluocinolone acetonide uveitis study group. Fluocinolone acetonide implant (retisert) for noninfectious posterior uveitis. *Ophthalmology* 2006;113:1020-7.
21. Multicenter Uveitis Steroid Treatment (MUST) Trial Research Group, Kempen JH, Altaweel MM, Holbrook JT, Jabs DA, Louis TA, *et al.* Randomized comparison of systemic anti-inflammatory therapy versus fluocinolone acetonide implant for intermediate, posterior, and panuveitis: The multicenter uveitis steroid treatment trial. *Ophthalmology* 2011;118:1916-26.
22. Lowder C, Belfort R Jr, Lightman S, Foster CS, Robinson MR, Schiffman RM, *et al.* Ozurdex HURON study group. Dexamethasone intravitreal implant for noninfectious intermediate or posterior uveitis. *Arch Ophthalmol* 2011;129:545-53.
23. Ghosn CR, Li Y, Orilla WC, Lin T, Wheeler L, Burke JA, *et al.* Treatment of experimental anterior and intermediate uveitis by a dexamethasone intravitreal implant. *Invest Ophthalmol Vis Sci* 2011;52:2917-23.

**Cite this article as:** Murthy SI, Pappuru RR, Latha KM, Kamat S, Sangwan VS. Surgical management in patient with uveitis. *Indian J Ophthalmol* 2013;61:284-90.

**Source of Support:** Nil. **Conflict of Interest:** None declared.