

# Bedside placement of small-bowel feeding tube in Intensive Care Unit for enteral nutrition

Antara Gokhale, Sandeep Kantoor, Sadanandan Prakash, Yogesh Manhas, Juhi Chandwani, Ashraf Ezzat Mahmoud

## Abstract

Enteral nutrition is the preferred mode of nutrition in critically ill patients whenever feasible as it has a number of advantages over parenteral feeding. Both gastric and small-bowel feeding can effectively deliver calories. In patients with gastroparesis, small-bowel feeding can help avoid parenteral feeding. We carried out a retrospective observational study to assess the ability to insert the Tiger 2 tube into the small bowel at the bedside in 25 patients who failed to tolerate gastric feeds. The time taken, rate of successful insertion, and ability to feed these patients using a standardized feeding protocol were noted. Success rate of insertion was 78% and feeding could be established. This method reduced the delays and risks associated with transportation and dependence on other specialties.

**Keywords:** Bedside placement, postpyloric feeds, Tiger 2 tube

## Access this article online

**Website:** [www.ijccm.org](http://www.ijccm.org)

**DOI:** 10.4103/0972-5229.183909

**Quick Response Code:**



## Introduction

Adequate nutrition is of vital importance in the critically ill patients to decrease the mortality and morbidity in the Intensive Care Unit (ICU).<sup>[1]</sup> Patients expected to stay in ICU for more than 3 days without adequate oral intake should be started on nutrition supplement preferably through enteral route.<sup>[2]</sup> Both gastric and small-bowel feeds are equally efficient.<sup>[2]</sup> Gastric feeding is routinely started as insertion of feeding tube is easy. However, it is not tolerated in a subset of patients as indicated by high residual volume. Small-bowel feeding was started in such patients to avoid parenteral feeding and its associated complications using a predesigned tube, Tiger 2 tube. This was introduced at the bedside by the attending staff. The ease of insertion, success rate of placement, and the duration in indicated cases were retrospectively analyzed.

## Case Report

A retrospective observational study was carried out over a 3-year period from 2012 to 2015 in a 13-bedded

adult ICU of a tertiary care hospital with mixed patient population. All patients expected to stay in the ICU for more than 1 week and eligible for enteral nutrition were included. Patients who had adequate oral intake or were planned for parenteral nutrition were excluded from the study.

Enteral feeds were started in these patients after adequate stabilization with gastric feeding tubes using standardized feeding formulas according to the feeding protocol in the unit [Figure 1]. The aim was to achieve 80% of target calories (20–25 kcal/kg/day) over the next 72 h. Gastric residual volume (GRV) was checked at 4 h interval. Metoclopramide 10 mg intravenous TID was started as prokinetic if GRV was more than 200 ml. Small-bowel feeding was started in cases where the GRV continued to be high despite using two doses of prokinetic agent and when the target calories were not

This is an open access article distributed under the terms of the Creative Commons Attribution-NonCommercial-ShareAlike 3.0 License, which allows others to remix, tweak, and build upon the work non-commercially, as long as the author is credited and the new creations are licensed under the identical terms.

## From:

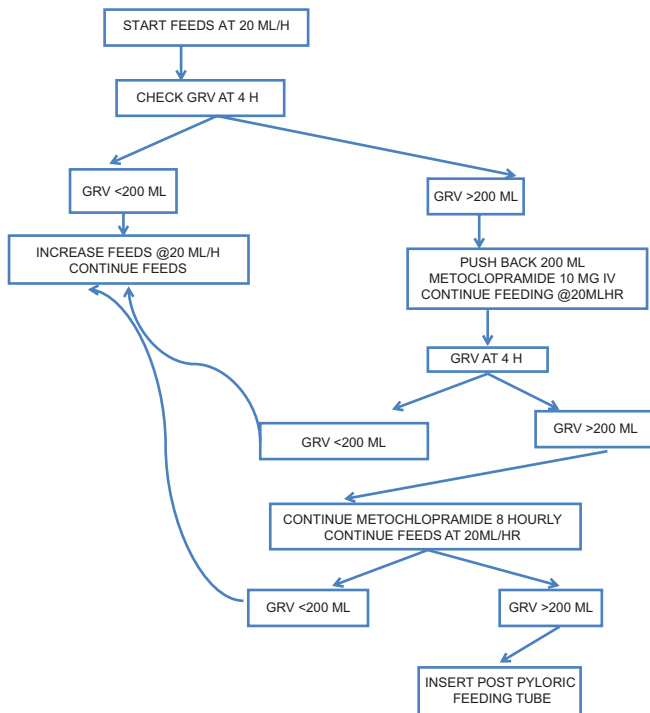
Department of Anesthesia and Adult Intensive Care Unit, Royal Hospital, Muscat, Oman

## Correspondence:

Dr. Antara Gokhale, P.O. Box 1076, PC-130, Azaiba, Muscat, Oman.  
E-mail: [gokhaleantara@gmail.com](mailto:gokhaleantara@gmail.com)

**For reprints contact:** [reprints@medknow.com](mailto:reprints@medknow.com)

**How to cite this article:** Gokhale A, Kantoor S, Prakash S, Manhas Y, Chandwani J, Mahmoud AE. Bedside placement of small-bowel feeding tube in Intensive Care Unit for enteral nutrition. *Indian J Crit Care Med* 2016;20:357-60.



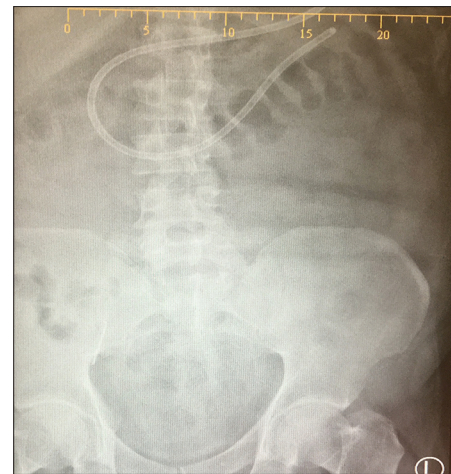**Figure 1:** Feeding protocol. Prerequisites: (i) Enteral feeding possible, (ii) resuscitation completed, (iii) feeding tube inserted and position confirmed with X-ray, (iv) calculate the desired calories, (v) achieve 80% of target at 72 h

achieved. We used the Tiger 2 tube which is available in our unit. 12F and 14F tubes made of silicone and 150 cm in length were introduced after adequate lubrication nasally or orally. The Tiger tube has claw-like extension which helps in forward propulsion of the tube with peristalsis, helps anchorage, and prevents retrograde migration.

The tube was inserted up to 50–55 cm into the stomach. Its position was confirmed by pushing air using syringe and auscultation over the epigastrium. X-ray was taken only if there was doubt about the position of tube. The tube was gradually pushed by 10 cm/h by the attending nurse till 100 cm. The patient's position was not changed specifically for the procedure. Tube position was confirmed with X-ray abdomen [Figures 2 - 5]. Tip of the tube crossing the midline over the vertebral column at lumbar region indicated its presence in the small bowel. Subsequently, the feeding was started as per the protocol to achieve the desired calories. Patients were observed for abdominal distension, bloating, pain, and diarrhea.

The success rate of insertion, ease of placement of the tube, time taken for insertion, confirmation of the tube's position, and the time taken to start feeding were noted.

If the tube was not in the desired position, it was withdrawn back to 55 cm and the procedure repeated



**Figure 2:** Image of abdominal X-rays showing successful placement of small-bowel feeding tubes

once again. On failing at the second attempt, procedure was abandoned and endoscopic insertion was planned at the earliest.

Small-bowel tubes were inserted in 25 patients during 3 years. The male:female ratio is 12:13. Eighteen patients had medical ailment and seven had surgical indications for ICU admission. Feeding tube was inserted in the first attempt in 18 patients with exception of one which required second attempt. Endoscopic placement was successfully attempted in 4 of 6 patients where manual placement had failed. The cases where tube placement failed are listed in Table 1.

Total time taken from start for insertion to the final planned level ranged from 4½ to 9 h. The duration required to confirm tube position by abdominal X-ray was also noted. Delay in obtaining X-ray lead to delay in initiation of feeding. The time taken for initiation of feeding ranged from 8 to 13 h with an average of 11 h. No immediate postprocedure complication was noted. Enteral feeds could be instituted in all 19 patients. Target feeds could not be achieved in three patients, in two due to raised intra-abdominal pressure, and in one due to nonosmotic diarrhea. The rate of successful insertion was 78% and the ability to achieve desired feeding target was in 60% of these cases [Table 2].

## Discussion

Adequate caloric intake in the critically ill patients has shown to decrease ICU mortality and morbidity.<sup>[1]</sup> All leading nutritional bodies recommend early enteral feeding whenever feasible, after adequate resuscitation.<sup>[2]</sup> Enteral nutrition offers a number of advantages over parenteral nutrition. Inability to achieve the target

**Table 1: Cases where small-bowel tube insertion failed**

Acute necrotizing pancreatitis with ileus
Antineutrophil cytoplasmic antibodies-positive vasculitis with abdominal distension
Open abdomen postpancreatic bed necrosectomy
Gastric distension with paresis postlaparotomy
Post-operative case of hepato-jejunostomy for common bile duct leak
Retroperitoneal inflammatory mass due to pancreatitis

**Table 2: Results**

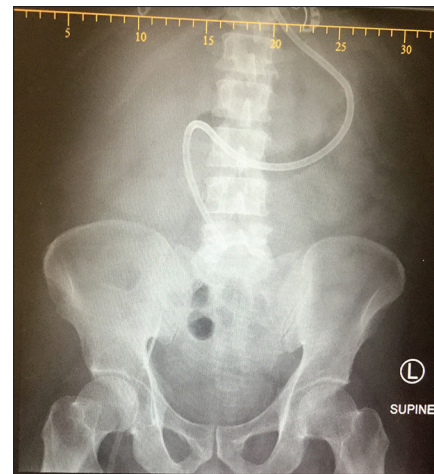Total cases	25
Male:female	12:13
Medical:surgical	19:6
Success rate of manual insertion (%)	78
Success in first attempt (%)	72
Success with endoscopy (%)	5/6
Immediate postprocedure complication	Nil
Target feeds achieved	16/19

calories by 7 days warrants supplementation with parenteral feeds partially or completely. Feeds can be introduced in the stomach, duodenum, or jejunum to provide nutritional benefits.<sup>[3,4]</sup> Postpyloric feeds reduce the risk of nosocomial pneumonia, aspiration, and vomiting significantly as shown recently by a meta-analysis.<sup>[4]</sup> Gastric feeding is the preferred mode in our unit due to the ease of insertion of the tubes.

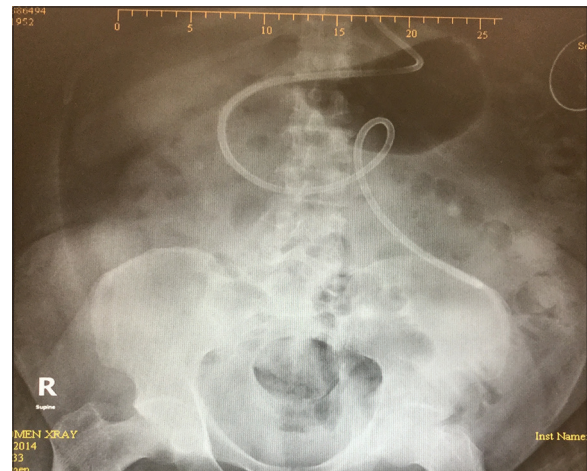The number of patients in our study is small as postpyloric feeding was considered only after adequate trial of gastric feeds. Small-bowel feeding is required in a subset of ICU patients who develop gastroparesis with high GRV due to underlying condition-burns, pancreatitis, postoperative patients, and neuroendocrine dysfunction or the effect of medications.<sup>[5]</sup>

Postpyloric feeding tubes are smaller in size (8–12F) and tend to get blocked or displaced. Successful insertion has facilitated at the bedside using stylet, positioning the patient in right lateral position, using prokinetics, and insertion under fluoroscopy or by endoscopy.<sup>[3]</sup> X-ray to confirm tip position before initiation of feeds is essential.<sup>[6]</sup>

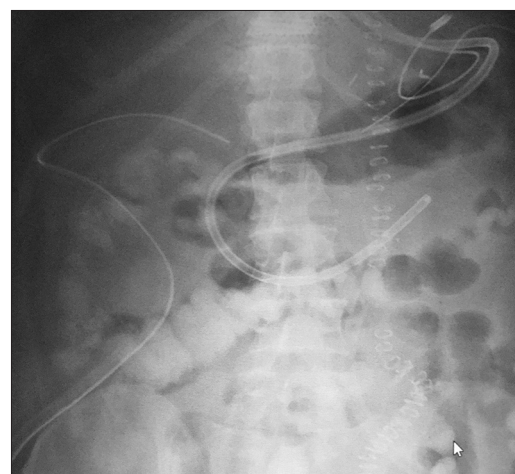The role of prokinetic to facilitate placement of postpyloric tubes is debatable.<sup>[7,8]</sup> Since the use of metoclopramide as a prokinetics is a part of our feeding protocol, all patients with high GRV received at least two doses of this medications before small-bowel feeding tubes were considered. Although a GRV up to 500 ml can be acceptable without the fear of aspiration according to clinical studies, we accepted GRV of 200 ml to interrupt the feeding as our unit has a nurse-driven protocol.<sup>[9]</sup>



**Figure 3:** Abdominal X-ray showing postpyloric feeding tube in patient with high residual gastric volume



**Figure 4:** Abdominal X-ray showing postpyloric feeding tube in case of ileus



**Figure 5:** Abdominal X-ray in post laparotomy patient with postpyloric feeding tube

Endoscopic insertion is considered the gold standard for insertion of postpyloric feeding tubes with high

success rate in expert hands. However, tube dislodgment after placement and trauma can occur. Insertion can be delayed as it depends on availability of the endoscopy team. Insertion under fluoroscopy requires shifting the critically ill patients out of the ICU to remote areas and involves manpower and patient safety issues. Both these methods use nonclawed, smaller sized tubes. In our method, no additional manpower or resources are required and avoids unnecessary delays.<sup>[6,10]</sup>

Only one X-ray was taken in most of the cases except one where insertion was successful in first attempt. One of the major causes of delay in initiating feeds was the time required to obtain the confirmatory X-ray which depends on availability of radiographer.

The success rate in various studies using different methods and tubes varies from 62% to 95%. Our success rate of 78% is in accordance with other studies.<sup>[3,6]</sup> We observed that pancreatitis was the major etiological factor among the unsuccessful cases. Perhaps early initiation of small-bowel feeds would have improved the success rate in these cases.

## Conclusion

Attempt to establish enteral feeding should be made in critically ill patients with a functional gut. Bedside placement of small-bowel feeding tube facilitates enteral feeding in patients with failed gastric feeding, thus reducing the need for parenteral nutrition and its associated complications. The procedure is simple and can be completed by the bedside staff. A larger study would be required to show significance of its advantages over endoscopic insertion at the bedside.

## Disclaimer

The Tiger 2 tube was used solely as it was procured by the hospital stores. This study was not intended to promote a particular product.

## Financial support and sponsorship

Nil.

## Conflicts of interest

There are no conflicts of interest.

## References

1. Marik PE, Zaloga GP. Early enteral nutrition in acutely ill patients: A systematic review. *Crit Care Med* 2001;29:2264-70.
2. Kreymann KG, Berger MM, Deutz NE, Hiesmayr M, Jolliet P, Kazandjiev G, *et al.* ESPEN guidelines on enteral nutrition: Intensive care. *Clin Nutr* 2006;25:210-23.
3. Powers J, Chance R, Bortenschlager L, Hottenstein J, Bobel K, Gervasio J, *et al.* Bedside placement of small-bowel feeding tubes in the intensive care unit. *Crit Care Nurse* 2003;23:16-24.
4. Jiyong J, Tiancha H, Huiqin W, Jingfen J. Effect of gastric versus post-pyloric feeding on the incidence of pneumonia in critically ill patients: Observations from traditional and Bayesian random-effects meta-analysis. *Clin Nutr* 2013;32:8-15.
5. Quigley EM. Critical care dysmotility: Abnormal foregut motor function in the ICU/ITU patient. *Gut* 2005;54:1351-2.
6. Blumenstein I, Shastri YM, Stein J. Gastroenteric tube feeding: Techniques, problems and solutions. *World J Gastroenterol* 2014;20:8505-24.
7. Heiselman DE, Hofer T, Vidovich RR. Enteral feeding tube placement success with intravenous metoclopramide administration in ICU patients. *Chest* 1995;107:1686-8.
8. Hu B, Ye H, Sun C, Zhang Y, Lao Z, Wu F, *et al.* Metoclopramide or domperidone improves post-pyloric placement of spiral nasojejunal tubes in critically ill patients: A prospective, multicenter, open-label, randomized, controlled clinical trial. *Crit Care* 2015;19:61.
9. Montejo JC, Miñambres E, Bordejé L, Mesejo A, Acosta J, Heras A, *et al.* Gastric residual volume during enteral nutrition in ICU patients: The REGANE study. *Intensive Care Med* 2010;36:1386-93.
10. Rafferty GP, Tham TC. Endoscopic placement of enteral feeding tubes. *World J Gastrointest Endosc* 2010;2:155-64.