


CASE REPORT

Open Access



Concomitant uveal melanoma and papillary thyroid carcinoma: a case report

Seiiedeh Samaneh Taghian Jamaledin Kolaii¹, Amir Reza Dehghanian² and Marjan Jeddi^{1,3*} 

Abstract

Background: Melanoma develops in the cells that produce melanin; ocular melanoma accounts for 3–4% of all malignant melanomas. Thyroid tumors are the most common endocrine neoplasms, with more than 95% of cases arising from follicular cell origin. Previous studies have reported associations between malignant melanoma and a wide variety of malignancies.

Case presentation: We report a 54-year-old Iranian woman who was diagnosed with ocular melanoma based on a mushroom-shaped filling defect with homogeneous echo pattern arising from the anterior third of the temporal side of the globe detected on ocular sonography during routine ophthalmological examination. She underwent right globe enucleation and implant replacement. During tumor surveillance, fluorodeoxyglucose positron emission tomography/computed tomography scan showed low-grade metabolically active tumoral involvement in the anterolateral aspect of the right lobe of thyroid. The patient subsequently underwent thyroidectomy and submandibular lymphadenectomy. Pathologic report demonstrated micropapillary carcinoma (9 × 8 mm²), tall cell variant without lymphovascular or perineural invasion in the base of lymphocytic thyroiditis.

Conclusion: This case illustrates the importance of precise active surveillance in case of papillary carcinoma of thyroid or malignant melanoma to avoid missing other associated pathologies and emphasizes the simultaneous treatment of two tumors.

Keywords: Ocular, Melanoma, Papillary thyroid cancer, Case report

Background

Melanoma is a type of cancer that develops from melanin-producing cells, which can arise in the eyes. Ocular melanoma accounts for 3–4% of all malignant melanomas [1]. There are two major subtypes of ocular melanoma: uveal melanoma, which arise from the iris, choroid, and ciliary body, and conjunctival melanoma, whose origin is the conjunctiva [2]. This malignant tumor can potentially disperse through the body and cause distant metastasis, most often in the liver [3].

Thyroid tumors are the most common endocrine neoplasms. More than 95% of them develop from follicular cell origin. In patients with widespread malignancy, bloodborne metastases to the thyroid are reported in 0.5–24.2% in autopsy studies, but these metastatic lesions are rarely detectable clinically [4].

There are some reports of associations between malignant melanoma and other malignancies, including second primary melanoma, nonmelanoma skin cancer, central nervous system tumors, Hodgkin's lymphoma, non-Hodgkin's lymphoma, leukemia, breast, and ovarian carcinoma [5]. Ozgun *et al.* reported a case with malignant melanoma and papillary thyroid carcinoma diagnosed concurrently and treated simultaneously [6].

*Correspondence: jedim@sums.ac.ir

¹ Endocrinology and Metabolism Research Center, Shiraz University of Medical Sciences, Shiraz, Iran

Full list of author information is available at the end of the article



© The Author(s) 2022. **Open Access** This article is licensed under a Creative Commons Attribution 4.0 International License, which permits use, sharing, adaptation, distribution and reproduction in any medium or format, as long as you give appropriate credit to the original author(s) and the source, provide a link to the Creative Commons licence, and indicate if changes were made. The images or other third party material in this article are included in the article's Creative Commons licence, unless indicated otherwise in a credit line to the material. If material is not included in the article's Creative Commons licence and your intended use is not permitted by statutory regulation or exceeds the permitted use, you will need to obtain permission directly from the copyright holder. To view a copy of this licence, visit <http://creativecommons.org/licenses/by/4.0/>. The Creative Commons Public Domain Dedication waiver (<http://creativecommons.org/publicdomain/zero/1.0/>) applies to the data made available in this article, unless otherwise stated in a credit line to the data.

The present study reports another case of this rare co-occurrence of malignant melanoma and papillary thyroid carcinoma, which were treated simultaneously.

Case presentation

A 54-year-old Iranian woman, married, resident in Shiraz, Fars Province in the south of Iran, referred to the ophthalmologist for routine eye examination. Her past medical history included only type II diabetes mellitus treated with 1000 mg metformin and 50 mg sitagliptin daily. The patient's social history was negative for cigarette smoking or alcohol use. Her family history for malignancy was negative.

Due to suspicious lesion on dilated eye examination by ophthalmologist, sonography was requested. Sonographer reported a mushroom-shaped filling defect with homogeneous echo pattern arising from the anterior third of the temporal side of the globe wall, suggestive of melanoma; this $10 \times 9.8 \text{ mm}^2$ lesion could arise from the ciliary body and the choroid.

In tumor surveillance, thoracic and abdominal CT scan with IV contrast were normal. FDG-PET/CT scan showed low-grade metabolically active tumoral involvement in the anterolateral aspect of the right lobe of thyroid as well as hypermetabolic lymphadenopathy at cervical zone VI (Fig. 1).

Right globe enucleation and implant replacement was performed for the patient; pathologic report revealed $9 \times 10 \text{ mm}^2$ malignant melanoma in choroid anterotemporal area with 0–1 mitotic area per 10 high-power fields (HPF) and involvement of anterior chamber and focal retina. Histologic type was mixed epitheloid (25%) and spindle cell melanoma (75%). Tumor cells were positive for HMB45 and Melan A. According to the AJCC 8th edition, tumor was T3aN0M0, G1, at least stage IIB (Fig. 2).

High-resolution ultrasonography of the neck soft tissue revealed normal thyroid gland without any sign of solid or cystic lesion, and a suspicious enlarged significant hypoechoic lymph node measuring about $12 \times 12 \text{ mm}^2$ in the right jugular chain at zone II. Sonography-guided fine-needle aspiration biopsy of this lesion revealed some clusters of malignant looking cells with high N/C ratio, hyperchromasia, and a few nuclear inclusions, suggestive of malignancy.

At this time, right-side parotidectomy and fascial nerve trunk exploration and right-side modified neck dissection was performed.

Pathologic report showed parotid gland without specific pathologic change, and seven lymph node labeled as level II and III; and four lymph node labeled as level IV, which were all reactive lymph nodes without evidence of malignancy.

One month later, high-resolution ultrasonography of the thyroid and neck showed an oval-shaped hypoechoic structure measuring 13 mm in right para tracheal area attached or invading right border of thyroid capsule with central echogenic hilum and central internal hypervascularity, which seems to be metastatic or suspicious lymph node.

The patient subsequently underwent thyroidectomy and submandibular lymphadenectomy. Pathologic report demonstrated micropapillary carcinoma ($9 \times 8 \text{ mm}^2$), tall cell variant without lymphovascular or perineural invasion in the base of lymphocytic thyroiditis. One tissue labeled as right cervical lymph node revealed soft tissue with chronic inflammation and foreign body giant cell reaction (Fig. 3). Postoperative ultrasonography of the neck did not show any evidence of lymphadenopathy.

Seventy-five days after thyroidectomy, 125-mCi I-131 was administered to the patient, who was off levothyroxine for 4 weeks. Whole-body scan after 7 days showed evidence of thyroid remnant and possibility of cervical lymph node involvement without evidence of distant metastases (Fig. 4). At time of iodine administration, she had TSH $>100 \text{ mIU/ml}$, thyroglobulin $<0.04 \text{ ng/ml}$, and negative antithyroglobulin antibody. Eight months later, whole-body scan 2 days after oral administration of 5-mCi I-131 did not show any evidence of abnormal radioiodine-avid lesion throughout the body. At time of iodine administration, she had TSH $>100 \text{ mIU/ml}$, thyroglobulin $<0.2 \text{ ng/ml}$, and negative antithyroglobulin antibody. At this time, the patient is in good health state and takes levothyroxine with daily dose of 125 μg .

Discussion

Malignant melanoma is reported to be associated with second primary malignancies such as prostate, soft tissue, salivary gland, and musculoskeletal cancers [7]. Although thyroid carcinoma is not a common secondary malignancy in melanoma, it is shown that its risk increases 2.17-fold among patients with malignant melanoma [8]. On the other hand, papillary carcinoma of thyroid increases the risk of melanoma by 1.8-fold [9].

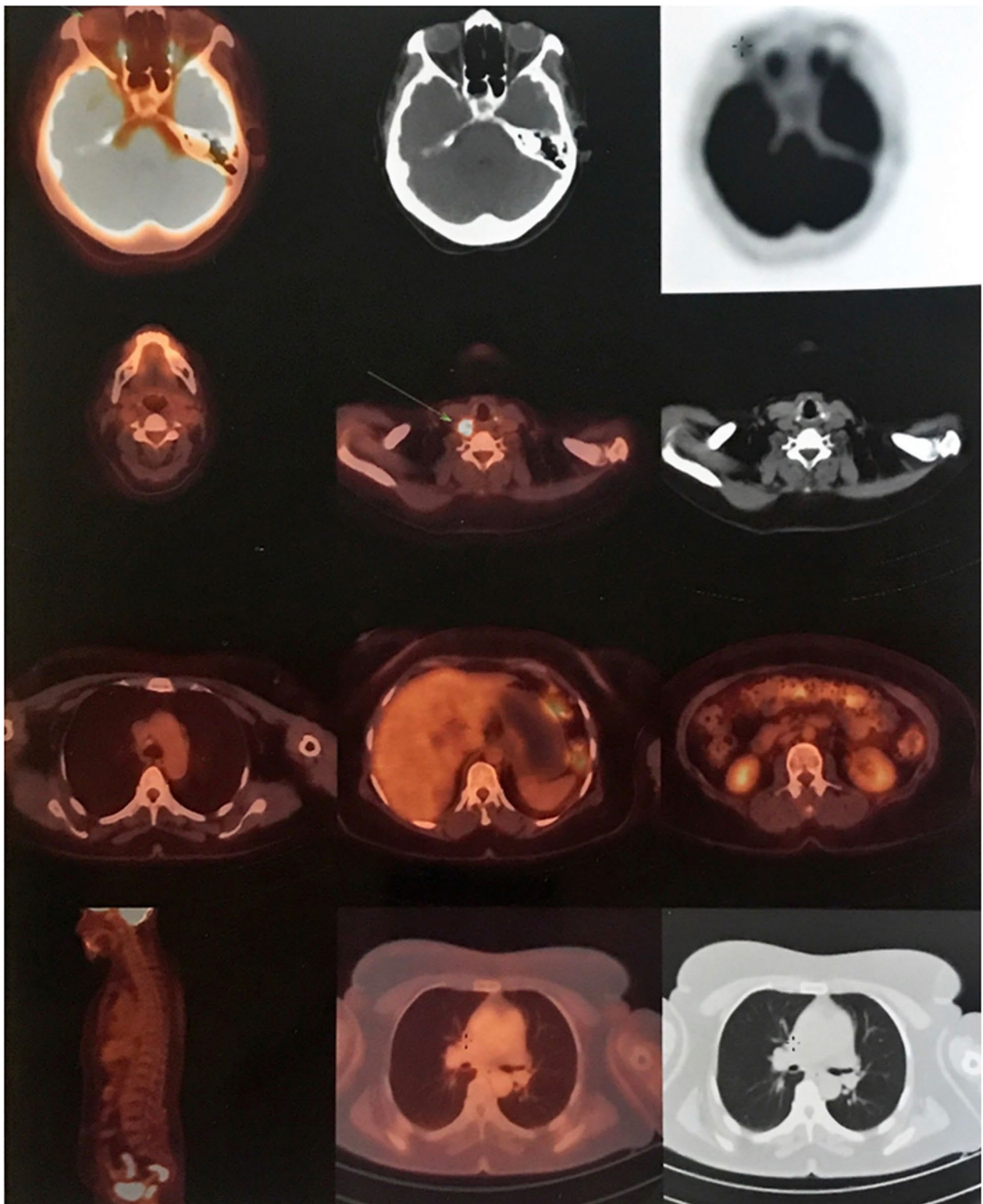


Fig. 1 FDG-PET/CT scan: low-grade metabolically active tumoral involvement in the anterolateral aspect of the right lobe of thyroid as well as hypermetabolic lymphadenopathy at cervical zone VI

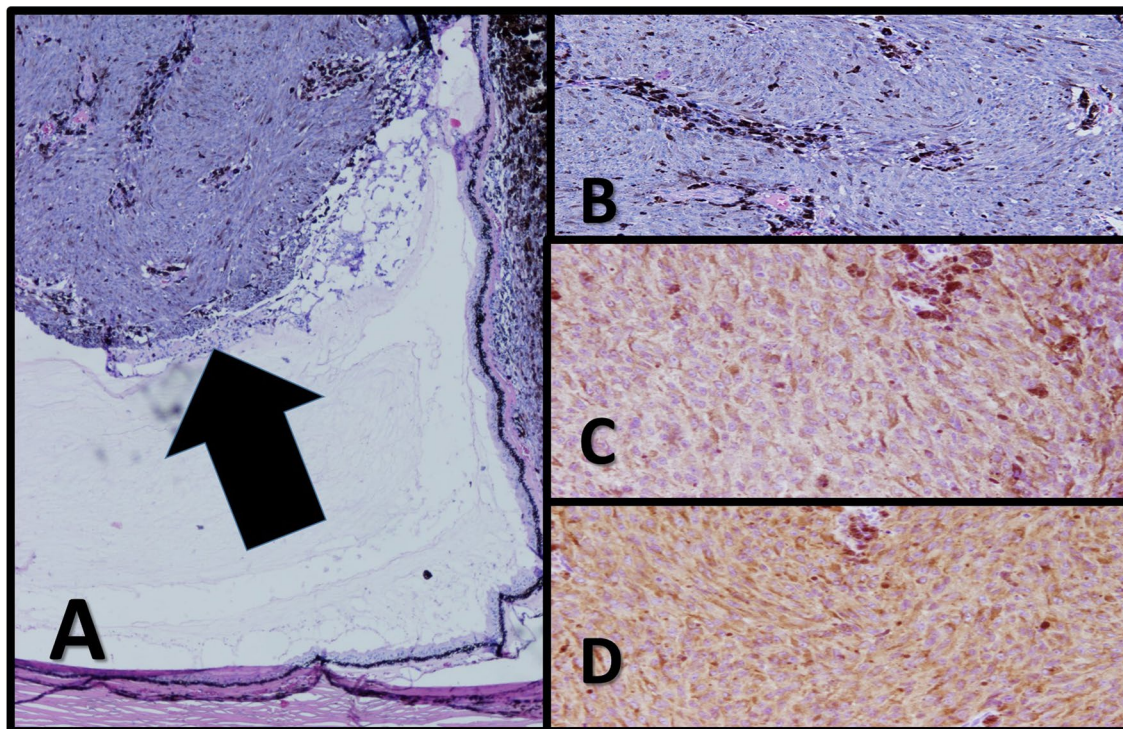


Fig. 2 Histopathology of the uveal tumor. **A, B** Histopathological sections show a mushroom-shaped tumoral process (arrow) arising from retina composed of highly pleomorphic plump spindle cells with some dense melanin pigments in the background. Individual cells show high degree of nuclear atypia with prominent nucleoli. Tumor infiltrating lymphocyte and macrophage is less than 5%. Vessels show loop pattern ($\times 40$, $\times 100$ H&E). **C, D** Immunohistochemical staining of the tumor shows diffuse, strong immunoreactivity for Melan-A and HMB-45 ($\times 100$, $\times 100$)

Various probable mechanisms have been described for an association between papillary thyroid carcinoma and melanoma. Thyroid stimulating hormone (TSH), which is increased in thyroid failure, can stimulate melanocyte growth and division via TSH receptors on their surface [10]. Recent studies have revealed that coincidence of thyroid papillary carcinoma and malignant melanoma is associated with *BRAF* gene mutation. *BRAF* gene is associated with aggressive subtypes. In a review on the role of *BRAF* in pathogenesis of papillary thyroid carcinoma and cutaneous melanoma, Mitchell *et al.* concluded that the BRAF protein acts as a catalyst for epithelial–mesenchymal transition in both malignancies [11]. Detection of this mutation is important since BRAF inhibitor medications such

as vemurafenib and dabrafenib can be useful in their treatment [12]. Another mutation that is reported to increase the risk of uveal melanoma and thyroid carcinoma is BRCA-1 associated protein (BAP1). This mutation is found more among families with familial cancer syndrome [13].

Although papillary thyroid carcinoma and malignant melanoma can occur with a time interval similar to our case, they have presented simultaneously in some cases where they were treated together [6, 14]. Previous studies reported cases of concomitant cutaneous malignant melanoma and papillary thyroid carcinoma. However, in our case, the origin of the malignant melanoma was the ciliary body and the choroid tissue.

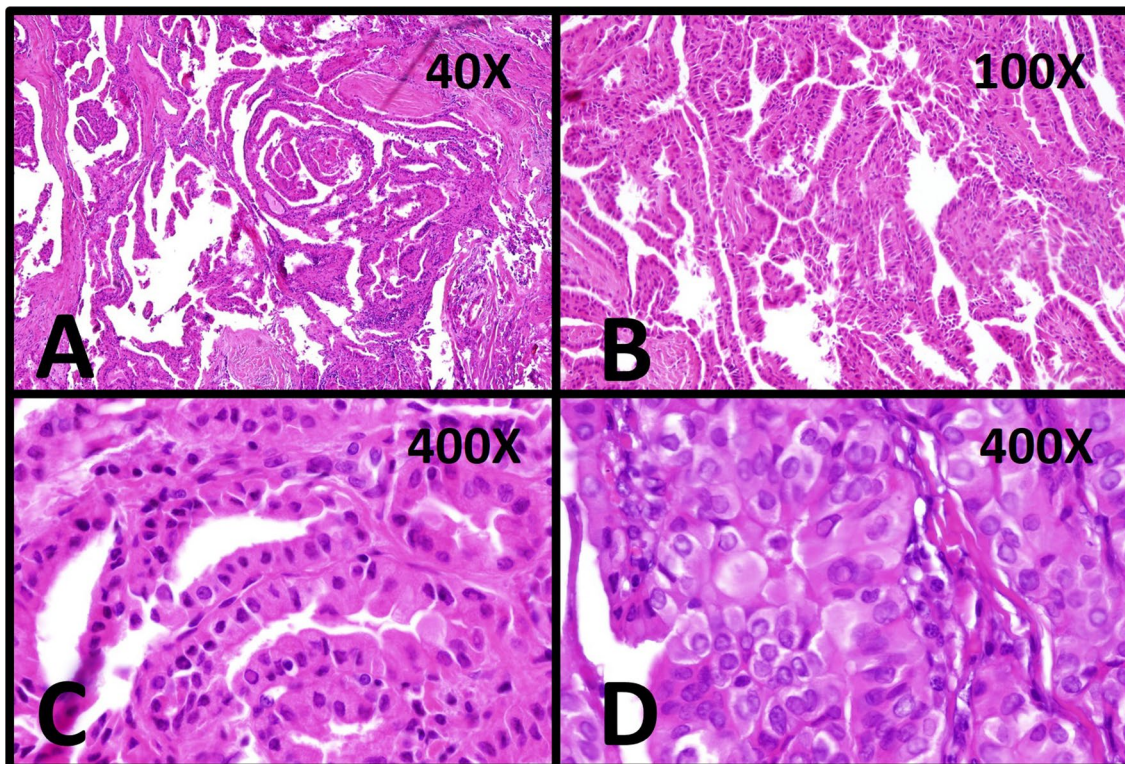


Fig. 3 Histopathology features of the thyroid tumor: **A, B** Histopathological sections show papillary architecture with minimal stromal lymphocytic infiltration and fibrous bandings (H&E stained, $\times 40$, $\times 100$). **C, D** Each papillae lined with columnar epithelium with round to oval nuclei with relatively clear chromatin and nuclear pseudoinclusions (arrows) sufficient for diagnosis of conventional-type papillary thyroid carcinoma (H&E stained, $\times 400$, $\times 400$)

It is worth mentioning that malignant melanoma can show similar pathologic features as papillary carcinoma of thyroid, with a pseudopapillary appearance, which is formed by cuffs of tumor cells surrounding stromal vessels [15, 16]. There are several studies reporting misdiagnosis and consequently mismanagement of such cases. It is thus important to distinguish these two pathologies, especially in case of amelanotic malignant melanoma with papillary features using immunohistochemical tests. One of the rare differential diagnoses of thyroid mass following malignant melanoma is metastasis, which was reported before

in a 63-year-old man [17]. Therefore, it is crucial to identify the nature of the mass carefully.

Conclusion

There is some evidence in favor of associations between malignant melanoma and a wide variety of malignancies, including papillary thyroid carcinoma. Our patient demonstrated these two cancers concomitantly. This case illustrates the importance of precise active surveillance in case of papillary carcinoma of thyroid or malignant melanoma to avoid missing other associated pathologies.

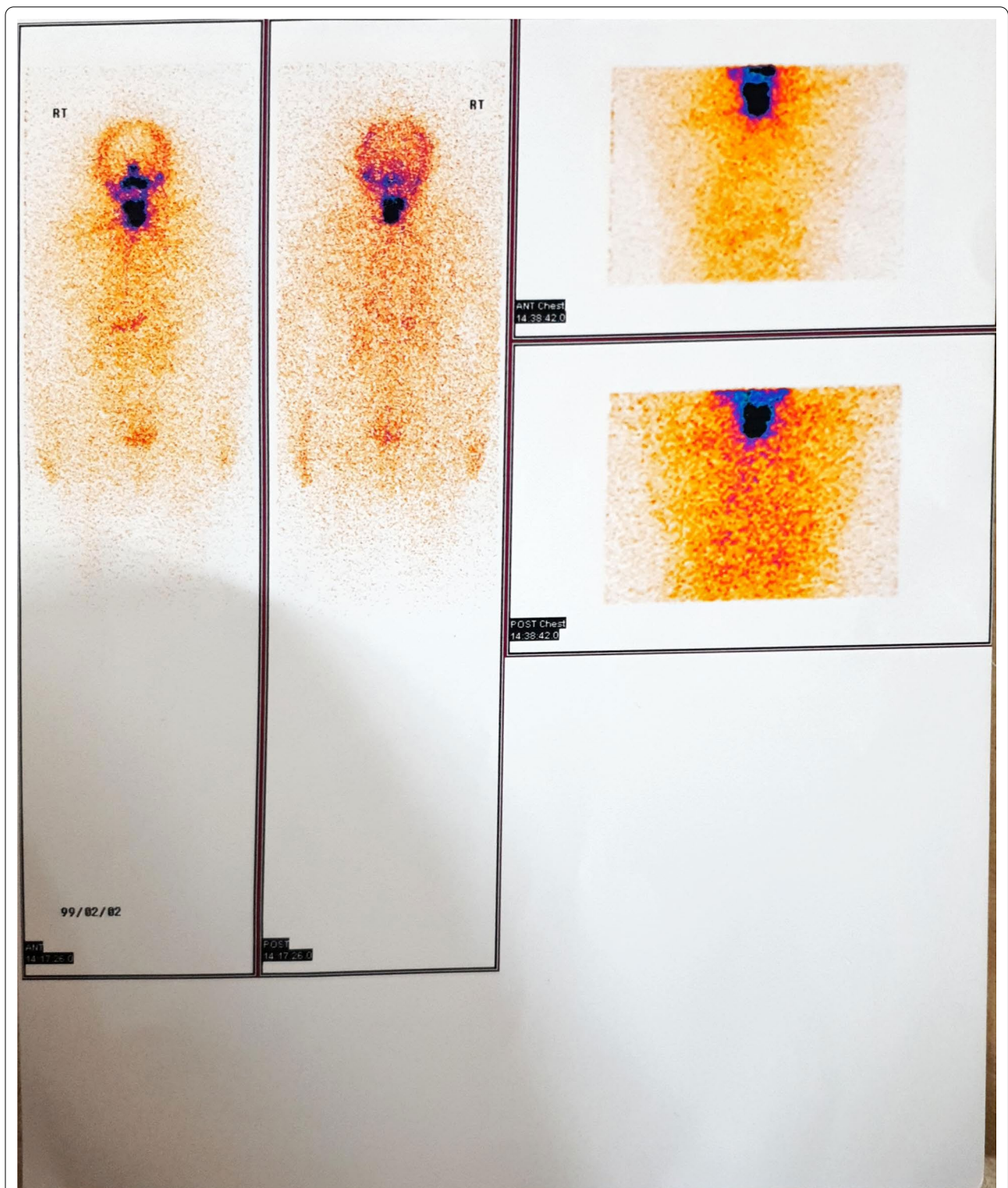


Fig. 4 Whole-body I-131 scan: evidence of thyroid remnant and possibility of cervical lymph node involvement without evidence of distant metastases

In addition, it should be considered that the treatment of either tumor should not be delayed and the two tumors can be treated simultaneously.

Acknowledgements

Not applicable.

Authors' contributions

ST and MJ analyzed and interpreted the patient data regarding the thyroid disease and its management. ARD performed the histological examination of the orbit, and thyroid and was a major contributor in writing the manuscript. All authors read and approved the final manuscript.

Funding

The authors did not receive support from any organization for the submitted work.

Availability of data and materials

The datasets used and analyzed during the present study are available from the corresponding author on reasonable request.

Declarations

Ethics approval and consent to participate

The Ethics Committee of the Shiraz University of Medical Science approved this study. The study protocol conformed to the ethical guidelines of the 1975 Helsinki Declaration. Written, informed consent was obtained from the patient.

Consent for publication

Written informed consent was obtained from the patient for publication of this case report and any accompanying images. A copy of the written consent is available for review by the Editor-in-Chief of this journal.

Competing interests

The authors have no competing interest to declare that are relevant to the content of this article.

Author details

¹Endocrinology and Metabolism Research Center, Shiraz University of Medical Sciences, Shiraz, Iran. ²Molecular Pathology and Cytogenetics Division, Department of Pathology, Shiraz University of Medical Sciences, Shiraz, Iran. ³Endocrinology and Metabolism Research Center, Nemazee Hospital, Shiraz University of Medical Sciences, Postal Box: 71345-1414, Shiraz, Iran.

Received: 28 April 2021 Accepted: 6 December 2021

Published online: 18 January 2022

References

- McLaughlin CC, Wu XC, Jemal A, Martin HJ, Roche LM, Chen VW. Incidence of noncutaneous melanomas in the US. *Cancer*. 2005;103(5):1000–7.
- Mahendraraj K, Shrestha S, Lau CS, Chamberlain RS. Ocular melanoma—when you have seen one, you have not seen them all: a clinical outcome study from the Surveillance, Epidemiology and End Results (SEER) database (1973–2012). *Clin Ophthalmol* (Auckland, NZ). 2017;11:153.
- Grossniklaus HE, Zhang Q, You S, McCarthy C, Heegaard S, Coupland SE. Metastatic ocular melanoma to the liver exhibits infiltrative and nodular growth patterns. *Hum Pathol*. 2016;57:165–75.
- Lam K, Lo C. Metastatic tumors of the thyroid gland: a study of 79 cases in Chinese patients. *Arch Pathol Lab Med*. 1998;122(1):37.
- Bhatia S, Estrada-Batres L, Maryon T, Bogue M, Chu D. Second primary tumors in patients with cutaneous malignant melanoma. *Cancer*. 1999;86(10):2014–20.
- Ozgun A, Tuncel T, Emirzeoglu L, Celik S, Bilgi O, Haholu A, et al. Malignant melanoma and papillary thyroid carcinoma that were diagnosed concurrently and treated simultaneously: a case report. *Oncol Lett*. 2015;9(1):468–70.
- Spanogle JP, Clarke CA, Aroner S, Swetter SM. Risk of second primary malignancies following cutaneous melanoma diagnosis: a population-based study. *J Am Acad Dermatol*. 2010;62(5):757–67.
- Goggins W, Daniels GH, Tsao H. Elevation of thyroid cancer risk among cutaneous melanoma survivors. *Int J Cancer*. 2006;118(1):185–8.
- Lazzara DR, Zarkhin SG, Rubenstein SN, Glick BP. Melanoma and thyroid carcinoma: our current understanding. *J Clin Aesth Dermatol*. 2019;12(9):39.
- Ellerhorst JA, Sendi-Naderi A, Johnson MK, Cooke CP, Dang SM, Diwan AH. Human melanoma cells express functional receptors for thyroid-stimulating hormone. *Endocr Relat Cancer*. 2006;13(4):1269–77.
- Mitchell B, Dhingra JK, Mahalingam M. BRAF and epithelial–mesenchymal transition: lessons from papillary thyroid carcinoma and primary. *Adv Anat Pathol*. 2016;23(4):244–71.
- Cohn AL, Day B-M, Abhyankar S, McKenna E, Riehl T, Puzanov I. BRAFV600 mutations in solid tumors, other than metastatic melanoma and papillary thyroid cancer, or multiple myeloma: a screening study. *OncoTargets Ther*. 2017;10:965.
- McDonnell KJ, Gallanis GT, Heller KA, Melas M, Idos GE, Culver JO, et al. A novel BAP1 mutation is associated with melanocytic neoplasms and thyroid cancer. *Cancer Genet*. 2016;209(3):75–81.
- Driouch Y, El AS, Chadli A, editors. Malignant melanoma and papillary thyroid carcinoma: a case report. In: 21st European congress of endocrinology; 2019. BioScientifica.
- Orloff LA, Weymuller EA, Flaherty MJ. Papillary thyroid carcinoma mistaken for malignant melanoma: pitfalls in diagnosis. *Head Neck*. 1995;17(2):157–60.
- Yahaya JJ. Primary cutaneous malignant melanoma with papillary features: a case report signifying morphologic diversity in malignant melanoma. *Asian J Case Rep Med Health*. 2019;2(1):1–7.
- Collins DC, Yela R, Horgan N, Power DG. A rare thyroid metastasis from uveal melanoma and response to immunotherapy agents. *Case Rep Oncol Med*. 2016. <https://doi.org/10.1155/2016/6564094>.

Publisher's Note

Springer Nature remains neutral with regard to jurisdictional claims in published maps and institutional affiliations.

Ready to submit your research? Choose BMC and benefit from:

- fast, convenient online submission
- thorough peer review by experienced researchers in your field
- rapid publication on acceptance
- support for research data, including large and complex data types
- gold Open Access which fosters wider collaboration and increased citations
- maximum visibility for your research: over 100M website views per year

At BMC, research is always in progress.

Learn more biomedcentral.com/submissions

