

Received: 2019.02.27
Accepted: 2019.06.06
Published: 2019.09.28

e-ISSN 1941-5923
© Am J Case Rep, 2019; 20: 1427-1433
DOI: 10.12659/AJCR.915941

A Case of Retained Catheter Guidewire Discovered Two Years After Central Venous Catheterization

Authors' Contribution:
Study Design A
Data Collection B
Statistical Analysis C
Data Interpretation D
Manuscript Preparation E
Literature Search F
Funds Collection G

ABCDEF 1 **Nidal Arnous**
EF 2 **Souvonik Adhya**
EF 1 **Biwar Marof**

1 Department of Medicine, University of Maryland Prince George's Hospital Center, Cheverly, MD, U.S.A.
2 Department of Medicine, Ross University School of Medicine, Miramar, FL, U.S.A.


Corresponding Author: Nidal Arnous, e-mail: nidal.arnous@hotmail.com
Conflict of interest: None declared

Patient: Male, 52
Final Diagnosis: Retained guidewire
Symptoms: Knee pain
Medication: —
Clinical Procedure: —
Specialty: General and Internal Medicine

Objective: Unusual clinical course
Background: Retained guidewire is a recognized complication of intravascular interventions. The majority of cases are identified immediately or shortly after the procedure. In rare cases, the guidewire is identified incidentally by X-ray after the procedure. This report presents a rare case of a retained venous guidewire that was discovered two years after central venous catheterization.
Case Report: A 52-year-old African-American man presented with a wire that was emerging from the skin near his right knee. He had undergone a right femoral central venous catheter placement two years previously. Imaging showed that the end of the guidewire was sited at the left pulmonary artery, and was associated with two small broken fragments of wire. During surgery to remove the guidewire, it had become adherent to the pulmonary artery wall. Most of the guidewire was removed, but the portion adherent to the pulmonary artery wall was left in place.
Conclusions: It is very rare for a retained guidewire to be discovered when it protrudes through the skin, two years after central venous catheter placement, as the majority of cases are discovered by physical inspection or imaging following intravascular interventions. Skill and attention in the clinical setting are required to minimize such complications.

MeSH Keywords: Central Venous Catheters • Endovascular Procedures • Foreign-Body Migration

Full-text PDF: <https://www.amjcaserep.com/abstract/index/idArt/915941>

 1938  1  5  14



Background

The use of intravascular interventions, including the use of central venous catheters, has been increasing over time [1]. The main indications for intravascular catheterization included hemodynamic monitoring, fluid and drug administration, parenteral nutrition, and hemodialysis. Intravascular catheterization can be associated with complications that include arterial puncture, bleeding and hematoma formation, pneumothorax, and infection [2–8]. Guidewire retention is a rare, but recognized complication of all intravascular interventions. However, the vast majority of cases are identified immediately, during, or shortly after the procedure [1]. In rare cases, when the guidewire has been retained long after the procedure, it is identified on X-ray or other imaging modalities [9]. It is extremely rare for the guidewire to be discovered protruding externally at a time when the wire has punctured through the vein wall and the overlying skin.

We report a rare and unusual presentation of a retained guidewire that was detected by the patient as it protruded outside the body through the skin of right knee area, two years after placement of a right femoral central venous catheter.

Case Report

A 52-year-old African American man presented with pain and swelling in his right knee for two weeks. He stated he had felt a hard object under his skin, which he initially thought was a hard vein. However, when he applied pressure, a foreign body resembling a wire emerged through the skin of the medial side of the right knee. He started to pull it out and managed to retrieve part of the wire out (about 20 cm), until he felt some resistance and then decided to attend the emergency department.

The patient had a past medical history of coronary artery disease (CAD). Two years previously, cardiac catheterization had been performed at a different institution in another state, without the placement of any stents. He also has a history of hypertension and osteoarthritis and smoked a pack of cigarettes every two days since his teens, drank two beers a day, and frequently used marijuana. The patient's medical records from the other institution were obtained. These previous medical records showed that about two years previously, he had undergone left heart catheterization for recurrent chest pain, with a right femoral central venous catheter placement, which was accessed through the right inguinal area. The findings had shown mild non-occlusive coronary artery disease. One week after central venous catheterization, he had been seen in the emergency department and was diagnosed with transient complete heart block, mild metabolic acidosis, and acute renal failure, with a creatinine of 12 mg/dl, which was

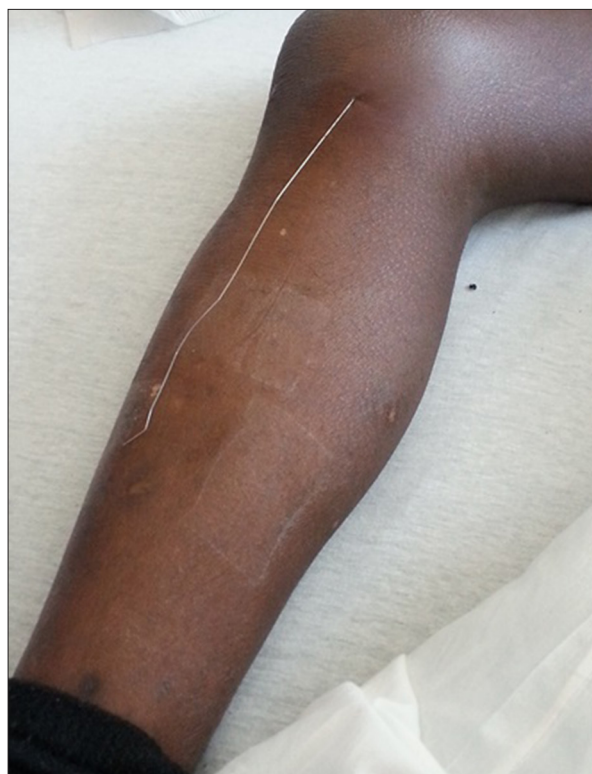

Figure 1. A 52-year-old African-American man who presented with a retained guidewire that was emerging from the skin near his right knee. The guidewire can be seen protruding through the skin from the medial side of the right knee.

raised when compared with the creatinine level of 0.83 mg/dl in the previous week when he underwent coronary angiography. His heart block was believed to have been due to metabolic changes, and he was treated with a single dose of atropine. Transcutaneous pacer pads remained attached to his chest during admission. The medical records also reported that he had difficult intravenous access, and the emergency room attending physician sited a right femoral triple lumen catheter. He was then admitted to the intensive care unit (ICU). His acute renal failure at this time was believed to be due to contrast-induced nephropathy that had developed during cardiac catheterization. His kidney function improved and normalized with medical management, without requiring dialysis. During his stay in the intensive care unit (ICU), a peripherally-inserted central catheter (PICC) was placed by the radiologist in the left arm two days into this admission to try to secure an IV access, and the femoral line was removed. A follow-up chest X-ray confirmed that the tip of the PICC line was in the superior vena cava. No guidewire was noted on this chest X-ray, possibly due to the presence of pacer pads over the chest. In total, the patient had two chest X-rays, one was performed in the emergency department before placing the femoral line, and the second one was performed after placing the PICC line.

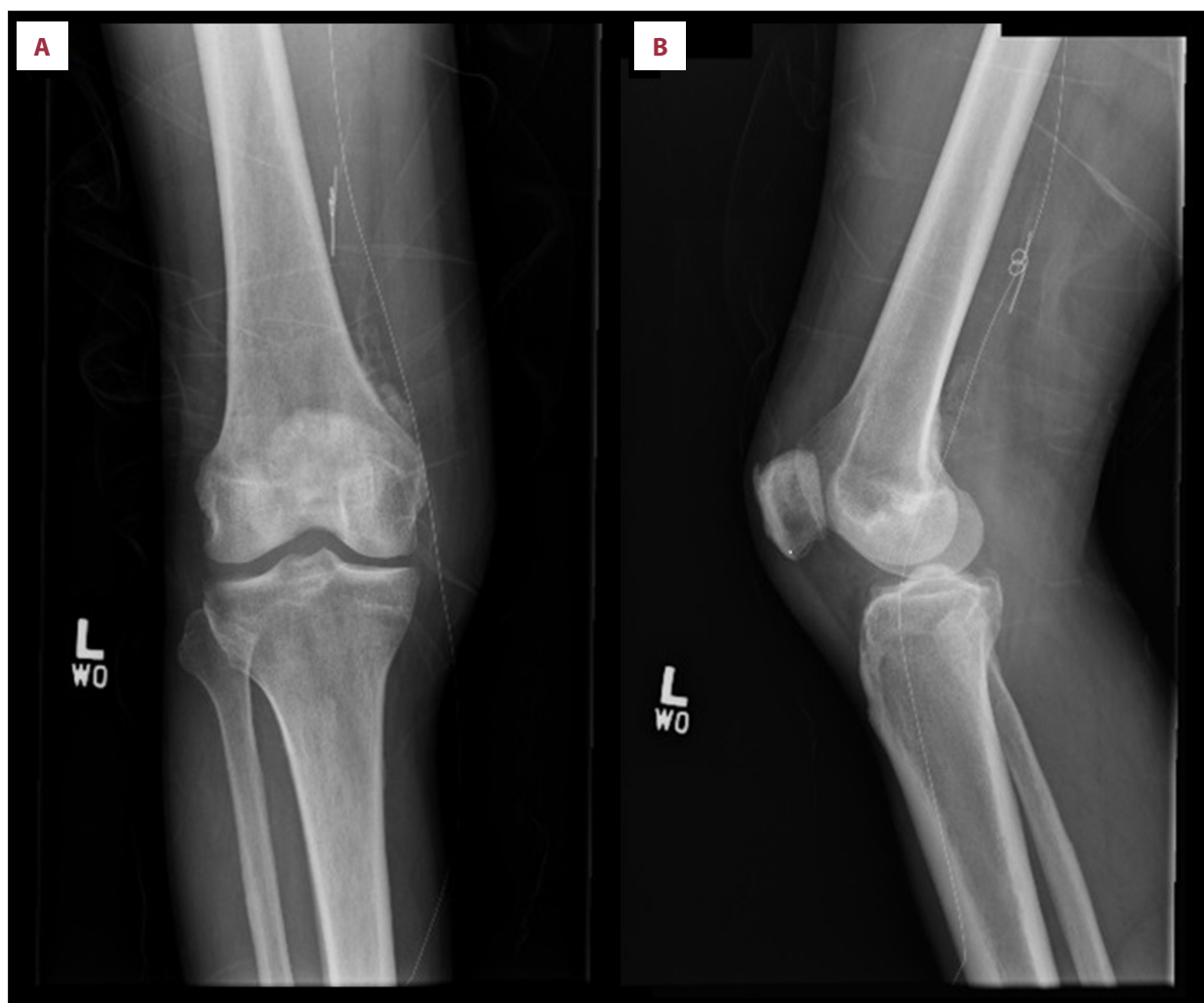

Figure 2. Anteroposterior and lateral X-radiographs of the right knee of a 52-year-old African-American man who presented with a retained venous guidewire. (A) Anteroposterior view and (B) lateral view shows a thin wire extending from the medial side of the right femur.

On the current admission to the emergency department of our institution, physical examination was unremarkable, except for a guidewire that was present protruding out of the skin on the inferior medial side of the right knee area (Figure 1). An X-ray of the right knee was performed, which showed a thin radiopaque wire on the medial side of the knee and femur extending upwards (Figure 2). Foreign material was also noted on the medial aspect of the lower part of the thigh, measuring approximately 2 cm, which appeared to be a coiled wire fragment. Abdominal and chest X-rays showed that the wire extended upwards into the right paravertebral area, with the distal end of the wire ending in the left hilar area (Figure 3). The abdominal and chest X-rays showed that the hook-like distal end of the guidewire (measuring approximately 5.5 cm) had broken off and was located in the inferior vena cava (IVC) at the level of the diaphragm (Figure 3). Computed tomography (CT) imaging of the knee, thigh, pelvis, abdomen, and chest showed

the path of the wire from the knee area, extending up in the thigh in the femoral vein, traveling through the IVC and terminating in the left pulmonary artery (Figures 4, 5). Also, a small piece of the wire was seen in the IVC.

Surgical extraction of the guidewire was performed under fluoroscopic guidance. Venotomy was performed in the right inguinal area where the guidewire was located, and removal was attempted. The wall of the vein had become very thickened. During the attempt at removal, no movement of the guidewire was noted at the level of the left pulmonary artery, and resistance was noted, which suggested that the guidewire was adherent to the pulmonary artery. Because rupture of the left pulmonary artery could have occurred if more force was applied, the extraction procedure was terminated and the outer part of the guidewire was cut and removed. The patient was then discharged home but did not attend follow-up after hospital discharge.

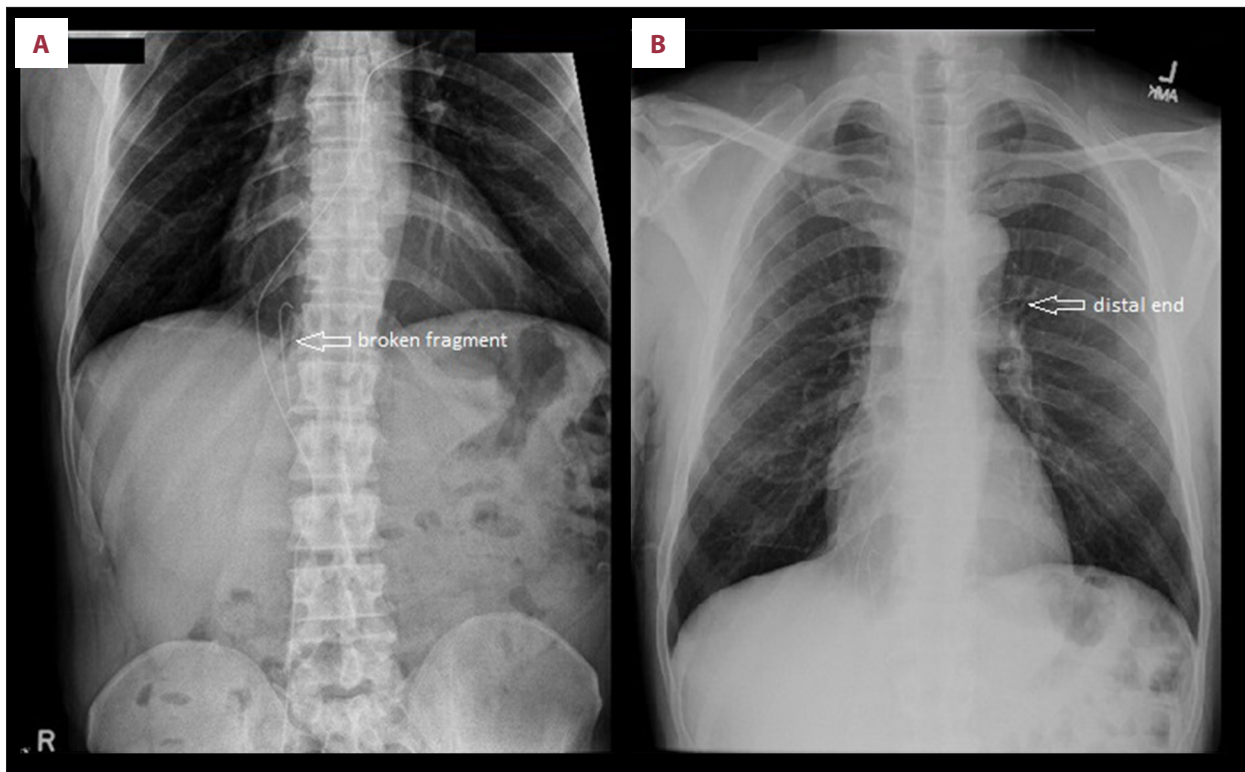


Figure 3. Abdominal and chest X-radiographs of a 52-year-old African-American man who presented with a retained venous guidewire. Abdominal (A) and chest X-radiographs (B) showing the guidewire extending upwards along the right paravertebral area to the level of the heart, ending in the left hilar area (arrow). A broken hook-like fragment is shown at the level of the diaphragm (arrow).

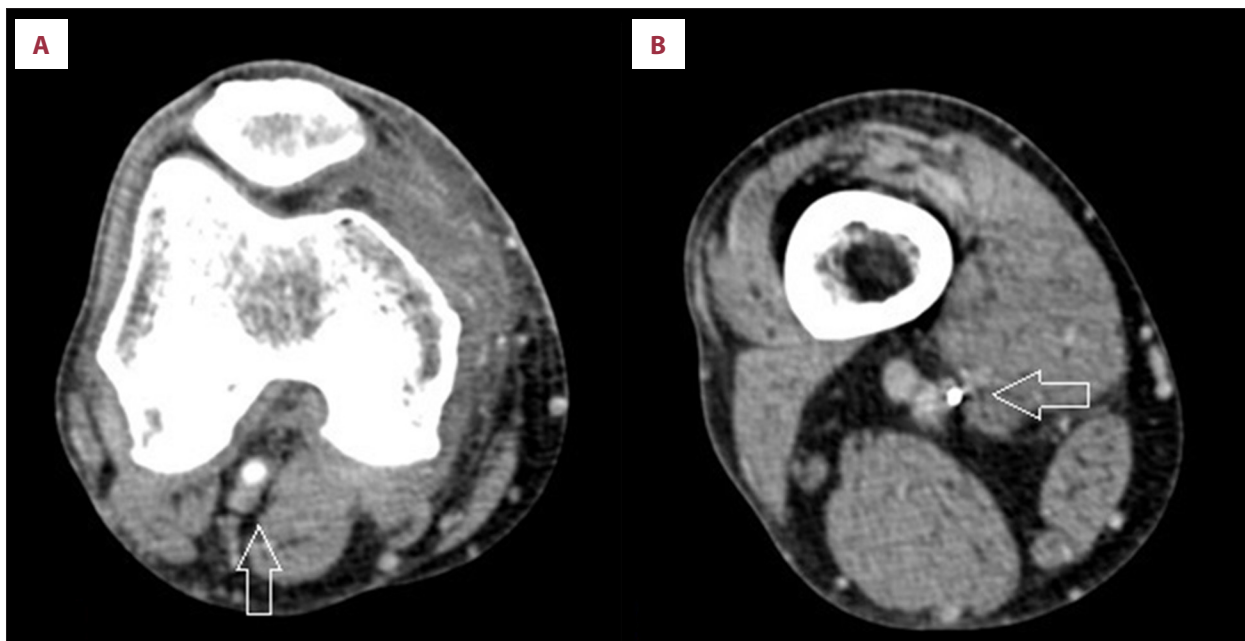
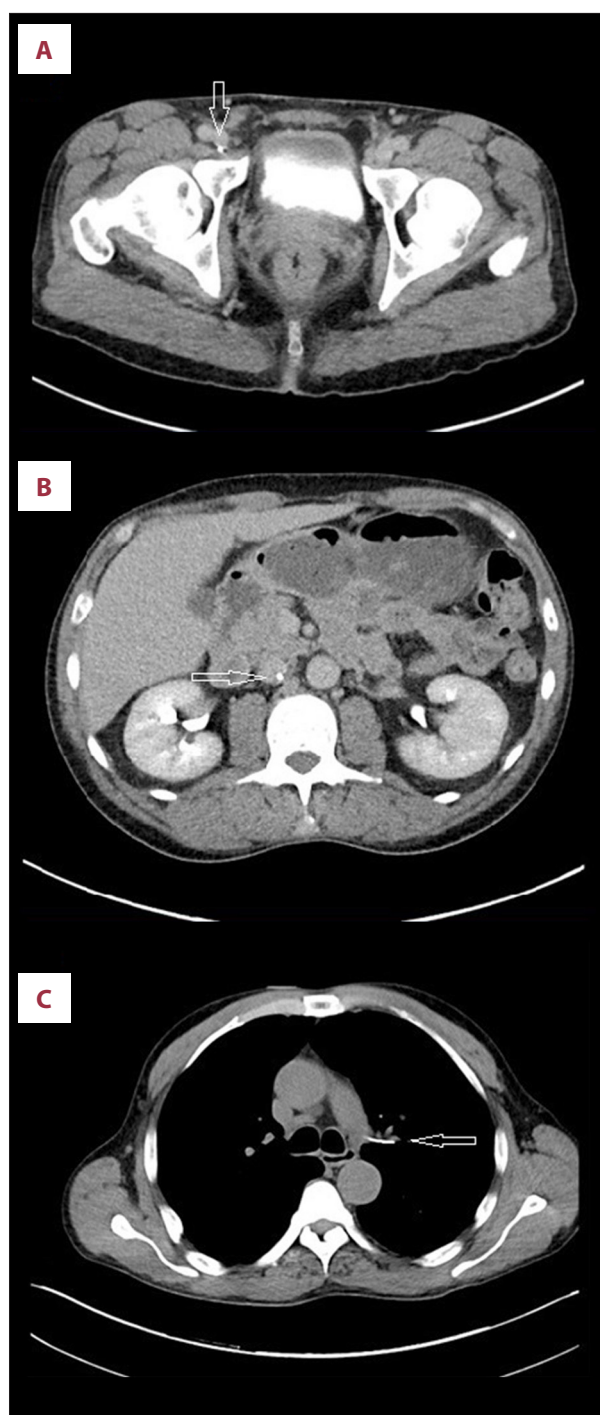


Figure 4. Computed tomography (CT) images of the knee and lower thigh of a 52-year-old African-American man who presented with a retained venous guidewire. CT images of (A) the knee area, and (B) the lower thigh area, showing the extension of the guidewire in the femoral vein at the knee and lower thigh areas (arrows).



Figures 5. Computed tomography (CT) images of the pelvis, abdomen, and chest of a 52-year-old African-American man who presented with a retained venous guidewire. CT scans of the pelvis (**A**) and abdomen (**B**) at the level of the kidneys, and of the chest (**C**) showing the path of the wire from the pelvic area, traveling through the inferior vena cava (IVC) and terminating in the left pulmonary artery.

Discussion

Guidewires are used in almost all intravascular interventions, including central venous catheterization. These common interventional procedures are considered to be safe when performed by skilled personnel. However, there are many complications associated with the insertion of guidewires, including retention after insertion, which may be associated with complications [2–8]. Retention of the guidewire may occur with any type or site of vascular access, in varied hospital locations, and when different administrators perform the procedures. The incidence of complications associated with guidewire insertion has been increasing, possibly due to an increase in the vascular interventional procedures or due to increased reporting of clinical adverse events [1].

Many factors have been identified that can increase the risk of retention of an intravascular guidewire, including distraction during the procedure, the level of experience of the operator, high workload of the operator, or lack of proper supervision. Lack of supervision has been identified as the commonest risk factor, with most of the cases seen with trainee doctors [5]. The consequences of the retained guidewire can include embolism from wire fragmentation. Although there are no published data on the effects of guidewire fragmentation, the risks of a foreign body reaction in the vasculature are recognized [10]. Measures to train personnel under the supervision of skilled operators may minimize these complications, including confirming that the guidewire has been returned to the catheter kit after insertion of a central venous catheter, and confirming placement with a chest X-ray [9].

Most retained guidewires are discovered immediately, usually during or shortly after the procedure. However, some may be discovered after a long period, as with our patient (after approximately two years). Detection usually occurs when the operator notes the missing guidewire, or when the tip is lost, or while inspecting the catheter tray after the procedure. Guidewire retention may also be detected post-procedure on radiographs, either performed immediately after the procedure or later for conditions that might be unrelated to the guidewire [5,9]. Other cases have been detected during post mortem examination and during laparotomy [5]. In this case, the guidewire was detected when it protruded through the skin to the outside of the body, which is an extremely rare occurrence. A previously described case has been reported with a similar presentation, where the guidewire protruded from the left great toe, six months after left femoral vein central line placement [11].

In this report, the patient had a total of three vascular interventions that required the use of guidewires. Various operators performed these procedures over a period of about two weeks.

Table 1. Summary of the case presentation.

Procedures performed (in sequence)
Cardiac catheterization, femoral triple lumen central line (likely cause of missed guidewire), left arm peripherally-inserted central catheter (PICC) line
Operator
Emergency physician (likely to be responsible), the cardiologist and interventional radiologist (unlikely to be responsible)
Risks identified
Acutely ill patient, intensive care unit (ICU) admission, multiple line placements, line placed as an emergency, and pacemaker pads attached to the chest wall.
Site of the distal tip
Left pulmonary artery
Site of the proximal tip
Protruded outside the body from the femoral vein
Any broken fragments
Distal tip (approximately 5 cm) was broken and found in the inferior vena cava (IVC) at the level of the diaphragm, and another smaller coiled fragment at the lower thigh level
Time from placement to discovery
Approximately two years
Circumstances of discovery
The wire punctured the vein and its overlying skin and then protruded outside the body
How the wire was first discovered
Seen by the patient
Who first discovered the wire?
The patient himself
Additional investigations performed because of the guidewire
Plain X-rays (right lower extremity, abdomen, chest) and computed tomography (CT) scans (knee, chest, abdomen, and pelvis)
Complications related to the retained wire when detected
Minor (pain and swelling around the puncture site)
Condition of the wire in the body (during the time of diagnosis or retrieval)
Slightly adherent to the vascular wall, not coiled, partially dislodged outside the vasculature, and had two small broken fragments (distal tip, and another coiled smaller fragment)
Method of retrieval
Bedside (unsuccessful), then surgical (partially removed)

The first procedure was cardiac catheterization and coronary angiography performed by a cardiologist, through the right inguinal area with the guidewire being present in the arterial circulation and not the venous circulation. The second procedure involved a right femoral triple-lumen central venous catheter, performed by an emergency attending physician. The third procedure involved a peripherally-inserted central catheter (PICC) line that was placed in the left arm by an interventional radiologist. It is less likely that the PICC line was the source of the missing guidewire since it was placed in the left arm. The guidewire was located in the right femoral vein and the inferior vena cava, which suggests that the right femoral central venous catheter placement was the procedure where the guidewire was retained.

Placing a line as an emergency procedure increases the risk of missing a guidewire and multiple line placements may further increase the risk. This patient underwent an admission to the intensive care unit (ICU), which may have made it easier to miss the findings on chest X-ray, due to the presence of the multiple wires attached to his body at that time. Also, the presence of large pacer patches attached to the chest may have made it difficult to identify the guidewire on X-ray. Table 1 summarizes the major factors related to the case.

Guidewire retention may result in multiple complications including, but not limited to, cardiac arrhythmias and conduction abnormalities, and perforation of blood vessels or a cardiac chamber. Also, the guidewire can undergo kinking, looping, or knotting of the wire, breakage of the distal tip with subsequent

embolization, and entanglement with a previously placed intravascular device [12]. Despite following procedure protocols, guidewire retention continues to occur, because intravascular catheterization relies on the human factor, that of the clinician remembering to remove the guidewire [13]. To minimize the risk of guidewire retention, a more stringent procedural protocol may need to be developed. Mariyaselvam et al. have investigated the use of a locked procedure kit, where the suture, suture holder, and antimicrobial dressing are placed in a special pack where the guidewire acts as a key and is required to open the pack [13]. This procedure requires that the clinician confirms that he has removed the guidewire before attempting to place the sutures, and has been confirmed to be an effective preventative approach that improves patient safety [13].

In most cases, the guidewire is removed through percutaneous endovascular means, using a gooseneck snare device [14]. In our patient, the guidewire could not be retrieved, as it was adherent to the wall of the pulmonary artery.

References:

1. Pokharel K, Biswas BK, Tripathi M, Subedi A: Missed central venous guide wires: A systematic analysis of published case reports. *Crit Care Med*, 2015; 43(8): 1745–56
2. Ruesch S, Walder B, Tramèr MR: Complications of central venous catheters: Internal jugular versus subclavian access – a systematic review. *Crit Care Med*, 2002; 30: 454–60
3. Ballard DW, Reed ME, Rauchwerger AS et al: Emergency physician perspectives on central venous catheterization in the Emergency Department: A survey-based study. *Acad Emerg Med*, 2014; 21: 623–30
4. Bhosale GP, Shah VR: Guide-wire embolism: A preventable complication. *J Anaesth Clin Pharmacol*, 2010; 26(3): 419–34
5. Schummer W, Schummer C, Gaser E, Bartunek R: Loss of guide wire: Mishap or blunder? *Br J Anaesth*, 2002; 88: 144–46
6. Narendra H, Baghavan KR: Guide-wire embolism during subclavian vein catheterization by Seldinger technique: *Indian J Crit Care Med*, 2006; 10(4): 257–59
7. Song Y, Messerlian AK, Matevosian R: A potentially hazardous complication during central venous catheterization: Lost guidewire retained in the patient. *J Clin Anesth*, 2012; 24: 221–26
8. Kornbau C, Lee KC, Hughes GD, Firstenberg MS: Central line complications. *Int J Crit Illn Inj Sci*, 2015; 5(3): 170–78
9. Gunduz Y, Vatan MB, Osken A, Cakar MA: A delayed diagnosis of a retained guidewire during central venous catheterisation: A case report and review of the literature. *BMJ Case Rep*, 2012; 2012: pii: bcr2012007064
10. Karabay K, Bagirtan B: Broken guidewire fragment. *Int J Angiol*, 2012; 21(4): 241–42
11. Cat BG, Guler S, Soyuduru M et al: Complete guidewire retention after femoral vein catheterization. *Ann Saudi Med*, 2015; 35(6): 479–81
12. Khasawneh FA, Smalligan RD: Guidewire-related complications during central venous catheter placement: A case report and review of the literature. *Case Rep Crit Care*, 2011; 2011: 287261
13. Mariyaselvam MZA, Catchpole KR, Menon DK et al: Preventing retained central venous catheter guidewires: A randomized controlled simulation study using a human factors approach. *Anesthesiology*, 2017; 127(4): 658–65
14. Cheddie S, Singh B: Guidewire embolism during central venous catheterization: Options in management. *The Internet Journal of Surgery*, 2013; 30(1): 1–4

Conclusions

Retention of guidewires during vascular catheterization is as an increasingly reported complication of what is now a common hospital intervention. As this case has shown, it is important to perform these techniques with the guidance of skilled and experienced operators that ensure such complications can be minimized in the clinical setting. While most cases are discovered immediately during or following the procedure, rare cases are discovered incidentally on X-rays. It is very unusual for the retained guidewire to present by protruding outside the body at two years after placement of a central venous catheter.

Conflict of interest

None.