

Use of the base purse-string suture approach to remove giant uterine fibroids during cesarean section

Journal of International Medical Research

48(4) 1–7

© The Author(s) 2019

Article reuse guidelines:

sagepub.com/journals-permissions

DOI: 10.1177/0300060519893868

journals.sagepub.com/home/imr



Dan Liu, Min Han, Pu Huang, Chunfang Li and Xuelan Li 

Abstract

Objective: This study aimed to investigate the optimal strategy for myomectomy for removing giant uterine fibroids when necessary in women undergoing cesarean section.

Methods: This study was retrospective in design, and assessed outcomes in 26 patients who underwent myomectomy using a “base purse-string suture” during cesarean section. The operative duration, blood loss, uterine involution, and duration of postpartum lochia were analyzed.

Results: This suture was associated with a mean operative duration of 11.17 ± 5.36 minutes and the mean estimated blood loss was 11.15 ± 6.05 mL. The mean postpartum duration of lochia was 34.92 ± 7.55 days and there were no cases of postpartum hemorrhage. Uterine size returned to normal within 6 weeks of delivery, without any apparent defects or abnormalities in the uterine wall as shown by an ultrasonic examination.

Conclusion: This novel implementation of a base purse-string suture during cesarean myomectomy for removal of giant fibroids is a simple, safe, and effective intervention that should be considered for implementation in appropriate patients.

Keywords

Giant uterine fibroid, cesarean section, myomectomy, base purse-string suture, postpartum hemorrhage, uterine involution

Date received: 7 July 2019; accepted: 18 November 2019

Introduction

Pregnancies can often be complicated by development of uterine fibroids. The incidence of uterine fibroids has been increasing

Department of Obstetrics and Gynecology, The First Affiliated Hospital of Xi'an Jiaotong University, Xi'an, China

Corresponding author:

Xuelan Li, Department of Obstetrics and Gynecology, The First Affiliated Hospital of Xi'an Jiaotong University, 277 West Yanta Road, Xi'an, 710061, China.
Email: lixuelan1225@126.com



in recent years as a consequence of an increase in average maternal age. Epidemiological studies have suggested that the incidence of these fibroids is between 0.1% and 3.9%,¹ with some reports of rates as high as 10.7%.² There is no specific definition for what constitutes a giant fibroid.

Fibroids blocking the birth canal constitute an indication for cesarean section. However, whether myomectomy to remove these fibroids should be performed during a cesarean operation remains controversial. Because uterine blood supply is more abundant during pregnancy, removing these fibroids during a cesarean operation can lead to increased intraoperative blood loss. This situation can result in postpartum hemorrhage, and increase in perioperative infection risks, and potentially elevate the risk for requiring a hysterectomy. However, if these fibroids are not removed during this operation, this can influence puerperal uterine involution and elevate the risk of certain complications, including pelvic inflammation. By operating on these fibroids during an already ongoing operation, cesarean myomectomy also reduces the need for future surgical operations, which have inherent risks.

To date, many studies have shown that conducting cesarean myomectomy is a generally safe and reliable surgical strategy, provided that the patient's condition is conducive to tolerating the operation and that the fibroids are not within the uterine cornua or cervix.³ However, when giant uterine fibroids must be removed during a cesarean operation, there is a higher risk of bleeding. However, in some cases, these fibromas must be removed, such as when they affect uterine contraction and thereby mediate blood loss or when they hinder delivery. In these circumstances, surgeons may have no choice but to perform a cesarean myomectomy to remove giant uterine fibroids, necessitating suturing to prevent

intraoperative blood loss. However, the optimal strategy for minimizing such blood loss without substantially increasing the operative duration remains unknown.

We have been implementing a novel surgical strategy for cesarean myomectomy termed a "base purse-string suture" since 2013 in patients with giant fibroids. This study aimed to assess the outcomes of cesarean myomectomy using the base purse-string suture approach in these patients.

Materials and methods

This study was a retrospective analysis of pregnant women who were diagnosed with giant uterine fibroids by ultrasound from 2013 to 2018 at the First Affiliated Hospital of Xi'an Jiaotong University. These patients each underwent cesarean myomectomy using the base purse-string suture method as described below. This technique was verified by the Hospital Ethics Committee and the Ministry of Medical Affairs and received clinical approval. Patients provided informed consent, which was embedded in the operation consent document and filed in the archives. All of the patients and their relatives were counseled regarding the necessity of removing fibroids and the risk of severe bleeding, postoperative adhesions, and the possibility of hysterectomy. Uterine fibroids were defined as fibroids >8 cm in diameter. The operative duration, intraoperative blood loss, incidence of uterine involution, and duration of postpartum lochia were assessed.

The base purse-string suture myomectomy procedure was as follows. Oxytocin was administered to patients immediately following delivery of the fetus, at which point we used digital palpation to delineate the anatomical boundary between the fibroid and the myometrial wall (Figure 1a). We then prepared a circular layer of purse-string suture using #1 absorbable suture at the fibroid base, with stitches

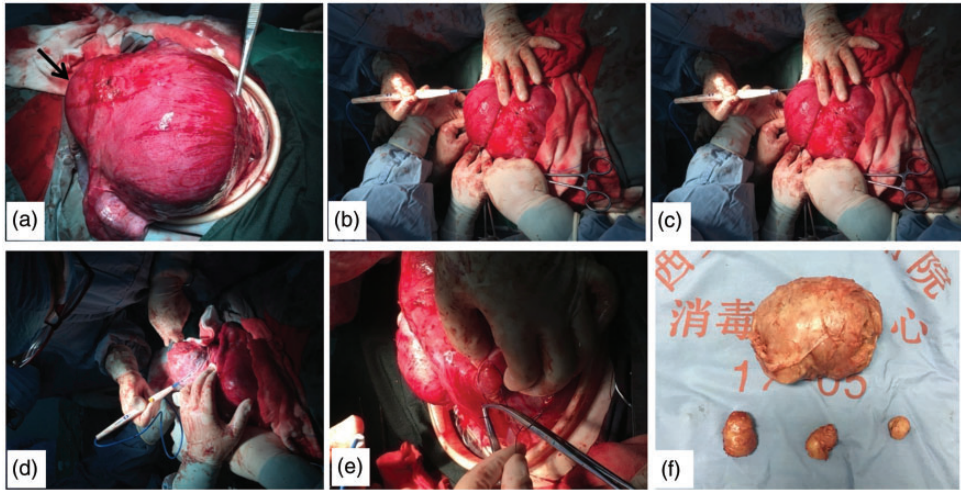


Figure 1. Intraoperative images of the base purse-string suture. (a) Full fibroid exposure following closure of the uterine incision. The tumor boundary can be identified (black arrow). (b) An initial layer of stitches are placed along the base of the fibroid. (c, d) The assistant tightens the suture, while the surgeon performs blunt removal of the tumor. (e) The tumor cavity is closed. (f) Removed fibroids.

positioned at 0.3 to 0.5 cm from the base and 0.5 to 0.8 cm deep to prevent endometrial penetration (Figure 1b). An assistant tied an initial knot and then maintained tension in the sutures, while the surgeon cut into the fibroid capsule using a cold knife or electric surgeon knife to expose the enclosed tumor (Figure 1c). The surgeon removed the tumor via blunt dissection, while the assistant continued to tighten the suture. This resulted in the capsule, which had enclosed the tumor, shrinking into a tight pocket. At this point, the surgeon assisted the assistant in tying two to three additional square knots to ensure that the purse-string suture remained in place without slipping. An additional layer of purse-string #1 suture was applied for enhancement purposes (Figure 1d). Finally, the tumor cavity was closed by using an interrupted absorbable suture (Figure 1e).

We recorded the following data. Intraoperative blood loss was determined as follows. Before resection of the fibroid, the area was cleaned, and the fibroid was entirely

wrapped with gauze. Gauze weight (g) was then measured before and following resection, and blood loss was estimated using the following formula: blood loss (mL) = (gauze weight [g] after myomectomy – gauze weight [g] before myomectomy)/1.05. Operative duration was calculated as the time between the initial suture placement and when tumor cavity closure was recorded. The postpartum duration of lochia was recorded by patient care providers. At 6 weeks postpartum, all patients underwent an ultrasound evaluation to assess the presence of uterine involution, and the time of the first postpartum period was additionally recorded.

Data are presented as the mean ± standard deviation. Statistical analysis was performed using SPSS 19.0 (IBM Corp., Armonk, NY, USA).

Results

The 26 patients enrolled in this study underwent cesarean section due to obstetric factors. Of these 26 patients, 15 were

multipara, 11 were primipara, five were pregnant with twins, and 21 were pregnant with singletons. Reasons for cesarean sections in these women included previous cesarean (46.15%), fetal stress (19.23%), advanced age (15.38%) of which one case was complicated by a cervical fibroid blocking the birth canal, and an abnormal presentation (11.54%) (Table 1). All patients received combined spinal and epidural anesthesia and underwent cesarean section at the lower uterine segment. Following fetal and placental delivery and closure of the uterine incision, myomectomy was performed in all patients. All patients in this study presented with satisfactory postoperative uterine contractions, with no indications for hysterectomy in any cases. All 26 women elected to breastfeed their newborns.

Most patients had intramural fibroids and some patients had subserosal fibroids (Table 1). Of these individuals, most had solitary fibroids, and they were mainly found in the anterior uterine wall, followed by the posterior wall, the fundus, and the cervix. Anterior wall fibroids and cervical fibroids were removed during cesarean section because they affected suturing of the incision. Posterior wall fibroids and fundus fibroids were removed because they had the potential to affect uterine contraction.

The mean age of the patients was 31.42 ± 4.5 years and the mean gestational age was 38.4 ± 1.5 weeks. Of the removed fibroids, the diameter of the largest was 20 cm, while that of the smallest was 8 cm, with a mean diameter of 12.31 ± 3.71 cm (Figure 1f). The volume of intraoperative blood loss ranged from 5 to 30 mL, with a mean loss of 11.15 ± 6.05 mL. Only one patient needed to undergo a blood transfusion (2 units) intraoperatively because of a low preoperative hemoglobin level (78 g/L). The mean duration of myomectomy was 11.17 ± 5.36 minutes and the mean duration

Table 1. Obstetric and fibroid data of the patients.

	Number	Percentage
Parity		
Primipara	11	68.75
Multipara	15	31.25
Births		
Twins	5	19.23
Singleton	21	80.77
Type of fibroid		
Intramural	21	80.77
Subserosal	5	19.23
Numbers of fibroids		
Solitary	23	88.46
Multiple	3	11.54
Location		
Anterior	12	46.15
Posterior	6	23.08
Fundus	7	26.92
Isthmus	1	3.85
Indications of cesarean section		
Fetal position	3	11.54
Previous cesarean section	12	46.15
Advanced maternal age	4	15.38
Fetal stress	5	19.23

of postpartum lochia was 34.92 ± 7.55 days. There were no cases of postpartum hemorrhage. The mean hospital stay was 5.46 ± 0.71 days (Table 2). When patients underwent postpartum ultrasound assessments after 6 weeks, there was no evidence of abnormalities regarding uterine size, and there was no evidence of uterine wall defects or any other abnormalities. The first postpartum period was recorded as 2 to 12 months after delivery.

Comment

At present, there is no definitive indication for conducting myomectomy during cesarean section. However, many studies have achieved higher success rates in this operation via subserosal fibroid removal.⁴⁻⁶ A number of variables affect the choice to conduct cesarean myomectomy, including the number, type, and location of the tumor, as well as the surgeon's experience

Table 2. Characteristics of the patients, uterine fibroid diameter, and operative data.

	Number	Maximum	Minimum	Mean	SD
Age (years)	26	43	24	31.42	4.5
Gestational weeks	26	40.6	35	38.4	1.5
Diameter of the fibroid (cm)	26	20	8	12.31	3.71
Duration of the operation (minutes)	26	23	4	11.17	5.36
Blood loss (mL)	26	30	5	11.15	6.05
Duration of lochia (days)	26	54	20	34.92	7.55
Length of hospitalization (days)	26	7	4	5.46	0.71

SD: standard deviation.

and maternal age.⁷ Sparic et al⁸ determined that the factors associated with admission to the intensive care unit of patients who have cesarean myomectomy include the type of tumor, the number of tumors, the amount of intraoperative blood loss, and the operative duration. Surgeons are inclined to remove subserosal and intramural fibroids because they can be readily exposed and tend to have cleaner boundaries, significantly decreasing operative times and blood loss.

When these giant uterine fibroids are discovered in the course of a cesarean section, their excision is often necessary and inevitable because some may interfere with excision or with uterine contractions and polarity. This situation increases the risk of postpartum hemorrhage and increases healing times. Patients with giant fibroids also have an increased risk of degeneration during puerperium. As such, there is an urgent need to determine the best method of conducting myomectomy during an ongoing cesarean section. Therefore, we applied the base purse-string suture approach to 26 patients who were diagnosed with giant uterine fibroids. We found that this approach was effective for minimizing blood loss without any incidence of postpartum hemorrhage. This approach is easy to learn. We found that, for a skilled attending surgeon who is experienced in performing

cesarean myomectomy, only 1 to 2 weeks are required to learn this procedure.

Because the uterus has an abundant blood supply during pregnancy, controlling bleeding is important and it can be accomplished either by reducing the uterine blood supply or reducing the local fibroid blood supply. A number of traditional myomectomy strategies have been used to date, including bilateral uterine artery ligation,⁵ U-stitches,⁹ uterine tourniquet use, high oxytocin doses,¹⁰ careful hemostasis, identification of the tumor boundary, pseudocapsule removal, and complete suturing of the empty cavity.¹¹ Desai et al¹² reported the outcomes in nine women who underwent elective cesarean section who also underwent myomectomy after selective uterine devascularization. This was achieved by bilateral ligation of the ovarian arteries medial to the ovaries, as well as of the ascending branches of the uterine artery. After these ligations were made, the uterine incision was sutured and the fibroid was dissected. While this technique was successful, it required considerable experience to avoid damage to surrounding tissues, and is thus only achievable by skilled and experienced surgeons.

The base purse-string suture method described in the current study was developed over several years by our team as a consequence of their experiences. Therefore,

there have been no reports of a comparable approach in the Chinese literature. This approach is based upon the fact that the uterine fibroid blood supply originates from extension of vessels in the uterine wall at the base of the fibroid. As such, ligating and knotting along the fibroid base facilitates a reduction in fibroid blood supply. As the suture is tightened, the fibroid increasingly protrudes and becomes substantially easier to excise from the uterine wall. This approach almost completely blocks the blood supply to the fibroid, and we found that this resulted in a considerably shortened operative duration and reduced intraoperative bleeding. Lee and Cho¹³ reported the outcomes of another purse-string suture approach that was applied to 31 patients who underwent cesarean myomectomy. In their study, removed fibroids were either intramural or subserosal and were 2.2 to 8.5 cm in diameter. Additionally, the mean operative time was 5.2 ± 2.5 minutes, with a mean intraoperative blood loss of 7.9 ± 4.3 mL. This resulted in no significant difference in duration of hospital stay relative to individuals who only underwent cesarean section. When patients underwent a postpartum ultrasound after 5 weeks, the uterine contour was intact and there were no cases of severe late puerperal hemorrhage. Of these 31 patients, six became pregnant and underwent a second successful cesarean section without any evidence of defects to previous uterine incisions. Our findings are similar to those of Lee and Cho's study¹³, with some small differences. We administered oxytocin before suturing the circular layer to ensure that there was a clearer margin of the myoma. Additionally, our suture distance from the base of the fibroid was 0.3 to 0.5 cm, while that in Lee and Cho's study¹³ was 1 to 2 cm. We further prepared a circular layer of sutures, whereas these other authors prepared a two-turn wrap. Although there were differences between these two methods, our results are

consistent with this previous study. We used our base purse-string suture approach in cesarean myomectomy when fibroids were >8 cm in diameter, with a mean intraoperative blood loss of 11.15 ± 6.05 mL, a mean operative duration of 11.17 ± 5.36 minutes, and a mean length of hospitalization of 5.46 ± 0.71 days.

The present study was limited in size. Therefore, future studies with larger sample size and randomization are required to confirm the efficacy of this strategy. We are planning to perform comparative studies of different approaches to cesarean myomectomy to confirm the benefits of our new method.

We consider that our base purse-string suture approach is safe, convenient, and easy to perform in cesarean myomectomy as a means of removing giant fibroids.

Acknowledgements

We are sincerely grateful for the colleagues who helped during data collection in the operation room of the Obstetrics and Gynaecology Department of The First Affiliated Hospital of Xi'an Jiaotong University.


Declaration of conflicting interest

The authors declare that there is no conflict of interest.

Funding

This research received no specific grant from any funding agency in the public, commercial, or not-for-profit sectors.

ORCID iD

Xuelan Li  <https://orcid.org/0000-0001-9110-1103>

References

1. Vitale SG, Tropea A, Rossetti D, et al. Management of uterine leiomyomas in pregnancy: review of literature. *Updates Surg* 2013; 65: 179–182.

2. Laughlin SK, Baird DD, Savitz DA, et al. Prevalence of uterine leiomyomas in the first trimester of pregnancy: an ultrasound-screening study. *Obstet Gynecol* 2009; 113: 630–635.
3. Incebiyik A, Hilali NG, Camuzcuoglu A, et al. Myomectomy during caesarean: a retrospective evaluation of 16 cases. *Arch Gynecol Obstet* 2014; 289: 569–573.
4. Topçu HO, İskender CT, Timur H, et al. Outcomes after cesarean myomectomy versus cesarean alone among pregnant women with uterine leiomyomas. *Int J Gynaecol Obstet* 2015; 130: 244–246.
5. Lin JY, Lee WL, Wang PH, et al. Uterine artery occlusion and myomectomy for treatment of pregnant women with uterine leiomyomas who are undergoing cesarean section. *J Obstet Gynaecol Res* 2010; 36: 284–290.
6. Kim YS, Choi SD and Bae DH. Risk factors for complications in patients undergoing myomectomy at the time of cesarean section. *J Obstet Gynaecol Res* 2010; 36: 550–554.
7. Sparić R, Malvasi A and Tinelli A. Analysis of clinical, biological and obstetric factors influencing the decision to perform cesarean myomectomy. *Ginekol Pol* 2015; 86: 40–45.
8. Sparić R, Guido M and Tinelli A. Cesarean myomectomy and possible risk factors for admission to intensive care unit - a retrospective study. *Ginekol Pol* 2015; 86: 731–736.
9. Cobellis L, Pecori E and Cobellis G. Hemostatic technique for myomectomy during cesarean section. *Int J Gynaecol Obstet* 2002; 79: 261–262.
10. Umezurike CC. Cesarean myomectomy in Aba, southeastern Nigeria. *Trop Doct* 2008; 38: 189–190.
11. Tinelli A, Malvasi A, Mynbaev OA, et al. The surgical outcome of intracapsular cesarean myomectomy. A match control study. *J Matern Fetal Neonatal Med* 2014; 27: 66–71. Epub 2013 Jun 20.
12. Desai BR, Patted SS, Pujar YV, et al. A novel technique of selective uterine devascularization before myomectomy at the time of cesarean section: a pilot study. *Fertil Steril* 2010; 94: 362–364.
13. Lee JH and Cho DH. Myomectomy using purse-string suture during cesarean section. *Arch Gynecol Obstet* 2011; 283: 35–37.