

Laboratory Investigation

Overexpressions of Vimentin and Integrins in Human Metastatic Spine Tumors

Sung Bae Park, M.D.,¹ Young-Joon Ryu, M.D., Ph.D.,² Young Seob Chung, M.D., Ph.D.,¹ Chi Heon Kim, M.D., Ph.D.,^{3,4}
Chun Kee Chung, M.D., Ph.D.^{3,4,5}

Department of Neurosurgery,¹ Seoul National University Boramae Medical Center, Seoul, Korea

Department of Pathology,² Kangwon National University School of Medicine, Chuncheon, Korea

Department of Neurosurgery,³ Seoul National University College of Medicine, Seoul, Korea

Department of Brain and Cognitive Sciences,⁴ Seoul National University College of Natural Sciences, Seoul, Korea

Clinical Research Institute,⁵ Seoul National University Hospital, Seoul, Korea

Objective : To comparatively investigate the expression of several integrins in specimens of human bone metastases and degenerative bone tissue.

Methods : Degenerative cancellous tissue was obtained from a sample of human degenerative spine. Thirteen human specimens were obtained from metastatic spine tumors, whose primary cancer was colon cancer (n=3), hepatocellular cancer (n=3), lung cancer (n=4), and breast cancer (n=3). The expression of vimentin and integrins α v, β 1, and β 3 was assessed in metastatic and degenerative specimens by immunohistochemistry and real-time reverse transcription-polymerase chain reaction (qRT-PCR).

Results : Immunohistochemical staining showed that vimentin and integrin α v was broadly expressed in all tissues examined. By contrast, integrin β 1 was weakly expressed only in 38.4% (5/13) of tissues. Integrin β 3 was consistently negative in all cases examined. qRT-PCR analysis showed that vimentin gene expression was higher in all metastatic specimens, as compared to degenerative bone. The gene expression of integrin α v in breast specimen was significantly higher than others ($p=0.045$). The gene expression of integrin β 1 was also higher in all metastatic specimens than in degenerative bone tissue. The gene expression of integrin β 3 was variable.

Conclusion : Spinal metastatic tumors have mesenchymal characteristics such as increased expression of vimentin. The increased expression of integrin α v and β 1 in spine metastatic tumors suggests that adhesive molecules such as integrin may have implications for the prevention of spine metastasis.

Key Words : Spine · Metastasis · Integrin α v · Vimentin.

INTRODUCTION

Cancer is the leading cause of death with most deaths related to bone metastasis^{2,8}. Bone metastases cause pain, pathological fractures, compression of the spinal cord, and life-threatening imbalances in minerals including hypercalcemia¹². Because of the devastating effects of metastases, attention has shifted from the pathogenesis of primary tumors to the less-understood process of metastasis². The metastatic process of primary tumors involves several sequential steps : dissemination, survival in transit, bone migration and engagement, metastasis formation by disseminated tumor cells, and establishment of distant macro-metastases^{2,10,17}. The emergence of primary cancer involves cancer stem cells and genetic or epigenetic alterations^{5,8}. By acquir-

ing properties of the epithelial-mesenchymal transition (EMT), cells from the malignant primary tumors disseminate to distant organs and become invasive^{9,14}. Vimentin, an intermediate filament protein, is considered a marker for EMT^{7,9}. Besides, the increased expression of vimentin appears to be a precondition to EMT induction⁷. Several factors including blood flow, growth factors, and adhesive molecules account for the predilection of some malignant tumors for bone^{6,12,23}.

Malignant tumor cells also produce adhesive molecules, including integrin family members, which allow tumor cells to bind bone marrow stromal cells^{13,14}. The integrin family members are involved in the signaling pathways for adhesion, migration, and cell survival¹³. Studies have identified several integrins, including α v, α 6, β 1, and β 3, in skeletal metastasis of cancers orig-

• Received : November 3, 2014 • Revised : February 26, 2015 • Accepted : February 27, 2015

• Address for reprints : Chun Kee Chung, M.D., Ph.D.

Department of Neurosurgery, Seoul National University Hospital, 101 Daehak-ro, Jongno-gu, Seoul 110-744, Korea

Tel : +82-2-2072-2352, Fax : +82-2-744-8459, E-mail : chungc@snu.ac.kr

• This is an Open Access article distributed under the terms of the Creative Commons Attribution Non-Commercial License (<http://creativecommons.org/licenses/by-nc/3.0>) which permits unrestricted non-commercial use, distribution, and reproduction in any medium, provided the original work is properly cited.

inating from epithelial cells such as breast and prostate cancers^{4,20,21}. However, the expression of integrins in human metastatic spine cancer has not been reported. The present study was designed to investigate the upregulation of vimentin in metastatic specimens and the potential clinical implications of integrins α , β 1, and β 3 expression in human metastatic spine tumors of different primary cancer origin using immunohistochemistry and real-time reverse transcription-polymerase chain reaction (qRT-PCR).

MATERIALS AND METHODS

Patient selection

Thirteen human spinal metastatic specimens obtained from 13 consecutive patients with spine metastasis and 1 degenerative bone specimen of 1 patient with degenerative spine disease were selected from a tissue bank in our neurosurgical department. All human tissues were obtained from patients who signed a consent form allowing the collection of their tissues obtained during spine surgery in liquid nitrogen and subsequent research use. The Institutional Review Board in our hospital approved the tissue banking of specimens and their use in the present study (H1111-050-386).

The primary cancers represented by the 13 specimens were colon cancer (n=3), hepatocellular cancer (n=3), lung cancer (n=4), and breast cancer (n=3) (Table 1).

A non-metastatic bone tissue sample was obtained from the lamina of 1 patient with degenerative spine disease. Because of the limited number of trabecular tissue of degenerative bone available in the tissue bank, only 1 specimen obtained in degenerative spine was used as control. Metastatic tissue samples were obtained from the spine metastasis area during decompressive spine surgery.

Immunohistochemistry staining

Vimentin expression was assessed in the metastatic specimens in order to evaluate the malignant characteristics related to EMT. Among the adhesive molecules of the integrin family, integrin α , β 1, and β 3 were selected based on the results of previous studies^{13,21}. Because the control tissue was trabecular bone and metastasis tissue was obtained from soft areas in spinal metastasis area, all specimens were not decalcified. Tissue specimens (trabecular bone and metastasis tissue) were stored in liquid nitrogen immediately after harvesting. Frozen tissue slides were prepared by cutting 10 μ m sections with a cryo-microtome (LEICA CM1850, Leica Biosystems, Nussloch, Germany) and mounting on slides. The slides were air dried for 30 min, fixed in cold acetone at room temperature for 5 min, removed from the acetone, and air dried again. The slides were rinsed for 5 min in tap water, incubated for 30 min in 0.3% H₂O₂ and 2% Triton X-100, washed in phosphate-buffered saline (PBS), incubated for 20 min in normal blocking serum, and then incubated with diluted primary antibody overnight in a cold room. The following

antibodies and dilutions were used: anti-vimentin antibody (1 : 100, mouse monoclonal, Abcam, Cambridge, UK); anti-integrin β 3 antibody (1 : 100, mouse monoclonal, Novus Biologicals); anti-integrin α v antibody (1 : 500, rabbit polyclonal, Abcam); and anti-integrin β 1 antibody (1 : 250, rabbit monoclonal, Abcam, Cambridge, UK). After incubation in the primary antibody, the slides were washed in PBS and incubated for 30 min with the secondary antibody (Vector, CA, USA). Vector Immpress Reagent kit anti-mouse IgG (MP7402) and anti-rabbit IgG (MP7401) were used as the secondary antibodies. The slides were washed in PBS, the tissue sections were stained for visualization with diaminobenzidine (Vector, USA), and coverslips were mounted with HistoChoice Mounting Media (Amresco, OH, USA).

Analysis of gene expression by real-time RT-PCR

The comparative expression of vimentin and integrins α v, β 1, and β 3 between metastatic and degenerative specimens were assessed by immunohistochemistry and qRT-PCR. The PCR primer and probe sets for vimentin, glyceraldehyde-3-phosphate dehydrogenase (GAPDH), and integrins α v, β 1, and β 3 were obtained from Life technologies (Applied Biosystems, Life Technologies, Carlsbad, CA, USA). Trabecular bone and metastasis tissue were stored in liquid nitrogen until RNA extraction. All specimens were treated alike. RNA was extracted from the metastatic and degenerative bone specimens with the QIA-GEN RNeasy mini kit (Qiagen, LA, USA). For cDNA synthesis, 1 μ g of RNA was reverse transcribed using random hexamer primers (Invitrogen, Life Technologies, CA, USA) and Impron II reverse transcriptase (Invitrogen, Life Technologies, CA, USA). The samples were analyzed using an Applied Biosystems SDS 7500 system with a master mix containing 6.25 μ L water, 1.25 μ L probe (2.5 M), and 12.5 μ L TaqMan PCR 2 \times Master Mix. Fifty nanograms of reverse-transcribed total RNA in 5 μ L was added as the PCR template in 96-well optical plates, and the results were analyzed on the Prism 7500 Sequence Detection System (PerkinElmer Applied Biosystems, Lincoln, CA, USA). The following PCR conditions were used. After initial activation of uracil-N-glycosylase at 50°C for 2 min, AmpliTaq Gold was activated at 95°C for 10 min. This was followed by 45 cycles of denaturation at 95°C for 15 s and annealing, and extension at 60°C for 1 min per cycle. The expression levels of the target genes were normalized to the internal control human GAPDH (FAM/MGB Probe, Primer Limited, Life Technologies, CA, USA), and fold changes were expressed relative to the data obtained at day 1.

Statistical analysis

The results were presented as mean \pm standard deviation. To identify significant differences between groups in mRNA expression of vimentin, integrin α v, β 1, and β 3, one-way analysis of variance and post hoc analysis were used. A *p*-value<0.05 was considered significant.

Table 1. Demographic data of 13 cases

Primary site of cancer	Age/sex	Histologic finding	Number of metastasis in the spine (>3, 2, 1)	Number of extraspinal bone metastases (>3, 2, 1)	Tumor progression after radiotherapy or radiosurgery in spine (Y or N)
Liver 1	59/M	Hepatocellular carcinoma	2	1	Y
Liver 2	53/M	Hepatocellular carcinoma	2	0	N
Liver 3	54/M	Hepatocellular carcinoma	>3	0	No trial
Colon 1	57/M	Adenocarcinoma	>3	1	Y
Colon 2	26/F	Adenocarcinoma	>3	0	N
Colon 3	51/M	Neuroendocrine neoplasm	>3	0	Y
Lung 1	56/F	Non-small cell carcinoma	>3	0	N
Lung 2	47/F	Adenocarcinoma	>3	1	Y
Lung 3	49/M	Adenocarcinoma	2	0	N
Lung 4	72/F	Adenocarcinoma	>3	1	N
Breast 1	56/F	Infiltrating ductal carcinoma	>3	0	No trial
Breast 2	36/F	Infiltrating ductal carcinoma	2	0	N
Breast 3	59/F	Infiltrating ductal carcinoma	>3	1	N

RESULTS

Demographic data of enrolled patients

The mean age of enrolled patients was 51.9±11.28 years. The ratio of male and female was 6 : 7. Five patients had extraspinal bone metastasis including pelvis and femur. Eleven patients underwent adjuvant radiotherapy or radiosurgery (Table 1).

Immunohistochemistry (Fig. 1)

Vimentin protein expression was used as a representative mesenchymal marker. Vimentin stained intensely in all samples obtained from metastatic spine tumors (Fig. 1B, C, D). Vimentin staining appeared predominantly in spindle cells and focally in epithelioid cells. Integrins are usually localized at the cell membrane of epithelial cells. Tumor cells expressed integrin α v in all cases (Fig. 1E, G, H). The integrin α v showed mostly cell membrane expression in epithelioid cells of all tumor tissue. However, integrin β 1 expression was present weakly only in 38.4% (5/13) tissues (Fig. 1J, K, L); and integrin β 3 was consistently negative in all cases examined (Fig. 1N, O, P).

Analysis of gene expression by real-time RT-PCR

Vimentin gene expression was used as a representative EMT marker. Vimentin gene expression was higher in all metastatic specimens than in degenerative bone (Table 2, Fig. 2). The mean value of vimentin expression in metastatic specimens was 5418±8814. This result suggested that all metastatic specimens exhibited mesenchymal characteristics and would therefore be good candidates for comparative evaluation of integrin expression in degenerative bone. The mean values for integrins α v, β 1, and β 3 were 13±12.4, 3311±3952.4, and 5.0±6.0, respectively. All metastatic specimens had higher expression levels of integrins α v and β 1, as compared with those of degenerative bone. Moreover, expression levels of integrin α v obtained from patients

with breast carcinoma were significantly higher than others ($p=0.045$) (Fig. 3). However, the expression of integrin β 3 was variable. Although the expression of integrin β 3 was higher in metastatic specimens obtained from breast and colon carcinomas than those from degenerative bone, the differences between metastatic specimens and degenerative bone were less prominent, as compared with integrin α v and β 1. The values were lower in other specimens from hepatocellular and lung carcinoma than degenerative bone (Table 2). However, because the comparison of integrin expression between degenerative bone and tumor tissues was relative to 1 sample of degenerative bone tissue, statistical analysis was not significant. The qRT-PCR results of vimentin, integrin α v, β 1, and β 3 expression in control and tumor specimens were representative of 1 of 3 independent experiments.

DISCUSSION

Thirteen human specimens were obtained from metastatic spine tumors, whose primary cancer was colon cancer, hepatocellular cancer, lung cancer, and breast cancer. The enrolled patients underwent adjuvant radiotherapy or chemotherapy. The present immunohistochemistry and qRT-PCR data showed that the expression of vimentin and integrin α v and β 1 was higher in metastatic spine specimens, as compared with degenerative bone tissue.

Most malignant tumors are epithelial in origin, and malignant tumors are highly osteotropic²². Acquisition of an invasive mesenchymal phenotype is necessary for metastasis of a malignant tumor through the destruction of the epithelial side^{18,22}. Acquisition of EMT properties causes the polarized epithelial cells to become invasive migratory mesenchymal cells^{19,22}. Many EMT biomarkers, such as vimentin, N-cadherin, Snail1, FOXC2, and Twist, have been reported^{22,24}. Among these biomarkers, the intermediate filament protein vimentin is regarded as a requisite

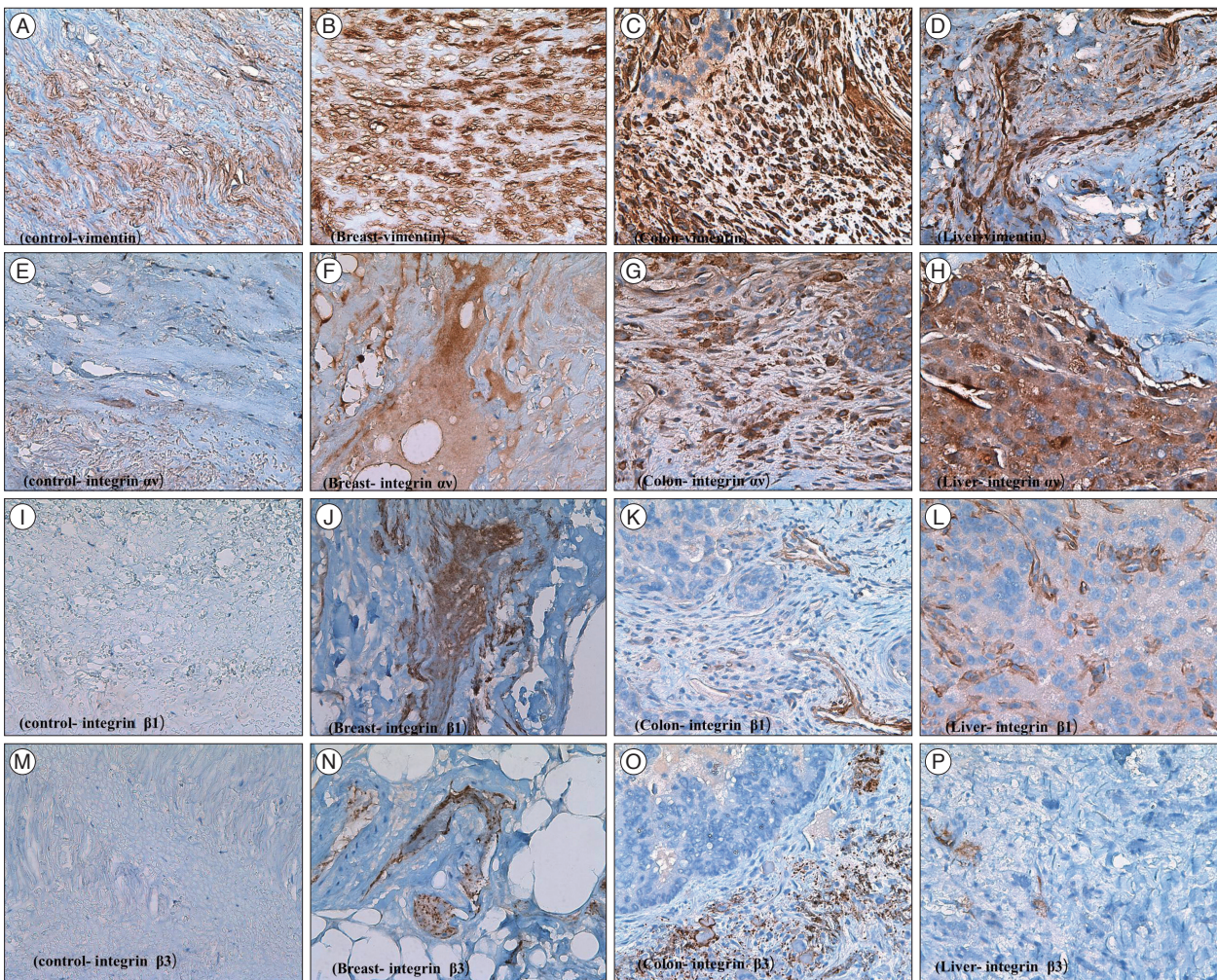


Fig. 1. Immunohistochemistry of tumor samples. The result of immunohistochemical staining. A : Control bone stroma, vimentin. B : Metastatic breast cancer, vimentin. C : Metastatic colon cancer, vimentin. D : Metastatic hepatocellular carcinoma, vimentin. E : Normal bone stroma, αv . F : Metastatic breast cancer, αv . G : Metastatic colon cancer, αv . H : Metastatic hepatocellular carcinoma, αv . I : Normal bone stroma, $\beta 1$. J : Metastatic breast cancer, $\beta 1$. K : Metastatic colon cancer, $\beta 1$. L : Metastatic hepatocellular carcinoma, $\beta 1$. M : Normal bone stroma, $\beta 3$. N : Metastatic breast cancer, $\beta 3$. O : Metastatic colon cancer, $\beta 3$. P : Metastatic hepatocellular carcinoma, $\beta 3$. Magnification of all slides ($\times 400$).

regulator of EMT induction and migration of malignant tumor cells^{7,24}. Elevated expression of vimentin is regarded as a poor prognostic factor in breast cancer²⁵. Therefore, an increase in the expression of vimentin may reflect the capacity for bone metastasis of malignant tumors. In the present study, vimentin expression level was higher in all metastatic specimens, as compared to degenerative bone suggestive of EMT in the tumor samples. The results of the present study indicated that the vimentin is an important biomarker of malignant tumor bone metastasis.

Integrins are a family of transmembrane glycoproteins that facilitate cell-to-cell and cell-to-extracellular matrix adhesion and cell migration^{11,13}. Integrins mediate inside-out and outside-in signaling, and may trigger the integrin-mediated cell-signaling cascade in metastasis¹¹. Malignant transformation, invasion, and metastasis to distant organs including the skeletal system, require the activity of many adhesive proteins including integrin family members. Metastatic tumor cells show differences in integrin activation, as compared with non metastatic tumor

cells^{1,3,16,26}. Among the 24 integrins identified, integrins such as $\alpha v\beta 3$, the $\beta 1$ family, and $\beta 3$ have been implicated in the processes involved in tumor metastasis, such as angiogenesis, adhesion, and progression¹⁵. The qRT-PCR results showed that the expression of integrins $\beta 1$ and αv was higher in metastatic specimens than non metastatic tissue such as the degenerative bone specimen. Integrin $\alpha v\beta 3$ is expressed in osteoclast cells and the selective inhibitor of integrin $\alpha v\beta 3$ was shown to decrease bone resorption in an animal model²⁷. The $\alpha v\beta 3$ integrin is an adhesion receptor expressed by breast cancer cells and osteoclasts^{16,27}. The present study showed that the expression of the integrin αv in specimens of breast carcinoma increased significantly, as compared to others. Integrin $\beta 3$ may be associated with angiogenesis during tumor progression and cancer invasion^{13,15}. In the present study, the expression of integrin $\beta 3$ was elevated only slightly in metastatic specimens, such as those of hepatocellular carcinoma and breast cancer, as compared with degenerative bone. This suggested that in breast carcinoma, integrin αv and

Table 2. The value of mRNA expression of vimentin and integrin α v, β 1, and β 3 in degenerative and metastatic spinal specimens

Cases	Vimentin	Integrin α v	Integrin β 1	Integrin β 3
Control (degenerative) case	1	1	1	1
HCC 1	797.1747	3.99935	2917.554	0.891636
HCC 2	32946.48	25.40257	14996.13	17.19953
HCC 3	1447.377	1.708462	3533.728	1.322626
Mean value	11730.3±18376.58	10.3±13.06	7149.1±6802.67	6.4±9.29
Colon 1	9762.764	6.629732	4986.484	9.184932
Colon 2	780.813	4.797411	1443.528	1.947615
Colon 3	3939.79	12.29258	4221.973	1.817886
Mean value	4827.7±4556.34	7.9 ±3.90	3550.6±1864.43	4.3±4.21
Lung 1	535.7248	2.126038	1231.922	0.118483
Lung 2	4414.293	17.56086	4650.749	17.27169
Lung 3	369.4229	1.125752	788.2939	0.180912
Lung 4	8704.042	8.591793	3940.139	2.189937
Mean value	3505.8±3937.22	7.3±7.56	2652.7±1927.37	4.9±8.27
Breast 1	2936.207	19.3515	101.9125	2.168851
Breast 2	3099.263	41.58894	146.8253	7.940409
Breast 3	713.0182	28.31228	85.85593	4.201479
Mean value	2249.4±1333.12	29.7±11.18	111.5±31.60	4.7±2.92
<i>p</i> value	0.604	0.045	0.173	0.982

HCC : hepatocellular carcinoma, Colon : colon cancer, Lung : lung cancer, Breast : breast cancer

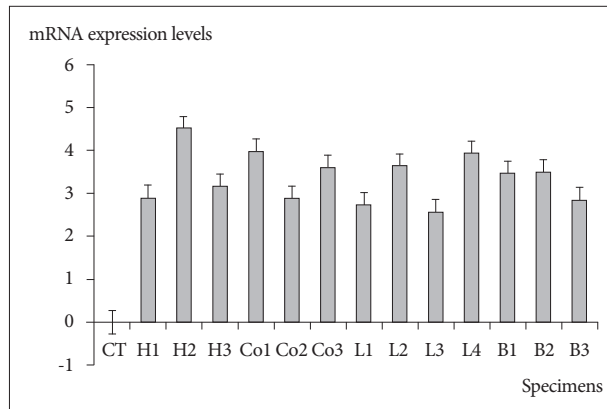


Fig. 2. Vimentin mRNA expression by qRT-PCR in degenerative and metastatic specimens. The values of mRNA in all metastatic specimens were expressed relative value 1 of the degenerative bone. However, this figure shows the logarithmic scale of vimentin mRNA expression in degenerative bone and all metastatic spinal specimens. Therefore, the value of mRNA in all metastatic specimens expressed relative value 0 of the degenerative bone in this figure. The mRNA value of was increased in all metastatic specimens, as compared to degenerative bone tissue. CT : control, degenerative bone, H : hepatocellular carcinoma, Co : colon cancer, L : lung cancer, B : breast cancer, qRT-PCR : real-time reverse transcription-polymerase chain reaction.

β 3 expression but not integrin β 1, may be related with tumor induced-osteolysis and angiogenesis. Therefore, integrin α v and β 3 are potential therapeutic targets for prevention of spine metastasis of malignant tumor including breast carcinoma.

In the present study, the immunochemical expression of integrins β 1 and β 3 was weak and absent, respectively. The discrepant results between qRT-PCR and immunohistochemistry might be due to freezing of the tumor samples. Immunohistochemical

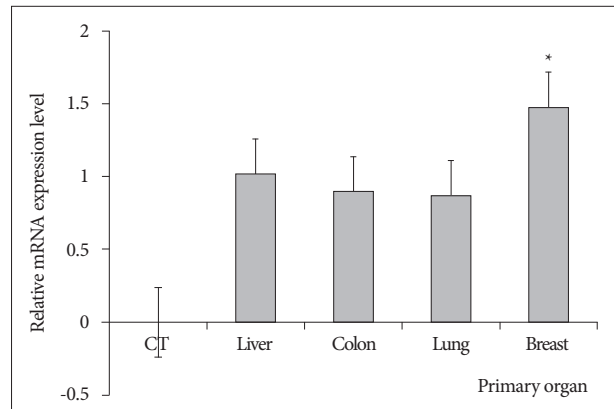


Fig. 3. Integrin α v mRNA expression by qRT-PCR in degenerative and metastatic specimens. Integrin α v mRNA in all metastatic specimens were expressed relative to value 1 of the degenerative bone. However, this figure shows the logarithmic scale of the mRNA expression levels of integrin α v in degenerative bone and all metastatic specimens. Therefore, the value of mRNA in all metastatic specimens expressed relative value 0 of the degenerative bone in this figure. The mean values integrin α v in breast specimens were significantly higher than those of others ($p=0.045$). * $p<0.05$. CT : control and degenerative bone, qRT-PCR : real-time reverse transcription-polymerase chain reaction.

results obtained from frozen tissue possibly do not reflect integrin expression accurately.

Limitations of study

There were several limitations of the present study. First, although the bone specimens were obtained from humans, the number of specimens was small and variable types of malignant tumors were included. Therefore, the evidence may be weak in

terms of providing insights into the relationships between integrins α v, β 1, and β 3 and the spine metastasis of malignant tumors, and any therapeutic potential of monitoring the expression of integrins. The present study measured only the expression of integrins α v, β 1, and β 3 using immunohistochemistry and qRT-PCR, which may not reflect the entire intracellular pathway related to integrins. Future studies of malignant tumors from more patients are needed to identify the pathological mechanisms and the relationships between integrins and malignancy. The present study also compared integrin expression between metastasized bone tissue and nonmetastatic bone tissue but not that of the primary tumor specimen. Future studies are required to compare integrin expression between malignant tumor and nonmalignant specimens, and between metastasized bone specimens and primary tumor tissues. However, because no studies have evaluated integrin expression in metastatic spine specimens, despite the limitations, the results of the present study provide meaningful information about the potential clinical implications of integrin β 1 and α v for spine metastasis.

CONCLUSION

Vimentin expression a biomarker of EMT was highest in specimens obtained from spinal metastatic tumors. The higher expression of the integrins α v and β 1 in metastatic specimens suggested that the integrins may be a potential target for the treatment of spine metastases from malignant tumors.

• Acknowledgements

This work was supported by the National Research Foundation of Korea (NRF) grant funded by the Korea government (MSIP) (No. 2010-0028631).

References

- Clézardin P : Integrins in bone metastasis formation and potential therapeutic implications. *Curr Cancer Drug Targets* 9 : 801-806, 2009
- Coghlin C, Murray GI : Current and emerging concepts in tumour metastasis. *J Pathol* 222 : 1-15, 2010
- Edlund M, Miyamoto T, Sikes RA, Ogle R, Laurie GW, Farach-Carson MC, et al. : Integrin expression and usage by prostate cancer cell lines on laminin substrata. *Cell Growth Differ* 12 : 99-107, 2001
- Enggebraaten O, Trikha M, Juell S, Garman-Vik S, Fodstad Ø : Inhibition of in vivo tumour growth by the blocking of host α (v) β 3 and α II(b) β 3 integrins. *Anticancer Res* 29 : 131-137, 2009
- Gudadze M, Kankava K, Mariamidze A, Burkadze G : Distribution of cancer stem cells in ductal invasive carcinoma of breast (review). *Georgian Med News* (222) : 44-50, 2013
- Hauschka PV, Mavrakos AE, Iafrazi MD, Doleman SE, Klagsbrun M : Growth factors in bone matrix. Isolation of multiple types by affinity chromatography on heparin-Sepharose. *J Biol Chem* 261 : 12665-12674, 1986
- Ivaska J : Vimentin : central hub in EMT induction? *Small GTPases* 2 : 51-53, 2011
- Jung KW, Won YJ, Kong HJ, Oh CM, Seo HG, Lee JS : Cancer statistics in Korea : incidence, mortality, survival and prevalence in 2010. *Cancer Res Treat* 45 : 1-14, 2013
- Mallini P, Lennard T, Kirby J, Meeson A : Epithelial-to-mesenchymal transition : what is the impact on breast cancer stem cells and drug resistance. *Cancer Treat Rev* 40 : 341-348, 2014
- Patel LR, Camacho DF, Shiozawa Y, Pienta KJ, Taichman RS : Mechanisms of cancer cell metastasis to the bone : a multistep process. *Future Oncol* 7 : 1285-1297, 2011
- Qin J, Vinogradova O, Plow EF : Integrin bidirectional signaling : a molecular view. *PLoS Biol* 2 : e169, 2004
- Roodman GD : Mechanisms of bone metastasis. *Discov Med* 4 : 144-148, 2004
- Schneider JG, Amend SR, Weilbaecher KN : Integrins and bone metastasis : integrating tumor cell and stromal cell interactions. *Bone* 48 : 54-65, 2011
- Sethi S, Macoska J, Chen W, Sarkar FH : Molecular signature of epithelial-mesenchymal transition (EMT) in human prostate cancer bone metastasis. *Am J Transl Res* 3 : 90-99, 2010
- Shen Z, Ye Y, Kauttu T, Seppänen H, Vainionpää S, Wang S, et al. : Novel focal adhesion protein kindlin-2 promotes the invasion of gastric cancer cells through phosphorylation of integrin β 1 and β 3. *J Surg Oncol* 108 : 106-112, 2013
- Sloan EK, Pouliot N, Stanley KL, Chia J, Moseley JM, Hards DK, et al. : Tumor-specific expression of α v β 3 integrin promotes spontaneous metastasis of breast cancer to bone. *Breast Cancer Res* 8 : R20, 2006
- Sterling JA, Edwards JR, Martin TJ, Mundy GR : Advances in the biology of bone metastasis : how the skeleton affects tumor behavior. *Bone* 48 : 6-15, 2011
- Tsai JH, Yang J : Epithelial-mesenchymal plasticity in carcinoma metastasis. *Genes Dev* 27 : 2192-2206, 2013
- Tsuji T, Ibaragi S, Hu GF : Epithelial-mesenchymal transition and cell cooperativity in metastasis. *Cancer Res* 69 : 7135-7139, 2009
- van den Hoogen C, van der Horst G, Cheung H, Buijs JT, Pelger RC, van der Pluijm G : Integrin α v expression is required for the acquisition of a metastatic stem/progenitor cell phenotype in human prostate cancer. *Am J Pathol* 179 : 2559-2568, 2011
- van der Horst G, van den Hoogen C, Buijs JT, Cheung H, Bloys H, Pelger RC, et al. : Targeting of α (v)-integrins in stem/progenitor cells and supportive microenvironment impairs bone metastasis in human prostate cancer. *Neoplasia* 13 : 516-525, 2011
- van der Pluijm G : Epithelial plasticity, cancer stem cells and bone metastasis formation. *Bone* 48 : 37-43, 2011
- van der Pluijm G, Sijmons B, Vloedgraven H, Deckers M, Papapoulos S, Löwik C : Monitoring metastatic behavior of human tumor cells in mice with species-specific polymerase chain reaction : elevated expression of angiogenesis and bone resorption stimulators by breast cancer in bone metastases. *J Bone Miner Res* 16 : 1077-1091, 2001
- Vuoriluoto K, Haugen H, Kiviluoto S, Mpindi JP, Nevo J, Gjerdrum C, et al. : Vimentin regulates EMT induction by Slug and oncogenic H-Ras and migration by governing Axl expression in breast cancer. *Oncogene* 30 : 1436-1448, 2011
- Yamashita N, Tokunaga E, Kitao H, Hisamatsu Y, Taketani K, Akiyoshi S, et al. : Vimentin as a poor prognostic factor for triple-negative breast cancer. *J Cancer Res Clin Oncol* 139 : 739-746, 2013
- Yoneda T : Cellular and molecular basis of preferential metastasis of breast cancer to bone. *J Orthop Sci* 5 : 75-81, 2000
- Zhao Y, Bachelier R, Treilleux I, Pujuguet P, Peyruchaud O, Baron R, et al. : Tumor α v β 3 integrin is a therapeutic target for breast cancer bone metastases. *Cancer Res* 67 : 5821-5830, 2007