

Preventable Sternocleidomastoid Muscular Atrophy after Neck Dissection

Nao Yamamoto, DDS, PhD
Natsuko Yoshimura Sawai,
DDS, PhD
Shunsuke Ishimoto, DDS,
PhD
Hide Ogura, DDS
Tomonao Aikawa, DDS, PhD
Mikihiko Kogo, DDS, PhD
Masaya Okura, DDS, PhD

Background: Modified radical neck dissection (mRND) [preserving the sternocleidomastoid muscle (SCM) and the spinal accessory nerve] and supraomohyoid neck dissection have become common surgical procedures for treating head and neck cancer. Postoperative severe asymmetry of the neck and severe atrophy of the SCM, however, have been demonstrated.

Methods: Using computed tomographic images, cross-sectional areas of the SCMs were measured in 99 patients with carcinoma of the oral cavity who underwent unilateral mRND or supraomohyoid neck dissection. An asymmetry index was used.

Results: Innervation to the SCM was preserved in 91 patients. The spinal accessory nerve and the innervation were sacrificed in 3 patients; the innervation was repaired in 5 patients. Sacrifice of innervation to the SCM resulted in extremely severe asymmetry. Repair of the innervation prevented severe asymmetry in 40%. Preservation of the innervation prevented severe asymmetry in 75% at the middle portion of the neck and in 56% at the lower portion after mRND.

Conclusion: Preserving innervation to the SCM and gentle handling of the nerve during neck dissection could prevent severe asymmetry after neck dissection. (*Plast Reconstr Surg Glob Open* 2015;3:e504; doi: 10.1097/GOX.0000000000000457; Published online 4 September 2015.)

Neck dissection is one of the most common operations for treating head and neck cancer. Modified radical neck dissection (mRND), which removes all lymphatic tissues in the neck while preserving one or more nonlymphatic structures [eg, spinal accessory nerve (SAN), internal jugular vein, and sternocleidomastoid muscle (SCM)], has been performed more frequently in recent years.¹ Preserving the SAN can reduce shoulder morbidity, including shoulder pain, weakness, restricted abduction, and a

wing scapula.²⁻⁴ Preserving the internal jugular vein helps to reduce cerebral and laryngeal edema and is useful for microvascular reconstruction.^{5,6} Preserving the SCM may maintain its ability to contract and may prevent cosmetic deformity of the neck. Few studies, however, revealed the postoperative condition of the SCM.⁶⁻⁸ These studies described frequent severe atrophies of the SCM after mRND and selective neck dissection. In this study, we examined SCM asymmetry after mRND and supraomohyoid neck dissection (SOHND) for carcinoma of the oral cavity under varying conditions of the innervation to the SCM. We also explored the importance of the innervation.

METHODS

Patients

During 2002 to 2013, a total of 99 patients with cancer of the oral cavity underwent unilateral neck

From the First Department of Oral and Maxillofacial Surgery, Osaka University Dental Hospital, Osaka University Graduate School of Dentistry, Osaka, Japan.

Received for publication April 13, 2015; accepted June 25, 2015.

Drs. Yamamoto and Sawai contributed equally to this work. Copyright © 2015 The Authors. Published by Wolters Kluwer Health, Inc. on behalf of The American Society of Plastic Surgeons. All rights reserved. This is an open-access article distributed under the terms of the Creative Commons Attribution-Non Commercial-No Derivatives License 4.0 (CCBY-NC-ND), where it is permissible to download and share the work provided it is properly cited. The work cannot be changed in any way or used commercially.

DOI: 10.1097/GOX.0000000000000457

Disclosure: The authors have no financial interest to declare in relation to the content of this article. The Article Processing Charge was paid for by a grant from the Japan Society for the Promotion of Science, Sports and Culture (#24593027 to MO).

dissection—mRND or SOHND—with preservation of the SCM. These patients were enrolled in this study. Patients who had undergone bilateral neck dissection or SCM resection were excluded. Informed consent was obtained from all patients, and the Institutional Review Board of Osaka University Dental Hospital, Osaka University Graduate School of Dentistry, approved the study (H20-E31-3).

Computed tomography (CT) scan was obtained before treatment and more than 6 months after treatment, which consisted of neck dissection and/or postoperative irradiation to the neck. For patients with several postoperative CT scans, the scan closest to the 12 months after treatment was analyzed. CT images were obtained with a multidetector CT scanner (LightSpeed QX/i or VCT; GE Healthcare, Milwaukee, Wis.). The field of view was 25×25 cm. The matrix size was 512×512, and slice thickness was 1.25–2.5 mm or 0.625–2.5 mm. Before and after contrast-enhanced CT scans were obtained at 120–140 kVp and 140–250 mA or 120 kVp and 100–330 mA (3D Auto mA).

Quantitative assessment of the SCM area was performed on 2 axial slices at the level of the hyoid bone

and the cricoid cartilage (Figs. 1, 2). The left and right SCMs were then identified. CT images were analyzed with the NIH ImageJ version 1.48 software (NIH, <http://imagej.nih.gov/ij/index.html>).⁹ To limit investigator bias, repeated measurements on the same CT image were separated by at least 1 week. To correct for age and interindividual differences in each muscle, the area of the affected side was expressed as ratio of the value on the unaffected side. An asymmetry index (AI) was also used.¹⁰ The AI was defined as follows:

$$AI(\%) = 100 \times (CSA_c - CSA_a) / 0.5(CSA_c + CSA_a),$$

where CSA_c and CSA_a are cross-sectional areas assessed at the control and affected sides, respectively. Index values >20% were defined as severe asymmetry,^{7,11} and those >50% were defined as extremely severe asymmetry.

Patients included 60 men (61%) and 39 women (39%), with a median age of 66 years (range, 21–91 years). The tumors were all located in the oral cavity and consisted of mobile tongue ($n = 46$), lower gum

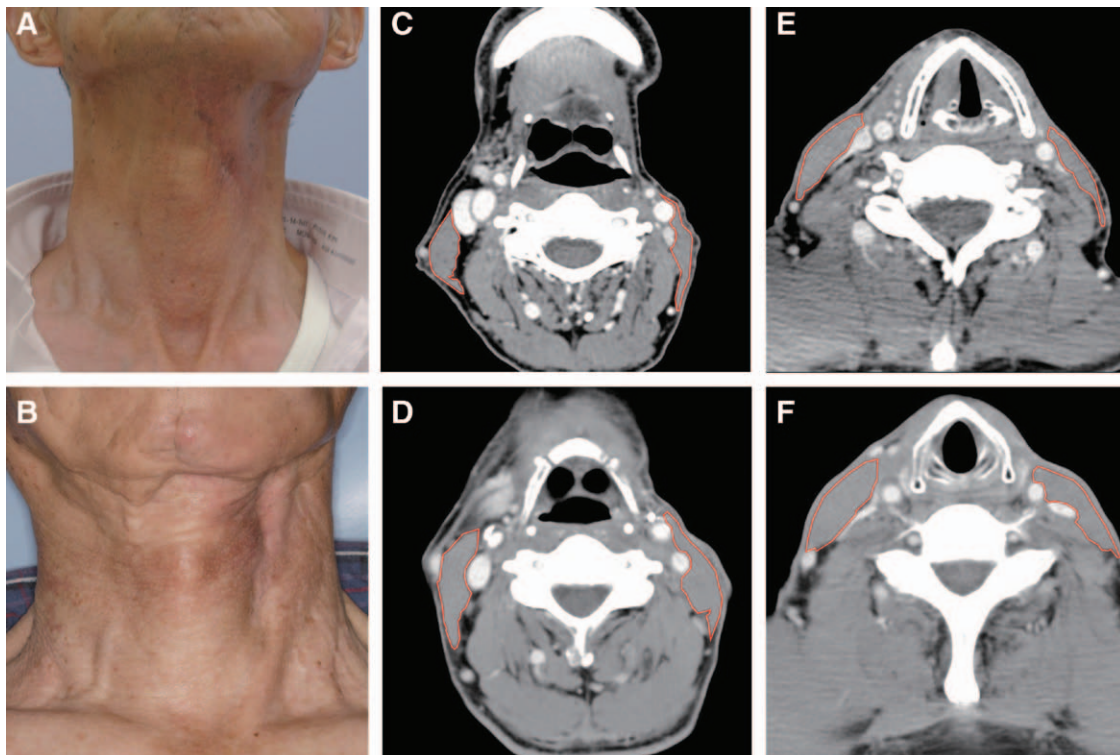


Fig. 1. Patients with cancers of the oral cavity. A, A 62-year-old man with T2N1M0 tongue cancer at 3 years after left supraomohyoid neck dissection. These CT images above were obtained 17 months after neck dissection. B, A 75-year-old man with T2N2bM0 with cancer of buccal mucosa at 6 years after left modified radical neck dissection. These CT images below were obtained 18 months after the treatment. C and D, CT images at the level of the hyoid bone. C, The CSA_c (right SCM) was 2.38 mm², CSA_a (left SCM) was 1.90 mm², and AI-H was 22.4%. D, The CSA_c (right SCM) was 3.55 mm², CSA_a was 3.12 mm², and AI-H was 12.9%. E and F, CT images at the level of the cricoid cartilage. E, CSA_c was 2.59 mm², CSA_a was 1.86 mm², and AI-C was 32.8%. F, CSA_c was 3.30 mm², CSA_a was 2.63 mm², and AI-C was 22.6%.

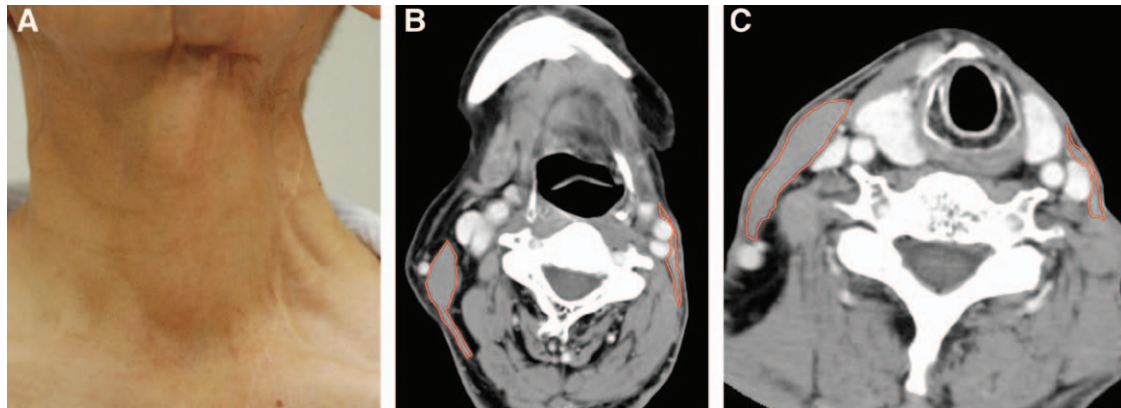


Fig. 2. A, A 68-year-old man with rT4aN1M0 tongue cancer 6 years after left modified radical neck dissection with postoperative radiotherapy. The spinal accessory nerve was sacrificed. The CT images were obtained 34 months after treatment. B, CT image at the level of the hyoid bone; CSAc was 2.62 mm², CSAa was 0.79, and AI-H was 107.3%. C, CT image at the level of the cricoid cartilage; CSAc was 2.98 mm², CSAa was 0.53 mm², and AI-C was 139.5%.

($n = 22$), upper gum ($n = 14$), floor of the mouth ($n = 11$), and buccal mucosa ($n = 6$). Among them, 95 were squamous cell carcinomas (well differentiated, 29; moderately, 56; poorly, 10), 2 were adenoid cystic carcinomas, 1 was a clear cell carcinoma, and 1 was a high-grade mucoepidermoid carcinoma. According to the TNM classification of the International Union against Cancer 7th edition/American Joint Committee on Cancer staging system (7th edition), 5 patients (5%) had clinical T1 tumors, 49 (49%) had T2 tumors, 13 (13%) had T3 tumors, 24 (24%) had T4a tumors, and 8 (8%) had T4b tumors. Clinical N0 classification was in 65 patients (66%), and 43 underwent elective neck dissection. The remaining 22 necks were initially observed with a wait-and-see policy and then underwent delayed therapeutic neck dissection after nodal diseases became apparent.¹² Sixteen patients (16%) had clinical N1 disease, 1 patient had N2a disease, and 17 patients had N2b disease (17%).

A total of 26 patients underwent radiotherapy to the neck. Twenty patients received postoperative radiotherapy (mean, 54 Gy; range, 48–68 Gy). Five patients received concurrent chemoradiotherapy: 2 cycles of cisplatin (80 mg/m²) and 5 cycles of fluorouracil (600 mg/m²) plus a mean of 60 Gy (range, 52–68 Gy) radiotherapy. One patient received radiotherapy (30 Gy) plus oral fluoropyrimidine S-1 (2 cycles of 80 mg/m² per day for 14 days). These 6 patients underwent salvage neck dissection after their chemoradiotherapy. Types of radiotherapy were three-dimensional conformal radiotherapy (3D-CRT) for 10 patients (mean, 60 Gy), conventional two-dimensional radiotherapy (2D-RT) from level I to level III for 7 patients (mean, 57 Gy), and 2D-RT from level I to level V for 9 patients (mean, 53 Gy).

Statistical Analysis

Sample distribution was examined by the chi-square goodness-of-fit test. Nonparametric Mann-Whitney *U* tests were used for continuous variables. Dichotomous variables were compared using the chi-square test with Yates correction. The two-sample *t* test or Wilcoxon rank-sum test was used to determine the difference between the pre-AI and post-AI values. A value of $P < 0.05$ was considered statistically significant. Statistical analyses were performed using StatView statistical software (version 5.0; Stata, College Station, Tex.) and Microsoft Excel 2013 (Microsoft, Edmonton, Wash.).

RESULTS

mRND (levels I–V) was performed for 32 patients synchronously with primary resection and in 22 patients metachronously (delayed mRND). SOHND (levels I–III) was performed in 45 patients. The submuscular recess (level Iib) was routinely dissected from all patients. The SAN and innervation to the SCM were sacrificed during 2 mRNDs and 1 SOHND. End-to-end innervation nerve repair with or without great auricular nerve transplant was performed during 4 mRNDs and 1 SOHND. In 91 patients, SAN and motor innervation to the SCM and the trapezius muscle were spared. Figure 3 shows box plots of the AIs of all measures taken for 99 patients. The mean \pm SD of pre-AI at the hyoid bone level (pre-AI-H) was $0\% \pm 8.7\%$ (range, -20.2% to 31.9%). The mean \pm SD of pre-AI at the cricoid cartilage level (pre-AI-C) was $-0.8\% \pm 11.0\%$ (range, -40.7% to 43.9%). The pre-AI-H and pre-AI-C followed normal distributions, whereas the post-AI-H and post-AI-C followed nonnormal distributions. The median time of post-treatment CT scans was 14 months after neck dissec-

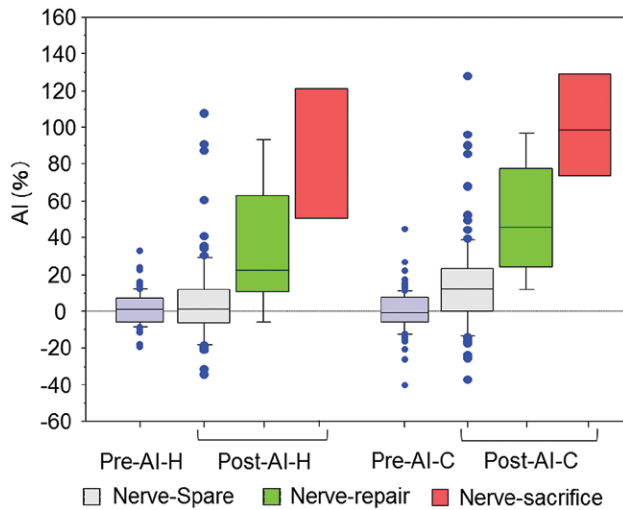


Fig. 3. Box plots of the pre-AI-H and pre-AI-C distributions and the post-AI-H and post-AI-C distributions according to the condition of the SCM innervation.

tion or postoperative irradiation of the neck (range, 6–72 months). Overall, the post-AI-H was $9.4\% \pm 28.7\%$ and post-AI-C was $19.5\% \pm 31.2\%$, which was significantly higher than the pre-AI values.

There were significant differences in the conditions of SCM innervation. All of the post-AI values with nerve sacrifice were $>50\%$. Also, sacrifice of the SCM innervation was significantly associated with extremely severe asymmetry. The mean post-AI-H was $82.0\% \pm 54.3\%$ (range, 50.7–144.6%). The mean post AI-C with the sacrifice was $101.3\% \pm 37.0\%$ (range, 65.6–139.5%). End-to-end SAN repair was performed in 5 patients and partly prevented SCM atrophy. Two of the 5 post-AI-H values for the SAN repair patients were $<20\%$, and two others indicated

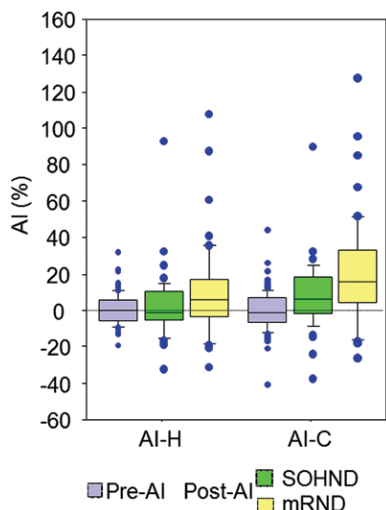


Fig. 4. Box plots of the AI-H and AI-C distributions according to the type of neck dissection.

extremely severe asymmetry in the middle portion. One patient with SAN repair had a post-AI-C value of $<20\%$. The other 2 patients had extremely severe asymmetry in the lower portion of the SCM. Preservation of the SCM innervation significantly inhibited SCM atrophy. The mean post-AI-H with preservation of the innervation was $5.2\% \pm 23.1\%$, and there was no difference between the pre- and post-AI-Hs ($P = 0.36$).

When patients were divided according to the type of neck dissection (Fig. 4), the mean difference between the pre- and post-AI-Hs was 0.1% for SOHND ($P = 0.38$). The mean difference for mRND was 8.8% , which was marginally significant ($P = 0.06$). If 3 maximum AI-H outliers (107.3%, 87.3%, and 60.7%) were excluded, the difference became completely nonsignificant ($P = 0.19$). The incidence of severe asymmetry in the middle portion of the SCM was 14% for SOHND and 25% for mRND. One patient (2%) with SOHND and 3 patients (6%) with mRND had extremely severe asymmetry. The mean post-AI-C was $15.1\% \pm 26.1\%$. There were significant differences between the pre- and post-AI-Cs for each type of neck dissection ($P < 0.0001$). The overall mean difference between the pre- and post-AI-Cs was 14.3% , and the mean differences were 9.1% for SOHND and 20.5% for mRND. SCM atrophy was more marked in the mRND patients than in those who underwent SOHND, as expected. The incidence of severe asymmetry in the caudal portion of the SCM was 28% with SOHND and 44% with mRND. One patient (2%) who underwent SOHND and 5 patients (10%) who underwent mRND had extremely severe asymmetry.

Because only 2 patients with SOHND received radiotherapy to the neck, a subset analysis on 48 patients with nerve-sparing mRND was performed to examine the effects of irradiation to the neck. Eight patients received 3D-CRT, 12 patients received 2D-RT, and 28 patients had no radiotherapy to the neck. In 3D-CRT, the dose given to the contralateral SCM was less than 25% of the total dose, whereas 2D-RT was bilateral irradiation. The mean difference between pre- and post-AI-H was nonsignificant irrespective of radiotherapy (Fig. 5). On the other hand, the mean value of post-AI-C was higher than that of pre-AI-C irrespective of radiotherapy. The mean differences were 20.1% for nonradiotherapy, 28.1% for 3D-CRT, and 14.4% for 2D-RT.

DISCUSSION

CT of the neck is one of the basic pretreatment examinations. It is also used for posttreatment surveillance of patients with head and neck cancers.

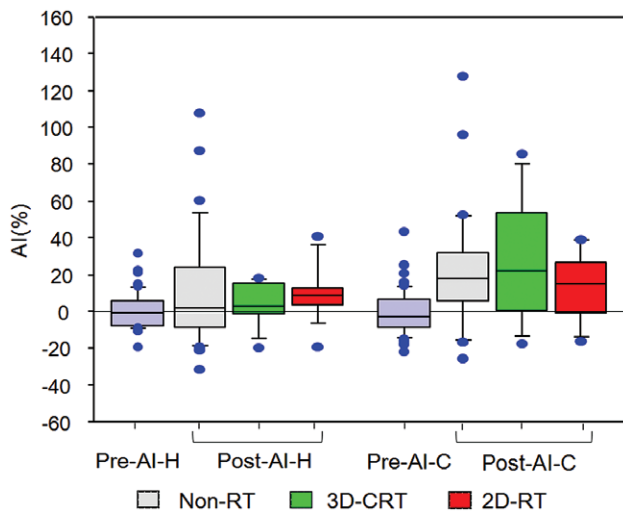


Fig. 5. Box plots of the AI-H and AI-C distributions according to radiotherapy to the neck.

Although CT images of the SCM in the cranial side are not always available for measurements because of artifacts generated by dental materials, those in the middle and in the caudal sides are generally scanned to identify primary tumors, recurrences, or lymph node metastases. CT images of SCM areas have been successful for evaluating the morphology and the atrophy of the muscle. Our results showed that sacrificing the innervation to the SCM gave rise to severe atrophy of the muscle (with extremely severe asymmetry). Repair of the innervation prevented SCM atrophy in certain patients, and preservation of the innervation prevented atrophy in a large number. The innervation to the SCM is the most important for preventing SCM atrophy.

SCM atrophy after mRND has often been mentioned, although few studies have revealed the post-operative condition of the SCM.⁶⁻⁸ These studies demonstrated significant SCM atrophy after mRND or selective neck dissection. Cuccia et al⁷ reported the frequency and the extent of SCM atrophy after mRND type III using ultrasonography. They used the absolute asymmetry index (AAI). AAI is just half the score of the AI used in this study because the denominator of the AAI fraction is the sum of bilateral SCM areas, whereas that of the AI fraction is the mean of bilateral SCM areas, with the same numerator. The percentage against the mean of bilateral SCM areas was considered to be more easily grasped than that against the sum, so AI was chosen for this study. Cuccia et al⁷ declared that >10% on the AAI (same as 20% on the AI) represented severe asymmetry and found that it was observed in 98% of the caudal portion of the SCM and in 80% of the middle portion after mRND that spared the SAN. Ohtawa

et al⁶ similarly found atrophy in 90% of the caudal portion of the SCM. In this study, severe asymmetry in the caudal portion (AI-C) was observed in 44% after mRND with nerve sparing and in 28% undergoing SOHND. The severe asymmetry in the middle portion (AI-H) was found in 25% during mRND and in 14% during SOHND. The mean difference in AI-H was only 0.1% for SOHND, suggesting no asymmetry in the middle portion of the SCM. The mean difference was 8.8% for mRND, suggesting less asymmetry. Muscle atrophy after mRND was usually marked in the caudal portion of the SCM rather than in the middle portion. Surprisingly, SOHND caused muscle atrophy more frequently at the cricoid cartilage level than at the hyoid bone level. Because the inferior surgical border of SOHND is the supraomohyoid muscle, blood supply to the lower third of the SCM from the subclavian branch^{6,7} cannot be disturbed. Another blood supply to the caudal half of the SCM is a branch of the superior thyroid artery,^{6,13} which is always encountered during SOHND. Therefore, SCM atrophy in the lower level may be partly attributed to damage to the branch of the superior thyroid artery. It seems difficult to preserve this blood flow to the SCM during SOHND and to avoid the damage.

There was asymmetry of the pre-AI-H and pre-AI-C values. None of the patients had extremely severe asymmetry of the SCM before treatment. However, 4 patients (4%) had severe pretreatment asymmetry in the middle portion and 6 (6%) had asymmetry in the lower portion of the SCM. The 95% confidence limits of pre-AI values were almost -20% and 20%. It is therefore reasonable that those with a post-AI >20% could be defined as having some degree of asymmetry. However, the degree of asymmetry needs to be reconsidered. Sacrifice of the SCM innervation resulted in extremely severe asymmetry (AI >50%) in the entire SCM. Some patients with nerve repair prevented severe asymmetry with functional recovery of the reinnervation. Others had extremely severe asymmetry, with no functional recovery of the reinnervation. Taken together, it is reasonable that AI values >50% indicate severe asymmetry. As shown in Figure 2, a neck with an AI value >100% had a neck concavity after mRND. By contrast, as shown in Figure 1, necks with post-AIs of 22-33% showed slight asymmetry rather than severe asymmetry. Also, this slight asymmetry is considered permissible because neck dissection consists of removing fibroadipose tissue in which cervical nodes are embedded. More studies are needed to define the degree of AI.

This present study failed to show the relationship between SCM atrophy and irradiation. The number of patients who received neck radiation was too small. However, the mean post-AI-C value

and the mean difference between pre- and post-AI-C for patients who received ipsilateral neck radiation (3D-CRT) were higher than for those with no neck radiation and higher than for those who received bilateral neck radiation (2D-RT). Ipsilateral neck radiation might cause SCM atrophy partly. Further studies seem to be needed to clarify the relationship.

Preserving the innervation to SCM did not totally prevent SCM atrophy. Intraoperative injury of the SAN and the branch to the SCM gives rise to SCM atrophy. Handling the nerve very gently is important and can prevent SCM atrophy to within a permissible range. Such handling could thus prevent neck asymmetry and cosmetic deformity, which in turn could improve quality of life.

CONCLUSIONS

Preserving the innervation to SCM and gentle handling of the SAN during neck dissection allows the surgeons to prevent severe asymmetry after neck dissection. We believe that such careful handling during the neck dissection helps to prevent cosmetic deformity and improves quality of life.

Masaya Okura, DDS, PhD

First Department of Oral and Maxillofacial Surgery,
Osaka University Dental Hospital
Osaka University Graduate School of Dentistry
Osaka 565-0871, Japan
E-mail: okura@dent.osaka-u.ac.jp

REFERENCES

1. Robbins KT, Clayman G, Levine PA, et al. Neck dissection classification update: revisions proposed by the American Head and Neck Society and the American Academy of Otolaryngology-Head and Neck Surgery. *Archiv Otolaryngol Head Neck Surg.* 2002;128:751–758.
2. Ahlberg A, Nikolaidis P, Engstrom T, et al. Morbidity of supraomohyoid and modified radical neck dissection combined with radiotherapy for head and neck cancer: a prospective longitudinal study. *Head Neck* 2012;34:66–72.
3. Cappiello J, Piazza C, Nicolai P. The spinal accessory nerve in head and neck surgery. *Curr Opin Otolaryngol Head Neck Surg.* 2007;15:107–111.
4. Orhan KS, Demirel T, Baslo B, et al. Spinal accessory nerve function after neck dissections. *J Laryngol Otol.* 2007;121:44–48.
5. Nagata T, Matsunaga K, Kawazu T, et al. Patency assessment of the internal jugular vein after neck dissection. *Int J Oral Maxillofac Surg.* 2006;35:416–420.
6. Ohtawa T, Katagiri M, Harada T. A study of sternocleidomastoid muscular atrophy after modified neck dissection. *Surg Today* 1998;28:46–58.
7. Cuccia G, Shelley OP, d'Alcontres FS, et al. Evidence of significant sternocleidomastoid atrophy following modified radical neck dissection type III. *Plast Reconstr Surg.* 2006;117:227–232.
8. Hudgins PA, Kingdom TT, Weissler MC, et al. Selective neck dissection: CT and MR imaging findings. *AJNR Am J Neuroradiol.* 2005;26:1174–1177.
9. Okura M, Kagamiuchi H, Tominaga G, et al. Morphological changes of regional lymph node in squamous cell carcinoma of the oral cavity. *J Oral Pathol Med.* 2005;34:214–219.
10. Brinkmann BH, Jones DT, Stead M, et al. Statistical parametric mapping demonstrates asymmetric uptake with Tc-99m ECD and Tc-99m HMPAO SPECT in normal brain. *J Cereb Blood Flow Metab.* 2012;32:190–198.
11. Emshoff R, Bertram S, Strobl H. Ultrasonographic cross-sectional characteristics of muscles of the head and neck. *Oral Surg Oral Med Oral Pathol Oral Radiol Endod.* 1999;87:93–106.
12. Okura M, Aikawa T, Sawai NY, et al. Decision analysis and treatment threshold in a management for the N0 neck of the oral cavity carcinoma. *Oral Oncol.* 2009;45:908–911.
13. Kumar V, Gaud U, Shukla M, et al. Sternocleidomastoid island flap preserving the branch from superior thyroid artery for the reconstruction following resection of oral cancer. *Euro J Surg Oncol.* 2009;35:1011–1015.