

Case Report

# Unusual Periaortic Mediastinal Recurrence of Pulmonary Adenocarcinoma: When Making Diagnosis Is Really Necessary

Umberto Caterino<sup>a</sup> Dario Amore<sup>b</sup> Cristiano Cesaro<sup>a</sup> Enzo Zamparelli<sup>c</sup>  
Flavio Cesaro<sup>d</sup> Alba Palma<sup>d</sup> Marcellino Cicalese<sup>b</sup> Dino Casazza<sup>b</sup>  
Raffaella Lucci<sup>e</sup> Alessandra Cancellieri<sup>f</sup>

<sup>a</sup>Unit of Bronchology, Monaldi Hospital, Naples, Italy; <sup>b</sup>Unit of Thoracic Surgery, Monaldi Hospital, Naples, Italy; <sup>c</sup>Unit of Anesthesia and Resuscitation Monaldi Hospital, Naples, Italy; <sup>d</sup>Unit of Emergency Medicine and Surgery and First Aid, C.T.O. Hospital, Turin, Italy; <sup>e</sup>Unit of Pathological Anatomy, Monaldi Hospital, Naples, Italy; <sup>f</sup>Division of Anatomic Pathology and Histology, Fondazione Policlinico Universitario A. Gemelli, IRCCS, Rome, Italy

## Keywords

Lung adenocarcinoma · Bronchial stump recurrence · Fluorodeoxyglucose positron emission tomography combined with computed tomography · Endobronchial ultrasound-guided transbronchial needle aspiration

## Abstract

We report an unusual mediastinal recurrence along descending thoracic aorta during oncologic follow-up in a 47-year-old female smoker issued by lung adenocarcinoma with a history of left lower lobectomy and lingulectomy en bloc followed by adjuvant chemotherapy for stage III A-N2. Regional recurrence occurring along the staple line was suspected and endobronchial ultrasound-guided transbronchial needle aspiration (EBUS-TBNA) combined to PET/CT allowed to reach definitive tissue diagnosis. High focal hypermetabolic activity on PET/CT at the site of suspect recurrence was necessary to check the lesion sampling by EBUS-TBNA.

© 2022 The Author(s).

Published by S. Karger AG, Basel

## Introduction

In locally advanced non-small-cell lung cancer, postoperative recurrence is the main cause for poor outcome with a 5-year survival rate of <35% [1]. The rate of post resection recurrence during the first 2 years has been reported to be significantly higher in stage III A non-small-cell lung cancer than in early stage disease [2].

Regional recurrence occurring in lymph nodes or along the staple line is quite common also if discrimination between loco-regional recurrence at the bronchial stump and granuloma or infection mass is difficult since scar tissue can present as a soft-tissue mass [1–3]. Fluorodeoxyglucose positron emission tomography combined with computed tomography (FDG-PET/CT) is now widely used for detecting recurrence and great value has been attributed to FDG uptake to differentiate benign recurrence and benign inflammatory changes.

High focal hypermetabolic activity on PET/CT at the site of suspect recurrence may be a better diagnostic indicator for tissue sampling and endobronchial ultrasound-guided trans-bronchial needle aspiration (EBUS-TBNA) represents an optimum diagnostic procedure in uncommon mediastinal recurrence of lung cancer [4]. We report a successful diagnostic procedure combining EBUS-TBNA with FDG-PET/CT in unusual mediastinal recurrence along the descending thoracic aorta during oncologic follow-up for lung adenocarcinoma surgery.

## Case Report

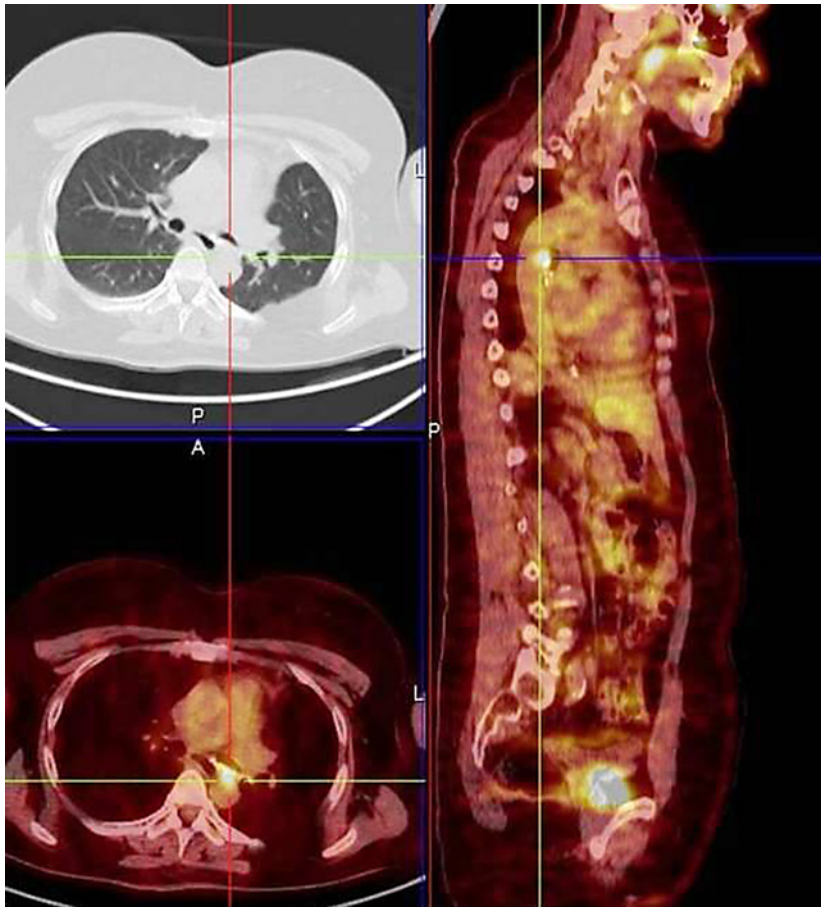A 47-year-old female smoker with a history of left lower lobectomy and lingulectomy en-bloc followed by adjuvant chemotherapy for stage III A-N2 (subcarinal lymph node metastasis) pulmonary adenocarcinoma was referred to our unit for suspected local recurrence. Two years after surgery, surveillance FDG-PET/CT revealed an avid mediastinal nodular lesion (SUV > 4, 5) located between the posterior wall of the left main stem bronchus and the descending thoracic aorta not clearly identifiable as a lymph node and close but not clearly along the staple line (Fig. 1).

On clinical examination, she had no dyspnea or cough and laboratory tests were within the normal range. Bronchoscopy showed mucosal irregularity of left main stem bronchus and pathologic specimen of bronchial biopsy resulted on chronic inflammatory fibrosis (Fig. 2).

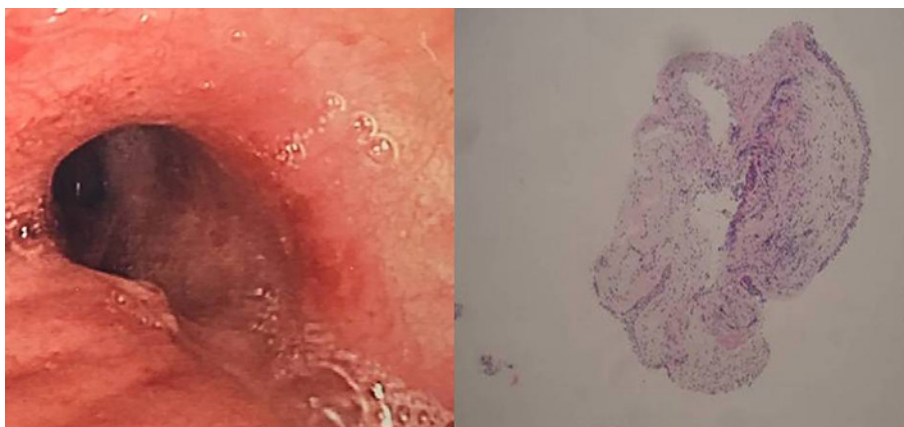
Endobronchial ultrasound was performed and a solid periaortic nodular lesion characterized by round shape, homogeneous echogenicity, and distinct borders was sampled on PET/CT scan guided. Pathological examination of the EBUS-derived specimens showed recurrence pulmonary adenocarcinoma (Fig. 3). Low-dose radiation therapy was performed and local control of nodular recurrence lesion was achieved.

## Discussion and Conclusion

Diagnosis of local recurrence of lung malignancy is extremely important, since staple-line thickening following pulmonary resection is a frequent occurrence which requires differential diagnosis from second primary lung cancer, infectious nodules, and granuloma [3]. Although serial CT scan follow-up is currently the standard methods to assess stability or growth of nodular lesion, differentiation of inflammation tissue post-surgery and tumor recurrence remains a potential pitfall for this procedure.

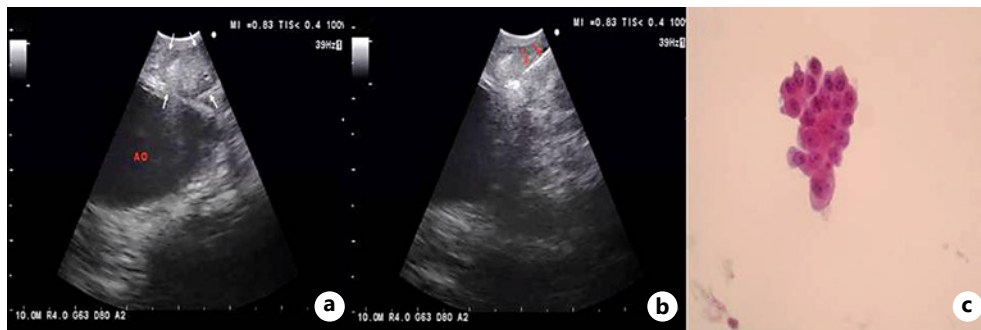

**Fig. 1.** PET/CT scan showing an avid 1-cm nodular lesion located between the posterior wall of the left main stem bronchus and the descending thoracic aorta.



**Fig. 2.** Bronchoscopy findings showed localized irregularity of mucosa corresponding to chronic inflammation on bronchial biopsy specimen (HE stain, ×100).

FDG-PET/CT after curative surgery therapy has become an additional option to differentiate inflammatory reaction from loco-regional recurrence, since, as single time point test, it allows biological characterization of tissue by visualizing glucose metabolism [5].



**Fig. 3.** a, b EBUS-TBNA image in B-mode showing a periaortic nodular lesion (white arrow) with the needle placed into the lesion (red arrow). c Cluster of pulmonary adenocarcinoma cells (HE stain,  $\times 200$ ).

The detection of high level of FDG uptake on or close to the bronchial stump after curative surgery helps determine the target for biopsy or needle puncture in patients with suspicious of recurrence [5, 6].

Over the last years, EBUS-TBNA is currently proposed as the first choice in the diagnosis of loco-regional relapse of lung cancer since in such instances, the mediastinal area and altered postoperative fibrotic mediastinum make other invasive diagnostic procedures as transcervical extended mediastinal lymphadenectomy and video-assisted mediastinal lymphadenectomy, challenging and unsafe [4, 7, 8]. “Xiauhi” comparing diagnostic yield of EBUS-TBNA and VAM in mediastinal LN staging in lung cancer confirmed that both techniques have similar performance, with EBUS-TBNA being less invasive, better tolerated, and with fewer complications [9].

The present study suggests that EBUS-TBNA combined with PET/CT represents an optimum diagnostic strategy in uncommon mediastinal recurrence of lung cancer. Furthermore, high focal hypermetabolic activity on PET/CT at the site of suspect recurrence allows to check the correct target for needle puncture of neoplastic tissue.

### Statement of Ethics

The procedures performed and described in this article were carried out in accordance with international guidelines and in accordance with the ethical standards of the Institutional Research Committee and the 1964 declaration of Helsinki and its later amendment. Ethical approval was not required for this study in accordance with local/national guidelines. Written informed consent was obtained from the patient for publication of this case report and any accompanying images.

### Conflict of Interest Statement

All authors involved in this work. C.U., A.D., C.C., E.Z., F.C., P.A., C.M., C.D.L., and R.C.A. declare no conflict of interest with this manuscript.

### Funding Sources

All authors involved in this work. C.U., A.D., C.C., E.Z., F.C., P.A., C.M., C.D., L.R., and C.A. declare that they have not benefited from any source of funding for this work.

### Author Contributions

C.U., A.D., C.C., E.Z., F.C., P.A., C.M., C.D., L.R., and C.A. were personally involved in the case reported. C.U., A.D., C.C., E.Z., F.C., P.A., C.M., C.D., L.R., and C.A. contributed to data collection and on the manuscript revision. C.U., A.D., C.C., E.Z., F.C., P.A., C.M., C.D., L.R., and C.A. contributed to the study design, interpretation, and manuscript revision. C.U., A.D., C.C., E.Z., F.C., P.A., C.M., C.D., L.R., and C.A. had full access to all the data in the work and take responsibility for data integrity, collection, accuracy, and description. All authors have read and approved the final version of the manuscript and agreed to be accountable for all aspects of the work. All authors involved in this work. C.U., A.D., C.C., E.Z., F.C., P.A., C.M., C.D., L.R., and C.A. declare that the manuscript, including related data, figures, and tables has not been published previously and is not under consideration elsewhere.

### Data Availability Statement

All data generated during this study are included in this article and can be inquired to the corresponding author.

### References

- 1 Cho S, Yum S, Kim K, Iheon S. Prognostic factors for post-recurrence survival in patients with completely resected Stage III (N2) non small lung cancer. *Eur J Cardiothorac Surg*. 2018;54(3):554–9.
- 2 Lou F, Sima CS, Rush VW, Jones DR, Huang J. Differences in patterns of recurrence in early-stage versus locally advanced non small cell lung cancer. *Ann Thorac Surg*. 2014;98(5):1755–61.
- 3 Mizukami Y, Takahashi Y, Adachi H. Pulmonary staple-stump granuloma after segmentectomy: two case reports and comparison with cases of stump recurrence. *Am J Case Rep*. 2019;20:1049–56.
- 4 Tournoy KG, Rintoul RC, Van Meerbeek JP, Carrol NR, Praet M, Buttery RC. EBUS TBNA for diagnosis of central parenchymal lung lesions not visible at routine bronchoscopy. *Lung cancer*. 2009;63:45–9.
- 5 Caulo A, Mirsadraee S, Maggi F, Leccisotti L, Van Beek EJR, Bonomo L. Integrated imaging of non small lung cancer recurrence: CT and PET-CT findings, possible pitfalls and risk of recurrence criteria. *Eur Radiol*. 2012;22:588–606.
- 6 Keyzer C, Corbusier F, Kyrtzi E, Sokolow Y, Gevenois PA, Goldman S. FDG uptake at the bronchial stump after curative lobectomy for non-small cell lung cancer. *Eur J Nucl Med Mol Imaging*. 2016;43(5):832–8.
- 7 JCLivi V, Morandi L, Cancellieri A, Annema JT, Trisolini R. The expanding role of endobronchial ultrasound in patients with centrally located intrapulmonary tumors. *Lung Cancer*. 2019;134:194–201.
- 8 Sanz-Santos J, Serra P, Andreo F, Torky M, Centeno C, Morán T, et al. Transbronchial and transesophageal fine-needle aspiration using a single ultrasound bronchoscope in the diagnosis of locoregional recurrence of surgically-treated lung cancer. *BMC Pulm Med*. 2017;17:46.
- 9 Ge X, Guan W, Han F, Guo X, Jin Z. Comparison of endobronchial ultrasound-guided fine needle aspiration and video assisted mediastinoscopy for mediastinal staging of lung cancer. *Lung*. 2015;193:757–66.