

Tuberculous Dactylitis in Adult – A Case Report and Review of Literature

Amit Kumar Yadav¹, Akshay KS¹, Shaswat Mishra¹, Sagar Bansal¹, Jitsen Manna², Arun Ranjan Napit³

Learning Point of the Article:

Anti-tubercular chemotherapy is the main treatment of tuberculous dactylitis.

Abstract

Introduction: Tubercular dactylitis is an uncommon form of musculoskeletal tuberculosis (TB), especially after the age of 5 years without any risk factors.

Case Report: A case of 49-year-old male presented with pain, swelling, and discharging sinus of proximal phalanx of third digit of the right hand with no constitutional symptoms for 2 years, with multiple failed treatment in form of antibiotic therapy. There were no risk factors such as immunodeficiency or any co-morbidities. The plain radiograph was suggestive of increased bone density with mild periosteal reaction; magnetic resonance imaging was suggestive of tubercular osteomyelitis. A biopsy was performed, the gene expert of the sample revealed TB with no drug resistance. The patient was managed with anti-tubercular drugs with complete resolution of clinical and radiological symptoms at 1-year follow-up.

Conclusion: TB should be considered a differential in patients with chronic soft-tissue or skeletal lesions even in the absence of the usual risk factors because with treatment it still carries a good prognosis.

Keywords: Tuberculous dactylitis, hand, phalanx.

Introduction

Osteoarticular tuberculosis (TB) accounts for only 1–3% of all the TB infections [1]. Hand and feet are involved in 14 and 10% of the case of osteoarticular TB [1, 2]. Tuberculous infection of the metatarsal, metacarpal, and phalanges of hand and feet is known as tuberculous dactylitis. Tubercular dactylitis is rare and it constitutes 2–4% of skeletal TB [3, 4]. The hand is more commonly involved than a foot in tuberculous dactylitis [5, 6, 7]. Tuberculous dactylitis is uncommon after the age of 5 years. It poses a serious diagnostic challenge due to its unusual presentations, inadequate diagnostic skills, limited understanding of the management, and many overlapping features with other diseases. Here, we report a rare case of TB dactylitis in adults without any risk factor diagnosed and treated successfully with anti-tubercular therapy.

Case Presentation

A 49-year-old male presented with pain, swelling, and discharging sinus over the proximal phalanx of the third digit of the right hand for 2 years. The patient was apparently asymptomatic 2 years back when he developed pain and swelling of the third digit which was insidious in onset and gradually progressive finally culminating with a discharging sinus 1 year back. There was no history of trauma, cough, weight loss, decreased appetite, and any other risk factors. The patient was previously treated at other centers with incision and drainage followed by antibiotics. On examination, there was a firm, globular swelling at the base of the third digit with a discharging sinus over the proximal phalanx of the third digit of the right hand (Fig. 1). No local inflammatory signs were found.

Author's Photo Gallery



Dr. Amit Kumar Yadav



Dr. Akshay KS



Dr. Shaswat Mishra



Dr. Sagar Bansal



Dr. Jitsen Manna



Dr. Arun Ranjan Napit

Access this article online

Website:
www.jocr.co.in

DOI:
10.13107/jocr.2020.v10.i07.1924

¹Department of Orthopaedic, Grant Government Medical College and Sir JJ Group of Hospitals, Mumbai, Maharashtra, India.

²Department of Orthopaedic, S.R.T.R Govt Medical College, Ambajogai, Maharashtra, India.

³Medical officer, Valley Health and Research Centre, Suryavinayak-5, Srijananagar Bhaktapur, Nepal.

Address of Correspondence:

Dr. Akshay KS,
Department of Orthopaedic, Grant Government Medical College and Sir JJ Group of Hospitals, Mumbai, Maharashtra, India.
E-mail: akshayks700@gmail.com

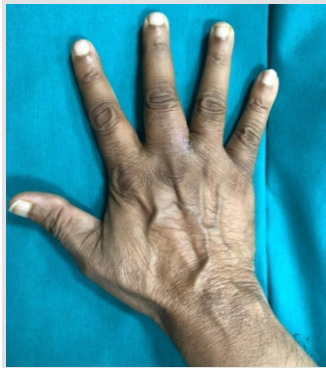

Figure 1: A swelling at proximal phalanx of third digit.

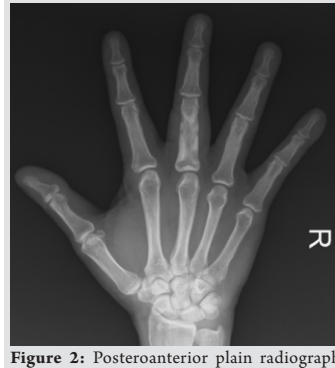

Figure 2: Posteroanterior plain radiograph increase bone density of proximal phalanx of third digit.

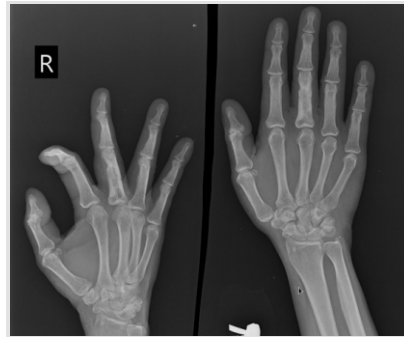


Figure 3: Oblique and posteroanterior view at 1-year follow-up.




Figure 4: Clinical picture at 1-year follow-up.

The finger range of motion was painful and restricted.

Plain radiographs showed increased bone density, mild periosteal reaction with an osteolytic lesion of proximal phalanx of the third finger (Fig. 2). The chest radiograph was normal. Local ultrasonography revealed dense internal echoes

measuring about $1.25 \times 1.37 \times 1.30$ cm. Magnetic resonance imaging (MRI) was suggestive of tubercular osteomyelitis. Erythrocyte sedimentation rate (ESR) and C reactive protein were elevated. Other laboratory parameters were normal. An open biopsy was done through Brunner's incision over the dorsal aspect of the lesion, sinus tract excised and the samples

Table 1: A brief summary of the previous studies.

Authors (year)	No of patients	Age (year)/sex	Outcome
Haider <i>et al.</i> (2011) [13]	2	55/male 4/male	Patient improved significantly with complete resolution of the symptoms of TB dactylitis with anti-tubercular therapy
Cahillet <i>et al.</i> (2011) [14]	1	33/male	A low serum Vitamin D levels were implicated with the development of the TB dactylitis. However, the outcome with the treatment could not be assessed as the patient was lost to follow-up
Krishnarajet <i>et al.</i> (2012) [15]	1	27/male, AIDS and pulmonary TB	Immune reconstitution inflammatory syndrome with acute tuberculous osteomyelitis of the calcaneum and disseminated mutilating tuberculous dactylitis involving both the fingers and toes healed with fixed deformities with restricted movements of joints following AKT and HAART therapy
Shantanuet <i>et al.</i> (2012) [16]	1	27/male	Patient with TB dactylitis involving the proximal phalanx of great toe responded well to AKT which healed with ankylosis of the interphalangeal joint
Sbai <i>et al.</i> (2015) [4]	4	43/male	Second phalanx of thumb, good outcome following AKT therapy
		56/female with breast cancer	Second phalanx of fifth finger, patient improved with AKT therapy
		38/female under corticotherapy	Second phalanx of fourth finger, Good outcome after AKT therapy
		64/female	First and second phalanx of fourth finger, Good outcome after AKT therapy
Vora <i>et al.</i> (2015) [17]	1	65/female	TB dactylitis involving the 1 st metacarpal, trapezium and carpometacarpal joint was treated with excisional arthroplasty and stabilization of the carpometacarpal joint with kirschner wire and anti-tubercular therapy
Phatak <i>et al.</i> (2016) [18]	1	20/male	TB dactylitis was diagnosed with concomitant presence of mycobacterium tuberculosis in the synovial fluid of the elbow swelling and discharge of the neck sinus
Fairaget <i>et al.</i> (2016) [19]	1	36/female	Proximal phalanx of fifth finger, good functional outcome
Thato <i>et al.</i> (2017) [6]	1	30/male	Multifocal tuberculous dactylitis involving both the hand and right foot in an immunocompetent person was successfully treated with anti-tubercular therapy
Sahliet <i>et al.</i> (2017) [5]	1	54/female	Second phalanx of major finger, good outcome was seen after anti-tubercular therapy
Murphy <i>et al.</i> (2020) [7]	1	29/male	Left second metatarsal neck treated with AKT
Present study	1	49/male	Proximal phalanx of third digit, good outcome at 1-year follow-up

were sent for histopathology which revealed chronic granulomatous inflammation. Gene-Xpert was done which detected TB and no resistance to first-line drugs was found.

Anti-tubercular therapy was started which included four drugs (isoniazid, rifampicin, pyrazinamide, and ethambutol) for 2 months, followed by three drugs (isoniazid, rifampicin, and ethambutol) for 7 months. The patient finger was immobilized for 1 month. The patient responded to the anti-tubercular therapy with complete resolution of the pain, swelling, and discharging sinus was satisfactorily healed. Radiographs of the right hand after the completion of the treatment course at 1 year revealed a decrease in the size of the osteolytic lesion with the resolution of associated sclerosis (Fig. 3). At 1 year follow-up, the patient had a full range of motion of fingers with no other symptoms (Fig. 4).

Discussion

Tuberculous infection of the metatarsal, metacarpal, and phalanges of hand and feet is known as tuberculous dactylitis. Tuberculous dactylitis is a rare <2–4% of skeletal TB [3, 4]. It is most common by hematogenous spread from the lungs. Fingers are more commonly affected than the toes, proximal phalanx of the index, and middle fingers are the most common sites involved [8, 9, 10]. Tuberculous dactylitis is uncommon beyond the age of 5 years after the formation of the epiphyseal center. It usually becomes symptomatic after 1–3 years following the initial infection. In children, the disease usually involves multiple bones. Children tubular bone has an abundant blood supply through a large nutrient artery. Infection is usually in the center of the marrow cavity and short tubular bone is gradually becomes tuberculous granuloma. When the nutrient artery of involved bone is occluded it leads to formation of the sequestrum, there is endosteal destruction and simultaneous new bone formation. It is also sometimes called “Spina ventosa” because radiologically it appears to be a cystic expansion of the phalanges. Typically, the disease presents as a chronic, painful, and progressive swelling of the fingers or toes, affecting most commonly the proximal phalanx and metacarpals of the hand. Multifocal involvement, sequestration, discharging sinus, and mutilation of the fingers occur more often in children or patients who are suffering from concomitant immunodeficiency. Abscess and sinus formation is common leading to secondary bacterial infections. A radiologic picture usually shows an osteolytic lesion, mild to no periosteal reaction, areas of bone sclerosis, and destruction. MRI is the modality of choice to see early marrow and soft-tissue involvement. In spina ventosa, the bone may take shape of honey combing, diffuse infiltration, cystic lesion, or rarely bone atrophy. Tuberculous dactylitis commonly occurs in the

background of tubercular contagion or a state of immunosuppression and for it to present in the absence of both is a rare entity, as it was in our case. The mainstay of diagnosis of tubercular dactylitis remains the histopathological examination of the biopsy specimens, demonstration of mycobacterium TB on Gene-Xpert studies, localizing acid-fast bacilli on Z-N stain. The culture of mycobacterium from bone tissue remains the Gold standard. Laboratory investigations such as white blood counts, differential counts, ESR, and CRP do not aid in the diagnosis of tubercular dactylitis; however, they tend to help in ruling out the other possible diagnosis. The treatment of TB dactylitis consists of long-term anti-tubercular therapy consisting of four drugs isoniazid, rifampicin, pyrazinamide, and ethambutol for 2 months, followed by isoniazid and rifampicin for 6–12 months [11]. Excellent clinical-radiological response is seen irrespective of the stage of the disease in which it is started [9, 11]. Ankylosis of the joint remains one of the dreaded complications of the disease; however, in most cases; complete remission is seen following the completion of anti-tubercular chemotherapy.

Differential diagnosis includes chronic pyogenic osteomyelitis, syphilitic dactylitis, fungal dactylitis, and conditions with lytic lesions (enchondroma or fibrous defect). Other conditions include sarcoidosis, brucellosis, psoriasis, hyperparathyroidism, and leukemia. Pyogenic osteomyelitis of the fingers should be considered when there is a local rise of temperature, severe tenderness over the affected parts, high-grade fever, and loss of finger movements with elevated white counts. Tuberculous dactylitis usually progresses through an indolent course, rarely manifesting systemic symptoms. The lack of sequestration and the presence of diffuse osteopenia distinguish tuberculous infection from pyogenic infection.

Khanna et al. reported a case of TB of distal phalanx of great toe presenting as painless paronychia with pseudopterygium and nail dystrophy [12].

We have done a review of literature in the past 10 years on tuberculous dactylitis in adults and tabulated (Table 1).

Conclusion

Tuberculous dactylitis usually affects children <5 years of age; it needs to be considered as a differential diagnosis in adults with unusual soft-tissue or skeletal lesions even in the absence of usual risk factors such as tubercular contagion, immunodeficiencies, and primary foci of TB elsewhere in the body. A high degree of suspicion accompanied by proper clinical examination and radiology helps in diagnosing this rare entity. Once the diagnosis is confirmed by biopsy, Anti-tubercular chemotherapy is the treatment of choice.

Clinical Message

Tuberculous dactylitis should be considered a differential diagnosis when a patient presents with soft-tissue or skeletal lesion of hand and foot so early diagnosis can be done.

References

1. Yadav AK, Kumar GS, Akshay KS, Harsoor A, Mane A, Mishra S. Tuberculosis of calcaneus-a case report and review of literature. *J Orthop Case Rep* 2020;10:24-6.
2. Ritz N, Connell TG, Tebruegge M, Johnstone BR, Curtis N. Tuberculous dactylitis-an easily missed diagnosis. *Eur J Clin Microbiol Infect Dis* 2011;30:1303-10.
3. Subasi M, Bukte Y, Kapukaya A, Gurkan F. Tuberculosis of the metacarpals and phalanges of the hand. *Ann Plast Surg* 2004;53:469-72.
4. Sbai MA, Benzarti S, Sahli H, Sbei F, Maalla R. Osteoarticular tuberculosis dactylitis: Four cases. *Int J Mycobacteriol* 2015;4:250-4.
5. Sahli H, Roueched L, Sbai MA, Bachali A, Tekaya R. The epidemiology of tuberculous dactylitis: A case report and review of literature. *Int J Mycobacteriol* 2017;6:333-5.
6. Thatoi P, Parida M, Barik R, Das B. Multifocal tubercular dactylitis: A rare presentation of skeletal tuberculosis in an adult. *J Clin Diagn Res* 2017;11:OD23-4.
7. Murphy MC, Murphy AN, Hughes H, McEneaney OJ, O'Keane C, Kavanagh E. Multimodal imaging of spina ventosa (TB dactylitis) of the foot. *Radiol Case Rep* 2020;15:1373-6.
8. Saibaba B, Gopinathan NR, Santhanam SS, Meena UK. Tubercular dactylitis in children. *J Pediatr Orthop B* 2017;26:261-5.
9. Kotwal PP, Khan SA. Tuberculosis of the hand: Clinical presentation and functional outcome in 32 patients. *J Bone Joint Surg Br* 2009;91:1054-7.
10. Chowdary VR, Kumar PS, Rajendra PS. Tuberculosis of short tubular bones: A rare presentation. *J Evol Med Dent Sci* 2014;3:4468.
11. Ranjan R, Goel L, Sud A, Sinha A, Tulika, Kumar R. Bilateral tubercular dactylitis: Unusual presentation of an usual disease. *Indian J Tuberc* 2019;66:346-52.
12. Khanna D, Chakravarty P, Agarwal A, Gupta R. Tuberculous dactylitis presenting as paronychia with pseudopterygium and nail dystrophy. *Pediatr Dermatol* 2013;30:172-6.
13. Haider N, Aziz M, Khan AQ, Zulfiqar M. Tubercular dactylitis and multifocal osteoarticular tuberculosis-two rare cases of extrapulmonary tuberculosis. *BMJ Case Rep* 2011;2011:bcr0920114800.
14. Cahill KC, Conroy FJ, Brown A, Dunlop RL, Eadie P, Keane J. Tuberculous dactylitis in the setting of low serum Vitamin D: A case report. *J Plast Reconstr Aesthet Surg* 2011;64:e321-4.
15. Krishnaraj R, Chockalingam C, Krishnarajasekhar OR, Ayyamperumal M, Narayanan R, Satagopan K. Immune reconstitution inflammatory syndrome (IRIS) with acute tuberculous osteomyelitis and disseminated mutilating tuberculous dactylitis in a person living with HIV and AIDS (PLHA): A case report. *J Int Assoc Physicians AIDS Care (Chic)* 2012;11:289-92.
16. Shantanu K, Kumar S, Jain S. Tubercular dactylitis with discharging sinus in an adult patient. *BMJ Case Rep* 2012;2012:bcr1120115249.
17. Vora HJ, Patil S, Latkar C, Sawant S. Excision arthroplasty for first CMC joint tuberculous osteomyelitis. *J Orthop Case Rep* 2015;5:25-7.
18. Picture C. Tubercular dactylitis. *QJM* 2016;109:277-8.
19. Fairag R, Hamdi A. Tuberculous dactylitis : Case presentation and functional outcome. *J Orthop Case Rep* 2016;6:22-4.

Conflict of Interest: Nil
Source of Support: Nil

Consent: The authors confirm that Informed consent of the patient is taken for publication of this case report

How to Cite this Article

Yadav AK, KS Akshay, Mishra S, Bansal S, Manna J, Napit AR. Tuberculous Dactylitis in Adult – A Case Report and Review of Literature. *Journal of Orthopaedic Case Reports* 2020 October;10(7): 72-75.

